

CASE REPORT

Four narrow dental implants and conventionally cast bar-supported removable hybrid acrylic complete denture as a therapeutic modality for terminal dentition

Mohammed A. Alfarsi | Sharaz Shaik 

Department of Prosthetic Dentistry,
College of Dentistry, King Khalid
University, Abha, Saudi Arabia

Correspondence

Sharaz Shaik, Department of Prosthetic
Dentistry, college of dentistry, King Khalid
University, Abha, Saudi Arabia.
Email: sharazshaik@gmail.com

Funding information

The case was self-funded.

Abstract

The report portrays four narrow implants and cast bar-supported removable hybrid acrylic complete dentures and other terminal dentition treatment options in the maxilla. The therapeutic module could be efficient and satisfactory to patients.

KEY WORDS

cast bar overdenture, hybrid acrylic dentures, implant-supported complete dentures, narrow implants, shortened dental arch

1 | INTRODUCTION

This report describes the phases involved and discusses the pros and cons of four narrow implants and conventionally cast bar-supported removable hybrid acrylic complete dentures and other treatment options available for terminal dentition in the maxilla. Within the report's limitations, the therapeutic module could be efficient and satisfactory to patients.

Edentulism and lack of functional dentition (<20 teeth) are highly prevalent conditions; reports on the US population suggest a prevalence of complete edentulism at 4.9% in 2012 and lack of functional dentition at 31.8% in 2016.^{1,2} The prevalence is significantly higher among the aged population of developing countries such as India, Mexico, and Russia.³ Though there is a declining trend, the absolute number of the population remain considerably high.¹ In addition to the common dysfunctions of mastication, esthetics, and speech, the patients with several missing teeth and occlusal discrepancies suffer from temporomandibular joint dysfunction (TMD).⁴

Treatment planning of terminal dentition is a challenging process. A decision to conserve the teeth or to extract teeth and employ implants is a multifaceted process. Appropriate

treatments to conserve the teeth may not always be successful. Other therapeutic modalities on hand for a potentially edentulous patient comprise extractions followed by a typical complete denture or overdentures or implant-retained removable denture or implant-supported fixed prosthesis. An implant-retained removable hybrid complete denture could be a reliable option compared to a conventional complete denture.^{5,6} The success rate of an implant-supported removable complete denture (RCD) and fixed complete dentures (FCD) are comparable.⁷ A removable prosthesis can provide adequate mastication, esthetics, and hygiene.^{5,6,8,9} On the other hand, implant-supported FCD may complicate the patient's hygiene maintenance in certain patients.¹⁰ The survival rate of maxillary implants is less than that of the mandible owing to the difference in alveolar ridge morphology and biomechanics¹¹; the maxillary sinus in the posterior region and narrow ridges in the anterior region confound the surgery further.

This report portrays maxillary terminal dentition treatment with tooth extractions followed by four soft tissue level narrow implants splinted with a conventionally cast bar having locator attachments. A hybrid acrylic RCD in the maxilla was fabricated against a shortened mandibular natural

This is an open access article under the terms of the Creative Commons Attribution-NonCommercial License, which permits use, distribution and reproduction in any medium, provided the original work is properly cited and is not used for commercial purposes.

© 2020 The Authors. *Clinical Case Reports* published by John Wiley & Sons Ltd.

dentition. This report describes the phases involved and discusses the pros and cons of implant-retained RCD and other treatment options available for a similar situation.

2 | CASE PRESENTATION

A 50-year-old healthy female patient reported with unesthetic fixed partial dentures (FPDs) in the maxilla, halitosis, masticatory deficiency, and chronic pain in the temporomandibular joints (TMJ). Extra orally, the patient exhibited no significant soft tissue menton deviation.¹² There was evidence of TMD, bilateral clicking on opening and closing plus tenderness on the joint's palpation. The patient's smile line revealed the incisal, middle, and a part of the cervical one-third of the anterior maxillary teeth 13.

There was generalized dental biofilm, gingivitis, and bleeding on probing. The patient had an overall plaque index score (Silness & Loe 1964) of 1.4 and a gingival index score (Loe & Silness 1963) of 1.9. The mean probing depth (PD) in the maxilla was 3.5 mm, and the mean clinical attachment level (CAL) was -5.3 mm. The PD and CAL in the mandible were 1.2 and -2.3 , respectively. Tooth # 16 and 26 had class II furcation involvement (Nevins and Capetta 1998). Teeth #16, 13, 12, 21, 22, 23, 26, and 34 were nonresponsive to thermal pulp testing. (Figure 1) The acrylic veneered metal fixed partial dentures and composite restorations were discolored (Figures 1 and 2). Radiographically, 12, 21, and 22 revealed endodontic obturation, post and core, and periapical

radiolucency (Figure 3). There was secondary caries under the crowns of teeth #14, 16, and 22. The bilateral maxillary sinuses were extensively pneumatized, extending from the second premolar to second molar region. (Figure 3).

The patient had long-standing missing posterior stoppers. She had a habitual mandibular forward positioning to attain a severe crossbite in both anterior and posterior regions (Figure 2). Manual mandibular manipulation to centric relation position returned an edge-to-edge anterior relation. There was a midline shift in the anterior region of approximately 2 mm to the right side (Figure 2). During the mandibular lateral movements, only a minimal shift was noted; the patient had an open-and-close chewing pattern and showed a tendency toward anterior guidance.

According to the intraoral and radiographic evaluation (Figures 1, 2, and 3), the patient was diagnosed with moderate chronic periodontitis, pulp necrosis, asymptomatic apical periodontitis, secondary caries, endodontic failures, esthetic failures in acrylic veneered fixed partial denture, TMD, and anterior crossbite. The maxillary teeth except tooth #11 had a questionable prognosis. The patient was offered appropriate treatments to preserve and restore the maxillary teeth with metal-reinforced fixed temporary restorations and a partial removable prosthesis to rehabilitate the mandibular posterior areas. However, the patient was unwilling to accept the option due to past dental experiences and long-term prognosis concerns. The patient was self-motivated for implant dentures and expected the dentures to function similar to natural teeth. After a detailed conversation of therapeutic

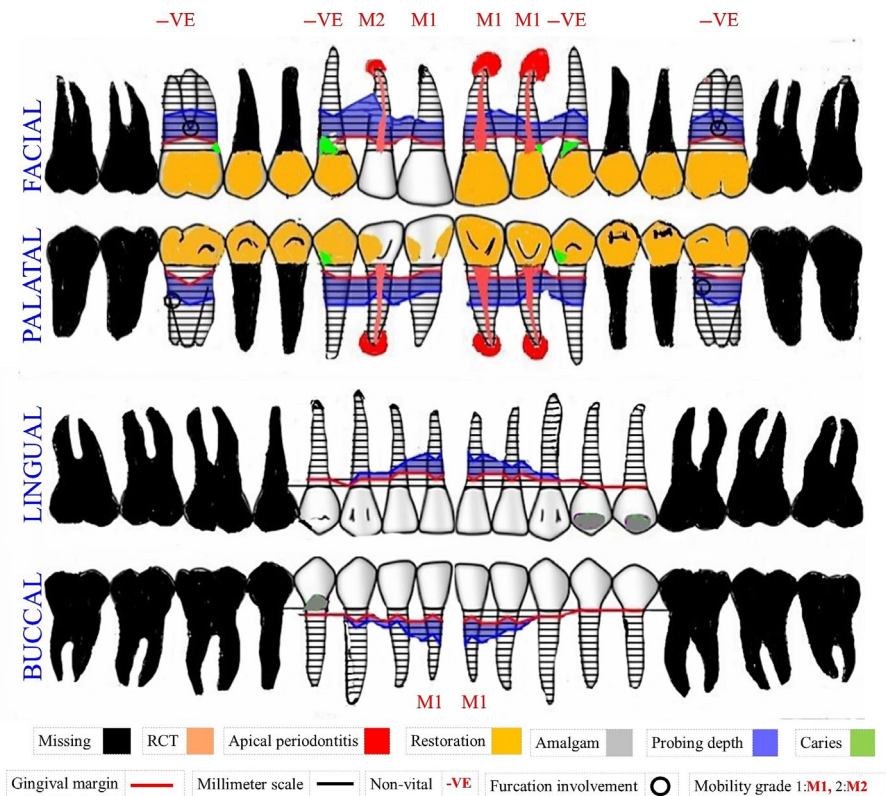


FIGURE 1 The patient's pretreatment comprehensive dental chart

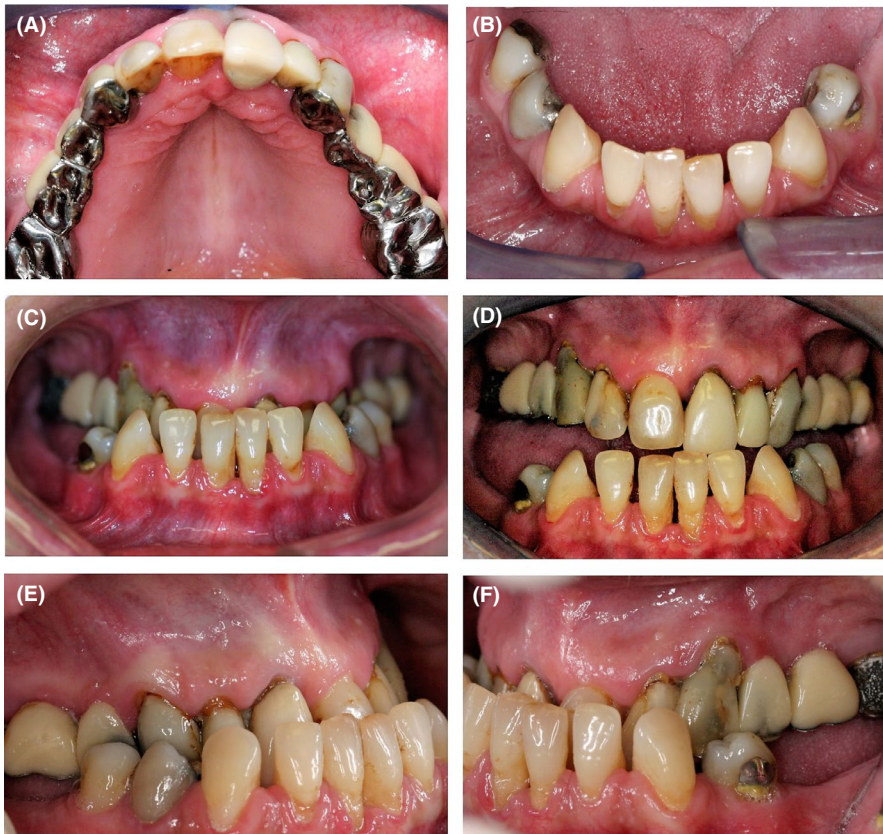

FIGURE 2 Preoperative intraoral condition. A, Occlusal view of the maxillary arch displaying unaesthetic restorations. B, Mandibular arch displaying amalgam restorations in tooth no. 35, 44, and 45. C, Frontal view of the teeth in habitual bite displaying deep crossbite. D, Frontal view of the mandible in edge to edge relation displaying midline shift. E, Right lateral view of the teeth in habitual bite displaying deep crossbite. F, Left lateral view of the teeth in habitual bite displaying deep crossbite

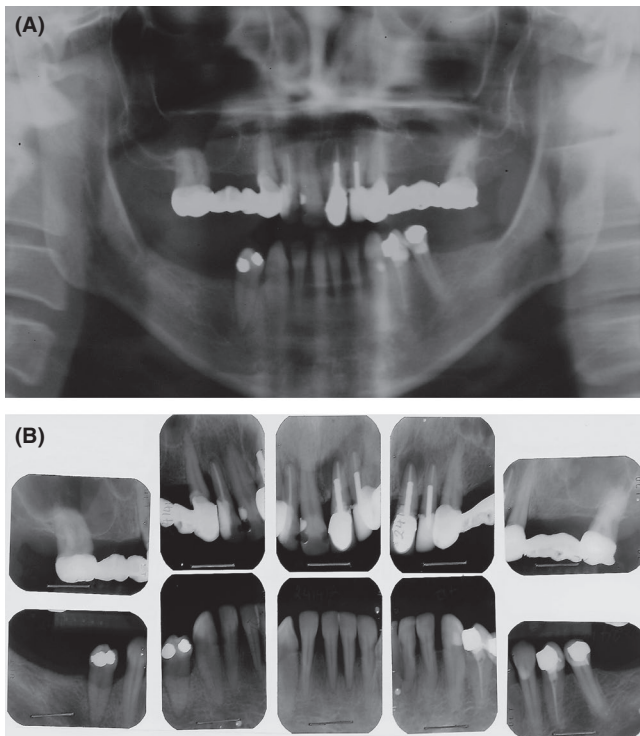


FIGURE 3 Preoperative radiographic evaluation. A, Preoperative orthopantomography. B, Preoperative intraoral periapical radiographs

options and monetary considerations, she agreed to have implant-retained, removable complete denture in the maxilla. However, she was not willing for complicated sinus lift surgical procedures. She intended to have mandibular molar

implant-supported crowns later, only if deemed necessary for better mastication. Prosthodontic rehabilitation was planned to extend over 1 year. Since she had no limiting factors to undergo surgical procedures, she was categorized as American Society of Anesthesiologists Physical Status-1 (ASA PS I).¹³

3 | TREATMENT

3.1 | Immediate dentures and raise in the vertical dimension

After extraction of maxillary posterior teeth and FPD on the left side, upper and lower impressions were made. In a later appointment, the vertical dimension of occlusion was recorded; there was a raise of 7 mm at the incisal region from that of the patient's habitual bite. After a try-in of the waxed denture, an immediate denture was processed. All the remaining maxillary teeth except the tooth #17 were extracted, and the denture was inserted and followed up after a week. The denture was relined with a temporary relining material (GC Soft-Liner Tissue Conditioner, GC Corporation) after a month.

3.2 | Surgical guide preparation

Two months after immediate denture insertion, the Immediate denture was copied to fabricate a radiographic guide that complements implant3D software (med3D implantology, med3D

GmbH). The tooth #17 helped retain the radiographic guide. The implants were virtually placed using the Med3D software.¹⁴ Based on the med3D analysis, the radiographic guide was modified to serve as a surgical guide. Metal sleeves were placed in the acrylic surgical guide in the designated implant locations (Figure 4).

3.3 | Guided surgical implantation

The surgical guide was retained with an anchor pin on the left and tooth #17 on the right, and the mucosa along the circular sleeves was excised using a manual tissue punch. The surgical template was removed to detach the excised mucosa with a tweezer and replaced. According to the standard protocol for Straumann implants, a drill guide was placed in the sleeve, and drilling was performed through the surgical

guide. After executing the drilling process in all the implant sites, the surgical guide was removed, a full-thickness mucoperiosteal flap was reflected, and irregular bony spicules leveled. The sockets were irrigated with sterile saline, and four implants (Straumann standard implants, Straumann®) were inserted in their respective sockets, free-hand (Table 1). Tissue level healing caps were screwed. Particulate mineralized bone allograft (Puros Allograft, Zimmer Dental, Inc) was applied to the exposed implants, secured by a resorbable collagen barrier membrane (OSSIX Plus, Datum Dental Ltd), and the flap was sutured closely around the healing caps (Figure 5).

Cap. Amoxicillin (500 mg) thrice daily for 5 days and tab. Diclofenac sodium (50 mg) twice daily for 3 days was advised. The subsequent week, the denture was adjusted and relined with temporary soft liner (Gc Soft-Liner Tissue Conditioner, GC Corporation).

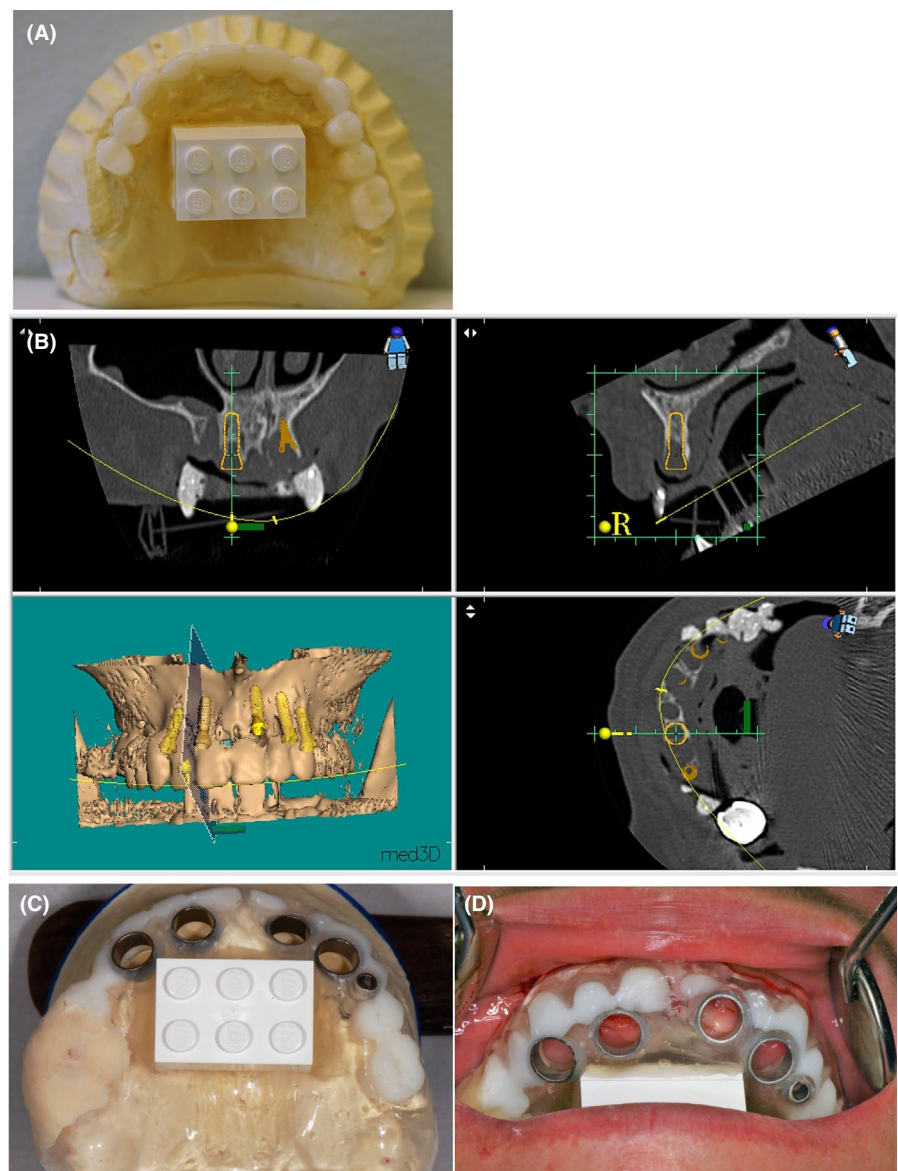
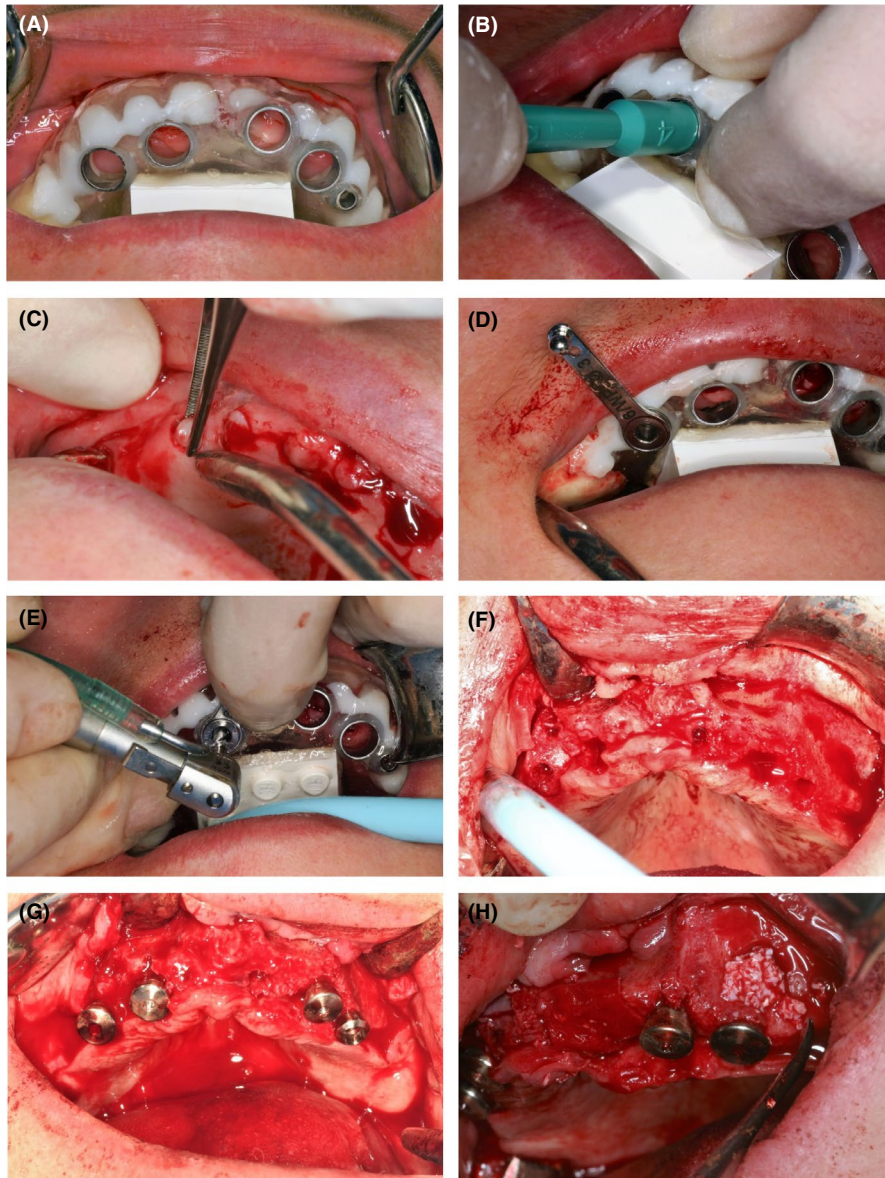


FIGURE 4 Preparation of the surgical guide. A, The radiographic guide duplicated from the immediate denture. B, Virtual positioning of the implants based on med3D analysis software. C, Implant positioning sleeves placed on the guide based on the med3D analysis. D, Surgical guide placed in the patient's mouth

TABLE 1 The list of implants used in the maxilla

Position	Implant type	Manufacturer/Type	Surface treatment	diameter	Walls	Length
11	Soft tissue level collar width: 2.8 mm	Straumann Standard	sandblasted and acid- etched (SLA)		Parallel	10 mm
13				3.3		8 mm
21						10 mm
23						10 mm

**FIGURE 5** Guided surgical placement of the implants. A, Surgical guide firmly placed over the maxillary ridge. B, A punch was used to make a circular incision. C, The incised mucosa was removed using a tweezer. D, A surgical drill guide was placed in the sleeve. E, Guided surgical drilling. F, A full-thickness mucoperiosteal flap reflected. G, Implants placed in their respective sockets. H, Bone grafting in deficient areas

3.4 | Fabrication of the prosthesis

Four months after the implant placement, the implants were well osseointegrated for fabricating the final prosthesis. An implant level impression was made using a regular setting, medium body polyether impression material (Impregum™

Soft Tray 3M™ ESPE™), and an open tray (Figure 6). The interimplant relationship was recorded using a self-cured resin verification jig (PATTERN RESIN™ LS, GC Corporation) and tried in the patient's mouth. After making necessary adjustments in the implant splint, a master impression using medium body polyether impression material (Impregum™

Soft Tray 3M™ ESPE™) was made using a custom open tray. (Figure 6) During the denture try-in, the centric relation was not precise; hence, a new record was made. A dental stone-based verification jig was used to evaluate the passivity. A metal bar was fabricated in the laboratory using a conventional casting technique, and three male locator attachments were soldered to the bar. The metal bar was tried, and the fit was verified using intraoral periapical radiographs (IOPAs). A metal casting, which will eventually be embedded in the acrylic complete denture, was fabricated with three openings corresponding to the bar's locator attachments. The metal casting was tried on the cast and later embedded into the final denture. Three female locator attachments were embedded into the acrylic denture, corresponding to the bar's male attachments (Figure 7). The final denture was inserted in the patient's mouth, and an occlusal prematurities were corrected.

4 | OUTCOME AND FOLLOW-UP

4.1 | Insertion of the final prosthesis

The complete maxillary denture was inserted in the patient's mouth, with the bar's male attachments corresponding to

the female locator attachments in the denture. The occlusal prematurities were corrected, and a balanced occlusion was attained. The patient's tendency to habitually protrude the mandible was less than the immediate denture's initial days. The patient's smile line revealed the teeth till the cervical third and the interdental denture base acrylic. The frontal and profile views of the patient were satisfactory (Figure 8). The patient was delighted with the outcome.

4.2 | The follow-up appointments

The 4-month postsurgery follow-up displayed a complete soft tissue healing clinically and successful osseointegration radiographically (Figure 9). The patient had no complaints during the 1-week postdenture insertion follow-up appointment. However, some minor occlusal discrepancies were corrected for functional reasons. The patient was able to maintain the hygiene well. There was no evidence of dental biofilm accumulation in the dentures, implant bar area, and the lower natural teeth. The patient succeeded in breaking away the habitual protrusion of the mandible by the 1-month follow-up appointment. The temporomandibular joint was no longer tender, and there was no clicking of the joint during mandibular movements. During the 6-month and 9-month

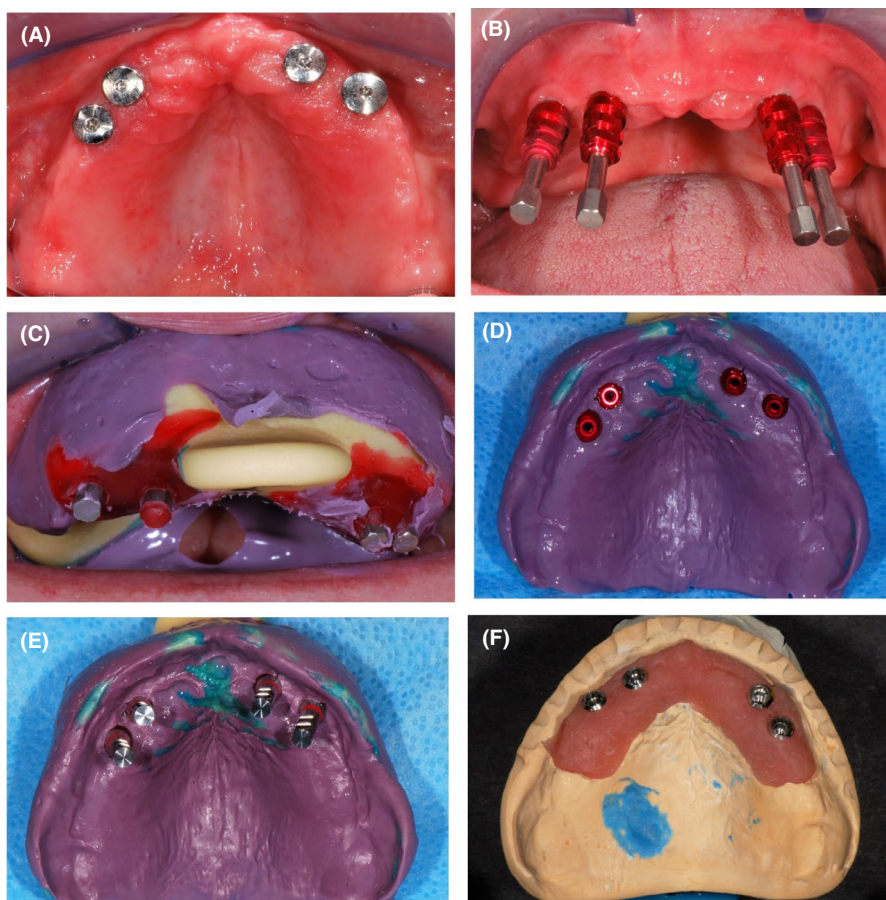


FIGURE 6 Abutment level, open tray impression technique. A, The Osseointegrated implants. B, The impression copings fully seated into the implants. C, Making the impression using an open tray. D, Impression copings secured in the impressions. E, Implant analogs secured in the impression copings. F, Soft tissue master cast

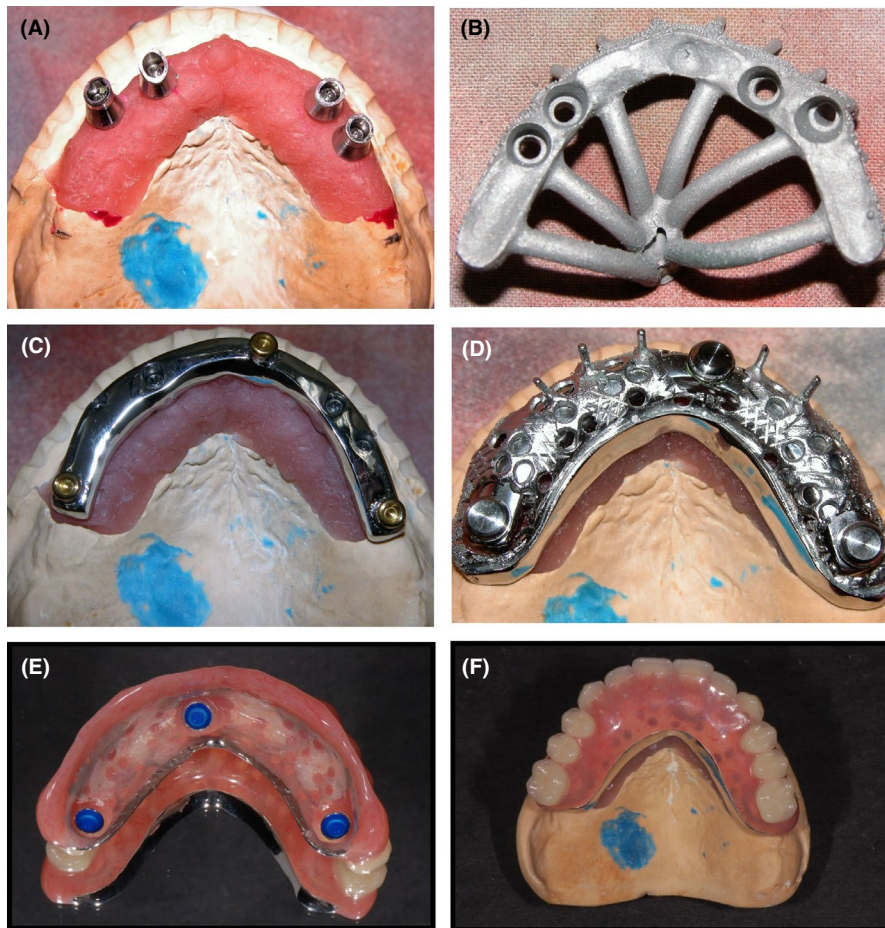


FIGURE 7 Laboratory fabrication of the metal bar and hybrid acrylic dentures with locator attachments. A, Metal abutments secured on the master cast. B, Metal bar cast in a conventional technique. C, The metal bar with three locator attachments. D, Metal insert of the complete denture evaluated on the metal bar. E & F, Finished hybrid acrylic complete dentures

follow-up appointment, the patient reported to have efficient mastication and intended not to have mandibular molar implants. There were no adverse events in the remaining natural teeth, the complete maxillary dentures, the bar attachments, and the implants. Radiographic evaluation revealed the right implants to bone integration (Figure 9).

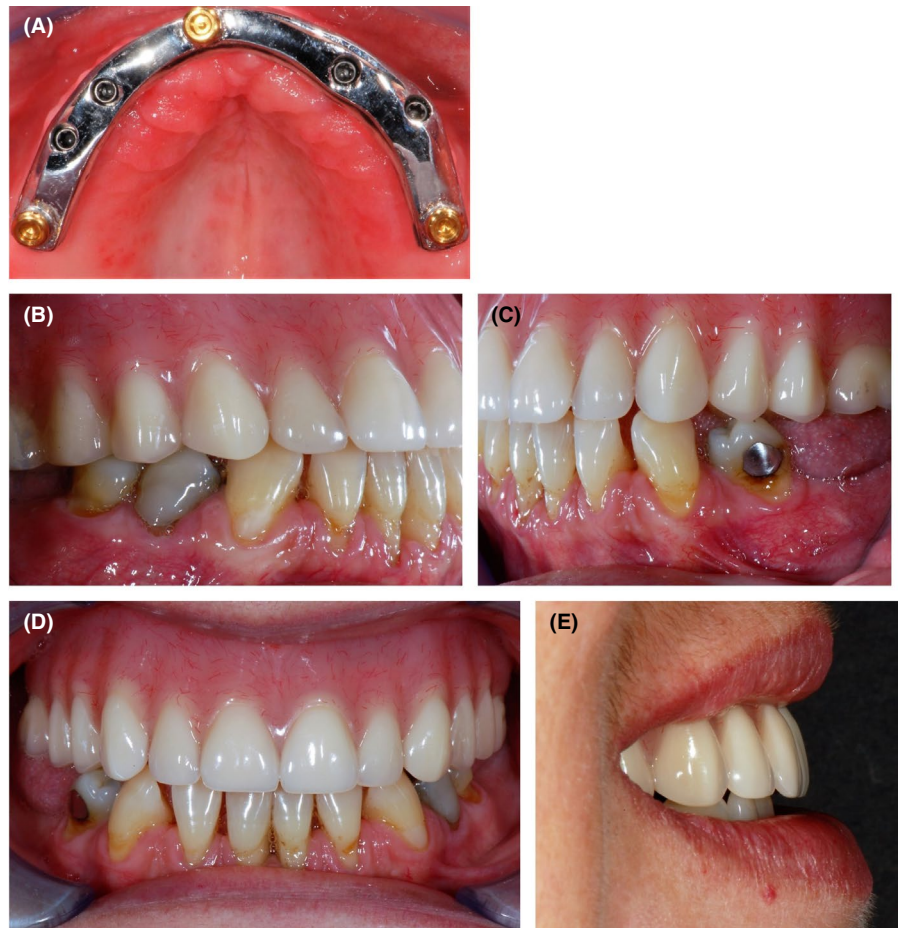
5 | DISCUSSION

The extraction of teeth is regarded as a final course of action in dental treatment planning; every attempt is made to preserve the natural teeth to support a fixed or removable prosthesis.¹⁵ Conversely, some contemporary implantologists consider implant-supported prosthesis equivalent to or sometimes superior to natural teeth regarding longevity.¹⁵ The treating dentist should consider several aspects to decide about saving the tooth or replacing with implants; these aspects include patient comfort, function, longevity, and esthetics.¹⁶ The patient in the current report had maxillary teeth with multiple complicating factors, including an overall CAL of -5.3 mm. (Figures 1, 2 and 3) Replacing the periodontally compromised teeth with implants has long-term reliability in bone preservation and oral hygiene maintenance.¹⁷ Tooth # 12, 21 and 22 had endodontic failures. A previous study

reported that implants replacing teeth with endodontic failures have a success rate comparable to endodontic retreatment.¹⁸ Moreover, in the current case, teeth # 21 and 22 were confronted by large parallel posts and a CAL >6 mm. The tooth #12 had a CAL of 9 mm on the distal side and a grade 2 mobility. All the abutment teeth (# 16, 13, 23 and 26) had necrotic pulp; teeth # 16, 13 and 23 had secondary caries and tooth # 16 and 26 had grade 2 furcation involvement. (Figures 1 and 3) The patient had difficulty maintaining adequate hygiene due to defective restorations and complained of long-standing halitosis.

There is a paucity of long-term randomized clinical trials involving a large sample size to determine a proper treatment protocol for the potentially edentulous maxilla.⁸ However, a maxillary denture without palatal coverage, supported by 4-6 implants, were shown to be successful.^{8,19} A collective 10-year survival rate of 99.3% was reported for 4-6 splinted implant-retained RCD compared to 85.7% for two independent implant-retained RCD.²⁰ In the reported case, only four anterior implants were used to avoid complicated sinus-related surgical procedures. A few earlier reports support the reliability of such an approach.^{21,22} Moreover, the implant survival, marginal bone loss, and prosthodontic complications of 4 anterior implants-bar-supported maxillary RCD were comparable to 6-8 implants extending posteriorly.⁹ Additionally,

FIGURE 8 Final insertion of the prosthesis. A, The metal bar secured on the implants. B, Right lateral view of the denture in occlusion with the lower natural teeth. C, Left lateral view of the denture in occlusion with the lower natural teeth. D, Frontal view of the denture in occlusion with the lower natural teeth. E, Extraoral profile view of the patient in a gentle smile



the bar attachment systems yielded lesser mechanical maintenance issues than independent attachments; however, they are disadvantaged with the possibility of mucosal inflammation below the bar.^{8,21,23,24} A bar-splinted, implant-retained RCD has long-term reliability concerning the preservation of bone.²⁵ Some studies reported the bar's fabrication using CAD/CAM technology.^{19,22,26} A CAD/CAM technology reduces the chance of casting errors, and using a titanium bar reduces the weight; however, the cost is usually on the higher side.²⁶ We used a conventional cast bar due to financial reasons and unavailability.

A misfit of the framework may lead to bacterial accumulation and micro-movements at the defect, leading to biological and mechanical complications. Previously, framed clinical guidelines were followed in this report to prevent such complications.^{27,28} An acrylic verification jig was used to record and evaluate the inter implant relations accurately, a dental stone verification jig to evaluate the passivity, and a radiographic examination to verify the cast bar fit. The most common complication in the first year of an RCD usage was a loss of retention due to wearing off/damaged retentive attachments.²⁷ In the current case, there was no retention loss during the first 9 months; however, the patient was informed, the importance of periodic follow-ups and the possible need to repair/replace the RCD components.

The long-term implant survival rate in the maxillary implant-overdentures is significantly less than that of the mandible.¹¹ Residual ridge resorption in the maxilla considerably affects the labial surface, often leading to a ridge narrower than 7 mm, especially anterior to the maxillary sinus.²⁹ A 2-staged surgical intervention to augment the ridge is generally a complicated process and suffers from a certain degree of morbidity to the patient. Alternatively, narrow dental implants of 3.3 mm can be considered. In the current case, the maxilla had bone width deficiency; hence, 3.3 mm Straumann standard dental implants were chosen. The bony defects were dealt with simultaneously guided bone regeneration during implant insertion. No implants were placed in the molar region due to severe maxillary sinus pneumatization and the patient's unwillingness to undergo a sinus lift procedure. During the 9-month follow-up, the clinical evaluation indicates that the four implants would be adequate to retain and support a removable prosthesis. A previous study reported a 97.5% success rate and 100% survival when four-dental implants with 3.3 mm width were used in the maxilla.³⁰ However, the study used titanium-zirconia implants, while in the current reported case, Straumann standard titanium alloy implants with a soft tissue collar of 2.8 mm were used (Table 1). The soft tissue level implants could have the same successful results and minimal marginal bone loss around the implants.³¹

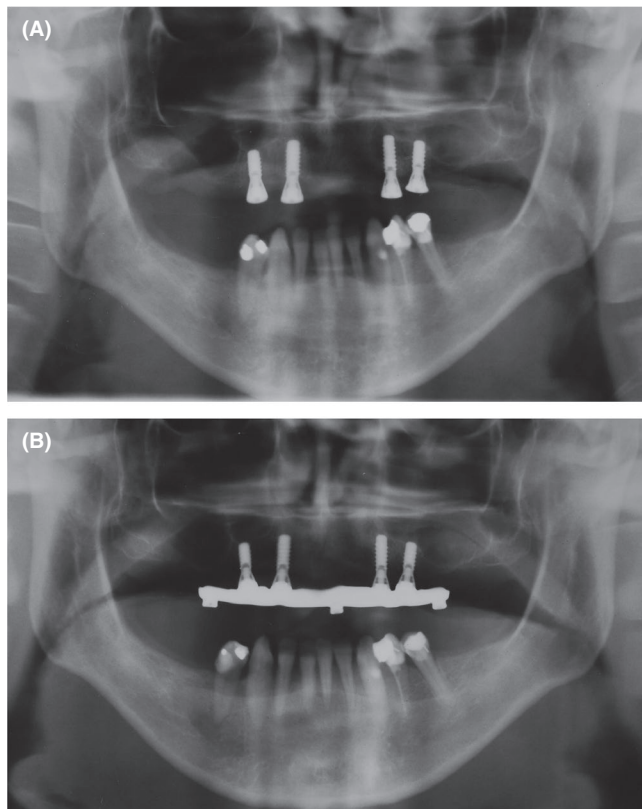


FIGURE 9 Follow-up radiographic evaluation. A, 4-mo postsurgery follow-up orthopantomography displaying good osseointegration. B, 6-mo postdenture insertion follow-up orthopantomography

The oral health-related quality of life and patient satisfaction (OHRQoL) with an implant-retained RCD is superior to that of a conventional complete denture,^{5,6} but inferior to that of an implant-supported FCD.³² The patient's clinical situation, preferences, and anatomical factors impact prosthodontic modality and, eventually, patient satisfaction. In the present case, the patient had a relative maxillary deficiency, which needed an out of the ridge placement of prosthetic teeth for adequate upper lip support. An FCD could pose difficulty in the hygiene measures in such situations.¹⁰ Overcontoured restorations, undercuts at the implant's junction, and the gaps between the FCD and the tissue complicate the cleanability.¹⁰ In the current case, the implant-retained RCD was found to facilitate easy hygiene. Though a bar-retained overdenture is complex, the cleanability is equivalent to that of direct precision attached overdentures.³³

Before the treatment, our Patient suffered from TMD, possibly because of collapsed occlusion, habitual protrusion, and over-closure, leading to constant micro-trauma to the TMJ. The patient's occlusal vertical dimension was low. The habitual protrusion did pose difficulties during jaw relations; it was not easy to manipulate the patient's jaw due to some degree of TMJ dysfunction, chronic pain, and tenderness on

palpation; the occlusion was adjusted several times by selective grinding during the delivery and follow-up appointments. An appropriate occlusal scheme for an RCD is debatable; we provided a balanced occlusion based on the published guidelines.³⁴ Toward the end, a significant recovery of the patient from TMD was recorded, demonstrating the importance of accurate maxillomandibular relations for an optimum TMJ health. However, using adjunctive diagnosis methods, such as RMN, bite plane therapy, and mandibular movement analyzer could have augmented TMJ dysfunction's diagnosis and treatment.

The patient was recommended to have the missing lower posteriors replaced with implant-supported restorations. However, the patient conveyed a satisfactory level of masticatory efficiency with the shortened dental arch (SDA) during the 6- and 9-month follow-ups and differed from having mandibular posterior implants. The patients' financial constraints could have influenced the reported feedback and needs further follow-ups. Moreover, she refused to wear a removable prosthesis in the mandible due to her past dissatisfaction with traditional RPD. The SDA concept has an acceptable long-term OHRQoL.³⁵ A minimum of four occlusal units (OU) is required for adequate patient adaptation for function.³⁶ In the current case, there were only three OU after maxillary rehabilitation as the patient was not willing for the lower posterior teeth replacement. Despite having only three OU, the patient reported a significant improvement in the TMJ dysfunction symptoms and masticatory efficiency. A previous study suggested that 3-5 OU does not pose a significant risk of TMD.³⁷ Furthermore, female patients display a lower correlation between the OU and the TMD.³⁸ The correction in the occlusal vertical dimension could have influenced the improvement in the current case. However, a long-term follow-up in the current case is needed to ascertain the results.

The current reported case portrayed the restoration of a potentially edentulous maxilla with four tissue level narrow implants (3.3 mm), conventionally cast metal bar with three locator attachments, and a hybrid acrylic RCD. The 9-month follow-up assessments and the patient feedback indicated the protocol to be reliable, esthetic, and hygienic. A few studies support the protocol; however, long-term clinical trials with a large sample size are required to establish credibility further.

6 | LEARNING POINTS/TAKE-HOME MESSAGES

Within the limited, 9-month follow-up of the current case, the following take-home messages can be drawn.

1. Four narrow dental implants and conventionally cast bar-retained removable hybrid acrylic complete denture

- may be adequately efficient and satisfactory to the terminal dentition patient.
- The temporomandibular joint dysfunction can be significantly reduced with appropriate rectification of errors in maxilla mandibular relation.
 - A shortened dental arch, having three occlusal units, may not pose a risk for TMD; it could be adequately efficient and satisfactory to the patient.

However, this patient's long-term follow-up and new clinical trials are necessary to ascertain the protocol's reliability. In the current case, we have learned that determining the maxilla mandibular records in a patient with habitual protrusion is difficult; the clinician may need to perform occlusal corrections several times during treatment and maintenance.

ACKNOWLEDGMENTS

We thank King Khalid University College of Dentistry for facilitating the patient treatment. Published with written consent of the patient.

CONFLICT OF INTEREST

The authors have no conflict of interest relevant to the contents of the submission. Published with written consent of the patient.

AUTHOR CONTRIBUTIONS

The authors listed in the study substantially contributed to the treatment plan, treatment, and follow-up, drafting/revising the submitted manuscript's paper and approval.

ETHICAL APPROVAL

The reporting was approved by the King Khalid University College of dentistry scientific research committee (approval no: SRC/ETH/2018-19/145).

PATIENT'S PERSPECTIVE

I was exceedingly happy with the overall outcome of the treatment. I initially had some difficulty in removing the denture out, but I learned it soon. There are no pain and clicking sounds in my ears after the treat chewing efficiency improved with time, and I do not need more implants, as initially recommended by the dentists. Maintaining oral hygiene with this denture is easy, and I think the dentures will serve me for a long time.

DATA AVAILABILITY STATEMENT

Data sharing does not apply to this article as no new data were created or analyzed in this study.

ORCID

Sharaz Shaik  <https://orcid.org/0000-0002-1017-6419>

REFERENCES

- Slade GD, Akinkugbe AA, Sanders AE. Projections of U.S. Edentulism prevalence following 5 decades of decline. *J Dent Res.* 2014;93(10):959-965.
- Parker ML, Thornton-Evans G, Wei L, et al. Prevalence of and changes in tooth loss among adults aged ≥ 50 years with selected chronic conditions - United States, 1999-2004 and 2011-2016. *MMWR Morb Mortal Wkly Rep.* 2020;69(21):641-646.
- Peltzer K, Hewlett S, Yawson AE, et al. Prevalence of loss of all teeth (edentulism) and associated factors in older adults in China, Ghana, India, Mexico, Russia and South Africa. *Int J Environ Res Public Health.* 2014;11(11):11308-11324.
- Hiltunen K, Vehkalahti M, Ainamo A. Occlusal imbalance and temporomandibular disorders in the elderly. *Acta Odontol Scand.* 1997;55(3):137-141.
- Assuncao WG, Barao VA, Delben JA, et al. A comparison of patient satisfaction between treatment with conventional complete dentures and overdentures in the elderly: a literature review. *Gerodontology.* 2010;27(2):154-162.
- Sanchez-Siles M, Ballester-Ferrandis JF, Salazar-Sanchez N, et al. Long-term evaluation of quality of life and satisfaction between implant bar overdentures and conventional complete dentures: a 23 years retrospective study. *Clin Implant Dent Relat Res.* 2018;20(2):208-214.
- Zitzmann NU, Marinello CP. Treatment outcomes of fixed or removable implant-supported prostheses in the edentulous maxilla. Part II: clinical findings. *J Prosthet Dent.* 2000;83(4):434-442.
- Sadowsky SJ, Zitzmann NU. Protocols for the maxillary implant overdenture: a systematic review. *Int J Oral Maxillofac Implants.* 2016;31(Suppl):s182-s191.
- Krennmair G, Krainhofner M, Piehslinger E. Implant-supported maxillary overdentures retained with milled bars: maxillary anterior versus maxillary posterior concept—a retrospective study. *Int J Oral Maxillofac Implants.* 2008;23(2):343-352.
- Alfarsi MA, Shaik S. Implant-supported fixed hybrid acrylic complete dentures opposing fully restored mandibular metal ceramic restorations. *BMJ Case Rep.* 2020;13(2):e233913.
- Schwartz-Arad D, Kidron N, Dolev E. A long-term study of implants supporting overdentures as a model for implant success. *J Periodontol.* 2005;76(9):1431-1435.
- Kim JY, Jung HD, Jung YS, et al. A simple classification of facial asymmetry by TML system. *J Craniomaxillofac Surg.* 2014;42(4):313-320.
- ASo A. ASA physical status classification system. ASA House of Delegates. 2014.
- Abboud M, Orentlicher G. An open system approach for surgical guide production. *J Oral Maxillofac Surg.* 2011;69(12):e519-e524.
- Moshaverinia A, Kar K, Chee WW. Treatment planning decisions: implant placement versus preserving natural teeth. *J Calif Dent Assoc.* 2014;42(12):859-868.
- Torabinejad M, Goodacre CJ. Endodontic or dental implant therapy: the factors affecting treatment planning. *J Am Dent Assoc.* 2006;137(7):973-977; quiz 1027-8.
- Babbush CA, Tallarico M. Twelve-year clinical and radiological results of maxillary and mandibular implant-retained bar overdentures carried out on oxidized (TiUnite) replace select implants: a clinical case. *J Oral Implantol.* 2013;39(6):737-742.
- Esposito M, Trullenque-Eriksson A, Tallarico M. Endodontic retreatment versus dental implants of teeth with an uncertain

- endodontic prognosis: 3-year results from a randomised controlled trial. *Eur J Oral Implantol*. 2018;11(4):423-438.
19. Tallarico M, Cervino G, Scrascia R, et al. Minimally invasive treatment of edentulous maxillae with overdenture fully supported by a Cad/Cam titanium bar with a low-profile attachment screwed on four or six implants: a case series. *Prosthesis*. 2020;2(2):53-64.
 20. Sanna A, Nuytens P, Naert I, et al. Successful outcome of splinted implants supporting a 'planned' maxillary overdenture: a retrospective evaluation and comparison with fixed full dental prostheses. *Clin Oral Implants Res*. 2009;20(4):406-413.
 21. Tallarico M, Ortensi L, Martinolli M, et al. Multicenter retrospective analysis of implant overdentures delivered with different design and attachment systems: results between one and 17 years of follow-up. *Dent J (Basel)*. 2018;6(4):71.
 22. Pozzi A, Tallarico M, Moy PK. Four-implant overdenture fully supported by a CAD-CAM titanium bar: a single-cohort prospective 1-year preliminary study. *J Prosthet Dent*. 2016;116(4):516-523.
 23. Stoumpis C, Kohal RJ. To splint or not to splint oral implants in the implant-supported overdenture therapy? A systematic literature review. *J Oral Rehabil*. 2011;38(11):857-869.
 24. Zou D, Wu Y, Huang W, et al. A 5- to 8-year retrospective study comparing the clinical results of implant-supported telescopic crown versus bar overdentures in patients with edentulous maxillae. *Int J Oral Maxillofac Implants*. 2013;28(5):1322-1330.
 25. French D, Tallarico M. Eight-year clinical and radiologic results of maxillary and mandibular implant-retained bar overdentures carried out on oxidized (TiUnite) replace select implants placed in regenerated bone: a clinical case. *Quintessence Int*. 2014;45(2):135-140.
 26. Goo CL, Tan KB. Fabricating CAD/CAM implant-retained mandibular bar overdentures: a clinical and technical overview. *Case Rep Dent*. 2017;2017:9373818.
 27. Calderon PS, Dantas PM, Montenegro SC, et al. Technical complications with implant-supported dental prostheses. *J Oral Sci*. 2014;56(2):179-184.
 28. Kan JY, Rungcharassaeng K, Bohsali K, et al. Clinical methods for evaluating implant framework fit. *J Prosthet Dent*. 1999;81(1):7-13.
 29. Cawood JJ, Howell RA. A classification of the edentulous jaws. *Int J Oral Maxillofac Surg*. 1988;17(4):232-236.
 30. Cordaro L, Torsello F, Mirisola di Torresanto V, et al. Rehabilitation of an edentulous atrophic maxilla with four unsplinted narrow diameter titanium-zirconium implants supporting an overdenture. *Quintessence Int*. 2013;44(1):37-43.
 31. Fischer K, Stenberg T. Prospective 10-year cohort study based on a randomized controlled trial (RCT) on implant-supported full-arch maxillary prostheses. Part 1: sandblasted and acid-etched implants and mucosal tissue. *Clin Implant Dent Relat Res*. 2012;14(6):808-815.
 32. Brennan M, Houston F, O'Sullivan M, et al. Patient satisfaction and oral health-related quality of life outcomes of implant overdentures and fixed complete dentures. *Int J Oral Maxillofac Implants*. 2010;25(4):791-800.
 33. Ambard AJ, Fanchiang JC, Mueninghoff L, et al. Cleansability of and patients' satisfaction with implant-retained overdentures: a retrospective comparison of two attachment methods. *J Am Dent Assoc*. 2002;133(9):1237-1242; quiz 61.
 34. Nikolopoulou F, Ktena-Agapitou P. Rationale for choices of occlusal schemes for complete dentures supported by implants. *J Oral Implantol*. 2006;32(4):200-203.
 35. Reissmann DR, Wolfart S, John MT, et al. Impact of shortened dental arch on oral health-related quality of life over a period of 10 years - A randomized controlled trial. *J Dent*. 2019;80:55-62.
 36. Kayser AF. Shortened dental arches and oral function. *J Oral Rehabil*. 1981;8(5):457-462.
 37. Witter DJ, De Haan AF, Kayser AF, et al. A 6-year follow-up study of oral function in shortened dental arches. Part II: Craniomandibular dysfunction and oral comfort. *J Oral Rehabil*. 1994;21(4):353-366.
 38. Mundt T, Mack F, Schwahn C, et al. Gender differences in associations between occlusal support and signs of temporomandibular disorders: results of the population-based Study of Health in Pomerania (SHIP). *Int J Prosthodont*. 2005;18(3):232-239.

How to cite this article: Alfarsi MA, Shaik S. Four narrow dental implants and conventionally cast bar-supported removable hybrid acrylic complete denture as a therapeutic modality for terminal dentition. *Clin Case Rep*. 2021;9:326–336. <https://doi.org/10.1002/ccr3.3525>