

## Membranous lipodystrophy: case report and review of the literature\*

Fatma Akpınar<sup>1</sup>  
Duygu Dusmez Apa<sup>1</sup>

Ektan Demir<sup>1</sup>

DOI: <http://dx.doi.org/10.1590/abd1806-4841.20153677>

**Abstract:** Membranous lipodystrophy is a distinct type of membranocystic fat necrosis. It is associated with many local and systemic diseases, including vascular disorders. The histopathological changes which characterize this phenomenon are variably sized cysts in the fat lobules of the subcutaneous tissue, which are surrounded by eosinophilic membranes projecting into the cystic space. We report a case of secondary membranous lipodystrophy associated with both hypertension and venous insufficiency.

**Keywords:** Cysts; Fat necrosis; Ischemia; Lipodystrophy; Venous insufficiency

### INTRODUCTION

Membranous lipodystrophy is membranocystic fat necrosis. Initially, it was described as polycystic lipomembranous osteodysplasia.<sup>1</sup> Various clinical conditions, such as lupus erythematosus, diabetes mellitus, erythema nodosum, morphea, as well as trauma and vascular disorders have been found to exhibit similar membranous lipodystrophies and lipodystrophy-like changes.<sup>2-5</sup> We report a case of secondary membranous lipodystrophy associated with hypertension and venous insufficiency.

### CASE REPORT

A 60-year-old man presented with dyspnea and painful plaques on the lower extremities, which progressed slowly within two months. He was using antihypertensive drugs and had never consulted a physician for his varicose leg veins. The patient was a smoker and a habitual drinker. He had no history of connective tissue disease, Behçet's disease, infection or trauma.

On physical examination, expiration was prolonged. Blood pressure was 180/100 mmHg. There were multiple, 2x4 cm erythematous indurated plaques on his distal lower legs. Multiple varices located bilaterally on the posterior aspect of his knee, around his ankle and on the medial side of his feet were identified (Figure 1). Laboratory findings were in normal ranges. The patient was diagnosed with chronic obstructive pulmonary disease by the specialist in chest diseases. Superficial venous insufficiency at the sapheno-femoral junction was observed by colored Doppler ultrasonography.

Histopathology of the punch biopsy revealed slight infiltration of mononuclear cells and fibrosis in the dermis, septa and fat lobules. The walls of the vessels were thickened and infiltrated by lymphohistiocytes. There were multiple cysts of irregular shape and variable size in the adipose tissue: the cysts were lined by an amorphous eosinophilic material (Figure 2A). Eosinophilic membranes were observed projecting

Received on 05.05.2014

Approved by the Advisory Board and accepted for publication on 15.06.2014

\* Study conducted at the Faculty of Medicine, Maltepe University - Istanbul, Turkey

Financial Support: None.

Conflict of Interest: None.

<sup>1</sup> Maltepe University - Istanbul, Turkey.

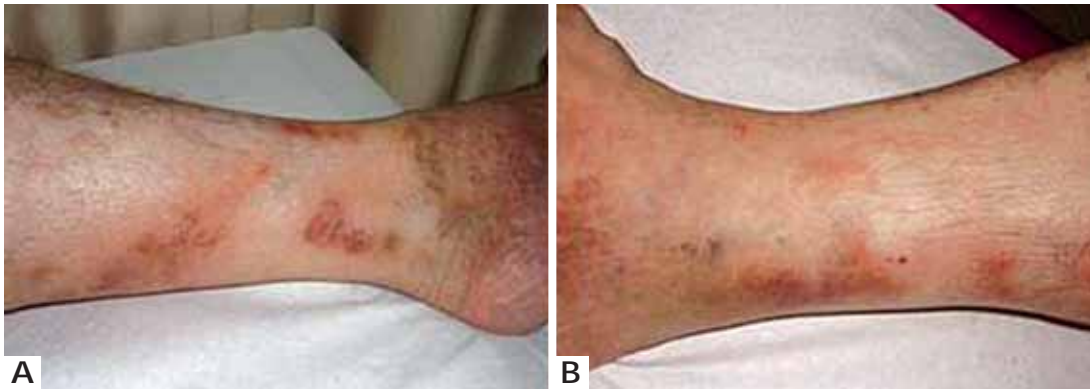into the cystic spaces (Figures 2B and 2C). The patient was diagnosed with membranous lipodystrophy due to vascular ischemia.

## DISCUSSION

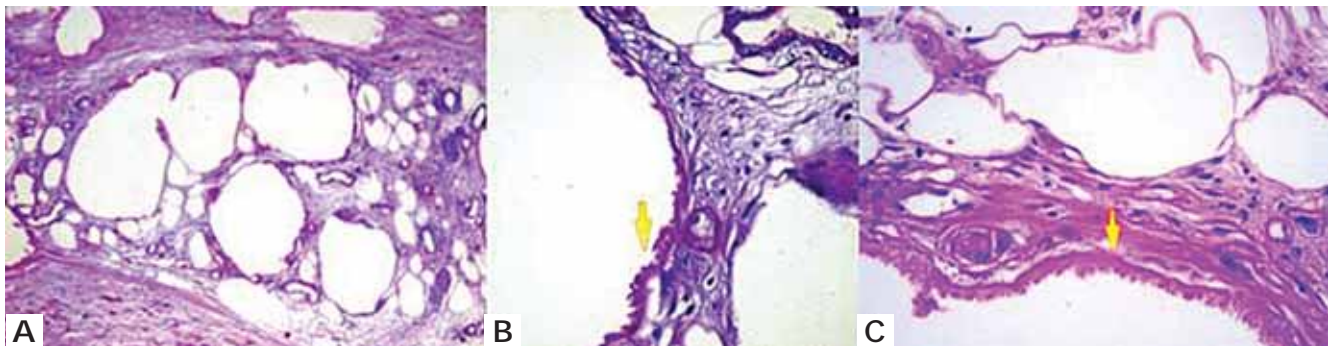
Membranous lipodystrophy was described by Nasu et al in 1973 as a genetic entity with membranocystic lesions of fat occurring in the long bones and associated with sudanophilic leukoencephalopathy.<sup>1</sup> Later, membranocystic changes were noted in morphea profunda, lupus panniculitis and factitial ulcer, and the term "secondary membranous lipodystrophy" was proposed.<sup>2</sup> Similar changes were also detected in diabetes mellitus, multiple myeloma, atypical mycobacterial infection, erythema nodosum, and vascular disorders, including arterial ischemia of lower limbs, varicose veins, thrombophlebitis and deep venous thrombosis.<sup>3-5</sup>

The pathogenesis of membranous lipodystrophy is unknown. Idiopathic processes, enormous proliferation of the fat cell membranes, physiochemical interaction between the ground substance in connective tissue and fat droplets, free fatty acids released

from degenerated fat cells processed by macrophages, metabolic disorders of lipids in mesenchymal cells, loops and fold in the basal laminae of fat cells in varying stages of lipid depletion at the time of necrosis; and ischemic injury of adipose tissue resulting from venous insufficiency are various mechanisms that have been proposed.<sup>3</sup> Our case had hypertension and superficial venous insufficiency, which were thought to be the underlying causes. Several clinical presentations comprising tender or nontender nodules, ulcerated or atrophic plaques, depressed lesions, diffuse swelling, and ecchymotic lesions may occur.<sup>6</sup> Our patient had tender, indurated plaques suggesting panniculitis, probably erythema nodosum or thrombophlebitis. The condition can only be diagnosed histopathologically by the presence of multiple, variably sized cysts in the panniculus, lined by an amorphous, homogeneous, eosinophilic membrane. This membrane may be flat and, in some cysts, be replaced by granulomatous inflammation.<sup>3</sup> It often projects into cysts, creating a pseudopapilla or arabesque appearance.<sup>5</sup> Our histopathological examination revealed similar findings, as well as dermal vascular hyperpla-



**FIGURE 1:**  
A. Erythematous indurated plaques and multiple varices;  
B. Similar clinical findings on the right leg



**FIGURE 2:** A. Multiple cysts of variable shape and size, including amorphous eosinophilic material on their walls (Periodic acid-Schiff x100); B. Eosinophilic membranes surrounding fat lobules and projecting (yellow arrow) into the cystic space (Periodic Acid-Schiff x100); C. Projections (yellow arrow) at higher magnification (haematoxylin and eosin x100)

sia and perivascular inflammatory cellular infiltration. High blood pressure and venous insufficiency led us to think that ischemia - the most important cause of membranous lipodystrophy - was the underlying etiology. Hypertension increases the medial thickness and narrows the vascular lumen, resulting in impaired capillary perfusion.<sup>4</sup> Machinami reported membranous lipodystrophy-like changes in the extremities of patients with chronic arterial obstruction.<sup>7</sup> Alegre *et al* reported that, histopathologically, more than half of the patients with lipomembranous changes in the panniculus in their study had ischemic injury to the adipose tissue.<sup>8</sup> Snow *et al* concluded that lipomem-

branous fat necrosis was more often seen in venous insufficiency-associated chronic sclerotic plaques.<sup>9</sup> Ten of 15 lipodermatosclerosis cases reviewed by Diaz-Cascajo *et al* showed pseudocystic cavities lined by crenulated membranes.<sup>10</sup>

Membranous lipodystrophy is a histological change induced by various clinical entities associated with fat necrosis in panniculitis. It is not a sui generis disease. Our case supports the roles of vascular insufficiency and ischemic injury of adipose tissue in the genesis of the lipomembranous alteration. □

## REFERENCES

1. Nasu T, Tsukahara Y, Terayama K. A lipid metabolic disease-"membranous lipodystrophy"-an autopsy case demonstrating numerous peculiar membrane-structures composed of compound lipid in bone and bone marrow and various adipose tissues. *Acta Pathol Jpn.* 1973;23:539-58.
2. Chun SI, Chung KY. Membranous lipodystrophy: secondary type. *J Am Acad Dermatol.* 1994;31:601-5.
3. Ahn S, Yoo M, Lee S, Choi E. A clinical and histopathological study of 22 patients with membranous lipodystrophy. *Clin Exp Dermatol.* 1996;21:269-72.
4. Bak H, Lee JW, Ahn HJ, Hwang SM, Choi EH, Lee SH, et al. An unusual case with membranous lipodystrophy in a hypertensive patient with transepidermal elimination. *Yonsei Med J.* 2006;47:428-31.
5. Lee Y, Ahn SY, Ji JH, Hong SP, Bak H, Lee SH, et al. A case of membranous lipodystrophy observed in lichen amyloidosis. *Ann Dermatol.* 2009;21:174-7.
6. Lee JW, Bak H, Park IH, Choi EH, Ahn SK. Membranous lipodystrophy-like changes in two cases of traumatic lipogranuloma caused by safety belts. *J Dermatol.* 2005;32:38-42.
7. Machinami R. Incidence of membranous lipodystrophylike change among patients with limb necrosis caused by chronic arterial obstruction. *Arch Pathol Lab Med.* 1984;108:823-6.
8. Alegre VA, Winkelmann RK, Aliaga A. Lipomembranous changes in chronic panniculitis. *J Am Acad Dermatol.* 1988;19:39-46.
9. Snow JL, Su WP. Lipomembranous (membranocystic) fat necrosis. Clinicopathologic correlation of 38 cases. *Am J Dermatopathol.* 1996;18:151-5.
10. Diaz-Cascajo C, Borghi S. Subcutaneous pseudomembranous fat necrosis: new observations. *J Cutan Pathol.* 2002;29:5-10.

## MAILING ADDRESS:

Fatma Akpınar  
Maltepe Üniversitesi Tıp Fakültesi Deri ve Zührevi  
Hastalıklar Anabilim Dalı  
Atatürk Caddesi Çam Sokak No: 3  
Maltepe  
Istanbul, Turkey.  
E-mail: fatma.akpinar@maltepe.edu.tr

**How to cite this article:** Akpınar F, Demir E, Apa DD. Membranous lipodystrophy: Case report and review of the literature. *An Bras Dermatol.* 2015;90 (3 Suppl 1):S115-7