



CONSENSUS STATEMENT

## International consensus on natural orifice specimen extraction surgery (NOSES) for colorectal cancer

Xu Guan<sup>1,†</sup>, Zheng Liu<sup>1,†</sup>, Antonio Longo<sup>2</sup>, Jian-Chun Cai<sup>3</sup>, William Tzu-Liang Chen<sup>4</sup>, Lu-Chuan Chen<sup>5</sup>, Ho-Kyung Chun<sup>6</sup>, Joaquim Manuel da Costa Pereira<sup>7</sup>, Sergey Efetov<sup>8</sup>, Ricardo Escalante<sup>9</sup>, Qing-Si He<sup>10</sup>, Jun-Hong Hu<sup>11</sup>, Cuneyt Kayaalp<sup>12</sup>, Seon-Hahn Kim<sup>13</sup>, Jim S. Khan<sup>14</sup>, Li-Jen Kuo<sup>15</sup>, Atsushi Nishimura<sup>16</sup>, Fernanda Nogueira<sup>7</sup>, Junji Okuda<sup>17</sup>, Avanish Saklani<sup>18</sup>, Ali A. Shafik<sup>19</sup>, Ming-Yin Shen<sup>4</sup>, Jung-Tack Son<sup>6</sup>, Jun-Min Song<sup>20</sup>, Dong-Hui Sun<sup>21</sup>, Keisuke Uehara<sup>22</sup>, Gui-Yu Wang<sup>23</sup>, Ye Wei<sup>24</sup>, Zhi-Guo Xiong<sup>25</sup>, Hong-Liang Yao<sup>26</sup>, Gang Yu<sup>27</sup>, Shao-Jun Yu<sup>28</sup>, Hai-Tao Zhou<sup>1</sup>, Suk-Hwan Lee<sup>29</sup>, Petr V. Tsarkov<sup>30</sup>, Chuan-Gang Fu<sup>31</sup> and Xi-Shan Wang<sup>1,\*</sup>, The International Alliance of NOSES

<sup>1</sup>Department of Colorectal Surgery, National Cancer Center/National Clinical Research Center for Cancer/Cancer Hospital, Chinese Academy of Medical Sciences and Peking Union Medical College, Beijing, China, <sup>2</sup>Department of Coloproctology and Pelvic Diseases, Humanitas Gavazzeni, Bergamo, Italy, <sup>3</sup>Department of Gastrointestinal Surgery, Zhongshan Hospital of Xiamen University, Xiamen, China, <sup>4</sup>Department of Surgery, China Medical University Hospital, Taichung, Taiwan, China, <sup>5</sup>Department of Abdominal Surgery, Fujian Medical University Cancer Hospital, Fuzhou, China, <sup>6</sup>Department of Surgery, Kangbuk Samsung Hospital, Sungkyunkwan University School of Medicine, Seoul, South Korea, <sup>7</sup>Department of Surgery, Hospital de Braga, Braga, Portugal, <sup>8</sup>Colorectal Surgery Department, Sechenov First Moscow State Medical University, Moscow, Russia, <sup>9</sup>Universidad Central de Venezuela, Centro Medico Loira, Caracas, Venezuela, <sup>10</sup>Department of General Surgery, Shandong University Qilu Hospital, Jinan, China, <sup>11</sup>Department of General Surgery, Huaihe Hospital of Henan University, Kaifeng, China, <sup>12</sup>Department of Gastrointestinal Surgery, Inonu University, Malatya, Turkey, <sup>13</sup>Department of Surgery, Korea University Anam Hospital, Korea University College of Medicine, Seoul, South Korea, <sup>14</sup>Department of Colorectal Surgery, Portsmouth Hospitals NHS Trust, Queen Alexandra Hospital, Portsmouth, UK, <sup>15</sup>Division of Colorectal Surgery, Taipei Medical University Hospital, Taipei, Taiwan, China, <sup>16</sup>Department of Surgery, Nagaka Chuo General Hospital, Nagaoka City, Japan, <sup>17</sup>Innovation Unit / Colorectal Cancer, Osaka Medical College Hospital Cancer Center, Osaka, Japan, <sup>18</sup>Department of GI Surgical Oncology, Tata Memorial Hospital, Mumbai, India, <sup>19</sup>Department of Colorectal Surgery, Cairo University, Cairo, Egypt, <sup>20</sup>Department of Anorectal Surgery, First Affiliated Hospital, Zhengzhou University, Zhengzhou, China, <sup>21</sup>Department of Gastric and Colorectal Surgery, Jilin University

Submitted: 11 November 2018; Accepted: 26 December 2018

© The Author(s) 2019. Published by Oxford University Press and Sixth Affiliated Hospital of Sun Yat-Sen University

This is an Open Access article distributed under the terms of the Creative Commons Attribution Non-Commercial License (<http://creativecommons.org/licenses/by-nc/4.0/>), which permits non-commercial re-use, distribution, and reproduction in any medium, provided the original work is properly cited. For commercial re-use, please contact [journals.permissions@oup.com](mailto:journals.permissions@oup.com)

First Hospital, Changchun, China, <sup>22</sup>Division of Surgical Oncology, Nagoya University Graduate School of Medicine, Nagoya, Japan, <sup>23</sup>Department of Colorectal Cancer Surgery, The Second Affiliated Hospital of Harbin Medical University, Harbin, China, <sup>24</sup>Department of General Surgery, Zhongshan Hospital, Fudan University, Shanghai, China, <sup>25</sup>Department of Gastrointestinal Surgery, Hubei Provincial Cancer Hospital, Wuhan, China, <sup>26</sup>Department of General Surgery, The Second Xiangya Hospital, Central South University, Changsha, China, <sup>27</sup>Department of Surgery, People's Hospital of Linzi District, Affiliated to Binzhou Medical College, Zibo, China, <sup>28</sup>Department of Surgical Oncology, The Second Affiliated Hospital, Zhejiang University School of Medicine, Hangzhou, China, <sup>29</sup>Department of Surgery, Kyung Hee University Hospital at Gangdong, Kyung Hee University School of Medicine, Seoul, South Korea, <sup>30</sup>Clinic of Colorectal and Minimally Invasive Surgery, Sechenov First Moscow State Medical University, Moscow, Russia and <sup>31</sup>Department of Gastrointestinal Surgery, Shanghai East Hospital, Tongji University School of Medicine, Shanghai, China

\*Corresponding author. Department of Colorectal Surgery, National Cancer Center/National Clinical Research Center for Cancer/Cancer Hospital, Chinese Academy of Medical Sciences and Peking Union Medical College, Beijing, 100021, China. Tel: +86-13552367779; Email: wxshan1208@126.com

<sup>†</sup>Xu Guan and Zheng Liu contributed equally to this work.

## Abstract

In recent years, natural orifice specimen extraction surgery (NOSES) in the treatment of colorectal cancer has attracted widespread attention. The potential benefits of NOSES including reduction in postoperative pain and wound complications, less use of postoperative analgesic, faster recovery of bowel function, shorter length of hospital stay, better cosmetic and psychological effect have been described in colorectal surgery. Despite significant decrease in surgical trauma of NOSES have been observed, the potential pitfalls of this technique have been demonstrated. Particularly, several issues including bacteriological concerns, oncological outcomes and patient selection are raised with this new technique. Therefore, it is urgent and necessary to reach a consensus as an industry guideline to standardize the implementation of NOSES in colorectal surgery. After three rounds of discussion by all members of the International Alliance of NOSES, the consensus is finally completed, which is also of great significance to the long-term progress of NOSES worldwide.

**Key words:** colorectal cancer; natural orifice specimen extraction surgery (NOSES); laparoscopy; natural orifice transluminal endoscopic surgery (NOTES); transanal total mesorectal excision (TaTME)

## Introduction

Great advances in minimally invasive surgery over the last decade have led to development of various techniques extending the benefits of minimal access surgery to patients with colorectal cancer [1–3]. However, current laparoscopic approach requires an extra incision at the abdominal wall for specimen extraction, which associated with postoperative pain, increased wound complications including infection, hernia formation and scarring [4, 5]. Natural orifice specimen extraction surgery (NOSES) is featured with the removal of surgical specimen from natural orifice in the avoidance of abdominal incision, which has been considered as an alternative approach to open surgery and conventional laparoscopic surgery in selected patients [6, 7]. Although the safety and feasibility of NOSES in colorectal surgery have been well proved, there are still many unresolved issues that need to be unified and standardized [8–10]. The International Alliance of NOSES is an international academic organization which aims to improve the profession level and clinical application for NOSES. To achieve a unified consensus of NOSES, all members of this international group participated in drafting this consensus to provide a full introduction of the theoretical and technical aspects of NOSES for colorectal cancer and provide a reliable basis for the development of NOSES involved in this field of colorectal surgery. The following will introduce the details of this consensus from several aspects.

## Definition

In recent years, based on the introduction of natural orifice transluminal endoscopic surgery (NOTES), a series of concepts related to NOTES have been gradually proposed by combining different instruments and different operative methods, for example, pre-NOTES, hybrid-NOTES, like-NOTES and so on [11, 12]. Although the terminology is different, all techniques are aimed at achieving a common goal, namely the pursuit of minimally invasive effects, avoidance of abdominal wall incisions and reduction of abdominal dysfunction. However, this complex nomenclature may cause confusion in literature retrieval and academic exchanges. Combining internationally accepted presentation methods and language habits, it is recommended that the technique is named 'Natural Orifice Specimen Extraction Surgery', the abbreviation is 'NOSES'. The definition of NOSES is as follow: the surgical specimen resection is performed intraabdominally, then the specimen is extracted by opening a hollow organ that communicates with the outside of body, including anus, vagina or mouth. The main features of NOSES for colorectal surgery involve specimen extraction from a natural orifice and complete intra-abdominal digestive tract reconstruction, which avoid the additional incision on the abdominal wall. In addition to colorectal surgery, it can also be applied to the fields of gastrointestinal, hepatobiliary, urinary, gynecological surgery, etc. Because NOTES is also taking specimen through natural orifice, it therefore should be one part of NOSES. Furthermore, recently developed transanal total

mesorectal excision (TaTME) is also a type of NOTES, so it also belongs to NOSES [13].

## Classification

According to the routes for specimen extraction in colorectal surgery, NOSES is divided into two categories including transanal- and transvaginal-NOSES [14, 15]. A large amount of research literatures and clinical practice have fully confirmed that the anus is the most ideal orifice to extract colorectal specimen which is more in line with the basic requirements of minimally invasive surgery [16]. The vagina has also been considered another ideal option to remove more bulky colorectal specimen when compared with anus, which presented several properties involving good elasticity, adequate blood supply, healing ability and easy access [17, 18]. However, transvaginal specimen extraction presents the following limitations: firstly, this technique is only confined to female patients; secondly, opening the vaginal wall may increase the risk of postoperative complications and sexual dysfunction; thirdly, transvaginal-NOSES is also limited by ethics. The orifice selection for specimen extraction is mainly based on the size of the specimen, especially the maximum circumferential diameter (CDmax). The transanal-NOSES is mainly applicable to patients with small tumors, and the transvaginal-NOSES is available for female patients with a bulky specimen that cannot be removed through the anus. Furthermore, gynecologic tumor resection can also be completed simultaneously by transvaginal specimen extraction [19].

According to the procedures of specimen extraction, NOSES can be classified into three categories. 1) Transanal specimen eversion and extra-abdominal resection technique, this technique is mainly used to lower rectal resection, the main surgical procedure is shown in [Figure 1](#) and [supplementary Video 1](#). 2) Transluminal specimen extraction and extra-abdominal resection technique, this technique is mainly used for middle rectal resection, the main surgical procedure is shown in [Figure 2](#) and [supplementary Video 2](#). 3) Intra-abdominal specimen resection and transluminal extraction technique, this technique is mainly used for upper rectal resection and colectomy, the main surgical procedure is shown in [Figure 3](#) and [supplementary Video 3](#). To further refine the classification, ten different NOSES approaches, from NOSES I to NOSES X, were proposed for the treatment of colorectal neoplasms. Five approaches were used for rectal resection, five approaches were used for colectomy ([Table 1](#)). Furthermore, the NOSES I includes five different methods: NOSES IA and NOSES IB are transanal specimen eversion and extra-abdominal resection technique, NOSES IC is Park technique, NOSES ID is intersphincteric resection (ISR) technique, NOSES IE is Bacon technique [14, 20].

## Indications

According to existing literature and current clinical practice, the indication of NOSES directly contributes to the feasibility of this technique. There are many requirements that should be careful considered before the implementation of NOSES in colorectal surgery. Firstly, basic requirements for NOSES should be followed. NOSES should be performed by experienced surgeons for conventional laparoscopic colorectal surgery. This is a very important prerequisite for surgeons to start NOSES. A more experienced surgeon in laparoscopic surgery may achieve a shorter learning curve for NOSES. Secondly, the indication of NOSES should follow the indication of conventional laparoscopic colorectal resection. Locally advanced tumor, acute bowel

obstruction and perforation from cancer are not recommended to perform laparoscopy. Thirdly, NOSES also has specific indication requirements, including: the depth of tumor invasion should be T2 or T3, the CDmax of specimen should be less than 3 cm for transanal-NOSES and 3–5cm for transvaginal-NOSES, body mass index (BMI) should be less than 30 kg/m<sup>2</sup> for transanal-NOSES and less than 35 kg/m<sup>2</sup> for transvaginal-NOSES [14, 21]. Fourthly, NOSES is also recommended for benign tumors, Tis and T1 tumor when local excision is not indicated for whatever reasons. Finally, transvaginal-NOSES is best to be avoided in young women who have not completed their family. The details of indication selection were shown in [Table 2](#). Furthermore, according to the indication requirements, this consensus recommends a flow chart for the selection of NOSES ([Figure 4](#)).

## Technology

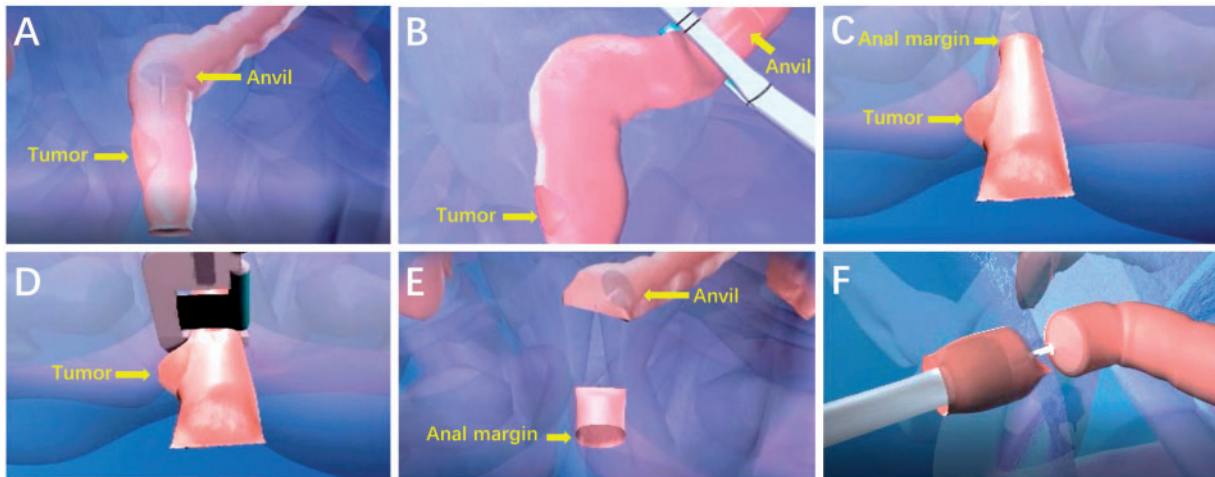
Although NOSES is an emerging technology, the innovativeness of this technology is mainly reflected in the removal of specimens and the reconstruction of the digestive tract. The main surgical instrument platform required by NOSES is the conventional 2-dimensional (2D) laparoscopic platform. Therefore, for surgeons with experience in laparoscopic surgery, the learning curve of NOSES will not be very long. In addition to 2D laparoscopic equipment, NOSES can also be performed by using other advanced equipment, such as high-definition 3D laparoscopy, the da Vinci<sup>®</sup> robotic platform, single-port laparoscopy, etc., which will provide better minimally invasive effect for NOSES [22, 23]. The high-definition 3D laparoscope makes the operation field clearer and more realistic, which helps the surgeon to complete a variety of difficult surgical operations in a relatively easy way [24]. The da Vinci<sup>®</sup> robot manipulator provides a more stable operation environment with avoiding subtle jitter of the human hands during a delicate and fine surgical dissection [23]. However, single-port laparoscopy is not routinely recommended to perform NOSES in the consideration of ‘chopstick effect’ of this technique.

Specimen extraction always requires an auxiliary tool to take the specimen out through natural orifice. Its main purpose is to avoid direct contact between specimen and natural orifice in order to ensure the aseptic and tumor-free operation. According to the current literature and clinical practice, various tools used to facilitate the specimen extraction include double-ringed wound protectors, transluminal endoscopic operation ports, self-made plastic sleeves, sterile specimen bags, Cai Tube, etc. [6, 25]. However, other study has opposite opinion that removal of specimens does not need any wound protection [6], which is not recommended in this consensus.

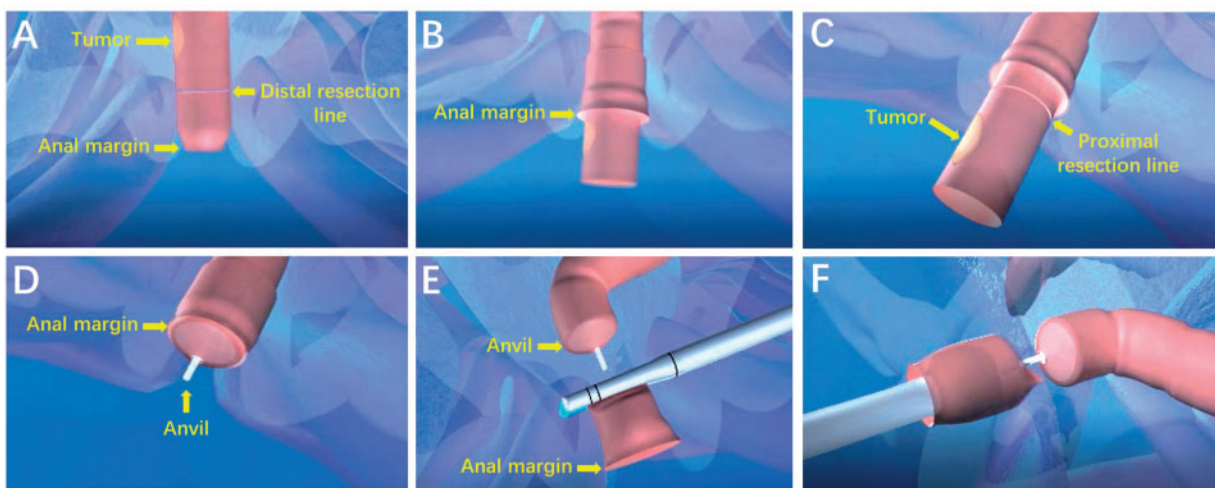
## Technical difficulty

The requirements for technical skills of NOSES are obviously higher in both of specimen extraction and digestive tract reconstruction as compared to conventional laparoscopic surgery. A steeper learning curve for NOSES is faced by surgeons who apply the laparotomy to extract specimen, especially with regard to ensure the aseptic operation. Bacteriological concerns have been raised because of the breach in peritoneal sterility in some procedures of NOSES [26], such as enterotomy and completely intraperitoneal bowel reconstruction. Previous studies have fully confirmed that the potential of bacterial contamination during NOSES by examining the bacterial positive rate of intraoperative pelvic fluid culture [27]. In order to solve this problem,





**Figure 1.** Transanal specimen eversion and extra-abdominal resection technique. (A) The anvil is introduced into the bowel lumen of rectum till to the proposed resection line of sigmoid colon. (B) Proximal bowel division is performed using linear stapler, leaving the anvil inside of sigmoid colon. (C) The rectal stump is everted out transanally. (D) The distal rectal resection is performed extraabdominally. (E) The rectal stump is delivered back to pelvic cavity. (F) The circular stapler is introduced transanally and an end-to-end anastomosis is performed



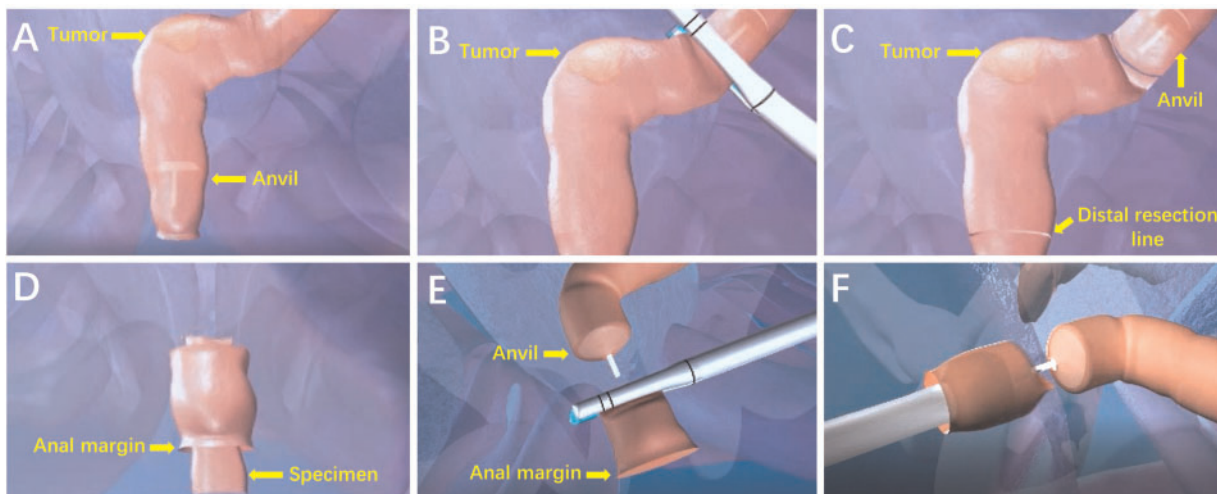
**Figure 2.** Transluminal specimen extraction and extra-abdominal resection technique. (A) The rectal wall is cut off at the distal resection line. (B) The distal side of specimen is gently pulled outside of the patient body transanally. (C) The proximal rectal resection is performed extraabdominally. (D) The anvil is introduced into the bowel lumen and closed with a purse string, and the sigmoid colon is delivered back to pelvic cavity. (E) The open rectal stump is closed by using linear stapler. (F) The circular stapling device is introduced into the rectum, and an end-to-end anastomosis is performed

this consensus recommends that prophylactic antibiotics administration, mechanical bowel preparation, intraoperative peritoneal irrigation, intraoperative transanal lavage with a large amount of povidone-iodine and normal saline, use of transluminal wound retractor and placement of pelvic or abdominal drains should be applied to reduce the bacterial load of NOSES [6, 20]. In addition, recent studies also further showed that the risk of bacterial contamination after NOSES was not significantly higher compared with conventional laparoscopic surgery [7].

In addition to bacteriological concern, there remains another major concern regarding the oncological safety in procedures of NOSES in colorectal surgery. Tumor related manipulation mainly arise from specimen extraction via narrow natural orifice, with the potential for compromise in oncological safety [27]. In clinical practice, there are also many clinical experience techniques summarized to prevent iatrogenic dissemination of

tumors, including the use of sterile protection devices when taking specimen, and avoiding over-pulling and compression of lesions during specimen extraction. Previous findings showed that transluminal specimen extraction provided the same degree of protection as in a transabdominal specimen extraction by comparison of peritoneal tumor cytology test [27]. Furthermore, the local recurrence rate and long-term oncologic results after NOSES are comparable with conventional laparoscopic surgery according to current literature search results [28]. This also indicated that NOSES in colorectal surgery can completely meet the requirements of tumor-free technology.

The vagina has many properties that are ideal for specimen extraction, including elasticity, redundant vascular supply lending to excellent healing, clean nature, and relatively easy access [29]. In gynecology, the vaginotomy is a safe technique which has been commonly used in gynecologic pathologies. In



**Figure 3.** Intra-abdominal specimen resection and transluminal extraction technique. (A) The anvil is introduced into the bowel lumen of rectum till to the proposed resection line of sigmoid colon. (B) The proximal bowel division is performed using linear stapler, leaving the anvil inside of sigmoid colon. (C) The rectal wall is cut off at the distal resection line. (D) The specimen is extracted through the anus. (E) The open rectal stump is closed with a linear stapler. (F) The circular stapling device is introduced into the rectum, and an end-to-end anastomosis is performed

**Table 1.** Natural orifice specimen extraction surgery (NOSES) techniques for colorectal neoplasms

Abbreviation	Full name	Orifice	Tumor location
NOSES I	Laparoscopic lower rectal cancer resection with transanal specimen extraction	Anus	Lower rectum
NOSES II	Laparoscopic middle rectal cancer resection with transanal specimen extraction	Anus	Middle rectum
NOSES III	Laparoscopic middle rectal cancer resection with transvaginal specimen extraction	Vagina	Middle rectum
NOSES IV	Laparoscopic upper rectal cancer resection with transanal specimen extraction	Anus	Upper rectum/distal sigmoid colon
NOSES V	Laparoscopic upper rectal cancer resection with transvaginal specimen extraction	Vagina	Upper rectum/distal sigmoid colon
NOSES VI	Laparoscopic left colectomy with transanal specimen extraction	Anus	Left colon/proximal sigmoid colon
NOSES VII	Laparoscopic left colectomy with transvaginal specimen extraction	Vagina	Left colon/proximal sigmoid colon
NOSES VIII	Laparoscopic right colectomy with transvaginal specimen extraction	Vagina	Right colon
NOSES IX	Laparoscopic total colectomy with transanal specimen extraction	Anus	Total colon
NOSES X	Laparoscopic total colectomy with transvaginal specimen extraction	Vagina	Total colon

colorectal surgery, transvaginal specimen extraction is also widely applied, especially for specimen of right colectomy [18, 30, 31]. However, the vaginotomy is not typically employed by colorectal surgeons, which may increase the difficulty of transvaginal NOSES due to the lack of standard operating procedure. Therefore, this consensus recommends that the location of vaginal incision should be selected at the posterior vaginal fornix. The posterior vaginal fornix is the most easily accessible part of vagina, and there is no obvious nerve and vessel distribution here. Therefore, the posterior colpotomy incision does not affect the sexual function and not increase the risk of bleeding. Currently, there are no complications related to the colpotomy incision reported in colorectal surgery [21].

### Clinical research

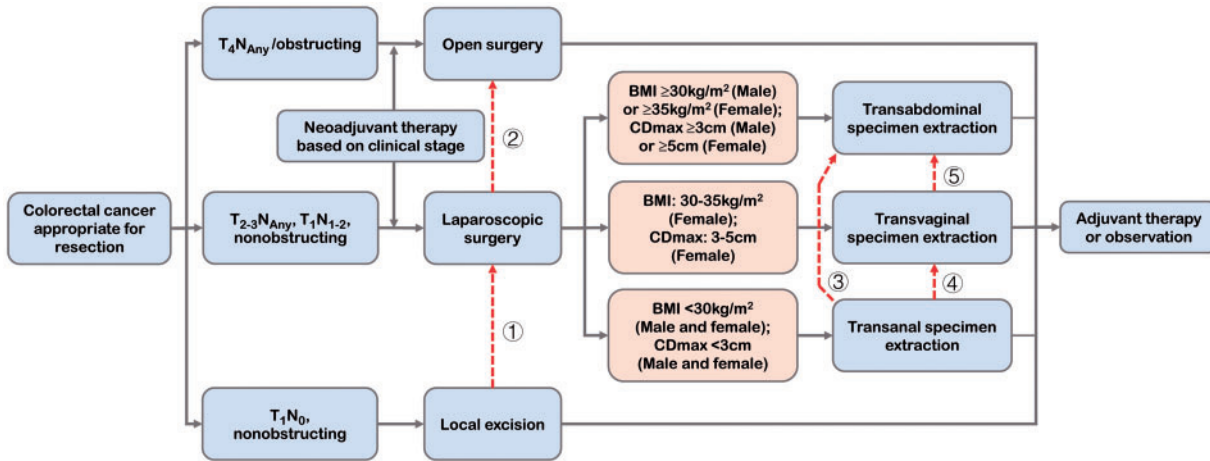
With wide adoption of NOSES, accumulating studies regarding colorectal NOSES are gradually increasing in recent years [6], and most of studies now present the advantages of NOSES including less analgesic use, less postoperative pain, better cosmetic effect and shorter length of hospital stay [32, 33]. This consensus presents many research results on the comparison between NOSES and conventional laparoscopic colorectal surgery to confirm the advantages of NOSES (Table 3). However, high-quality evidence is still needed to further demonstrate its

short- and long-term efficacy. Therefore, this consensus recommends more prospective randomized controlled clinical trials to obtain reasonable and strong evidence to support the performance of NOSES. For the purpose of clinical research, the indication could be expanded to patients with locally advanced tumor, multiple primary colorectal cancer, multi-organ resection, etc. However, there is little evidence to support the application of NOSES in this group of patients. Therefore, it is only recommended for experienced surgeons.

The short- and long-term outcomes of NOSES should be presented in clinical research. The incidence of postoperative complications (e.g. anal or vaginal dysfunction) have very important significance, these indicators are also the important references for evaluating the feasibility of NOSES. Therefore, this consensus recommends a detailed assessment of all patients undergoing NOSES. The data collection of NOSES should include surgical data, pain assessment, postoperative recovery, morbidity and mortality, pathological data, functional outcome, quality of life assessment, and oncological follow-up.

### Prospects

At present, due to the extensive development of laparoscopic and robotic techniques, most surgeons have experience in



**Figure 4.** The flow chart for the selection of natural orifice specimen extraction surgery (NOSES). BMI: body mass index; CDmax: maximum circumferential diameter  
 ① If pathologic examination shows pT2 or pT1 with high-risk features including positive margins, lymphovascular invasion, poor differentiation or invasion into the lower third of the submucosa (sm3 level), a more radical transabdominal resection is recommended.  
 ② If extensive adhesions are detected in the abdominal cavity, tumor is detected in locally advanced stage or an uncontrollable complication occurs during surgery, the laparoscopic surgery should be converted to open surgery.  
 ③ For male patient, if the specimen cannot be extracted transanally, transabdominal specimen extraction should be performed.  
 ④ For female patient, if the specimen cannot be extracted transanally, transvaginal specimen extraction should be performed.  
 ⑤ For female patient, if the specimen cannot be extracted transvaginally, transabdominal specimen extraction should be performed.

**Table 2.** The indication requirements of transanal- and transvaginal-natural orifice specimen extraction surgery (NOSES).

Indication requirements	Transanal-NOSES	Transvaginal-NOSES
Basic requirements for surgeon	Surgeon should have experience of conventional laparoscopic colorectal surgery	Surgeon should have experience of conventional laparoscopic colorectal surgery
Basic requirements for disease	Non-locally advanced tumor; No bowel obstruction and perforation; Benign tumor, Tis and T1 tumor when local excision is not indicated	Non-locally advanced tumor; No bowel obstruction and perforation; Benign tumor, Tis and T1 tumor when local excision is not indicated
Tumor invasion depth	T2 or T3 most appropriate	T2 or T3 most appropriate
Maximum circumferential diameter of specimen	<3 cm most appropriate	3–5 cm most appropriate
Body mass index	<30 kg/m <sup>2</sup> most appropriate	30-35 kg/m <sup>2</sup> most appropriate
Other requirements	Anal stenosis and anal dysfunction should be not recommended	Young women who have not completed their family should be not recommended

**Table 3.** Related studies confirming the advantages of natural orifice specimen extraction surgery (NOSES) compared with conventional laparoscopic colorectal resection

Potential advantages	Transanal-NOSES	Transvaginal-NOSES
Faster recovery	[23], [28], [34], [35]	[36]
Shorter hospital stay	[23], [28], [34], [35], [37]	[8]
Better postoperative pain control	[23, 34, 37], [9], [38]	[8], [36]
Reduced incisional complications	[28, 35], [9]	[33], [36]
Improved cosmesis	[39]	[8], [33], [36]

minimally invasive surgery, which also provides favorable pre-requisites and basis for the development of NOSES. Here, we also appeal to all surgical colleagues working on NOSES to comply with the specific requirements in this NOSES consensus, to strictly select indication of NOSES and to guarantee the

standardization of NOSES. As an attractive minimally invasive technique, NOSES should homogenize worldwide. This consensus will be of great significance to the improvement of NOSES, and also a necessary prerequisite for the development of NOSES in the world.



## Supplementary data

Supplementary data is available at Gastroenterology Report online

## Acknowledgment

Thanks to all members of the International Alliance of NOSES for their contributions to the development and revision of this consensus.

Conflict of interest statement: none declared.

## References

- Bonjer HJ, Deijen CL, Abis GA et al. A randomized trial of laparoscopic versus open surgery for rectal cancer. *N Engl J Med* 2015;**373**:1324–32.
- Fleshman J, Branda M, Sargent DJ et al. Effect of laparoscopic-assisted resection vs open resection of stage II or III rectal cancer on pathologic outcomes: the ACOSOG Z6051 randomized clinical trial. *JAMA* 2015;**314**:1346–55.
- Stevenson ARL, Solomon MJ, Lumley JW et al. Effect of laparoscopic assisted resection vs open resection on pathological outcomes in rectal cancer. The ALaCaRT randomized clinical trial. *JAMA* 2015;**314**:1356–63.
- Kamiński JP, Pai A, Ailabouni L et al. Role of epidural and patient-controlled analgesia in site-specific laparoscopic colorectal surgery. *JLS* 2014;**18**:Pii: e204.00207.
- Winslow ER, Fleshman JW, Bimbaum EH et al. Wound complications of laparoscopic vs open colectomy. *Surg Endosc* 2002;**16**:1420–5.
- Wolthuis AM, de Buck van Overstraeten A, D’Hoore A. Laparoscopic natural orifice specimen extraction-colectomy: a systematic review. *World J Gastroenterol* 2014;**20**:12981–92.
- Guan X, Wang GY, Zhou ZQ et al. Retrospective study of 718 colorectal neoplasms treated by natural orifice specimen extraction surgery in 79 hospitals. *Chin J Colorec Dis (Electronic Edition)* 2017;**6**:469–77.
- Park JS, Choi GS, Kim HJ et al. Natural orifice specimen extraction versus conventional laparoscopically assisted right hemicolectomy. *Br J Surg* 2011;**98**:710–5.
- Costantino FA, Diana M, Wall J et al. Prospective evaluation of peritoneal fluid contamination following transabdominal vs. transanal specimen extraction in laparoscopic left-sided colorectal resections. *Surg Endosc* 2012;**26**:1495–500.
- Karagul S, Kayaalp C, Sumer F et al. Success rate of natural orifice specimen extraction after laparoscopic colorectal resections. *Tech Coloproctol* 2017;**21**:295–300.
- Senft JD, Warschkow R, Diener MK et al. The transvaginal hybrid NOTES versus conventionally assisted laparoscopic sigmoid resection for diverticular disease (TRANSVERSAL) trial: study protocol for a randomized controlled trial. *Trials* 2014;**15**:454.
- Nau P, Ellison EC, Muscarella P et al. A review of 130 humans enrolled in transgastric NOTES protocols at a single institution. *Surg Endosc* 2011;**25**:1004–11.
- Wang XS. Prospects and challenges of NOSES, NOTES, taTME. *Chin J Gastrointest Surg* 2018;**21**:16–21.
- China NOSES Alliance. Expert consensus of natural orifice specimen extraction surgery in colorectal neoplasm (2017 edition). *Chin J Colorec Dis (Electronic Edition)* 2017;**6**:266–72.
- Abu Gazala M, Wexner SD. Re-appraisal and consideration of minimally invasive surgery in colorectal cancer. *Gastroenterol Rep (Oxf)* 2017;**5**:1–10.
- Wolthuis AM, Penninckx F, D’Hoore A. Laparoscopic sigmoid resection with transrectal specimen extraction has a good short-term outcome. *Surg Endosc* 2011;**25**:2034–8.
- Yagci MA, Kayaalp C, Novruzov NH. Intracorporeal mesenteric division of the colon can make the specimen more suitable for natural orifice extraction. *J Laparoendosc Adv Surg Tech A* 2014;**24**:484–6.
- Torres RA, Orban RD, Tocaimaza L et al. Transvaginal specimen extraction after laparoscopic colectomy. *World J Surg* 2012;**36**:1699–702.
- Nishimura A, Kawahara M, Honda K et al. Totally laparoscopic anterior resection with transvaginal assistance and transvaginal specimen extraction: a technique for natural orifice surgery combined with reduced-port surgery. *Surg Endosc* 2013;**27**:4734–40.
- Wang XS. *Natural Orifice Specimen Extraction Surgery*. Berlin: Springer, 2018.
- Izquierdo KM, Unal E, Marks JH. Natural orifice specimen extraction in colorectal surgery: patient selection and perspectives. *Clin Exp Gastroenterol* 2018;**11**:265–79.
- Fu C, Han J. Strategy and technique for simultaneous resection of rectal cancer and liver metastasis. *Chin J Gastrointest Surg* 2017;**20**:618–20.
- Kang J, Min BS, Hur H et al. Transanal specimen extraction in robotic rectal cancer surgery. *Br J Surg* 2012;**99**:133–6.
- Feng X, Morandi A, Boehne M et al. 3-Dimensional (3D) laparoscopy improves operating time in small spaces without impact on hemodynamics and psychomental stress parameters of the surgeon. *Surg Endosc* 2015;**29**:1231–9.
- Cai JC, Hong XY. Laparoscopic-assisted natural orifice specimen extraction radical descending colectomy using a Cai tube. *World J Surg* 2016;**40**:2803–7.
- Leroy J, Costantino F, Cahill RA et al. Laparoscopic resection with transanal specimen extraction for sigmoid diverticulitis. *Br J Surg* 2011;**98**:1327–34.
- Ngu J, Wong AS. Transanal natural orifice specimen extraction in colorectal surgery: bacteriological and oncological concerns. *ANZ J Surg* 2016;**86**:299–302.
- Park JS, Kang H, Park SY et al. Long-term outcomes after Natural Orifice Specimen Extraction versus conventional laparoscopy-assisted surgery for rectal cancer: a matched case-control study. *Ann Surg Treat Res* 2018;**94**:26–35.
- Sehgal R, Cahill RA. Advanced laparoscopic surgery for colorectal disease: NOTES/NOSE or single port? *Best Pract Res Clin Gastroenterol* 2014;**28**:81–96.
- Franklin ME, Jr, Liang S, Russek K. Natural orifice specimen extraction in laparoscopic colorectal surgery: transanal and transvaginal approaches. *Tech Coloproctol* 2013;**17**(Suppl 1): S63–7.
- McKenzie S, Baek JH, Wakabayashi M et al. Totally laparoscopic right colectomy with transvaginal specimen extraction: the authors’ initial institutional experience. *Surg Endosc* 2010;**24**:2048–52.
- Wang XS. Current challenges and prospects of NOSES in China. *Chin J Colorec Dis (Electronic Edition)* 2018;**7**:2–7.
- Awad Z, Griffin R. Laparoscopic right hemicolectomy: a comparison of natural orifice vs. transabdominal specimen extraction. *Surg Endosc* 2014;**28**:2871–6.

34. Saurabh B, Chang SC, Ke TW et al. Natural orifice specimen extraction with single stapling colorectal anastomosis for laparoscopic anterior resection: feasibility, outcomes, and technical considerations. *Dis Colon Rectum* 2017;**60**:43–50.
35. Xingmao Z, Haitao Z, Jianwei L et al. Totally laparoscopic resection with natural orifice specimen extraction (NOSE) has more advantages comparing with laparoscopic-assisted resection for selected patients with sigmoid colon or rectal cancer. *Int J Colorectal Dis* 2014;**29**:1119–24.
36. Kim HJ, Choi GS, Park JS et al. Transvaginal specimen extraction versus conventional minilaparotomy after laparoscopic anterior resection for colorectal cancer: mid-term results of a case-matched study. *Surg Endosc* 2014;**28**:2342–8.
37. Wolthuis AM, Fieuws S, Van Den Bosch A et al. Randomized clinical trial of laparoscopic colectomy with or without natural-orifice specimen extraction. *Br J Surg* 2015;**102**:630–7.
38. Hisada M, Katsumata K, Ishizaki T et al. Complete laparoscopic resection of the rectum using natural orifice specimen extraction. *World J Gastroenterol* 2014;**20**:16707–13.
39. Wolthuis AM, Meuleman C, Tomassetti C et al. How do patients score cosmesis after laparoscopic natural orifice specimen extraction colectomy? *Colorectal Dis* 2015;**17**: 536–41.