

Effect of Double-Balloon Enteroscopy on Diagnosis and Treatment of Small-Bowel Diseases

Li Tang¹, Liu-Ye Huang², Jun Cui², Cheng-Rong Wu²

¹Department of Clinical Medicine, Qingdao University Medical College, Qingdao, Shandong 266021, China

²Department of Gastroenterology, The Affiliated Yantai Yuhuangding Hospital of Qingdao University, Yantai, Shandong 264000, China

Abstract

Background: The diagnosis and treatment of small-bowel diseases is clinically difficult. The purpose of this study was to evaluate the diagnostic and therapeutic value of double-balloon enteroscopy in small-bowel diseases.

Methods: The history and outcomes of 2806 patients who underwent double-balloon enteroscopy from July 2004 to April 2017 were reviewed, which included 562 patients with obscure digestive tract bleeding, 457 patients with obscure diarrhea, 930 patients with obscure abdominal pain, 795 patients with obscure weight loss, and 62 patients with obscure intestinal obstruction. Examinations were performed through the mouth and/or anus according to the clinical symptoms and abdominal images. If a lesion was not detected through one direction, examination through the other direction was performed as necessary. Eighty-four patients with small-bowel polyps, 26 with intestinal obstruction caused by enterolith, and 18 with bleeding from Dieulafoy's lesions in the small intestine were treated endoscopically.

Results: A total of 2806 patients underwent double-balloon enteroscopy, and no serious complications occurred. An endoscopic approach through both the mouth and anus was used in 212 patients. Lesions were detected in 1696 patients, with a detection rate of 60.4%; the rates for obscure digestive tract bleeding, diarrhea, abdominal pain, weight loss, and intestinal obstruction were 85.9% (483/562), 73.5% (336/457), 48.2% (448/930), 49.1% (390/795), and 62.9% (39/62), respectively. For patients with small-bowel polyps who underwent endoscopic therapy, no complications such as digestive tract bleeding and perforation occurred. Intestinal obstruction with enteroliths was relieved with endoscopic lithotripsy. Among the 18 patients with bleeding from small-bowel Dieulafoy's lesions, 14 patients were controlled with endoscopic hemostasis.

Conclusion: Double-balloon enteroscopy is useful for diagnosing and treating some small-bowel disease.

Key words: Diagnosis; Double-Balloon Enteroscopy; Small Bowel; Therapy

INTRODUCTION

The small bowel is vital for digestion and absorption and is located between the stomach and large bowel. Because of its anatomical position, the small bowel was originally thought to be a "blind area" beyond the reach of ordinary endoscopic examination, leading to difficulty in diagnosing small-bowel disease.^[1] The introduction of double-balloon enteroscopy, enabling examination of the entire small bowel through the mouth and anus, facilitated the accurate diagnosis of small-bowel disease.^[2] Further improvements in instrumentation have allowed for endoscopic microtraumatic therapy for small intestinal disease.^[3] Small-bowel polyps can be resected with double-balloon enteroscopy, intestinal obstruction caused by enteroliths can be treated with endoscopic lithotripsy, and small intestinal bleeding caused by Dieulafoy's lesions can be treated endoscopically, thus

avoiding open surgery to treat these conditions. The purpose of this study was to explore the value of double-balloon enteroscopy to diagnose and treat small-bowel disease.

METHODS

Ethical approval

The study was conducted in accordance with the *Declaration of Helsinki* and was approved by the Research Ethics

Address for correspondence: Dr. Jun Cui,

Department of Gastroenterology, The Affiliated Yantai Yuhuangding Hospital of Qingdao University, 20 Yu Huang Ding Road East, Zhifu

District, Yantai, Shandong 264000, China

E-Mail: cuijun89@163.com

This is an open access journal, and articles are distributed under the terms of the Creative Commons Attribution-NonCommercial-ShareAlike 4.0 License, which allows others to remix, tweak, and build upon the work non-commercially, as long as appropriate credit is given and the new creations are licensed under the identical terms.

For reprints contact: reprints@medknow.com

© 2018 Chinese Medical Journal | Produced by Wolters Kluwer - Medknow

Received: 07-02-2018 **Edited by:** Xin Chen

How to cite this article: Tang L, Huang LY, Cui J, Wu CR. Effect of Double-Balloon Enteroscopy on Diagnosis and Treatment of Small-Bowel Diseases. *Chin Med J* 2018;131:1321-6.

Access this article online

Quick Response Code:



Website:
www.cmj.org

DOI:
10.4103/0366-6999.232802

Committee of the Affiliated Yantai Yuhuangding Hospital of Qingdao University. Informed written consent was obtained from all patients before their enrollment in this study.

Patients

From July 2004 to April 2017, 2806 patients who underwent double-balloon enteroscopy, including 562 patients with obscure digestive tract bleeding, 457 patients with obscure diarrhea, 930 patients with obscure abdominal pain, 795 patients with obscure weight loss, and 62 patients with obscure intestinal obstruction, were examined. Patients included 1712 men and 1094 women with the age of 14–83 years (average age: 43 years). All patients had undergone gastroscopy, colonoscopy, abdominal computed tomography and/or magnetic resonance imaging, or radionuclide examination without a clear diagnosis; therefore, double-balloon enteroscopy was performed. Eighty-four patients with small-bowel polyps, 26 with intestinal obstruction caused by enteroliths, and 18 with small intestinal bleeding from Dieulafoy's lesions were enrolled. These patients were treated with endoscopic polypectomy, endoscopic lithotripsy, and endoscopic hemostasis, respectively.

Instruments and procedures

The Fujinon EN-450P5/20 double-balloon enteroscope (Fujinon Corporation, Saitama, Japan) comprises a scope and a trocar sheath. The enteroscope is 2-m long and 8.5 mm in diameter with a visual angle of 120°. The trocar sheath is 1.5-m long. One balloon is located at the anterior extremity of the scope and can reach 2.5 cm in diameter when charged; the other is located at the tip of the trocar sheath and can reach 5 cm in diameter when charged. The pressure in the balloon is 5.6–8.2 kPa, and the scope can be advanced by charging and discharging the balloon. Also necessary are a single-use snare, injection needles, titanium clips, a high-frequency electric knife, and argon plasma coagulation (APC) equipment (Erbe Elektromedizin GmbH, Tubingen, German).

Preexamination preparation

An electrocardiogram, routine blood evaluation, liver and renal function tests, blood typing, and blood coagulation tests were performed in each patient. Based on symptoms and test results, patients were examined with the double-balloon enteroscope through the mouth or anus. If the lesion could not be detected from one direction, methylene blue was injected as a marker and examination was continued from the other direction until the marked site was observed. Twelve hours of fasting was required for examination through the mouth, and clearance of the small bowel was necessary for the anal approach. Oxygen supply, electrocardiographic, and oxygen saturation monitoring were performed throughout the procedure, and disoprofol was injected 10 min before examination.

Examination method

An assistant held the scope and fixed the trocar sheath while the doctor performed the examination. When the two

balloons reached the horizontal part of the duodenum, the scope's balloon was charged so that the scope could fix to the duodenal wall, then the trocar sheath was pushed to the tip of the scope, and the balloon of the trocar sheath was charged. With the two balloons charged, the scope and trocar sheath were fixed to the wall of the duodenum; the scope and trocar sheath were then pulled, the small bowel was invaginated to the trocar sheath, and the scope straightened. The scope's balloon was discharged and the scope pushed ahead, and then the balloon was recharged and the balloon of the trocar sheath discharged to push the trocar sheath ahead. Charging and discharging the balloons was repeated in a push-and-pull manner until the lesion was detected. Charging and discharging the two balloons was automatically controlled with an air pump at a pressure of 6.0–6.5 kPa when discharged and 7.0–7.5 kPa when charged.

Endoscopic polypectomy for small-bowel polyps

Based on the size and shape of the polyps, an appropriate method was used as follows: (1) for polyps <10 mm in size, high-frequency electric coagulation, APC, or snare trap; (2) for pedunculated 10–30 mm polyps, a snare trap; (3) for thin and flat or wide-based polyps >20 mm in size, endoscopic mucosal resection; and (4) for large polyps >30 mm in size, endoscopic one-piece mucosal resection.^[4]

Adrenaline saline (1:10,000) was injected submucosally to protrude the mucosa. For polyp resection with endoscopic mucosal resection, direct snare or coagulation should be avoided to prevent small-bowel perforation. Spray hemostatics, adrenaline saline injection, APC, and titanium clips were used to prevent posttreatment bleeding; for deep wound surfaces, titanium clips were used to prevent perforation.

Fasting for 2–3 days with fluid replacement and intravenous nutrition was necessary after endoscopic polypectomy. Clinical signs and presentations such as body temperature, abdominal pain, fever, and hematochezia were monitored during this time.

Enterolith treatment

When the double-balloon enteroscope reached the enterolith, we used a snare to trap the enterolith. For soft enteroliths, direct cutting was preferred. For hard and large enteroliths, *in vitro* lithotripsy was used. Large enteroliths were crushed using a mechanical lithotripter (Olympus Corporation, Tokyo, Japan). The stone was grasped with the lithotripter under direct vision and crushed into small fragments. We then injected paraffin into the small intestinal lumen to encourage the enterolith to pass easily.

Method for small intestinal Dieulafoy's lesion bleeding

The diagnostic criteria for Dieulafoy's lesions were as follows: (1) arterial spurt or impulsive bleeding detected on a localized mucosal ulcer or erosion; (2) constant-diameter (1–3 mm) arterial blood vessel detected on a localized mucosal ulcer or erosion, with or

without bleeding; (3) blood clot or thrombus seen on a localized mucosal ulcer or erosion.^[5]

The method for titanium clip hemostasis was as follows: when the enteroscope was inserted, if the field of vision was not clear because of blood in the intestinal cavity, cooled noradrenaline (8 mg noradrenaline added to 100–200 ml of cooled saline) was used as a spray until the bleeding lesion was exposed.^[6] Based on the size of the bleeding vessel, a suitable titanium clip was selected, the clip was stretched open at the bleeding vessel, and the vessel was clamped with the clip. As many titanium clips as necessary were used until bleeding was controlled, and observation continued for 5 min after titanium clip hemostasis. For some patients, submucosal injection of 1:10000 adrenaline saline was needed posthemostasis. After the procedure, bed rest and avoidance of heavy exercise was mandatory. Abdominal pain and stools were monitored, with administration of blood transfusion and fluid infusion as necessary.

RESULTS

Endoscopic examination results

A total of 2806 patients underwent enteroscopy examination, 212 through both the mouth and anus. Lesions were detected in 1696 patients, with a detection rate of 60.4% [Table 1]. The detection rates were 85.9% (483/562) for obscure digestive tract bleeding, 73.5% (336/457) for obscure diarrhea, 48.2% (448/930) for obscure abdominal pain, 49.1% (390/795) for obscure weight loss, and 62.9% (39/62) for intestinal obstruction. Among the 483 patients with obscure digestive tract bleeding, the three most common conditions were nonsteroidal anti-inflammatory drug-related ulcer (17.4%), stromal tumor (14.1%), and allergic purpura (9.4%). Figures 1-5 show small intestinal stromal tumor, lymphoma, angioma, duplication, and leiomyosarcoma.

Safety of double-balloon enteroscopy

Of the 2806 double-balloon enteroscopy procedures, 212 were performed through both the mouth and anus. All of the patients tolerated the procedure under intravenous anesthesia without side effects. Almost all patients examined via the anus tolerated the procedure, also with no side effects. Some patients who underwent oral examination without anesthesia had nausea and transient abdominal pain, which resolved spontaneously without the need for specific treatment. There were no complications related to suffocation, bleeding, and perforation.

Clinical characteristics of double-balloon enteroscopy examination

The average duration of the procedure was 100 min (range: 40–180 min). Endoscopy through the mouth could reach the small bowel of the 3rd–5th groups, and the ileocecal valve could be reached within 5–10 min through the anus, whereby it was easy to reach the small bowel of the 4th–6th groups. Six patients with intestinal duplication in this

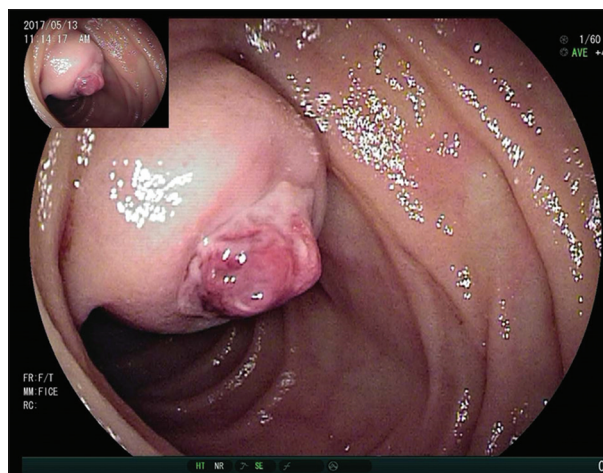


Figure 1: High-risk stromal tumor in the small intestine complicated by bleeding.

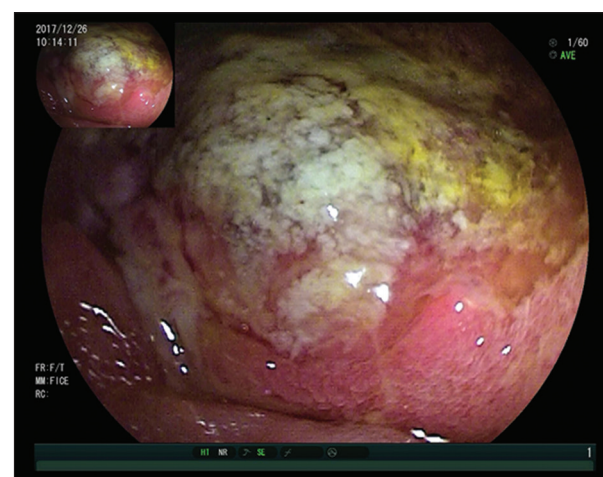


Figure 2: Small intestinal lymphoma.

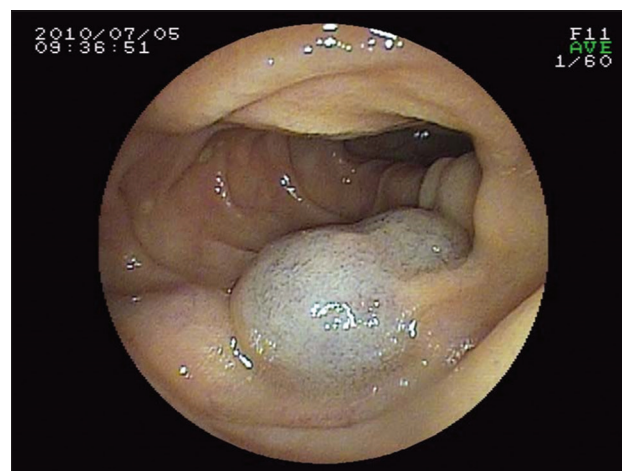


Figure 3: Small intestinal angioma.

study had symptoms of digestive bleeding, and no rebleeding occurred in the six patients who underwent surgery.

- Endoscopic polypectomy to remove small-bowel polyps involved no digestive tract bleeding and perforation, and open surgery was avoided

Table 1: Results of 2806 patients undergoing examination by double-balloon enteroscopy

Lesion*	Number of cases	Number of cases underwent examination through both mouth and anus
Obscure digestive tract bleeding	562	53
Vascular malformation	9	2
Angioma	12	3
Leiomyoma	10	0
Polyp (include Peutz-Jeghers syndrome)	42	3
Leiomyosarcoma	8	0
Crohn's disease	25	0
Stromal tumor	77	6
Lipoma	5	1
Multiulcer (NSAID related)	98	17
Diverticulum of ileum complicated with fistula cannulas	18	2
Duplication of intestine	6	1
Meckel's diverticulum with ulcer	21	2
Adenocarcinoma	35	2
Allergic purpura	53	5
Dieulafoy's disease	18	1
Lymphangioma	11	0
Portal hypertensive small intestine disease	35	2
Undetected lesion	79	14
Diarrhea	457	106
Small-bowel nonspecific inflammation	112	22
Multierosion	141	23
Polyp (include Peutz-Jeghers syndrome)	20	2
Crohn's disease	24	1
Celiac disease	4	0
Tuberculosis of small intestine	35	2
Undetected lesion	121	56
Abdominal pain	930	42
Small-bowel nonspecific inflammation	369	12
Crohn's disease	8	0
Polyp (include Peutz-Jeghers syndrome)	14	2
Small-bowel metastatic tumor	3	0
Lymphoma	6	0
Acidophilia enteritis	45	3
Behcet's disease	3	0
Undetected lesion	482	25
Weight loss	795	10
Small-bowel nonspecific inflammation	384	6
Adenocarcinoma	6	0
Undetected lesion	405	4
Obscure partial Intestinal obstruction	62	1
Polyp (include Peutz-Jeghers syndrome)	8	0
Crohn's disease	3	0
Adenocarcinoma	2	0
Enterolith	26	1
Undetected lesion	23	0

*Confirmed with surgery or pathology. NSAID: Nonsteroidal anti-inflammatory drug.

- Similarly, surgery was unnecessary after endoscopic lithotripsy for small intestinal obstruction caused by an enterolith because the obstruction was relieved when the enterolith was shattered
- Among the 18 patients with bleeding from Dieulafoy's lesions of the small bowel, 14 patients were controlled with endoscopic hemostasis. The success rate was

77.8%, and bleeding recurred in four patients who subsequently underwent surgery.

DISCUSSION

Capsule endoscopy is an innovative method for diagnosing small-bowel disease. The reported positivity rate of capsule endoscopy for diagnosing small-bowel disease

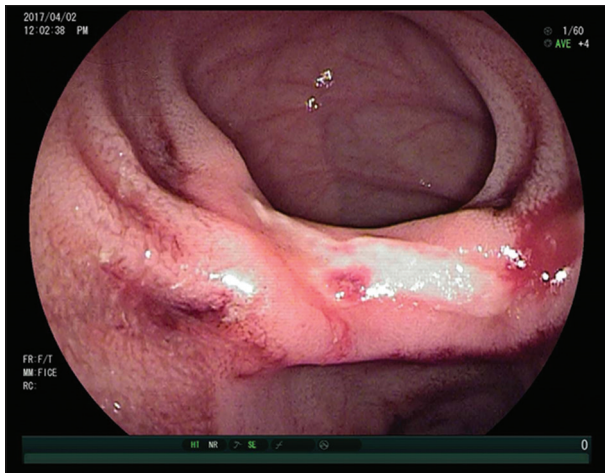

Figure 4: Intestinal duplication complicated by ulcer and bleeding.

is approximately 45–81% with an accuracy rate of approximately 20–30%. However, biopsy is not possible using this approach, the precise lesion location cannot be determined, and endoscopic therapy is not possible, which limit its use.^[7] Double-balloon enteroscopy partly overcomes the deficiencies of capsule endoscopy, enabling examination of the entire small bowel while making biopsy and therapy possible.^[8] The diagnostic rate of double-balloon enteroscopy for small-bowel disease ranges from 82.4% to 86.8%.^[9] The importance of double-balloon enteroscopy lies in differential diagnostics of lesions identified using capsule endoscopy with possible biopsy sampling and in the therapeutic potential of this method in patients with complications (stenosis dilation, extracting retained capsule endoscopy, and controlling bleeding). In our study, 2806 patients underwent a total of 3018 examinations, and lesions were detected in 1696 patients with a diagnostic rate of 60.4%. Specifically, the diagnostic rate for obscure digestive tract bleeding in 562 patients was 85.9% (483/562), and the rate for obscure diarrhea was 73.5% (336/457); the rates for obscure abdominal pain and weight loss were low, namely, 48.2% (448/930) and 49.1% (390/795), respectively; the rate for obscure intestinal obstruction was 62.9% (39/62). Our results showed that double-balloon enteroscopy was the most effective method for diagnosing obscure digestive tract bleeding. However, our evaluation of the diagnostic value of double-balloon enteroscopy for obscure abdominal pain and weight loss was insufficient because specificity and sensitivity for this technique require multicenter studies with larger cohorts. Nevertheless, enteroscopy through the mouth and anus enables examination of the entire small bowel, complementing imaging and pathological data and improving the lesion-detection rate. Given this evidence, double-balloon enteroscopy represents a preferred choice for diagnosing suspected small-bowel disease in patients who are able to tolerate the examination.

Previously, some patients suffered acute pancreatitis after enteroscopy through the mouth because the pressure in the

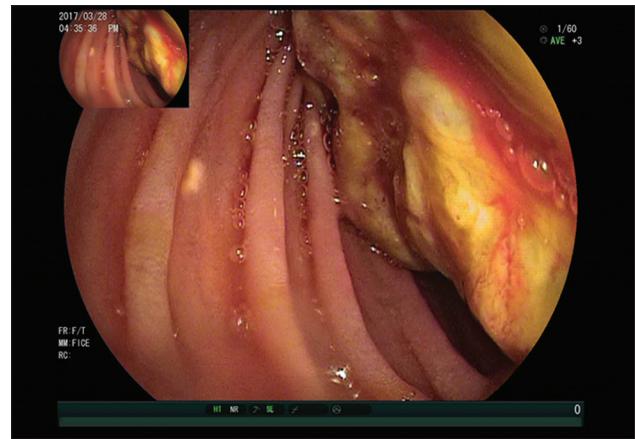


Figure 5: Leiomyosarcoma protruding into the small intestinal lumen.

intestinal cavity during the procedure was too high because of excess infusion of gas.^[10] However, no such complication occurred in this study, suggesting that during enteroscopy through the mouth, the operator reduced the gas flow in the intestine to reduce the pressure in the intestinal tract. Splenic rupture following deep enteroscopy has also been reported,^[11] but did not occur in this study; our experience showed that brute force should be avoided when the scope is being moved forward and backward.

Manifestations of allergic purpura in the small bowel include mucous hyperemia and edema, irregular form, ulcer visible in some patients, normal mucosa between the lesions, and nonspecific inflammation under pathological examination.^[12] Intestinal duplication has no specificity and involves repeated abdominal pain, digestive tract bleeding, and abdominal mass, depending on the location and size. Six patients in this study had symptoms of digestive bleeding, perhaps the reason is that other patients with intestinal duplication had no symptoms and they did not undergo enteroscopy. The most common clinical manifestation of intestinal duplication is digestive bleeding, with good recovery being reported after surgery.^[13] No rebleeding occurred in our six patients who underwent surgery.

Small intestinal stromal tumor (SIST) often occurs in patients aged 50–60 years. The most common site is the jejunum, followed by the duodenum and ileum. The most frequent clinical manifestation of SIST is digestive bleeding because a tumor located in the muscular layer can grow into the submucosa and subserosa leading to an ulcer, which causes bleeding. Such patients always have dark stools. If bleeding is profuse, patients may experience dizziness, weakness, pale skin and conjunctiva, and even syncope and shock.^[14] The main methods for diagnosing SIST are digestive tract X-ray, abdominal computed tomography, capsule endoscopy, and double-balloon enteroscopy. In our study, diagnosis by double-balloon enteroscopy had the advantage of confirming the size of the tumor and verifying the pathological diagnosis with biopsy. With a detection rate of 75–90%, double-balloon enteroscopy represents a viable method for diagnosing SIST.

The usual therapy for small-bowel polyps is surgery. For multiple small-bowel polyps, a single operation is insufficient to resect all polyps, and further procedures could lead to complications such as short-bowel syndrome, intestinal adhesion, intestinal obstruction, and malnutrition. Bleeding complications and perforation can occur in patients who undergo endoscopic polypectomy, and the larger the polyp, the more often the complication occurs.^[15] In this study, 84 patients underwent endoscopic polypectomy with no complications. The following measures for polypectomy of small-bowel polyps were taken: for wound bleeding, noradrenaline saline spray, APC, and titanium clip hemostasis are used. For long and thick polyps, a nylon ligature can be placed at the stem root before polypectomy followed by injection of 1:10,000 adrenaline saline at the stem root. Endoscopic polypectomy was an effective method for polypectomy of small-bowel polyps in our study, especially for multiple polyps, as it could be performed several times to remove the polyps in stages. Briefly, this method has the advantages of fewer complications, microtrauma, high safety, and low cost, with high clinical application value and promise.

Intestinal obstruction caused by enteroliths is uncommon, accounting for 3–4% of intestinal obstructions. The most frequent cause of an enterolith is taking persimmon; gum and pectin in persimmon aggregate when they meet gastric acid and can precipitate and agglomerate as well as form a huge mass with food. These masses move to both the small and large intestine. At the egress of the ileocecal valve, a large enterolith was reported to obstruct the inferior segment of the ileum.^[16] Formerly, the treatment for intestinal obstruction caused by an enterolith was open surgery. In this study, we shattered the enterolith using a snare within the intestinal lumen using double-balloon enteroscopy while paraffin was injected into the small intestine to encourage passing the shattered enterolith, thus avoiding surgery.

In summary, double-balloon enteroscopy is safe and effective for diagnosing small-bowel disease. For some small-bowel polyps, small intestinal obstruction caused by an enterolith, and small intestinal bleeding from Dieulafoy's lesion, endoscopic therapy is a viable alternative to open surgery.

Financial support and sponsorship

Nil.

Conflicts of interest

There are no conflicts of interest.

REFERENCES

1. Shin JY, Park IS, Bang BW, Kim HK, Shin YW, Kwon KS, *et al.* A case of primary small bowel melanoma diagnosed by single-balloon enteroscopy. *Clin Endosc* 2017;50:395-9. doi: 10.5946/ce.2016.153.
2. Saito Y, Hiramatsu K, Nosaka T, Ozaki Y, Takahashi K, Naito T, *et al.* A case of protein-losing enteropathy caused by sclerosing mesenteritis diagnosed with capsule endoscopy and double-balloon enteroscopy. *Clin J Gastroenterol* 2017;10:351-6. doi: 10.1007/s12328-017-0755-y.
3. de Latour RA, Kilaru SM, Gross SA. Management of small bowel polyps: A literature review. *Best Pract Res Clin Gastroenterol* 2017;31:401-8. doi: 10.1016/j.bpg.2017.06.003.
4. Rahmi G, Vinet MA, Perrod G, Saurin JC, Samaha E, Ponchon T, *et al.* Efficacy of double-balloon enteroscopy for small-bowel polypectomy: Clinical and economic evaluation. *Therap Adv Gastroenterol* 2017;10:465-72. doi: 10.1177/1756283X17696232.
5. Holleran G, Hussey M, McNamara D. Small bowel Dieulafoy lesions: An uncommon cause of obscure bleeding in cirrhosis. *World J Gastrointest Endosc* 2016;8:568-71. doi: 10.4253/wjge.v8.i16.568.
6. Lipka S, Rabbanifard R, Kumar A, Brady P. A single-center United States experience with bleeding Dieulafoy lesions of the small bowel: Diagnosis and treatment with single-balloon enteroscopy. *Endosc Int Open* 2015;3:E339-45. doi: 10.1055/s-0034-1391901.
7. Nakano M, Oka S, Tanaka S, Igawa A, Kuniyama S, Ueno Y, *et al.* Indications for small-bowel capsule endoscopy in patients with chronic abdominal pain. *Intern Med* 2017;56:1453-7. doi: 10.2169/internalmedicine.56.7458.
8. Takenaka K, Ohtsuka K, Kitazume Y, Matsuoka K, Fujii T, Nagahori M, *et al.* Magnetic resonance evaluation for small bowel strictures in Crohn's disease: Comparison with balloon enteroscopy. *J Gastroenterol* 2017;52:879-88. doi: 10.1007/s00535-016-1284-z.
9. ASGE Standards of Practice Committee, Gurudu SR, Bruining DH, Acosta RD, Eloubeidi MA, Faulx AL, *et al.* The role of endoscopy in the management of suspected small-bowel bleeding. *Gastrointest Endosc* 2017;85:22-31. doi: 10.1016/j.gie.2016.06.013.
10. Tsujikawa T, Bamba S, Inatomi O, Hasegawa H, Ban H, Nishida A, *et al.* Factors affecting pancreatic hyperamylasemia in patients undergoing peroral single-balloon enteroscopy. *Dig Endosc* 2015;27:674-8. doi: 10.1111/den.12449.
11. Girelli CM, Pometta R, Faccioto C, Mella R, Bernasconi G. First report of splenic rupture following deep enteroscopy. *World J Gastrointest Endosc* 2016;8:391-4. doi: 10.4253/wjge.v8.i9.391.
12. Nam EJ, Kim GW, Kang JW, Im CH, Jeon SW, Cho CM, *et al.* Gastrointestinal bleeding in adult patients with Henoch-Schönlein purpura. *Endoscopy* 2014;46:981-6. doi: 10.1055/s-0034-1377757.
13. Górecki W, Bogusz B, Zajac A, Soltysiak P. Laparoscopic and laparoscopy-assisted resection of enteric duplication cysts in children. *J Laparoendosc Adv Surg Tech A* 2015;25:838-40. doi: 10.1089/lap.2015.0103.
14. Nakano A, Nakamura M, Watanabe O, Yamamura T, Funasaka K, Ohno E, *et al.* Endoscopic characteristics, risk grade, and prognostic prediction in gastrointestinal stromal tumors of the small bowel. *Digestion* 2017;95:122-31. doi: 10.1159/000454728.
15. Gaspar JP, Stelow EB, Wang AY. Approach to the endoscopic resection of duodenal lesions. *World J Gastroenterol* 2016;22:600-17. doi: 10.3748/wjg.v22.i2.600.
16. Ishioka M, Jin M, Matsuhashi T, Arata S, Suzuki Y, Watanabe N, *et al.* True primary enterolith treated by balloon-assisted enteroscopy. *Intern Med* 2015;54:2439-42. doi: 10.2169/internalmedicine.54.5208.

双气囊小肠镜对小肠疾病诊治的研究

摘要

背景：临床上小肠疾病的诊断和治疗困难，本研究的目的是评价双气囊小肠镜在小肠疾病诊治中的价值。

方法：分析2004年7月至2017年4月2806例患者双气囊小肠镜检查及治疗的临床资料，不明原因的消化道出血562例、腹泻457例、腹痛930例、消瘦795例、小肠梗阻62例。进镜方式分为经口及经肛两种，根据临床症状及影像学检查结果决定首选进镜方式（经口/经肛），经一侧检查后未发现病灶者，对疾病诊断不明确的病例择期改换另一侧进镜方式再行检查。小肠息肉84例，小肠粪石并发肠梗阻26例，小肠Dieulafoy病出血18例，分别采用内镜下息肉切除术、内镜下碎石术、内镜下止血术治疗。

结果：2806例患者接受双气囊小肠镜检查，所有患者未出现严重不良反应及并发症，耐受性尚好。212例患者接受双侧进镜，有阳性发现1696例，病变检出率为60.4%；对不明原因消化道出血患者病变检出率为85.9%（483/562）；对不明原因腹泻的病变检出率为73.5%（336/457）；对不明原因腹痛的检出率较低为48.2%（448/930）；对不明原因消瘦的检出率为49.1%（390/795）；对小肠梗阻的病变检出率为62.9%（39/62）。小肠息肉行内镜下切除后未发生消化道出血、穿孔等并发症；小肠粪石并发肠梗阻经内镜下碎石后肠梗阻解除；18例小肠Dieulafoy病出血行内镜下止血治疗后14例出血停止。

结论：双气囊小肠镜对小肠疾病的诊治有重要价值。