

Contents lists available at [ScienceDirect](https://www.sciencedirect.com)

International Journal of Surgery Case Reports

journal homepage: www.casereports.com

Modified Eden-Lange procedure for iatrogenic lateral scapular winging

Renaldi Prasetia*, Wendy Yolanda Rosa, Raden Andri Primadhi, Hermawan Nagar Rasyid

Department of Orthopaedics- Traumatology, Faculty of Medicine, University Padjajaran, Hasan Sadikin General Hospital, Bandung, Indonesia

ARTICLE INFO

Article history:

Received 10 September 2020

Accepted 17 October 2020

Available online 28 October 2020

Keywords:

Winging scapular
Eden-Lange procedure
Trapezius palsy
Shoulder pain

ABSTRACT

INTRODUCTION: Lateral winging scapula is rare and generated by the trapezius paralysis. It is most likely iatrogenic from procedures involving the posterior cervical triangle. The modified Eden-Lange procedures one of the options by restoring the major actions of a flaccid trapezius. This case report aims to evaluate the outcomes.

CASE REPORT: A 34-year-old female came with right lateral scapular winging after radical neck tumor dissection and miss diagnosed by another hospital and underwent shoulder surgery. We performed a physical examination and showed lateral winging scapula. The best management therapy for this patient used modified Eden-Lange procedure.

DISCUSSION: Conservative treatments for Lateral scapular winging caused by spinal accessory nerve injury might be successful in early 20 months. However, our patient was injured 26 months before surgery which made Eden-Lange Procedures was the best choice for the patient. Modifications to this procedure allowed her to achieve excellent results.

CONCLUSION: Correction of the lateral scapular winging by modified Eden-Lange procedure combined with physical therapy for patient's trapezius palsy to gain adequate stability for daily activities.

© 2020 The Authors. Published by Elsevier Ltd on behalf of IJS Publishing Group Ltd. This is an open access article under the CC BY-NC-ND license (<http://creativecommons.org/licenses/by-nc-nd/4.0/>).

1. Introduction

Scapular winging can be a painful and impairing condition. It has been categorized anatomically as medial or lateral winging. Lateral winging is rare and generated by the trapezius and rhomboid paralysis. It usually caused by spinal accessory nerve injury and may result in pain, drooping of the shoulder, and an asymmetric neckline with the prominence of the scapula and diminished trapezial muscle girth. Lateral winging is most likely iatrogenic from procedures involving the posterior cervical triangle. The reported prevalence of scapular winging is unexpectedly limited. The diagnosis is difficult and maybe commonly missed as a result of the examining physician's failure to remove the patient's garments and inspect the back during an examination. Due to the limited number of published cases have made their treatment still controversial [1–4].

Non-surgical management may resolve most of the cases. When conservative treatments are unsuccessful, or for some cases, while there is a loss of accessory nerve function, surgical intervention is often considered. Some surgical options exist for the management of lateral winging scapular, which includes neurolysis, primary nerve anastomosis, cable graft, and the Eden-Lange procedure.

Neurolysis, nerve repair, and nerve grafting/reconstruction are typically performed within the first 20 months of the injury [1,5,6].

The surgical treatment for lateral scapular winging caused by trapezius palsy more than 20 months is the Eden-Lange procedure [7]. This procedure modified by *Bigliani* and his team includes the transfer of the levator scapulae muscle laterally to the scapular spine, and lateral transfer of the rhomboid minor and major muscles to the supraspinatus and infraspinatus fossae, respectively. This article review aims to evaluate reported outcomes for patients undergoing modified Eden-Lange surgical treatments, to describe the surgical indications, the efficacy of the available interventions, as well as complication and revision rates [1,8].

2. Case report

A 34-year-old female, right-handed dominant, presented to our Orthopaedic Clinic department. She came with the chief complaint of right shoulder pain, and difficulty in raising her arm. The patient's surgical history was a benign neck tumor 26 months ago and underwent radical neck tumor dissection. A month afterwards, the patient complaint commenced. The further patient complaint is a sense of pinched on her shoulder blades (scapula) and couldn't lift an object over chest level. In the attended year, this condition began to worsen with some activities of daily living including the inability to sleep on the affected side, wash her back, lift anything on her shoulder, reach high to a shelf, throw a ball, or participate in sports.

* Corresponding author.
E-mail address: renaldi@unpad.ac.id (R. Prasetia).

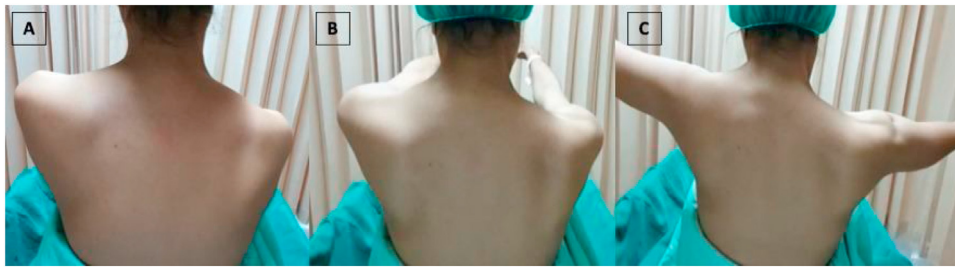

Fig. 1. (A) Asymmetric neckline with the prominence of the scapula. (B) Right shoulder flexion was 160/180 (C) Right shoulder abduction was 130/180.

The patient managed the symptoms by going to another hospital and underwent shoulder surgery. The patient was also going some isometric exercises at home, as taught by her primary care physician. However, the patient’s shoulder became more problematic, and her pain was so great that she had to make a constant effort to position her shoulder to prevent the illness. The patient also said that she feels the numbness of the right shoulder through the back, drooping of her right shoulder, and an asymmetric neckline with the prominence of the scapula. She had never participated into a formal physical therapy program for these symptoms, which is now, set down to worsening of her underlying symptoms and the pain by what she described as the relatively more recent “Lateral winging of the scapula”.

So, we performed physical examination to this patient, and it showed us there were prominent rhomboids, but the trapezius was flaccid. The lateral scapular winging resulted by apparent trapezius palsy as would be expected with this condition.

There was pain on the right shoulder, asymmetric neckline with the prominence of the scapula. Right shoulder abduction was 130/180, and flexion was 160/180, but the patient showed pain, very difficult to do and guard for the manoeuvre (Fig. 1). The otherwise left shoulder had full range of motion. Muscle testing with manual manoeuvre showed 5 of 5 strength in all planes of shoulder motion, and the deltoid strength was also normal. The Beighton scale scored of the patient was 0 of 9, suggesting there is no generalized joint hyperlaxity. Radiographic examination showed there is no abnormalities of the shoulder and glenohumeral joint with lateral subluxation of the right scapulae. Electromyography confirmed the presence of low amplitude and no evidence of trapezius innervation caused by right spinal accessory nerve injury.

The management therapy for this patient used soft tissue approach to correct the lateral scapular winging with surgery and then institute a physical therapy program. Therefore, to restore the dynamic actions of the trapezius, the author performed a modified Eden-Lange procedure [9]. (Fig. 2). The patient went under general anaesthesia and in the position of left lateral decubitus with the head elevated. The first incision was made along the length of the medial border of the scapula. The rhomboid major and minor muscles were identified and transferred to the infraspinous and supraspinous fossae, separately. Part of the bone was taken and transferred to the scapula. The second incision was made parallelly over the middle portion of the scapular spine for the transfer of the levator scapulae muscle to the middle of the scapular spine (Fig. 3).

Postoperative management to this patient was a sling and swathed with an abduction pillow for 6 weeks. At 3 weeks after surgery, the patient started the exercise with physical therapy that emphasized glenohumeral strengthening in addition to periscapular muscle strengthening (Fig. 4). At this moment, the patient has improvement her daily activity with the pain reduces with VAS from 8 to 5 (Table 1), and the shoulder can abduction in 160/180 and flexion in 180/180.

At final follow-up at six months after surgery, the patient’s scapular winging was eliminated, and her shoulder was now stable

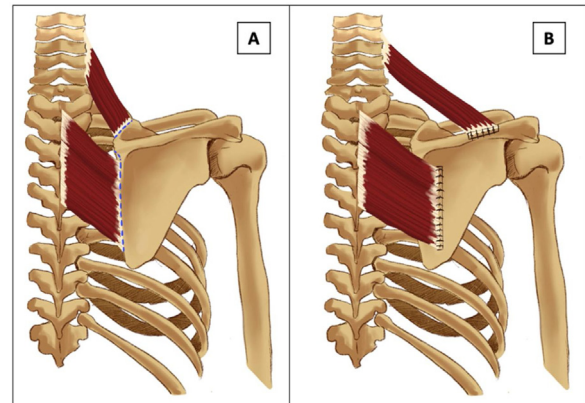


Fig. 2. Modified Eden-lange Procedure (A). The rhomboid and levator scapulae muscles were identified. (B) The transfer of the levator scapulae muscle to the middle of the scapular spine. Rhomboid major and minor muscles transferred to the infraspinous and supraspinous fossae.

Table 1
The preoperative and postoperative score of shoulder pain and function.

No.	Parameter	Preoperative	Postoperative			
			3 weeks	1 month	3 months	6 months
1	VAS Score	8	5	3	2	0
2	ASES Score	23	36.6	41.2	45.0	79.9

even though she had a sensation that it was permanently sitting more forward than before surgery. The patient was back to work as a tailor, where she detailed sawing without significant shoulder discomfort. She was able to lift something on her shoulder more effectively than before surgery. However, due to persistent pain with this motion, overhead throwing was avoided as much as possible. Even the patient admitted that she was very satisfied with this outcome of the treatment, results from postoperative pain and function questionnaires show residual pain and reduced function. The work has been reported in line with the SCARE 2018 criteria [10].

3. Discussion

Lateral scapular winging is usually caused by injury to the spinal accessory nerve, which is at risk of surgical neck dissections or trauma because it courses superficially through the posterior triangle of the neck. Surgical neck dissections are what happened to our patient, and it has been associated with spinal accessory nerve palsy. Football tackles, blunt trauma, stabbing, gunshot, and bite injury, also described as the cause of spinal accessory nerve injury and subsequent trapezius palsy [11,12].

Treatments for Lateral scapular winging caused by spinal accessory nerve injury, such as nerve exploration with neurolysis, direct nerve repair, or nerve grafting, might be successful in early 20

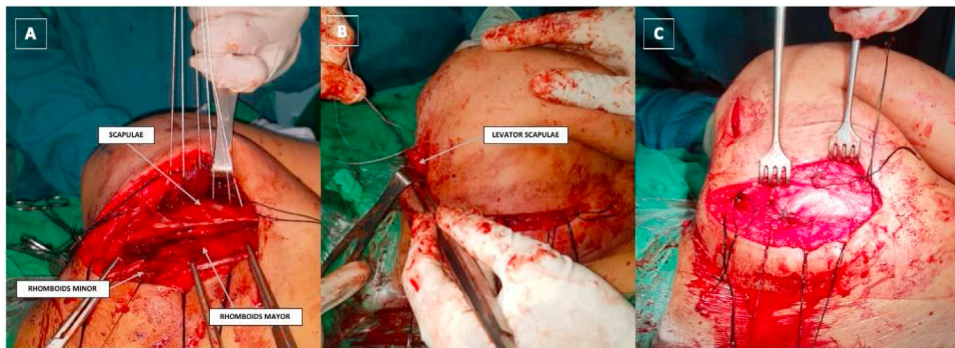


Fig. 3. Modified Eden-lange Procedure (A). The rhomboid major and minor muscles were transferred to the infraspinous and supraspinous fossae, separately, Part of the bone was taken and transferred to the scapula.(B) The transfer of the levator scapulae muscle to the middle of the scapular spine. (C) Rhomboid major and minor muscles transferred to the infraspinous and supraspinous fossae, the levator scapulae muscle to the middle of the scapular spine.

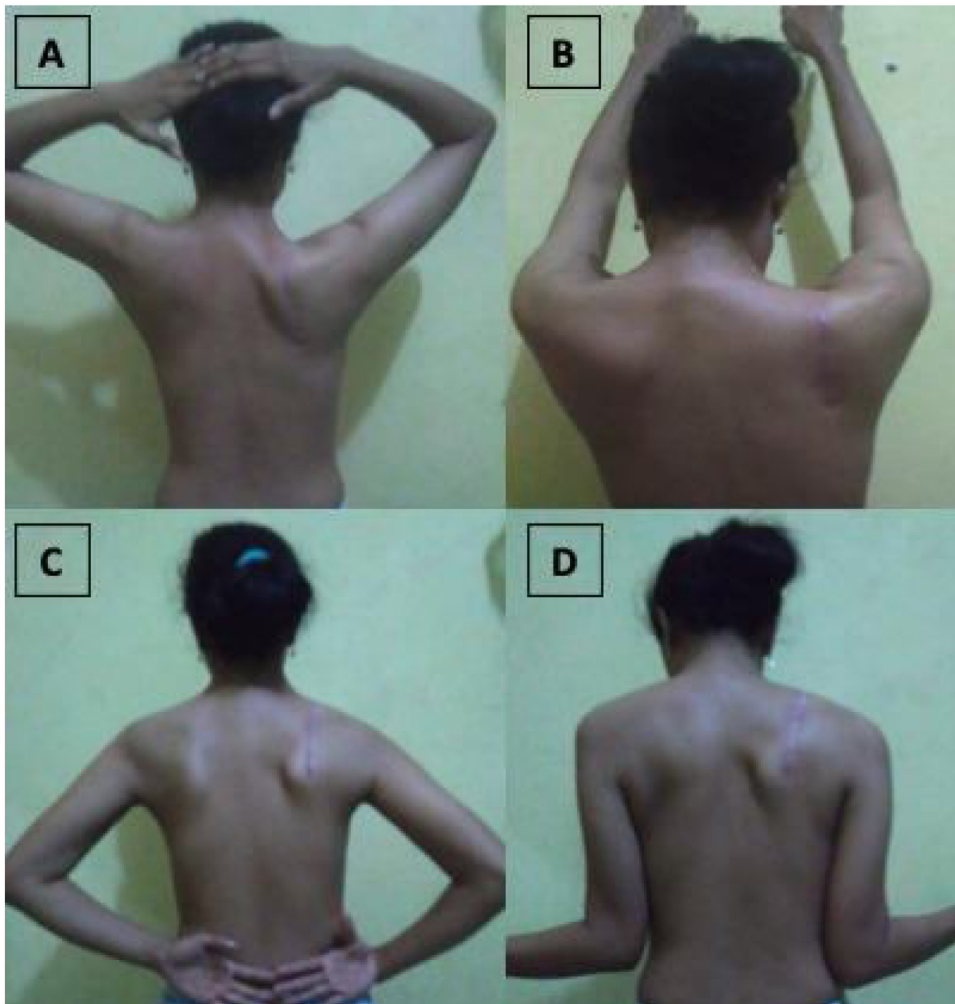

Fig. 4. A,B,C,D The patient Improvement motion in 3 weeks after surgery.

months [13]. However, our patient was injured 26 months before surgery, which made primary soft tissue repair was the right choice for this patient. Physical therapy and conservative treatment for spinal accessory nerve injuries more than 20 months have been shown to be unsuccessful because of the damaged nerve and inability to adequately strengthen adjacent muscle groups to compensate for the trapezius palsy. Therefore, the modified Eden-Lange procedure was chosen as the surgical treatment for our patient’s lateral scapular winging.

Modifications to this procedure by Bigliani and his team included the lateral transfer of the scapular levator muscle to the scapular spine and lateral displacement and the main lateral rhomboid to the supraspinous and infraspinous fossa, respectively. The modified and standard Eden-Lange procedure has been proven to successfully remove the scapular wing by restoring the main action of the trapezius muscle. From Amroodi et al., The results of the Eden-Lange procedure for a single incision in trapezius muscle paralysis from 11 patients increased from 32.8 to 82.1 points which

concluded with a single incision Eden-Lange procedure seems to be a safe and effective treatment option for patients with trapezius muscle paralysis [3,14].

This procedure allowed her to achieve excellent results in terms of pain relief, strength, and stability after a routine physical therapy program (Table 1). In this study, our patient's shoulder pain attributed to dysfunctional scapulothoracic kinematics and stability that were caused by trapezius palsy were significantly improved with the modified Eden-Lange procedure. Correction of the scapular winging allowed her to participate in physical therapy, which strengthened the shoulder muscles sufficiently to gain adequate stability for his daily activities and As a result, she no longer complained of shoulder instability, and improvement in terms of pain relief, stability, and strength were shown with the American Shoulder and Elbow Surgeons score (increasing from 36.6 to 79.9) and other outcome measures (Table 1) with no requirement for a stabilization procedure.

4. Conclusion

Correction of the lateral scapular winging by Eden-Lange procedure combined with physical therapy for her trapezius palsy, which strengthened the shoulder muscles sufficiently to gain adequate stability for daily activities.

Declaration of Competing Interest

The authors report no declarations of interest.

Funding

The authors declare that sponsors had no such involvement.

Ethical approval

The patient received an explanation of the procedures and possible risks of the surgery, and gave written informed consent.

Ethical approval has been granted in this study

Consent

The patient received an explanation of the procedures and possible risks of the surgery, and gave written informed consent.

Authors contribution

Renaldi Prasetia (RP) contributed to perform the operation, to collect, to analyze data, to revise the manuscript and to approve for publishing.

Wendy Yolanda (WY) contributed to perform the operation, to collect, to analyze data, to draft manuscript, to create illustration and to approve for publishing. Raden Andri Primadhi (RAP) contributed to perform the operation, to collect, to analyze data, to draft manuscript, to create illustration and to approve for publishing. Hermawan Nagar Rasyid (HNR) contributed to perform the operation, to collect, to analyze data, to draft manuscript, to create illustration and to approve for publishing.

Open Access

This article is published Open Access at [sciencedirect.com](https://www.sciencedirect.com). It is distributed under the [IJSCR Supplemental terms and conditions](#), which permits unrestricted non commercial use, distribution, and reproduction in any medium, provided the original authors and source are credited.

Registration of research studies

Research Registry

UIN : researchregistry2780

[researchregistry.com/register-now#home/registrationdetails/596d67f6543f1860a177c272/](https://www.researchregistry.com/register-now#home/registrationdetails/596d67f6543f1860a177c272/)

Guarantor

Guarantor in this study is Renaldi Prasetia (RP).

Provenance and peer review

Not commissioned, externally peer-reviewed.

Acknowledgement

The authors would like to thank all parties that support on making this manuscript, and author would thank to the patient that already gave her consent for publication of this case report.

References

- [1] R.S. Elsayi, S.Y. Vancolen, N.S. Horner, M. Khan, B. Alolabi, Surgical treatment of trapezius palsy: a systematic review, *Shoulder Elb.* 12 (2020) 153–162.
- [2] A.L. Cabrera, K.D. Plancher, S.C. Petterson, J.E. Kuhn, Treatment for medial and lateral scapular winging: tendon transfers, *Oper. Tech. Sports Med.* 22 (2014) 97–107.
- [3] M.N. Amroodi, M. Salariyeh, Single-incision Eden-Lange procedure in trapezius muscle paralysis: a report of 11 cases, *Acta Orthop. Traumatol. Turc.* 52 (2018) 115–119.
- [4] S.B. Park, J.L. Ramage, Winging of the Scapula, in: StatPearls [Internet], StatPearls Publishing, 2019.
- [5] S. Lee, D.D. Savin, N.R. Shah, D. Bronsnick, B. Goldberg, Scapular winging: evaluation and treatment: AAOS exhibit selection, *J. Bone Jt. Surg. - Am. Vol.* 97 (2015) 1708–1716.
- [6] J.T. Didesch, P. Tang, Anatomy, Etiology, and Management of Scapular Winging, *J. Hand Surg.* 44 (2019) 321–330.
- [7] W.R. Frontera, J.A. DeLisa, DeLisa's Physical Medicine & Rehabilitation: Principles and Practice, 5th ed., Wolters Kluwer/Lippincott Williams & Wilkins Health, Philadelphia, 2010.
- [8] J.G. Skedros, C.J. Kiser, Modified eden-lange procedure for trapezius paralysis with ipsilateral rotator cuff-tear arthropathy, *J. Bone Jt. Surg. [Am.]* 93 (2011), e131(1)-e131(5).
- [9] Bassem Elhassan, Eric Wagner, Outcome of triple-tendon transfer, an Eden-Lange variant, to reconstruct trapezius paralysis, *J. Shoulder Elbow Surg.* 24 (8) (2015), <http://dx.doi.org/10.1016/j.jse.2015.01.008>.
- [10] R.A. Agha, M.R. Borrelli, R. Farwana, K. Koshy, A.J. Fowler, D.P. Orgill, The SCARE 2018 statement: updating consensus Surgical CAse REport (SCARE) guidelines, *Int. J. Surg.* 60 (2018) 132–136, <http://dx.doi.org/10.1016/j.ijsu.2018.10.028>.
- [11] M. Vetter, O. Charran, E. Yilmaz, B. Edwards, M.A. Muhleman, R.J. Oskouian, R.S. Tubbs, M. Loukas, Winged scapula: a comprehensive review of surgical treatment, *Cureus.* 9 (2017), <http://dx.doi.org/10.7759/cureus.1923>.
- [12] R.M. Martin, A.D.E. Fish, *Scapular Winging: Anatomical Review, Diagnosis, and Treatments*, 2008, pp. 1–11.
- [13] N. Maire, L. Abane, J. Kempf, P. Clavert, E. Sofec, Long thoracic nerve release for scapular winging: clinical study of a continuous series of eight patients, *Orthop. Traumatol. Surg. Res.* 99 (2013) S329–S335.
- [14] J.G. Skedros, A.N. Knight, Treatment of scapular winging with modified Eden-Lange procedure in patient with pre-existing glenohumeral instability, *J. Shoulder Elb. Surg.* 21 (2012) e10–e13, <http://dx.doi.org/10.1016/j.jse.2011.11.037>.