


## Dissociation of the subjective and objective bodies: Out-of-body experiences following the development of a posterior cingulate lesion

Kentaro Hiromitsu<sup>1,2\*</sup> , Nobusada Shinoura<sup>3</sup>, Ryoji Yamada<sup>3</sup> and Akira Midorikawa<sup>4</sup> 

<sup>1</sup>Department of Psychology, Graduate School of Humanities and Sociology, The University of Tokyo, Japan

<sup>2</sup>Institute of Cultural Sciences, Chuo University, Tokyo, Japan

<sup>3</sup>Department of Neurosurgery, Tokyo Metropolitan Cancer and Infectious Diseases Center Komagome Hospital, Tokyo, Japan

<sup>4</sup>Department of Psychology, Faculty of Letters, Chuo University, Tokyo, Japan

An out-of-body experience (OBE) is a phenomenon whereby an individual views his/her body and the world from a location outside the physical body. Previous studies have suggested that the temporoparietal junction (TPJ), the brain region responsible for integrating multisensory signals, is responsible for OBE development. Here, however, we first present a case of OBE after brain tumour development in the posterior cingulate cortex (PCC). The patient was a 46-year-old right-handed female; she underwent brain surgery. She reported that she had experienced OBEs several times monthly (during daily life) before surgery but never after surgery. She defined her OBEs explicitly; she drew pictures. Her OBEs exhibited phenomenological, overt dissociation of the subjective and objective bodies. We discuss the mechanisms underlying this phenomenon and the relationship between OBEs and the PCC in terms of anatomical and functional brain connectivity. Our case sheds some light on the mechanism involved in creating spatial (dis)unity between the self and the body.

The self is typically perceived as localized within the bodily boundary or even as the body *per se* (Merleau-Ponty, 1945/2012). However, neurological patients reporting out-of-body experiences (OBEs) have revealed that self-alterations associated with disembodiment reflect disruption of the spatial unity between the self and the body. An OBE occurs when an individual seems to view his/her body and the world from a location outside the physical body (Blanke, Landis, Spinelli, & Seeck, 2004; Devinsky, Feldmann, Burrowes, & Bromfield, 1989). The core feature of an OBE is the feeling of spatial separation of the self and body (Brugger, 2002). An OBE may be followed by a floating or flying sensation with elevation of the disembodied perspective. The current view suggests that transient

---

This is an open access article under the terms of the Creative Commons Attribution-NonCommercial-NoDerivs License, which permits use and distribution in any medium, provided the original work is properly cited, the use is non-commercial and no modifications or adaptations are made.

\*Correspondence should be addressed to Kentaro Hiromitsu, 1130033, 7-3-1, Hongo, Bunkyo-ku, Tokyo, Japan (email: mitsuhiromitsu@gmail.com).

abnormal integration of visual, somatosensory and vestibular signals explains the disembodiment (Lopez & Elzière, 2018). Although OBEs may exhibit various aetiologies (e.g., psychiatric diseases, migraine or sleep paralysis), few neurological patients with OBEs caused by brain damage have been reported (Blanke *et al.*, 2004; Blanke, Ortigue, Landis, & Seeck, 2002; Bos, Spoor, Smits, Schouten, & Vincent, 2016; Brandt, Kramme, Storm, & Pohlmann-Eden, 2009; Brugger, REGARD, & Landis, 1997; Daly, 1958; De Ridder, Van Laere, Dupont, Menovsky, & Van de Heyning, 2007; Devinsky *et al.*, 1989; Greyson, Fountain, Derr, & Broshek, 2014; Lunn, 1970; Maillard, Vignal, Anxionnat, Taillandier, & Vespignani, 2004; Yu *et al.*, 2018). In terms of the neural basis of OBEs, almost all cases exhibit involvement of the temporoparietal junction (TPJ), as revealed by electrical stimulation and lesional studies (Blanke *et al.*, 2004; Bos *et al.*, 2016; Maillard *et al.*, 2004). One study featuring voxel-based lesional symptom mapping of focal brain damage triggering OBEs revealed that the maximal lesional overlap was in the TPJ, including the right angular and posterior superior temporal gyri (Ionta *et al.*, 2011). The TPJ integrates multisensory signals (visual, somatosensory and vestibular), contributing to the maintenance of an embodied sense of self (i.e., a sense of spatial unity between the self and the body; Blanke, 2012). However, some studies have suggested that additional brain regions contribute to OBEs. Here, we present the first case of a patient with a posterior cingulate lesion and OBEs and discuss whether OBEs might involve the posterior cingulate cortex (PCC).

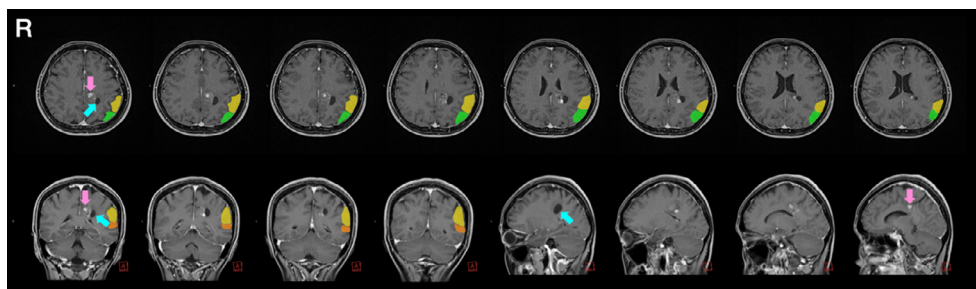
## Case report

### Medical history

Our patient was a 46-year-old right-handed female. After graduating from university, she worked at a trading company for 9 years, and then became a homemaker. In October 2014, she suffered from memory problems, recurrent migraine headaches, vertigo and transient (1 min) anarthria. She consulted a local hospital; magnetic resonance imaging (MRI) revealed brain tumours, primarily in the left medial parietal lobe and PCC (Figure 1). She was admitted to our hospital and underwent awake craniotomy to remove the tumours in December 2014. The final diagnosis was a ganglioglioma (WHO grade I; Louis *et al.*, 2016). The results of the neuropsychological examinations performed before and after surgery are presented in Table 1. The memory test (WMS-R) revealed deterioration of the patient's memory before surgery, but this was ameliorated after surgery (Table 1), which is consistent with previous findings showing the relevance of the PCC to memory deficits (Hayashi *et al.*, 2018; Weaver *et al.*, 2015). Neurological assessment revealed that the contralesional (right) side exhibited somatosensory weakness prior to surgery. Related to the contralesional somatosensory deficit, she reported an experience of touch-colour synaesthesia. Before surgery, when she was stimulated on the contralesional side of the body, where the tactile sensation was weaker than that on the ipsilesional side, she experienced a white colour; when stimulated on the ipsilesional side the body, where the tactile sensation was stronger than that on the contralesional side, she perceived an orange colour. During and after surgery, both the somatosensory deficits and the touch-colour synaesthesia disappeared.

### Out-of-body experiences

The patient reported that she experienced OBEs on several occasions in October and November 2014. In early October, she had suffered from frequent headaches, and, when



**Figure 1.** T1-weighted magnetic resonance imaging before surgery in the axial (upper row), coronal and sagittal (lower row) planes reveals the tumour (red arrows) and the cyst (blue arrows) in the left medial parietal lobe. The lesion includes the posterior cingulate cortex (PCC). To visually distinguish the PCC (location of the present patient's lesion) from the temporoparietal junction (TPJ) (region considered responsible for out-of-body experiences), the inferior parietal lobule: supramarginal gyrus (yellow-coloured area) and angular gyrus (green-coloured area), and the superior temporal gyrus (orange-coloured area) are shown; the TPJ is not an anatomical entity but a functional one comprising the region of the cerebral cortex that lies along the boundary of the inferior parietal lobule (supramarginal and angular gyri) and the posterior part of the superior temporal gyrus (Schurz, Tholen, Perner, Mars, & Sallet, 2017). 'R': right side of the head.

sleeping at night, heard low notes such as those made by a male baritone singer. She interpreted the notes as music because they lay on a musical scale. Thereafter, she experienced OBEs several times a month during daily life. Her OBEs occurred indoors, for instance, she experienced OBEs when she was cooking in the kitchen. She had never experienced OBEs before, and they disappeared after surgery. She remembered the OBEs in detail, and the experience was so vivid that she drew pictures (Figure 2). We interviewed her carefully; we report our findings below:

1. She viewed her body from above and 1–1.5 m behind the physical body (the parasomatic body is shown on the left of Figure 2a).
2. Other than below the feet, she could view all parts of her physical body from behind.
3. She felt that the parasomatic body was larger than the physical body.
4. The parasomatic body could not move.
5. Although she recognized her own body from behind, as revealed by the statement: 'I can see myself moving' in Figure 2b, she also recognized the parasomatic body as herself (as depicted by the oblique line with the descriptors 'real form', 'myself' and 'myself who is thinking') (Figure 2b).

## Discussion

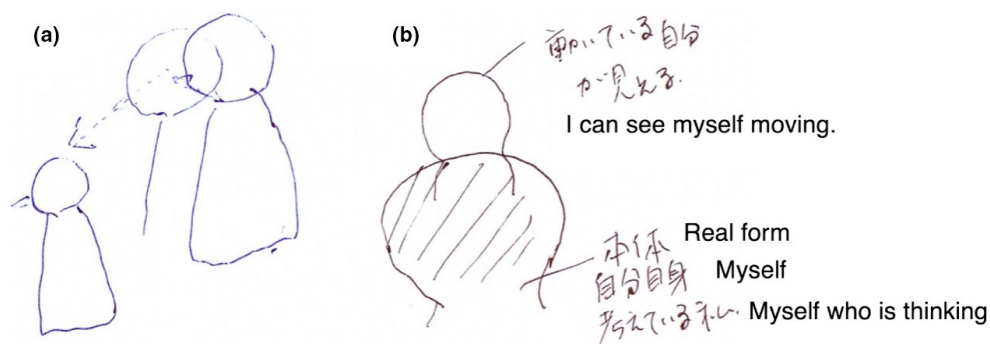
We describe a patient who experienced OBEs after the development of a PCC lesion. Her OBE reports were phenomenologically extremely detailed; they allow us to discuss a possible origin of OBEs in terms of PCC function. Commencing with the phenomenology, the patient first heard low musical notes made by a male during sleep. This is an auditory hallucination that often accompanies OBEs (Brandt *et al.*, 2009): hearing a 'presence', that is an auditory manifestation characterized by the impression of the physical presence of another (Blanke *et al.*, 2003). Description (1) above shows that the patient experienced a parasomatic body that was elevated above the 'real' body; this is both a common and a

**Table 1.** Neuropsychological profile

	Before surgery	After surgery	Maximum score
General intelligence			
MMSE	30	–	/30
RCPM	31	36	/36
Executive function			
FAB	17	17	/18
Memory			
Digit forward	9	8	–
Digit backward	5	5	–
Verbal memory <sup>a</sup>	9-10-	10- -	/10-10-10
Visual memory (immediate recall) <sup>b</sup>	5	6	/7
Visual memory (recognition) <sup>b</sup>	15	15	/15
RBMT			
Profile score	23	20	/24
Screening score	11	10	/12
WMS-R			
Verbal memory index	80	112	
Visual memory index	98	106	
General memory index	83	112	
Attention/concentration index	115	101	
Delayed recall index	81	94	
Language			
Verbal fluency	22	18	–
Naming	19	19	/20
Repetition	5	5	/5
Auditory comprehension	10	10	/10
Visuospatial function			
ROCFT (copy, immediate recall, delayed recall)	34- 31- 30	36- 30- 28	/36
Necker cube (copy)	9	7	/10
Line bisection test	–2%, 0.6%, –0.6%	0.9%, 1%, 1%	Positive values indicate leftward bias
COGNISTAT			
Orientation	10	–	/10
Attention			
Comprehension	10	–	/10
Repetition	11	–	/11
Naming	10	–	/10
Construction	11	–	/11
Memory	10	–	/10
Calculation	10	–	/10
Similarities	10	–	/11
Judgment	11	–	/12

Note. COGNISTAT = Neurobehavioral Cognitive Status Examination; FAB = Frontal Assessment Battery; MMSE = Mini-Mental State Examination; RBMT = Rivermead Behavioural Memory Test; RCPM = Raven's Coloured Progressive Matrices; ROCFT = Rey–Osterrieth's Complex Figure Test; WMS-R = Wechsler Memory Scale Revised.

<sup>a</sup>Miyake paired verbal association learning test.; <sup>b</sup>Randt memory test.



**Figure 2.** Drawings of the out-of-body experiences. The patient depicted the parasomatic body as the conscious self (the shaded portion); she watched the physical body moving (a). The patient depicted the parasomatic body as larger than the physical body; she saw the physical body below her and to the front (b). [Color figure can be viewed at [wileyonlinelibrary.com](http://wileyonlinelibrary.com)]

characteristic feature of OBEs (Blanke *et al.*, 2004; Bos *et al.*, 2016). The elevated location reflects vestibular dysfunction caused by brain damage (Lopez & Elzière, 2018). The distance from the physical to the parasomatic body (1–1.5 m) implies that the OBE lay within the peripersonal space (di Pellegrino & Làdavas, 2015); this reflects the plasticity of the bodily boundary (Noel, Pfeiffer, Blanke, & Serino, 2015). Description (2) suggests the ambiguity of the visual appearance of the physical body, especially below her feet, as depicted in Figure 2a. This implies the possibility that the seen body could be a visual hallucination. Generally, others' feet cannot be seen from above and behind; she reported the invisibility of her physical body during the OBE similarly. Indeed, a previous case report revealed the presence of autoscopic hallucinations together with visual agnosia (Zamboni, Budriesi, Nichelli, Budriese, & Nichelli, 2005), suggesting that anomalous visual processing is involved in this phenomenon. Description (3) indicates that the parasomatic body was larger than the physical body. This suggests macrosomatognosia-like symptoms, a condition in which individuals perceive themselves as abnormally large (Frederiks, 1963). Macrosomatognosia exhibits several aetiologies, including migraine, epilepsy and stroke (Podoll & Robinson, 2000; Weijers, Rietveld, Meijer, & De Leeuw, 2013). In terms of the neural mechanism involved, an earlier neuroimaging study suggested that body size perception involves the postcentral and intraparietal sulci (Ehrsson, Kito, Sadato, Passingham, & Naito, 2005). Thus, it is possible that damage to the parietal lobe in our patient may have elicited macrosomatognosia-like symptoms. The spatial separation of the parasomatic and physical bodies suggests that she felt that she (i.e. the parasomatic body) was not confined within the 'conventional' spatial coordinates of the physical body because she observed her own physical body outside of it. An ambiguous boundary between the parasomatic body and the environment induced by the feeling of detachment from the physical body may be related to the sense of elevated location and macrosomatognosia-like symptoms.

Description (4) indicates motor dysfunction of the physical body. The novel features of OBEs are evident. Although OBEs are commonly accompanied by floating or flying sensations (considered to reflect anomalous vestibular sensations; Blanke *et al.*, 2004; Lopez & Elzière, 2018), our patient reported that she (the parasomatic body) could not move, whereas the physical body could. She did not report any subjective, anomalous vestibular sensation such as floating or flying. This indicates that OBEs do not necessarily include such sensations. In fact, the patient did not exhibit continuous vestibular

dysfunction, although she suffered from vertigo at symptom onset. Furthermore, a focus on the functional difference between the parasomatic and physical bodies reveals a difference in bodily representation. Description (4) implies that the body responsible for motor function is independent of the body charged with self-localization in space. The former corresponds to the concept of a body schema (i.e. a system of sensorimotor capacities; Gallagher, 2005), and the latter to the concept of body image, which is considered to be divided into preceptual (body structural description) and conceptual (body semantics) aspects of the body (de Vignemont, 2010; Schwoebel & Coslett, 2005). An earlier study showed that body schema and body image could be mutually dissociated (Paillard, 1999); it is possible that OBEs result from a separation of the concepts. Description (5) features self-location in terms of the perceived bodily position in space (Maselli, 2015). The patient recognized the physical body in front of and below her as herself, and she simultaneously accepted the parasomatic body as herself. This is a prototypical feature of OBEs (Blanke *et al.*, 2004; Devinsky *et al.*, 1989). More interestingly, she described the parasomatic body as her 'real form' (a type of bodily representation), but also described the parasomatic body both abstractly and conceptually as 'myself who is thinking'. The patient clearly differentiated the observing body (a subject) from the observed body (an object), indicating that the body potentially has both subjective and objective aspects. Based on these descriptions, the semantic and conceptual aspects of the conscious self seemed to be located in disembodied (i.e. empty) space. However, this does not reflect a Cartesian dualism, but rather indicates that the visual perspective is independent of the physical body that is accompanied by sensorimotor function. When we perceive the external world, we can adopt different perspectives depending on the bodily boundary. For example, we can imagine and understand how others perceive the world spatially and psychologically from their perspectives; this is termed the 'theory of mind' (Aichhorn, Perner, Kronbichler, Staffen, & Ladurner, 2006), 'mentalizing' (Amodio & Frith, 2006) or 'perspective taking' (Vogeley & Fink, 2003). Many studies have found that a disembodied perspective is a useful biological function, allowing us to know how to perceive the world (Arnold, Spence, & Auvray, 2017) and interact with others (Frith, 1999). However, those experiencing OBEs perform worse than others on tasks requiring adoption of a disembodied perspective towards an avatar (Blanke *et al.*, 2005; Braithwaite, Samson, Apperly, Brogna, & Hulleman, 2011), suggesting that the anomalous nature of the disembodied perspective is linked to the OBE mechanism. Indeed, an earlier neuroimaging study suggested that adoption of a disembodied perspective reflects TPJ activation (Schurz, Aichhorn, Martin, & Perner, 2013); the TPJ is the brain region considered responsible for OBEs (Blanke & Arzy, 2005). Moreover, a previous report found that self-location involving a visual first-person perspective reflected TPJ activity (Ionta *et al.*, 2011), suggesting that one's visual perspective was associated with a sense of being localized in space. This interpretation can be applied to our case. Experiencing the parasomatic body with a sensation of disembodiment makes it impossible to apply a normal perspective (Blanke *et al.*, 2005; Braithwaite *et al.*, 2011).

Next, we turn to the possible neural mechanism underlying OBEs in terms of PCC function. To the best of our knowledge, this is the first report of OBEs in a patient with a PCC lesion. Previous neuroimaging studies on OBEs of both healthy and neurologically compromised individuals found that the TPJ contributed to the convergence of multisensory signals (Blanke *et al.*, 2004; Bos *et al.*, 2016; De Ridder *et al.*, 2007). However, as the role played by the PCC in OBEs remains unknown, the topic should be discussed. An earlier study suggested that patients with PCC lesions exhibited impaired

spatial orientation (termed ‘topological disorientation’; Katayama, Takahashi, Ogawara, & Hattori, 1999; Takahashi, Kawamura, Shiota, Kasahata, & Hirayama, 1997). This seems to share a phenomenological basis with the difficulty in localizing the self in space associated with a PCC lesion. Furthermore, in the resting brain, the PCC is functionally connected to the TPJ (Mars *et al.*, 2012); the PCC and TPJ both lie in the posterior region of the default-mode network (one of the central resting brain networks; Zhang *et al.*, 2017). Anatomically, the PCC projects to the macaque homologue of the inferior parietal lobule and the superior temporal sulcus, both of which are TPJ regions (Parvizi, Van Hoesen, Buckwalter, & Damasio, 2006). Given this PCC/TPJ connectivity, it is possible that within-body multisensory integration, which is mediated in the TPJ (Blanke & Arzy, 2005), was impaired by the PCC lesion in our patient. Indeed, the patient showed transient touch-colour synaesthesia (Steven & Blakemore, 2004), suggesting that the aberrant multisensory processing was mediated in the TPJ, as this symptom has been characterized as a failure of inhibition in mutual connection between the somatosensory cortex and TPJ, which mediates the perception of colour (Horiguchi, Wandell, & Winawer, 2016). Importantly, neuroimaging research on out-of-body illusions suggested that the PCC engages in self-location in space (Guterstam, Björnsdotter, Gentile, & Ehrsson, 2015). In the cited work, the self-location illusion was induced from the perspective of the body of a stranger, suggesting that self-location by reference to personal visual perspective reflects PCC activity. The evidence we present above explains the OBEs of our patient in terms of anomalous self-location in space by the PCC.

Finally, we raise the question of why there are no previous reports of OBEs developing after PCC lesions. It is possible that the anatomical connections between the PCC and TPJ are so robust that OBEs are rarely induced by such lesions. As maintenance by the TPJ of spatial unity between the self and the body is crucial in terms of human self-consciousness, the neural connection from the TPJ to various other regions may indeed be very strong. Furthermore, it may be that some subpopulations are OBE-prone (Nakul & Lopez, 2017). Not only brain damage, but also psychological dysfunctions such as depersonalization/derealization may precipitate OBEs. In future, simultaneous evaluation of the neurological and psychological aspects of OBEs will allow us to better understand OBEs.

In summary, we first present a case in whom OBEs developed after a PCC lesion. The case suggests that the PCC contributes to self-location depending on the visual perspective; this is in line with prior patient and neuroimaging findings and sheds some light on the mechanism involved in creating spatial (dis)unity between the self and the body.

## Acknowledgements

This study was supported by JSPS KAKENHI (16H01517, 18H03663) and Topic-Setting Program to Advance Cutting-Edge Humanities and Social Sciences Research, JSPS.

## Conflicts of interest

All authors declare no conflict of interest.

## Author contributions

Kentaro Hiromitsu: Conceptualization, Data curation, Formal analysis, Investigation, Methodology, Validation, Visualization, Writing - original draft, Writing - review &

editing; Nobusada Shinoura: Data curation, Investigation, Project administration, Resources, Writing – review & editing; Ryoji Yamada: Data curation, Investigation, Resources, Writing – review & editing; Akira Midorikawa: Data curation, Funding acquisition, Methodology, Supervision, Writing – review & editing.

## Data availability statement

The data that support the findings of this study are available on request from the corresponding author. The data are not publicly available due to privacy or ethical restrictions.

## References

- Aichhorn, M., Perner, J., Kronbichler, M., Staffen, W., & Ladurner, G. (2006). Do visual perspective tasks need theory of mind? *NeuroImage*, *30*(3), 1059–1068. <https://doi.org/10.1016/j.neuroimage.2005.10.026>
- Amodio, D. M., & Frith, C. D. (2006). Meeting of minds: The medial frontal cortex and social cognition. *Nature Reviews Neuroscience*, *7*(4), 268–277. <https://doi.org/10.1038/nrn1884>
- Arnold, G., Spence, C., & Auvray, M. (2017). A unity of the self or a multiplicity of locations? How the graphesthesia task sheds light on the role of spatial perspectives in bodily self-consciousness. *Consciousness and Cognition*, *56*, 100–114. <https://doi.org/10.1016/j.concog.2017.06.012>
- Blanke, O. (2012). Multisensory brain mechanisms of bodily self-consciousness. *Nature Reviews Neuroscience*, *13*, 556–571. <https://doi.org/10.1038/nrn3292>
- Blanke, O., & Arzy, S. (2005). The out-of-body experience: Disturbed self-processing at the temporo-parietal junction. *The Neuroscientist*, *11*(1), 16–24. <https://doi.org/10.1177/1073858404270885>
- Blanke, O., Landis, T., Spinelli, L., & Seeck, M. (2004). Out-of-body experience and autoscopia of neurological origin. *Brain*, *127*(Pt 2), 243–258. <https://doi.org/10.1093/brain/awh040>
- Blanke, O., Mohr, C., Michel, C. M., Pascual-Leone, A., Brugger, P., Seeck, M., . . . Thut, G. (2005). Linking out-of-body experience and self processing to mental own-body imagery at the temporoparietal junction. *The Journal of Neuroscience*, *25*(3), 550–557. <https://doi.org/10.1523/JNEUROSCI.2612-04.2005>
- Blanke, O., Ortigue, S., Coeytaux, A., Martory, M.-D., Landis, T., Blanke, O., . . . Landis, T. (2003). Hearing of a presence. *Neurocase*, *9*(4), 329–339. <https://doi.org/10.1076/neur.9.4.329.15552>
- Blanke, O., Ortigue, S., Landis, T., & Seeck, M. (2002). Stimulating illusory own-body perceptions. *Nature*, *419*(6904), 269–270. <https://doi.org/10.1038/419269a>
- Bos, E. M., Spoor, J. K. H., Smits, M., Schouten, J. W., & Vincent, A. J. P. E. (2016). Out-of-body experience during awake craniotomy. *World Neurosurgery*, *92*, 586.e9–586.e13. <https://doi.org/10.1016/j.wneu.2016.05.002>
- Braithwaite, J. J., Samson, D., Apperly, I., Brogna, E., & Hulleman, J. (2011). Cognitive correlates of the spontaneous out-of-body experience (OBE) in the psychologically normal population: Evidence for an increased role of temporal-lobe instability, body-distortion processing, and impairments in own-body transformations. *Cortex*, *47*(7), 839–853. <https://doi.org/10.1016/j.cortex.2010.05.002>
- Brandt, C., Kramme, C., Storm, H., & Pohlmann-Eden, B. (2009). Out-of-body experience and auditory and visual hallucinations in a patient with cardiogenic syncope: Crucial role of cardiac event recorder in establishing the diagnosis. *Epilepsy and Behavior*, *15*(2), 254–255. <https://doi.org/10.1016/j.yebeh.2009.02.047>
- Brugger, P. (2002). Reflective mirrors: Perspective-taking in autoscopic phenomena. *Cognitive Neuropsychiatry*, *7*(3), 179–194. <https://doi.org/10.1080/13546800244000076>
- Brugger, P., Regard, M., & Landis, T. (1997). Illusory reduplication of one's own body: Phenomenology and classification of autoscopic phenomena. *Cognitive Neuropsychiatry*, *2*(1), 19–38. <https://doi.org/10.1080/135468097396397>



- Daly, D. (1958). Ictal affect. *The American Journal of Psychiatry*, 115(2), 97–108. <https://doi.org/10.1176/ajp.115.2.97>
- De Ridder, D., Van Laere, K., Dupont, P., Menovsky, T., & Van de Heyning, P. (2007). Visualizing out-of-body experience in the brain. *New England Journal of Medicine*, 357(18), 1829–1833. <https://doi.org/10.1056/NEJMoa070010>
- de Vignemont, F. (2010). Body schema and body image—Pros and cons. *Neuropsychologia*, 48(3), 669–680. <https://doi.org/10.1016/j.neuropsychologia.2009.09.022>
- Devinsky, O., Feldmann, E., Burrowes, K., & Bromfield, E. (1989). Autoscopy phenomena with seizures. *Archives of Neurology*, 46(10), 1080–1088. <https://doi.org/10.1001/archneur.1989.00520460060015>
- di Pellegrino, G., & Làdavas, E. (2015). Peripersonal space in the brain. *Neuropsychologia*, 66, 126–133. <https://doi.org/10.1016/j.neuropsychologia.2014.11.011>
- Ehrsson, H. H., Kito, T., Sadato, N., Passingham, R. E., & Naito, E. (2005). Neural substrate of body size: Illusory feeling of shrinking of the waist. *PLoS Biology*, 3(12), 1–8. <https://doi.org/10.1371/journal.pbio.0030412>
- Frederiks, J. A. (1963). Macrosomatognosia and microsomatognosia. *Psychiatria, Neurologia, Neurochirurgia*, 66, 531–536.
- Frith, C. D. (1999). Interacting minds—A biological basis. *Science*, 286(5445), 1692–1695. <https://doi.org/10.1126/science.286.5445.1692>
- Gallagher, S. (2005). *How the body shapes the mind*. Oxford, UK: Oxford University Press. <https://doi.org/10.1093/0199271941.001.0001>
- Greyson, B., Fountain, N. B., Derr, L. L., & Broshek, D. K. (2014). Out-of-body experiences associated with seizures. *Frontiers in Human Neuroscience*, 8, 65. <https://doi.org/10.3389/fnhum.2014.00065>
- Guterstam, A., Björnsdotter, M., Gentile, G., & Ehrsson, H. H. (2015). Posterior cingulate cortex integrates the senses of self-location and body ownership. *Current Biology*, 25(11), 1416–1425. <https://doi.org/10.1016/j.cub.2015.03.059>
- Hayashi, S., Terada, S., Oshima, E., Sato, S., Kurisu, K., Takenoshita, S., . . . Yamada, N. (2018). Verbal or visual memory score and regional cerebral blood flow in Alzheimer disease. *Dementia and Geriatric Cognitive Disorders Extra*, 8(1), 1–11. <https://doi.org/10.1159/000486093>
- Horiguchi, H., Wandell, B. A., & Winawer, J. (2016). A predominantly visual subdivision of the right temporo-parietal junction (vTPJ). *Cerebral Cortex*, 26(2), 639–646. <https://doi.org/10.1093/cercor/bhu226>
- Ionta, S., Heydrich, L., Lenggenhager, B., Mouthon, M., Fornari, E., Chapuis, D., . . . Blanke, O. (2011). Multisensory mechanisms in temporo-parietal cortex support self-location and first-person perspective. *Neuron*, 70(2), 363–374. <https://doi.org/10.1016/j.neuron.2011.03.009>
- Katayama, K., Takahashi, N., Ogawara, K., & Hattori, T. (1999). Pure topographical disorientation due to right posterior cingulate lesion. *Cortex*, 35(2), 279–282. [https://doi.org/10.1016/S0010-9452\(08\)70801-3](https://doi.org/10.1016/S0010-9452(08)70801-3)
- Lopez, C., & Elzière, M. (2018). Out-of-body experience in vestibular disorders—A prospective study of 210 patients with dizziness. *Cortex*, 104, 193–206. <https://doi.org/10.1016/j.cortex.2017.05.026>
- Louis, D. N., Perry, A., Reifenberger, G., von Deimling, A., Figarella-Branger, D., Cavenee, W. K., . . . Ellison, D. W. (2016). The 2016 World Health Organization classification of tumors of the central nervous system: A summary. *Acta Neuropathologica*, 131(6), 803–820. <https://doi.org/10.1007/s00401-016-1545-1>
- Lunn, V. (1970). Autoscopy phenomena. *Acta Psychiatrica Scandinavica*, 46, 118–125. <https://doi.org/10.1111/j.1600-0447.1970.tb07987.x>
- Maillard, L., Vignal, J. P., Anxionnat, R., Taillandier, L., & Vespignani, H. (2004). Semiologic value of ictal autoscopy. *Epilepsia*, 45(4), 391–394. <https://doi.org/10.1111/j.0013-9580.2004.39103.x>
- Mars, R. B., Sallet, J., Schüffelgen, U., Jbabdi, S., Toni, I., & Rushworth, M. F. S. (2012). Connectivity-based subdivisions of the human right “temporoparietal junction area”: Evidence for different areas participating in different cortical networks. *Cerebral Cortex*, 22(8), 1894–1903. <https://doi.org/10.1093/cercor/bhr268>

- Maselli, A. (2015). Allocentric and egocentric manipulations of the sense of self-location in full-body illusions and their relation with the sense of body ownership. *Cognitive Processing*, *16*, 309–312. <https://doi.org/10.1007/s10339-015-0667-z>
- Merleau-Ponty, M. (2012). *Phenomenology of perception* (Landes, D. A., Trans.). New York, NY: Routledge. (Original work published 1945).
- Nakul, E., & Lopez, C. (2017). Commentary: Out-of-body experience during awake craniotomy. *Frontiers in Human Neuroscience*, *11*, 1–4. <https://doi.org/10.3389/fnhum.2017.00417>
- Noel, J.-P., Pfeiffer, C., Blanke, O., & Serino, A. (2015). Peripersonal space as the space of the bodily self. *Cognition*, *144*, 49–57. <https://doi.org/10.1016/j.cognition.2015.07.012>
- Paillard, J. (1999). Body schema and body image – A double dissociation in deafferented patients. *Motor Control, Today and Tomorrow*, *48*, 197–214. <https://doi.org/10.1016/j.neuropsychologia.2009.09.022>
- Parvizi, J., Van Hoesen, G. W., Buckwalter, J., & Damasio, A. (2006). Neural connections of the posteromedial cortex in the macaque. *Proceedings of the National Academy of Sciences*, *103* (5), 1563–1568. <https://doi.org/10.1073/pnas.0507729103>
- Podoll, K., & Robinson, D. (2000). Macrosomatognosia and microsomatognosia in migraine art. *Acta Neurologica Scandinavica*, *101*(6), 413–416. <https://doi.org/10.1034/j.1600-0404.2000.9s334.x>
- Schurz, M., Aichhorn, M., Martin, A., & Perner, J. (2013). Common brain areas engaged in false belief reasoning and visual perspective taking: A meta-analysis of functional brain imaging studies. *Frontiers in Human Neuroscience*, *7*, 1–14. <https://doi.org/10.3389/fnhum.2013.00712>
- Schurz, M., Tholen, M. G., Perner, J., Mars, R. B., & Sallet, J. (2017). Specifying the brain anatomy underlying temporo-parietal junction activations for theory of mind: A review using probabilistic atlases from different imaging modalities. *Human Brain Mapping*, *38*(9), 4788–4805. <https://doi.org/10.1002/hbm.23675>
- Schwoebel, J., & Coslett, H. B. (2005). Evidence for multiple, distinct representations of the human body. *Journal of Cognitive Neuroscience*, *17*(4), 543–553. <https://doi.org/10.1162/0898929053467587>
- Steven, M. S., & Blakemore, C. (2004). Visual synaesthesia in the blind. *Perception*, *33*(7), 855–869. <https://doi.org/10.1068/p5160>
- Takahashi, N., Kawamura, M., Shiota, J., Kasahata, N., & Hirayama, K. (1997). Pure topographic disorientation due to right retrosplenial lesion. *Neurology*, *49*(2), 464–469. <https://doi.org/10.1212/WNL.49.2.464>
- Vogeley, K., & Fink, G. R. (2003). Neural correlates of the first-person-perspective. *Trends in Cognitive Sciences*, *7*(1), 38–42. [https://doi.org/10.1016/S1364-6613\(02\)00003-7](https://doi.org/10.1016/S1364-6613(02)00003-7)
- Weaver, K. E., Richards, T. L., Logsdon, R. G., McGough, E. L., Minoshima, S., Aylward, E. H., . . . Teri, L. (2015). Posterior cingulate lactate as a metabolic biomarker in amnesic mild cognitive impairment. *BioMed Research International*, *2015*, 1–13. <https://doi.org/10.1155/2015/610605>
- Weijers, N. R., Rietveld, A., Meijer, F. J. A., & De Leeuw, F. E. (2013). Macrosomatognosia in frontal lobe infarct – A case report. *Journal of Neurology*, *260*(3), 925–926. <https://doi.org/10.1007/s00415-012-6827-5>
- Yu, K., Liu, C., Yu, T., Wang, X., Xu, C., Ni, D., . . . Liu, C. (2018). Out-of-body experience in the anterior insular cortex during the intracranial electrodes stimulation in an epileptic child. *Journal of Clinical Neuroscience*, *54*, 122–125. <https://doi.org/10.1016/j.jocn.2018.04.050>
- Zamboni, G., Budriesi, C., Nichelli, P., Budriese, C., & Nichelli, P. (2005). “Seeing oneself”: A case of autoscapy. *Neurocase*, *11*(3), 212–215. <https://doi.org/10.1080/13554790590944799>
- Zhang, H., Dai, R., Qin, P., Tang, W., Hu, J., Weng, X., . . . Northoff, G. (2017). Posterior cingulate cross-hemispheric functional connectivity predicts the level of consciousness in traumatic brain injury. *Scientific Reports*, *7*(1), 1–9. <https://doi.org/10.1038/s41598-017-00392-5>