

# Lip Reshaping with LOVE Approach: A Prospective Analysis Based on Two Hyaluronic Acid Fillers

Dario Bertossi, MD\*  
 Riccardo Nocini, MD†  
 Berend van der Lei, MD‡  
 Philippe Magistretti, MD§  
 Alessandro Gualdi, MD¶  
 Ali Pirayesh, MD||  
 Alberto Marchetti, MD\*\*

**Background:** Aesthetic improvement of the lips with hyaluronic acid fillers is a popular procedure. A comprehensive, modular, and highly individualizable method has been developed: the Lip Omnicomprehensive Volume Enhancement (LOVE) approach. The present study assessed the safety and effectiveness of LOVE across different patient age groups.

**Methods:** This was a prospective, single-center study of women aged 20–70 years seeking nonsurgical lip enhancement or asymmetry correction. Three equally sized groups were formed based on patient age: 20–34, 35–45, and 46 years or older. Individualized treatment plans were developed taking into account patient preferences expressed in a pre-injection questionnaire. Treatment used one or more of the three modules of LOVE: lip shape [vermilion border, Vycross (VYC)-17.5]; volume (vermilion body, VYC-17.5); and hydration (submucosal area, VYC-12). Follow-up lasted 6 months.

**Results:** Sixty patients were enrolled (mean age:  $41.3 \pm 13.3$  years;  $n = 20$  per age group), all of whom were White. Most were treated with all three LOVE modules. Mean filler quantities increased with age: 20–34 years,  $1.1 \pm 0.1$  mL; 35–45 years,  $1.5 \pm 0.1$  mL; 46 years or older,  $1.6 \text{ mL} \pm 0.2$  mL. Mean patient satisfaction at 4 weeks [on a seven-point scale from 0 (extremely dissatisfied) to 6 (extremely satisfied)] was 4.8–4.9 in each age group. Apart from minor and transient edema/bruising, there was only one complication: a case of lumps that resolved with home massage.

**Conclusion:** The LOVE approach is safe and effective across a range of ages, with high levels of patient satisfaction. (*Plast Reconstr Surg Glob Open* 2021;9:e3957; doi: 10.1097/GOX.0000000000003957; Published online 24 November 2021.)

## INTRODUCTION

The mouth and lips are key features of an aesthetically pleasing face, and play an important role in human interaction.<sup>1–3</sup> For example, the mouth area is fundamental to conveying happy facial expressions,<sup>1</sup> whereas the size and

shape of the mouth and lips have been linked with creating an impression of approachability.<sup>2</sup> Upper lip height may also be an important correlate of perceived attractiveness, successfulness, and overall health.<sup>4</sup> Hence, it is not surprising that adequate lip volume and a sharp lip border have come to represent important social features of youth and beauty.

The underlying proportions that define “optimal” lips have been analyzed. A vertical height ratio of 1:1.6 between the upper and lower lip has been proposed to define the aesthetic ideal (at least among White subjects).<sup>5,6</sup> However, during the aging process, these proportions typically regress away from the ideal, with a gradual elongation of the cutaneous part of the upper lip and thinning of the vermilion. At the same time, the combined effects of gravity as well as bony and soft-tissue volume loss often cause the oral

From the \*Department of Oral and Maxillofacial Surgery, University of Verona, Policlinico G.B. Rossi, Verona, Italy; †Section of Ear Nose and Throat (ENT), Department of Surgical Sciences, Dentistry, Gynecology and Pediatrics, University of Verona, Verona, Italy; ‡Department of Plastic Surgery, University Medical Center Groningen, Groningen, the Netherlands; §Summit Clinic, Crans, Switzerland; ¶Alessandro Gualdi & Partners, Milan, Italy; ||Amsterdam Plastic Surgery, Amsterdam, the Netherlands; and \*\*Private Practice, Verona, Italy.

Received for publication September 9, 2021; accepted October 5, 2021.

Copyright © 2021 The Authors. Published by Wolters Kluwer Health, Inc. on behalf of The American Society of Plastic Surgeons. This is an open-access article distributed under the terms of the [Creative Commons Attribution-Non Commercial-No Derivatives License 4.0 \(CCBY-NC-ND\)](https://creativecommons.org/licenses/by-nc-nd/4.0/), where it is permissible to download and share the work provided it is properly cited. The work cannot be changed in any way or used commercially without permission from the journal.

DOI: 10.1097/GOX.0000000000003957

**Disclosure:** Drs. Bertossi and Gualdi are consultants and speakers for Allergan S.p.A. Dr Pirayesh is a consultant for Teoxane and Adoderm. All the other authors have no financial interest to declare in relation to the content of this article.

Related Digital Media are available in the full-text version of the article on [www.PRSGlobalOpen.com](http://www.PRSGlobalOpen.com).

commissures to turn downward, creating an impression of frowning.<sup>6</sup>

Thus, it is perhaps not surprising that the popularity of lip treatments is increasing. For example, survey data from the American Society of Plastic Surgeons suggested that surgical lip augmentations increased by 3% in 2019 relative to 2018.<sup>7</sup> However, many patients are unwilling to undergo surgery and instead favor the reduced downtime and lower complication rates associated with minimally invasive, injectable treatments.<sup>8,9</sup> For example, hyaluronic acid (HA) fillers are an important option, and a recent systematic review confirmed their safety and efficacy in the lip area.<sup>10</sup>

Over the past few years, rapid development of novel HA fillers has meant that multiple different products are now available with varying physical properties, such as differences in G'. This allows for a more tailored and individualized approach to treatment and makes obsolete the notion of a single product being used within a "one size fits all" methodology. For the lips, practitioners can now differentiate various zones for treatment with different products with appropriate physical properties.

This raises an important practical question around how best to standardize the approach to treatment with these new tools. Many injection models have been proposed.<sup>11–16</sup> However, there are few comprehensive approaches that are appropriate for patients of any age and can address all aspects of lip improvement with fillers.

In an attempt to deliver a safe protocol for HA filler lip treatment with predictable outcomes, we have developed a new technique called the Lip Omnicomprehensive Volume Enhancement (LOVE) approach.

The LOVE technique with HA uses two different HA filler products across three modules of lip treatment, focusing on shape, volume, and hydration, respectively. The specific products and injection techniques employed within this approach have been developed based on previous experience and by matching the anatomy of the lips with aesthetic standards. The aim of the present work was to assess the safety and effectiveness of the LOVE approach to lip treatment of patients across a range of age groups.

## METHODS

### Study Design and Participants

This was a prospective, single-center study of female patients aged 20–70 years seeking nonsurgical lip enhancement or lip asymmetry correction. All were enrolled between December 2017 and October 2019. Exclusion criteria were previous filler treatment of the lips, history of lip surgery or trauma, or hypersensitivity to HA fillers or lidocaine. The study was conducted in accordance with the Declaration of Helsinki, and all subjects provided written informed consent.

Three separate, equally sized groups were formed based on patient age: 20–34 years; 35–45 years; and 46 years or older.

### Takeaways

**Question:** The Lip Omnicomprehensive Volume Enhancement (LOVE) approach is a comprehensive, modular, and highly individualizable method for aesthetic improvement of the lips using two different hyaluronic acid fillers. Is it safe and effective across a range of age groups?

**Findings:** This prospective study of 60 female patients aged 20–70 years demonstrated high levels of patient satisfaction using the LOVE approach, with low rates of complications.

**Meaning:** The LOVE approach is safe and effective across a range of ages, with high levels of patient satisfaction.

### Procedures

During an initial consultation, the size and shape of the lips were assessed. Patients also completed a brief pretreatment questionnaire, in which they indicated what they liked about their lips and what they wanted to improve in terms of shape, volume, and hydration; the questionnaire also allowed patients to describe the most important defects. Lip treatment plans were developed on an individual basis, taking into account each patient's specific requests and the views expressed in their pretreatment questionnaire. Final treatment plans were based around the three modules of the LOVE approach: shape, volume, and hydration. In some cases, treatment was planned using all three modules; in others, only one or two of these were recommended.


Before treatment, the lips were first disinfected with chlorhexidine in 70% alcohol. Pain was controlled by applying a local anesthetic cream. All patients were treated by the same injector (DB) to minimize the risk of bias.

Fillers were from the Vycross range (Allergan, Dublin, Ireland), which uses differing mixtures of high and low molecular weight HA to deliver different physical properties, some of which are particularly relevant to lip treatment.<sup>17,18</sup> Specifically, the products used had intermediate G' (17.5 mg/mL HA; VYC-17.5; Volift) or very low G' (12 mg/mL HA; VYC-12; Volite).

Treatment proceeded based on the three modules of the LOVE approach: lip shape (treatment of the vermilion border with VYC-17.5), lip volume (treatment of the vermilion body with VYC-17.5), and lip hydration (treatment of the submucosal area with VYC-12) (Fig. 1).

The specific injection techniques that characterized each module were as follows:

- **Lip shape:** This module was based entirely on VYC-17.5 (Fig. 1B). Two 0.2 mL boluses were injected using a 30G needle into the lip to support the corners of the mouth. The entire vermilion border was then treated using a retrograde linear technique with a 30G needle. The philtral column was also injected in a retrograde fashion. This used a bolus of about 0.05 mL injected using a 30G needle at the nasal–labial angle area (anterior nasal spine) at the two ends of the philtrum (ie, columella and vermilion). The needle was gradually retracted, injecting smaller quantities towards the apex of the philtrum,



**Fig. 1.** The LOVE approach. Summary of the LOVE approach to aesthetic lip treatment with hyaluronic acid fillers, showing all three modules combined (A), and the shape (B), volume (C), and hydration (D) modules separately.

where another mini-bolus was injected to give a concave appearance and create upper lip out-rotation.

- **Lip volume:** This module used VYC-17.5 (Fig. 1C). Four points were injected in the upper lip and four in the lower lip using a 38 mm 25G cannula or a 30G needle. A bolus technique was used and the product was placed in the body of the lip over the orbicularis muscle. A greater amount was placed in the central area near the lip tubercles and less was placed laterally. The typical volume was 0.1 mL per point but this could be varied based on individual anatomy.
- **Lip hydration:** This module used VYC-12, which has a very low  $G'$  and hence is extremely soft, allowing for superficial (submucosal) placement without a significant risk of creating product lumps (Fig. 1D). Thus, it was possible to hydrate the lips and camouflage deeper filler injections. Bolus injections of 0.1–0.15 mL were made in the upper lip and three on the lower lip. All used a 38 mm 25G cannula.

Fusidic acid cream was applied after completing treatment. The area was gently massaged if small lumps or irregularities were detected in the lips.

Patients were followed up via telephone in the first few days after injection. If required, a second consultation was scheduled for 2 weeks after initial treatment and touch-up was offered.

#### Assessments

To assess treatment results, a series of six photographs of each patient in standardized poses were taken at four different timepoints: before treatment, after treatment, at 4 weeks, and at 6 months. Patient satisfaction was assessed anonymously at 4 weeks by self-assessment of appearance (using a mirror and photographs) based on a seven-point Likert scale: 0, extremely dissatisfied; 1, dissatisfied; 2, somewhat dissatisfied; 3, neither satisfied nor dissatisfied; 4, somewhat satisfied; 5, satisfied; 6, extremely satisfied. Complications were recorded during and after treatment and throughout 6 months of follow-up.

#### Statistical Analyses

Descriptive statistics are provided, including frequency and percentage for categorical variables, and mean, SD and range for continuous variables.

## RESULTS

A total of 60 female patients were enrolled, with a mean age of  $41.3 \pm 13.3$  years (range: 20–70 years). This included 20 individuals from each of the three age groups: 20–34 years; 35–45 years; and 46 years or older. All 60 study subjects were White.

Results from the pretreatment questionnaires are provided in [Table 1](#). Patients complained primarily of defects in the volume ( $n = 59$ ; 98%) and shape ( $n = 47$ ; 78%) of their lips. Other defects noted included asymmetry ( $n = 23$ ; 38%), as well as concerns about the philtrum ( $n = 35$ ; 58%), perioral lines ( $n = 27$ ; 45%) and down-turning of the oral commissure ( $n = 15$ ; 25%).

Most patients in each of the age groups were treated with all three of the LOVE modules ([Table 2](#)). Typically, treatment required only a single injection session. However, three individuals (5%; all from the oldest age group) needed a touch-up at 2 weeks due to minor asymmetries or a lack of volume; they were treated with 0.4 mL of VYC-17.5 in the middle portion of the upper lip. Mean overall filler quantities (including touch-ups) increased with age: 20–34 years,  $1.1 \pm 0.1$  mL; 35–45 years,  $1.5 \pm 0.1$  mL;  $\geq 46$  years,  $1.6 \text{ mL} \pm 0.2 \text{ mL}$ .

Example patient images are provided in [Figures 2–5](#) and in the supplemental video. (See [Video \[online\]](#), which displays the injection process using the LOVE approach.)

Patient satisfaction was assessed 4 weeks posttreatment on a seven-point scale from 0 (extremely dissatisfied) to 6 (extremely satisfied) ([Table 3](#)). The mean score was 4.9 in patients aged 20–34 years and 4.8 in patients aged 35–45 or 46 years or older. In total, 55 patients (92%) stated that they were satisfied with the results (ie, gave a score of 4–6), and only five (8%) said that they were dissatisfied (ie, gave a score of 0–2).

With regard to complications, 53 patients (88%) experienced edema and 10 (17%) had bruising. These were all minor and transient and resolved spontaneously. One patient (2%) presented with lumps that resolved without further problems with home massage. There were no major complications, such as skin necrosis, vascular occlusion, prolonged edema, granuloma, filler extrusion, or bacterial or viral infection.

**Table 1. Pretreatment Questionnaire Results**

Traits	Patients, n (%)
What do you like most about your lips?	
Shape	47 (78)
Volume	41 (68)
Hydration	9 (15)
What do you think should be changed in your lips?	
Shape	47 (78)
Volume	59 (98)
Hydration	9 (15)
Describe the most important defects in your lips	
Asymmetry	23 (38)
Volume defect	60 (100)
Philtrum	35 (58)
Perioral lines	27 (45)
Down-turning of oral commissure	15 (25)

N = 60.

**Table 2. Patients and Treatments**

	20–34 years	35–45 years	$\geq 46$ years
Patients, N	20	20	20
Patients treated using each module, n (%)			
Shape	20 (100)	17 (85)	20 (100)
Volume	20 (100)	20 (100)	20 (100)
Hydration	18 (90)	20 (100)	18 (90)
Volume of HA filler, mL, mean $\pm$ SD	$1.1 \pm 0.1$	$1.5 \pm 0.1$	$1.6 \pm 0.2$

## DISCUSSION

In this prospective assessment of 60 patients undergoing lip treatment with HA fillers, the LOVE approach proved to be safe and effective irrespective of patient age. Indeed, satisfaction rates (assessed 4 weeks after treatment) were similar across all three prespecified age groups, suggesting that this method is usable throughout the aging process, probably owing to the versatility of both the methodology itself and of the two filler products used. Only five patients reported being dissatisfied with results, and these were mostly individuals with unrealistic expectations about what could be achieved.

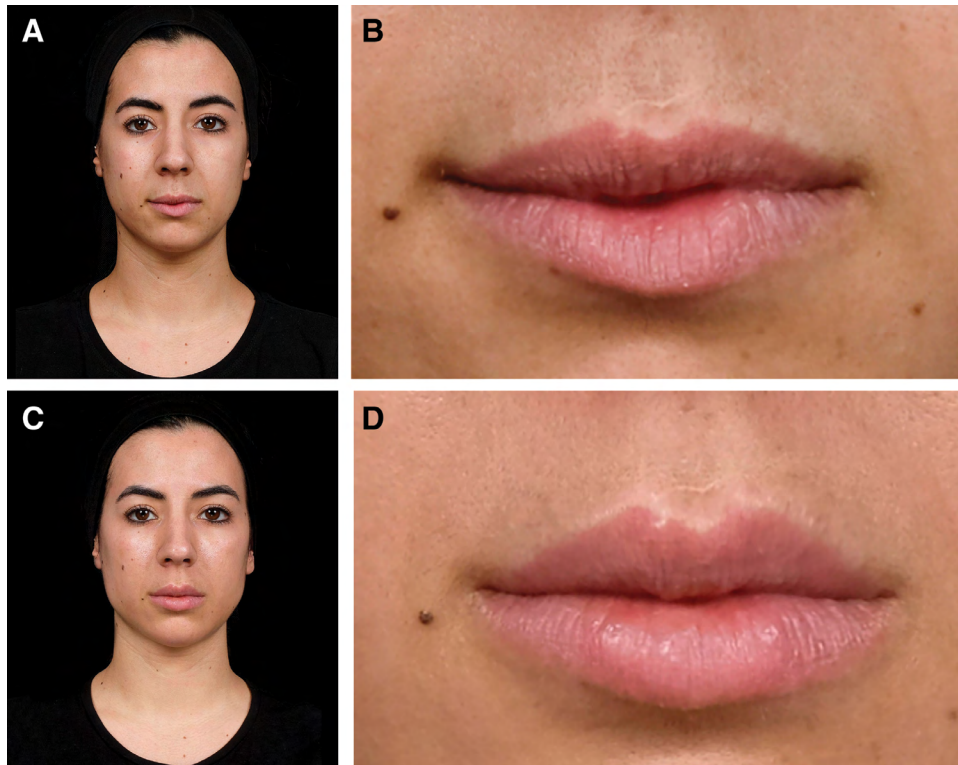In addition, only three patients required a touch-up 2 weeks after initial lip injection, even though this was offered free of charge. All related to minor asymmetries or requests for extra volume. The low rate of touch-up further confirms the effectiveness of the LOVE approach in matching results with patient desires.

Repeat treatment of the lips was not assessed as part of the study, but many patients subsequently returned for further rounds of injection. The typical time between treatments was around 10 months.

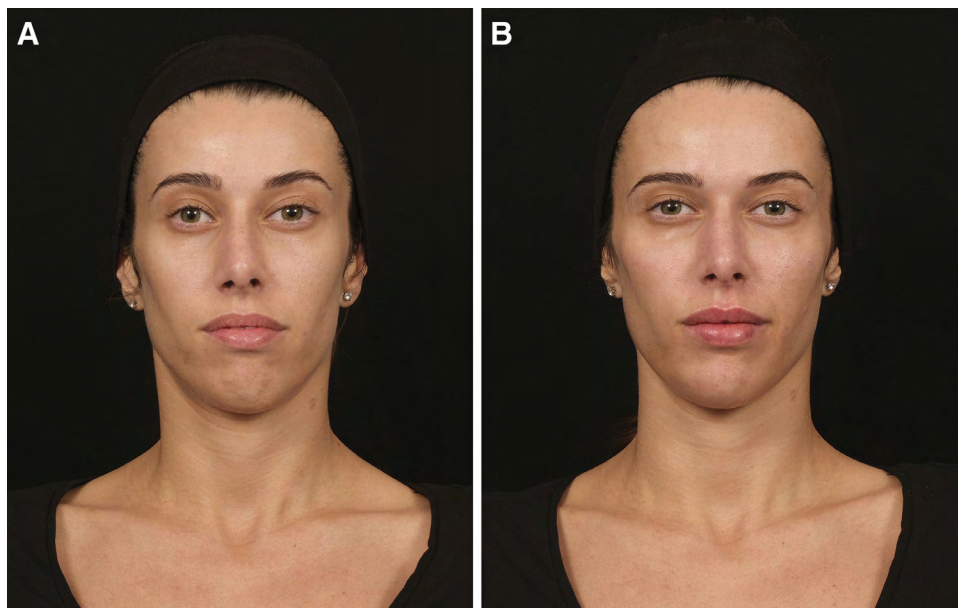Although there are other approaches to injection of the lip area,<sup>11–16</sup> LOVE has the advantage of being a comprehensive method covering all aspects of lip improvement with fillers, based on injection of different anatomical layers and using more than one product. It can be utilized irrespective of patient age. This is particularly important given that the objectives of treatment are likely to differ substantially with age. In young patients, the key aims are typically to improve volume and create a sharper vermilion border; in older individuals, treatment is more likely to focus on volume and hydration, and attempting to reshape the vermilion border can sometimes cause undesirable increases in volume.

The LOVE approach is also extremely flexible, allowing injectors to divide lip treatment into three different modules and correct each aspect separately. In any given treatment plan, patients and injectors may agree to use one, two, or all three modules. Furthermore, LOVE can be used for treating the lips in isolation or within the context of a broader, “full face” treatment program.<sup>19</sup>

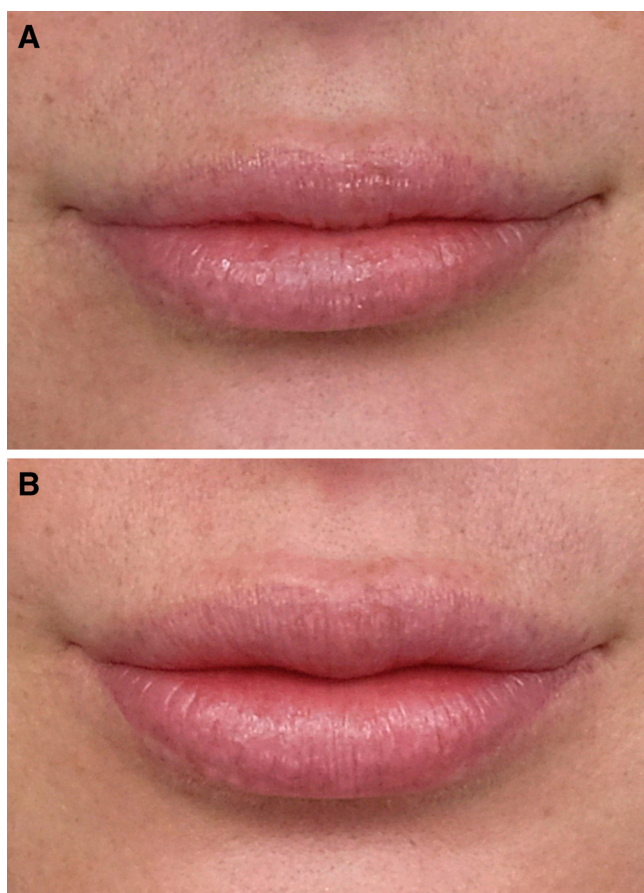All injections utilized products from the Vycross range, which has proven safety and efficacy from multiple clinical trials in the lip area.<sup>20–24</sup> Specifically, treatment was based on two fillers with varying physical properties.<sup>17,18</sup> VYC-17.5L has an intermediate G', and therefore provides the subtle lift capacity needed to add form and structure—ideal for the shape and volume modules of LOVE.



**Fig. 2.** Treatment of the lips using the LOVE approach. A 29-year-old woman before (A, B) and 25 weeks after (C, D) aesthetic treatment of the lips using HA fillers, based on the LOVE approach. The patient was injected with all three LOVE modules using a total of 1.4 mL of HA filler (1.0 mL VYC-17.5 and 0.4 mL VYC-12).



**Fig. 3.** Treatment of the lips using the LOVE approach. A 29-year-old woman before (A) and 12 weeks after (B) aesthetic treatment of the lips using HA fillers, based on the LOVE approach. The patient was injected with all three LOVE modules using a total of 1.4 mL of HA filler (1 mL VYC-17.5 and 0.4 mL VYC-12).

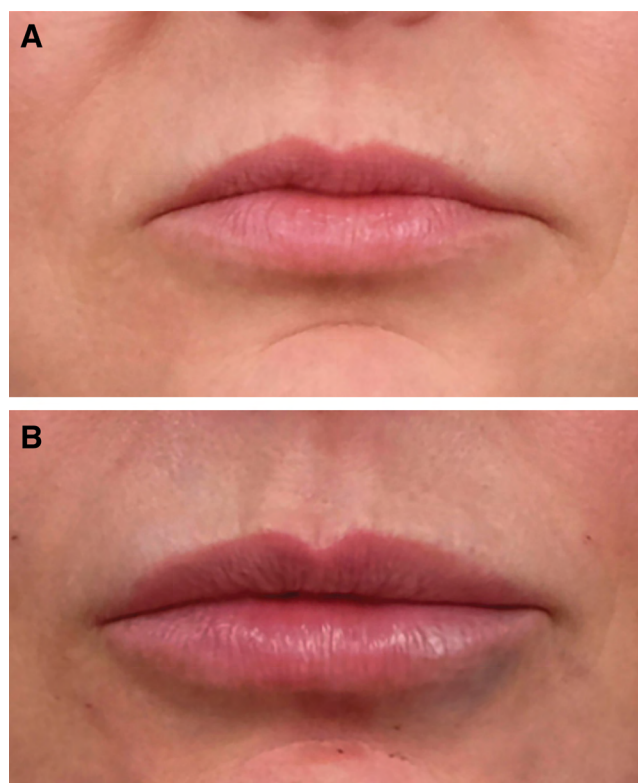

**Fig. 4.** Treatment of the lips using the LOVE approach. A 35-year-old woman before (A) and 25 weeks after (B) aesthetic treatment of the lips using HA fillers, based on the LOVE approach. The patient was injected with all three LOVE modules using a total of 1.6mL of HA filler (1.0mL VYC-17.5 and 0.6mL VYC-12).

By contrast, VYC-12 has a very low  $G'$ , which allows for superficial injection and hence improvements in fine lines and skin quality attributes—ideal for the hydration module. We believe it is rational to optimize the physical properties of the product used according to the specific aims of the procedure, even within the same area of the face (in this case, the lips). Some practitioners might consider it a limitation of the LOVE technique that it requires more than one product to be used in a single facial area. However, manufacturers have invested heavily in research to expand their injectable product portfolios and thus better meet varying clinical needs.

A product with intermediate  $G'$  (VYC-17.5) was used for the shape module, to redefine lip contour. A small quantity was typically sufficient to obtain good results. With the wrong product or technique, injection of the vermillion border can lead to filler migration and distortion of the upper lip. The medium cohesiveness of VYC-17.5 is crucial to obtaining good lip projection and giving definition to the Cupid's bow.

VYC-17.5 was also used for the volume module. Previously, to restore volume to the lips, practitioners typically had to choose between stiffer products, which



**Fig. 5.** Treatment of the lips using the LOVE approach. A 57-year-old woman before (A) and 26 weeks after (B) aesthetic treatment of the lips using HA fillers, based on the LOVE approach. The patient was injected with all three LOVE modules using a total of 1.8mL of HA filler (1.0mL VYC-17.5 and 0.8mL VYC-12).

were more durable but carried a high risk of lump development, and softer products that reduced this risk but had a faster rate of absorption.<sup>11,25</sup> Newer formulations like VYC-17.5 may provide an improved balance of these properties.

The hydration module was based on VYC-12. Superficial placement of this product has been shown to improve various skin quality attributes (eg, hydration, smoothness, and deformation),<sup>18,26</sup> most likely by stabilizing the extracellular matrix and increasing hydration of the dermis.<sup>27</sup> Furthermore, some patients prefer not to volumize their lips, either because they are anxious about

**Table 3. Patient Satisfaction with Treatment**

	Patient Age		
	20–34 years	35–45 years	≥46 years
Patients giving score, n (%)			
0	0 (0)	0 (0)	0 (0)
1	1 (5)	2 (10)	2 (10)
2	0 (0)	0 (0)	0 (0)
3	0 (0)	0 (0)	0 (0)
4	1 (5)	1 (5)	1 (5)
5	16 (80)	13 (65)	13 (65)
6	2 (10)	4 (20)	4 (20)
Mean score	<b>4.9</b>	<b>4.8</b>	<b>4.8</b>

N = 20 in each group. Satisfaction was assessed on a seven-point scale from 0 (extremely dissatisfied) to 6 (extremely satisfied).

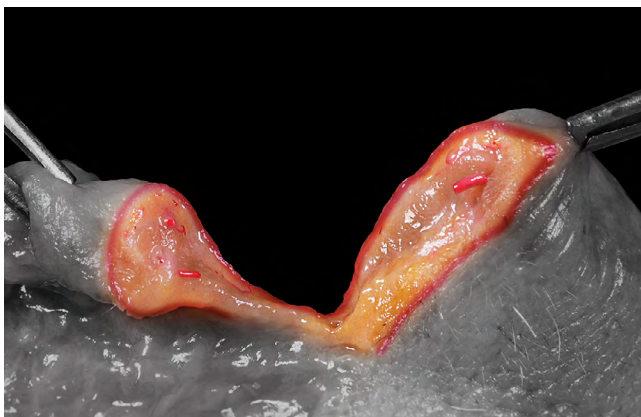The final score in bold indicates the high satisfaction rate we have achieved with the technique.

this effect or because they only want to correct the vertical wrinkles of the vermilion; in these cases, a softer product like VYC-12 may be preferred to create a natural look. In the LOVE approach, VYC-12 was also used to cover up the filler placed at greater depth and to give a homogeneous appearance to the vermilion.

The preferred injection device was also tailored accordingly within LOVE. Thus, a cannula was typically used for the volume and hydration modules to reduce bleeding risk, whereas a needle was favored for the shape module to allow more precise positioning of filler into the required anatomical layer, thereby avoiding the superior and inferior labial arteries (Fig. 6).

The complication rate in the present study was low. Apart from the usual minor, transient bruising and edema that occurs frequently with HA fillers, there was only one complication of note: a single case of lump formation that resolved with home massage. The LOVE approach was designed primarily for advanced practitioners, but its versatility and targeted use of different fillers may help minimize complications, and hence potentially make the techniques more accessible to less experienced injectors. Nonetheless, great care is always required when treating the lips. A thorough knowledge of the anatomy and vasculature of the perioral area is the basis of good clinical practice, to avoid serious complications.<sup>28</sup> We favor the use of aspiration as a safety checkpoint, and a recent guidance article concurs that this should at least be considered.<sup>29</sup> Injection technique is also important, and the consequences of poor product positioning can include filler migration and lump formation.<sup>29,30</sup>

An important limitation of the present work was that all 60 patients were White. Optimal lip proportions are often highly specific to racial and cultural background,<sup>31–33</sup> and practitioners must be sensitive to these differences when managing diverse patient groups. For example, lip volume is typically greater among black populations compared with other racial groups, and there is a reduced tendency for volume to decline with age;<sup>6,34</sup> in Asian patients,



**Fig. 6.** Anatomical dissection of the lower lip. This shows the sectioned inferior labial artery within the orbicularis muscle. The superior labial artery of the upper lip can be found in a similar anatomical layer.

aesthetic ideals may be defined by a smaller upper lip height compared with other groups.<sup>31,33</sup> Underestimation of these differences can lead to subversion rather than to enhancement of the patient's own anatomy. We are currently working on adaptations to the LOVE approach that will broaden its usability across different racial and cultural profiles.

We also acknowledge other limitations of this work. First, it was an uncontrolled analysis and it would be interesting to compare the LOVE approach with other protocols in the context of a randomized trial. Second, all of the included patients were women. The lips and perioral region are among the lowest priority areas for most male patients,<sup>35,36</sup> but it would nonetheless be valuable to extend the LOVE approach to men. Third, patients were only followed up for 6 months. However, previous work suggests that delayed complications are rare when these products are used in the lips.<sup>22</sup>

## CONCLUSIONS

The LOVE approach is a comprehensive, flexible and highly individualizable method for nonsurgical aesthetic improvement of the lips. It employs two different HA filler products injected based on three separate modules, focusing on lip shape, volume, and hydration, respectively. The present study demonstrated that LOVE is safe and effective irrespective of age, with high levels of patient satisfaction. This method has potential to elevate the technical level of lip treatment.

**Dario Bertossi, MD**

Department of Oral and Maxillofacial Surgery  
University of Verona, Policlinico G.B. Rossi  
Piazzale L. Scuro, 10 – 37134, Verona  
Italy

E-mail: [dario.bertossi@univr.it](mailto:dario.bertossi@univr.it)

## ACKNOWLEDGMENTS

*Writing and editorial assistance was provided to the authors by Timothy Ryder, DPhil, of Biological Communications Limited (London, UK) and funded by Allergan plc (now AbbVie) at the request of the investigator. All authors met the ICMJE authorship criteria. Neither honoraria nor payments were made for authorship. The study was conducted in accordance with the Declaration of Helsinki.*

## PATIENT CONSENT

*The patients provided written consent for the use of their images.*

## REFERENCES

1. Eisenbarth H, Alpers GW. Happy mouth and sad eyes: scanning emotional facial expressions. *Emotion*. 2011;11:860–865.
2. Vernon RJ, Sutherland CA, Young AW, et al. Modeling first impressions from highly variable facial images. *Proc Natl Acad Sci USA*. 2014;111:E3353–E3361.
3. Wu SQ, Pan BL, An Y, et al. Lip morphology and aesthetics: study review and prospects in plastic surgery. *Aesthetic Plast Surg*. 2019;43:637–643.

4. Linkov G, Wick E, Kallogjeri D, et al. Perception of upper lip augmentation utilizing simulated photography. *Arch Plast Surg*. 2019;46:248–254.
5. Mandy S. Art of the lip. *Dermatol Surg*. 2007;33:521–522.
6. Kar M, Muluk NB, Bafaqeeh SA, et al. Is it possible to define the ideal lips? *Acta Otorhinolaryngol Ital*. 2018;38:67–72.
7. American Society of Plastic Surgeons. 2019 Plastic surgery statistics report. 2020. Available at [www.plasticsurgery.org/documents/News/Statistics/2019/plastic-surgery-statistics-full-report-2019.pdf](http://www.plasticsurgery.org/documents/News/Statistics/2019/plastic-surgery-statistics-full-report-2019.pdf). 2020. Accessed April 20, 2021.
8. Philipp-Dormston WG, Bergfeld D, Sommer BM, et al. Consensus statement on prevention and management of adverse effects following rejuvenation procedures with hyaluronic acid-based fillers. *J Eur Acad Dermatol Venerol*. 2017;31:1088–1095.
9. Alam M, Tung R. Injection technique in neurotoxins and fillers: planning and basic technique. *J Am Acad Dermatol*. 2018;79:407–419.
10. Stojanović L, Majdič N. Effectiveness and safety of hyaluronic acid fillers used to enhance overall lip fullness: a systematic review of clinical studies. *J Cosmet Dermatol*. 2019;18:436–443.
11. Sarnoff DS, Gotkin RH. Six steps to the “perfect” lip. *J Drugs Dermatol*. 2012;11:1081–1088.
12. San Miguel Moragas J, Reddy RR, Hernández Alfaro F, et al. Systematic review of “filling” procedures for lip augmentation regarding types of material, outcomes and complications. *J Craniomaxillofac Surg*. 2015;43:883–906.
13. Sahan A, Funda T. Four-point injection technique for lip augmentation. *Acta Dermatovenerol Alp Pannonica Adriat*. 2018;27:71–73.
14. Sito G, Consolini L, Trévidic P. Proposed guide to lip treatment in Caucasian women using objective and measurable parameters. *Aesthet Surg J*. 2019;39:NP474–NP483.
15. Zazzaron M. Customized lip enhancement for clinical different lip features: an observational study. *J Cosmet Dermatol*. 2020;19:38–46.
16. Bertossi D, Nocini PF, Rahman E, et al. Non surgical facial reshaping using MD Codes. *J Cosmet Dermatol*. 2020;19:2219–2228.
17. Goodman GJ, Swift A, Remington BK. Current concepts in the use of voluma, volift, and volbella. *Plast Reconstr Surg*. 2015;136(5 Suppl):139S–148S.
18. Niforos F, Ogilvie P, Cavallini M, et al. VYC-12 injectable gel is safe and effective for improvement of facial skin topography: a prospective study. *Clin Cosmet Investig Dermatol*. 2019;12:791–798.
19. Bertossi D, Tessari G, Girolomoni G, et al. The facial grid analysis for filler injection: a cohort study of 300 patients. *G Ital Dermatol Venerol*. 2016;151:467–472.
20. Philipp-Dormston WG, Hilton S, Nathan M. A prospective, open-label, multicenter, observational, postmarket study of the use of a 15 mg/mL hyaluronic acid dermal filler in the lips. *J Cosmet Dermatol*. 2014;13:125–134.
21. Raspaldo H, Chantrey J, Belhaouari L, et al. Lip and perioral enhancement: a 12-month prospective, randomized, controlled study. *J Drugs Dermatol*. 2015;14:1444–1452.
22. Calvisi L, Gilbert E, Tonini D. Rejuvenation of the perioral and lip regions with two new dermal fillers: the Italian experience with Vycross technology. *J Cosmet Laser Ther*. 2017;19:54–58.
23. Geronemus RG, Bank DE, Hardas B, et al. Safety and effectiveness of VYC-15L, a hyaluronic acid filler for lip and perioral enhancement: one-year results from a randomized, controlled study. *Dermatol Surg*. 2017;43:396–404.
24. Rivkin A, Weinkle SH, Hardas B, et al. Safety and effectiveness of repeat treatment with VYC-15L for lip and perioral enhancement: results from a prospective multicenter study. *Aesthet Surg J*. 2019;39:413–422.
25. Sarnoff DS, Saini R, Gotkin RH. Comparison of filling agents for lip augmentation. *Aesthet Surg J*. 2008;28:556–563.
26. Cavallini M, Papagni M, Ryder TJ, et al. Skin quality improvement with VYC-12, a new injectable hyaluronic acid: objective results using digital analysis. *Dermatol Surg*. 2019;45:1598–1604.
27. Landau M, Fagien S. Science of hyaluronic acid beyond filling: fibroblasts and their response to the extracellular matrix. *Plast Reconstr Surg*. 2015;136(5 Suppl):188S–195S.
28. Samizadeh S, Pirayesh A, Bertossi D. Anatomical variations in the course of labial arteries: a literature review. *Aesthet Surg J*. 2019;39:1225–1235.
29. Heydenrych I, Kapoor KM, De Boule K, et al. A 10-point plan for avoiding hyaluronic acid dermal filler-related complications during facial aesthetic procedures and algorithms for management. *Clin Cosmet Investig Dermatol*. 2018;11:603–611.
30. De Boule K, Heydenrych I. Patient factors influencing dermal filler complications: prevention, assessment, and treatment. *Clin Cosmet Investig Dermatol*. 2015;8:205–214.
31. Wong WW, Davis DG, Camp MC, et al. Contribution of lip proportions to facial aesthetics in different ethnicities: a three-dimensional analysis. *J Plast Reconstr Aesthet Surg*. 2010;63:2032–2039.
32. Broer PN, Juran S, Liu YJ, et al. The impact of geographic, ethnic, and demographic dynamics on the perception of beauty. *J Craniofac Surg*. 2014;25:e157–e161.
33. Heidekrueger PI, Szpalski C, Weichman K, et al. Lip attractiveness: a cross-cultural analysis. *Aesthet Surg J*. 2017;37:828–836.
34. Kau CH, Wang J, Davis M. A cross-sectional study to understand 3D facial differences in a population of African Americans and Caucasians. *Eur J Dent*. 2019;13:485–496.
35. Jagdeo J, Keaney T, Narurkar V, et al. Facial treatment preferences among aesthetically oriented men. *Dermatol Surg*. 2016;42:1155–1163.
36. Keaney TC, Anolik R, Braz A, et al. The male aesthetic patient: facial anatomy, concepts of attractiveness, and treatment patterns. *J Drugs Dermatol*. 2018;17:19–28.