

Received: 2015.07.28
Accepted: 2015.12.28
Published: 2016.06.28

Noninvasive Cardiac Quantum Spectrum Technology Effectively Detects Myocardial Ischemia

Authors' Contribution:
Study Design A
Data Collection B
Statistical Analysis C
Data Interpretation D
Manuscript Preparation E
Literature Search F
Funds Collection G

ABCDEF 1 **Ke Li***
BCDE 1 **Qiao Xue***
BCDE 2 **Mohan Liu**
BCDE 2 **Xiaoqin Zheng**
BCDE 2 **Rui Chen**
ABCE 2 **Yufeng Li**
BCE 2 **Qing Dan**
BCE 3 **Danqun Fang**

1 Department of Cardiology, Hainan Branch of Chinese PLA General Hospital, Sanya, Hainan, P.R. China
2 Department of Cardiology, Chinese PLA General Hospital, Beijing, P.R. China
3 Micro Bio-Physics Laboratory, Los Angeles, CA, U.S.A.

* These authors contributed equally to this study

Corresponding Author: Yufeng Li, e-mail: yfli518@sina.com

Source of support: Departmental sources

Background: A standard resting electrocardiogram (ECG) shows limited sensitivity and specificity for the detection of coronary artery disease (CAD). Several analytic methods exist to enhance the sensitivity and specificity of resting ECG for diagnosis of CAD. We compared a new computer-enhanced, resting ECG analysis device, the cardiac quantum spectrum (CQS) technique, with coronary angiography in the detection of CAD.





Material/Methods: A consecutive sample of 93 patients with a history of suspected CAD scheduled for coronary angiography was evaluated with CQS before coronary angiography. The sensitivity and specificity of CQS and standard 12-lead ECG for detecting hemodynamically relevant coronary stenosis were compared, using coronary angiography as the reference standard. Kappa analysis was performed to assess the agreement between CQS severity scores and the level of stenosis determined by coronary angiography.

Results: The CQS system identified 78 of 82 patients with hemodynamically relevant stenosis (sensitivity, 95.1%; specificity, 63.6%; accuracy, 91.4%; positive predictive value, 95.1%; negative predictive value, 63.6%). Sensitivity and accuracy were much higher for CQS analysis than for the standard ECG. The Kappa value, assessing the level of agreement between CQS and coronary angiography, was 0.376 ($P < 0.001$).

Conclusions: CQS analysis of resting ECG data detects hemodynamically relevant CAD with high sensitivity and specificity.

MeSH Keywords: **Coronary Angiography • Coronary Artery Disease • Diagnostic Techniques, Cardiovascular**

Full-text PDF: <http://www.medscimonit.com/abstract/index/idArt/895480>

 2579  4  2  8



Background

The standard resting electrocardiogram (ECG) has been used as an important tool to detect heart diseases for over 100 years, and has the advantages of being simple, quick, and non-invasive in its application. However, despite developments in the traditional ECG during the past 50 years, little progress has been made in improving its sensitivity and specificity for the diagnosis of coronary artery diseases (CAD), which remain at 50–55% [1–3].

The treadmill stress test, which uses medication or exercise to induce myocardial ischemia, can improve the sensitivity of the ECG in the diagnosis of CAD. However, clinical application of the treadmill stress test is limited by a high rate of false positives and the possibility of precipitating serious cardiac events (such as acute myocardial infarction, cardiogenic shock, and sudden death).

Cardiac quantum spectrum (CQS) technology constructs a mathematic model of the heart by considering the myocardium to behave as a viscoelastic solid and the blood to behave as a non-Newtonian fluid, and detects CAD using quantum spectrum analysis and biocybernetic theory. The CQS measures the electrical signals generated by the heart from a 12-lead ECG, acquired over 90 seconds with the patient in a resting state. The Fast-Fourier Transfer transforms the time-domain wave into its frequency power spectrum. A cardiac mathematical and physical model based on the concept that the human heart works like a blood pump, with the blood vessels and electric conduction acting as the transmission is used to model cardiac functions and conditions. The quantum analysis is then compared against a database containing more than 30,000 clinical results, allowing the detection and differentiation of various heart dysfunctions in an early, accurate, fast, and non-invasive manner (Figure 1).

This clinical study aimed to explore the diagnostic value of CQS technology in the detection of CAD by analyzing the characteristics of the quantum spectra of patients with CAD, and compare its ability to detect CAD with that of the traditional ECG and coronary angiography, which is currently considered the gold standard method.

Material and Methods

Study participants

This was a prospective study of patients scheduled to undergo coronary angiography between January 2011 and June 2012 at the PLA General Hospital (Beijing, China) and the University of California in San Diego (CA, USA). The inclusion criteria were: 1) age ≥ 18 years; 2) CAD suspected on the basis of clinical

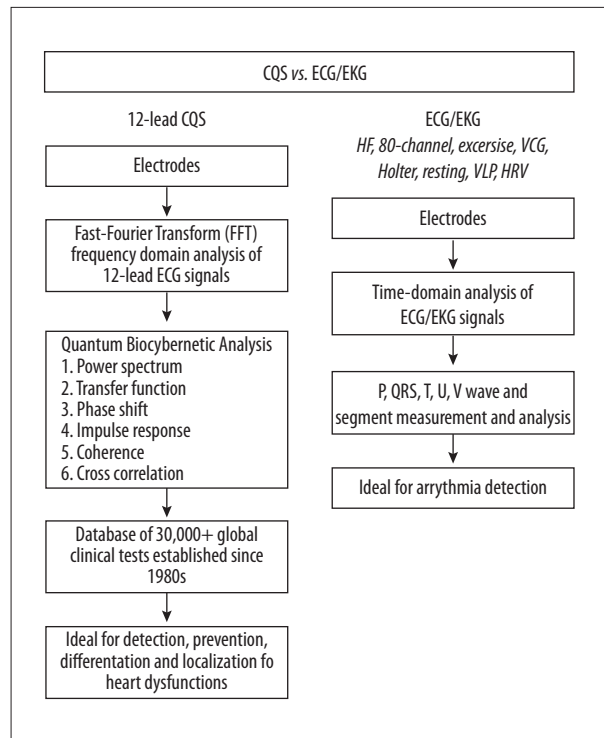


Figure 1. Comparison of the CQS and ECG techniques.

symptoms (shortness of breath, oppressive or squeezing chest pain, and/or sensation of constriction substernally or at the throat); and 3) scheduled to undergo diagnostic coronary angiography. The following exclusion criteria were used: 1) severe lung disease; 2) chest deformity; 3) scheduled to undergo surgery; 4) not suitable for coronary angiography (e.g., due to recent infectious disease); 5) liver or kidney dysfunction; or 6) electrolyte disturbances. The study was approved by the local Ethics Committees, and all patients provided informed written consent prior to enrolment.

Devices and methods

ECG

All patients were investigated using a 12-lead ECG. The results were analyzed, using a computer replay system, by three physicians trained in the interpretation of ECG and blinded to the clinical diagnosis. The following ECG characteristics were used to identify myocardial ischemia: 1) depression of the ST segment, as a horizontal or dipping oblique wave, in more than two leads; 2) a low, flat or inverted T wave; 3) a U wave, with a depth of inversion ≥ 0.05 mV; and 4) a pathologic Q wave.

CQS analysis

Clinical testing was conducted using the Cardiac Quantum Spectrum (CQSD) (NOVONT Cardio Inc., USA). Before testing,

patients were required to remove any metallic objects. Signals from a 12-lead ECG were recorded over a 90-second period with the patient lying in the supine position. The collected signals were processed to derive the cardiac quantum power spectrum, and biocybernetic analysis was performed (using V5 as the input signal and lead II as the output signal) to obtain the phase shift, impulse response, cross correlation, and coherence. 3D-localization of ischemic areas was undertaken, with obvious abnormalities in three or more leads indicating myocardial ischemia or insufficient perfusion to the myocardium. Based on these analyses, the CQS results were classified as either “normal”, “mild”, or “moderate to severe”. Cardiac risk was determined by combining the CQS analysis with ECG findings and traditional risk factors for heart disease. The CQS disease evaluation scores were rated on a scale of 0 to 9, with a higher number indicating a more severe heart condition, as follows: 0–3: normal; 4–6: borderline; 7–9: moderate to severe.

Coronary angiography

The Seldinger method was used to insert a 6F arterial sheath into the femoral or radial artery for angiography of the left and right coronary artery, with the patient in the supine position. The left main branch, left anterior descending artery, left circumflex artery, right coronary artery and first-level large arteries were evaluated for stenosis.

The results of coronary angiography were categorized as follows:

1. Normal: coronary artery with a smooth internal surface, and no visible calcification, atherosclerotic plaque, ulceration, arterial dissection, stenosis, or abnormal density.
2. Low to moderate lesion: partial stenosis of one or multiple coronary arteries, with vessel diameter reduced by 1–59%.
3. Moderate to severe lesion: stenosis of one or multiple coronary arteries, with vessel diameter reduced by 60% or more.

Statistical analysis

SPSS 11.0 (Chicago, IL, USA) was used for statistical analysis. The diagnostic performances of CQS analysis and the standard resting ECG for the detection of coronary artery stenosis were described in terms of sensitivity, specificity, positive predictive value (PPV), negative predictive value (NPV), and accuracy, using coronary angiography as the reference technique. Sensitivity was calculated as the true positive rate (number of true positives divided by the sum of the number of true positives and number of false negatives); specificity as the true negative rate (number of true negatives divided by the sum of the number of true negatives and number of false positives); PPV as the number of true positives divided by the sum of the number of true positives and number of false positives; NPV as the number of true negatives divided by the sum of

the number of true negatives and number of false negatives; and accuracy as the sum of the number of true positives and number of true negatives divided by the total number of results (i.e. all positives and all negatives). Data are presented as the mean±standard deviation. Statistical analyses of continuous variables were made using Student’s t-test for comparisons between two groups, or analysis of variance (ANOVA) with Fisher’s least significant difference post-hoc test for comparisons between more than two groups. The χ^2 test was used for comparison of categorical variables between groups. Kappa analysis was employed to assess the level of agreement between CQS evaluation scores and the degree of stenosis detected by coronary angiography. $P<0.05$ was regarded as indicating statistical significance.

Results

Demographic and clinical characteristics of the included patients

A total of 93 patients were included in the study, 75 (mean age, 62.28 ± 11.34 years) enrolled at the PLA General Hospital, and 18 (mean age, 59.06 ± 12.73 years) at the Micro Bio-Physic Laboratory. The demographic and clinical characteristics of these patients are presented in Table 1. The proportion of patients with oral antiplatelet agents was lower in the American cohort than that in the Chinese cohort (12.5% vs. 25.9%, $P<0.05$). However, there were no significant differences between the two groups in age, gender, prevalence of hypertension, or hypercholesterolemia, and history of PCI or CABG. Table 2 presents the characteristics of the patients according to the angiography findings.

Detection of coronary artery disease using the resting 12-lead ECG and CQS analysis

Using coronary angiography as the reference standard, CQS was found to have a much higher sensitivity (95.1% vs. 28.0%) and accuracy (91.4% vs. 34.4%) than the standard 12-lead ECG for the diagnosis of CAD, although the specificity of CQS was lower (63.6% vs. 81.8%) (Table 2). Both techniques had high PPV values ($>90\%$), but the NPV of CQS was superior to that of the standard ECG (63.6% vs. 13.2%) (Table 3).

Agreement between CQS analysis and coronary angiography in the evaluation of the severity of coronary artery stenosis

Table 4 compares the evaluation of the degree of coronary stenosis between coronary angiography and CQS analysis. The Kappa value was calculated to be 0.376 ($P<0.001$), which indicates that the level of agreement between the two techniques

Table 1. Demographic and clinical characteristics of the patients in three groups.

Variable	China cohort (N=75)		USA cohort (N=18)		P value
Age (years)	62.28±11.34		59.06±12.73		0.18
Gender (male/total)	51/75	(68.00%)	12/18	(66.67%)	0.21
Body mass index (kg/m ²)	23.77		25.31		0.20
Diabetes	11/75	(14.67%)	5/18	(27.78%)	0.01
Hypertension	49/75	(65.33%)	12/18	(66.67%)	0.22
Systolic BP (mmHg)	132.3±19.1		131.2±19.7		0.91
Diastolic BP (mmHg)	71.1± 13.0		71.5±14.3		0.95
Average heart rate (bpm)	67.2± 13.1		67.2± 15.6		1.00
Medication					
Antiplatelet agents	13/75	(17.3%)	10/18	(55.9%)	0.00
ACE inhibitor or ARB	34/75	(45.3%)	10/18	(55.6%)	0.60
β-blocker	19/75	(25.3%)	8/18	(44.4%)	0.15
Calcium channel blocker	36/75	(48.0%)	7/18	(38.9%)	0.60
Diuretics	16/75	(21.3%)	3/18	(16.7%)	1.00
History of PCI or CABG	14/75	(18.67%)	3/18	(16.67%)	0.08

ACE – angiotensin-converting enzyme; ARB – angiotensin receptor antagonist; BP – blood pressure; HDL – high-density lipoprotein; LDL – low-density lipoprotein; LVEF – left ventricle ejection fraction; bpm – beats per minute; PCI – percutaneous coronary intervention; CABG – coronary artery bypasses graft. Data are presented as the mean±standard deviation of the mean or n/N (%).

was not high. This, in part, may have resulted from CQS analysis failing to detect coronary artery stenosis in 12 patients who were diagnosed by coronary angiography as having low-to-moderate stenosis.

Judgment of special cases

Coronary angiography identified eight patients with slow coronary blood flow; seven of these patients had mild coronary artery stenosis while one had no obvious stenosis. Only two of these eight patients exhibited abnormalities (non-specific ST-T segment changes) in the standard 12-lead ECG, while six were considered to have normal ECGs. However, CQS analysis successfully identified all seven patients with slow coronary blood flow and mild coronary stenosis; the one patient with slow flow but no coronary stenosis was categorized by CQS as having no abnormality.

Both standard ECG testing and CQS analysis failed to identify three-vessel CAD in two of eight patients. In addition, one patient with dilated cardiomyopathy (as demonstrated by coronary angiography) was diagnosed by CQS as having myocardial ischemia.

Discussion

The physiologic and pathologic electrical activities of the heart are reflected in the standard ECG, which represents the combination of the electrical activities of all the myocardial cells. Standard ECG analysis of cardiac function relies on detecting changes in the shape of the waveform with time as the horizontal ordinate. Analyzing these signals using the CQS technique provides more information than that yielded by standard ECG interpretation, and allows the extraction of additional biologically relevant data that give further insight into cardiac physiology and pathology. Therefore, the CQS technique can potentially improve the sensitivity and specificity of noninvasive tests for cardiovascular diseases. Indeed, CQS has been used since the 1990s for the diagnosis of cardiac disease [4–6]. In the present research, CQS analysis was utilized in the diagnosis of coronary artery stenosis in both Chinese and American patients. The study was designed to comprehensively compare the CQS technique with the traditional ECG method, using coronary angiography as the reference standard, in order to assess the diagnostic value of CQS analysis in patients with CAD and correlate its evaluation of cardiac risk with the degree of stenosis identified by coronary angiography.

Table 2. Baseline characteristics of the subjects with normal (NA) and abnormal (AA) angiography findings.

Variable	NA (N=8)	AA (N=85)	P value
Age (years)	58.2±15.2	63.0±11.3	0.12
Gender (male/total)	4/8 (50%)	59/85 (69.41%)	0.27
Body mass index (kg/m ²)	22.0± 3.4	27.1±5.0	0.31
Diabetes mellitus (n/total)	1/8 (13%)	15/85 (18%)	1.00
Hypertension (n/total)	3/8 (38%)	58/85 (68%)	0.10
Systolic BP (mmHg)	126±10	137±11	0.55
Diastolic BP (mmHg)	71± 10	73±11	0.91
Current Smoking (n/total)	2/8 (25%)	22/85 (26%)	1.00
Triglyceride (mg/dL)	127.1±81.3	148.3±98.8	0.17
HDL cholesterol (mg/dL)	169.5±41.1	176.9±41.5	0.46
LDL cholesterol (mg/dL)	44.8±11.1	54.3±18.7	0.15
Average heart rate (bpm)	65.3± 21.0	68.8± 30.1	0.28
Medication			
Antiplatelet agents (n/total)	2/8 (25%)	21/85 (25%)	1.00
ACE inhibitor or ARB (n/total)	3/8 (38%)	41/85 (48%)	0.72
β-blocker (n/total)	2/8 (25%)	25/85 (29%)	1.00
Calcium channel blocker (n/total)	4/8 (50%)	39/85 (46%)	1.00
Diuretics (n/total)	2/8 (25%)	17/85 (20%)	0.66
LVEF (%)	56.9± 3.4	57.6± 7.4	0.57
History of PCI or CABG	0/8 (0%)	17/85 (20%)	0.34

ACE – angiotensin-converting enzyme; ARB – angiotensin receptor antagonist; BP – blood pressure; HDL – high-density lipoprotein; LDL – low-density lipoprotein; LVEF – left ventricle ejection fraction; bpm – beats per minute.

Table 3. The utility of CQS analysis and the resting 12-lead ECG for the detection of coronary artery disease, compared against coronary artery angiography as the reference standard.

	Sensitivity	Specificity	Accuracy	Positive predictive value	Negative predictive value
ECG	28.0% (23/82)	81.8% (9/11)	34.4% (32/93)	92.0% (23/25)	13.2% (9/68)
CQS	95.1% (78/82)	63.6% (7/11)	91.4% (85/93)	95.1% (78/82)	63.6% (7/11)

CQS – cardiac quantum spectrum analysis; ECG – resting 12-lead electrocardiogram.

Table 4. Agreement between cardiac quantum spectrum analysis and coronary angiography in the evaluation of the severity of coronary artery stenosis.

CQS evaluation scores	Degree of stenosis detected by coronary angiography			Total
	Normal	Low to moderate	Moderate to severe	
Normal	6	12	3	21
Mild	2	28	10	40
Moderate to severe	0	9	23	32
Total	8	49	36	93

The Kappa value was calculated to be 0.376, P<0.001.

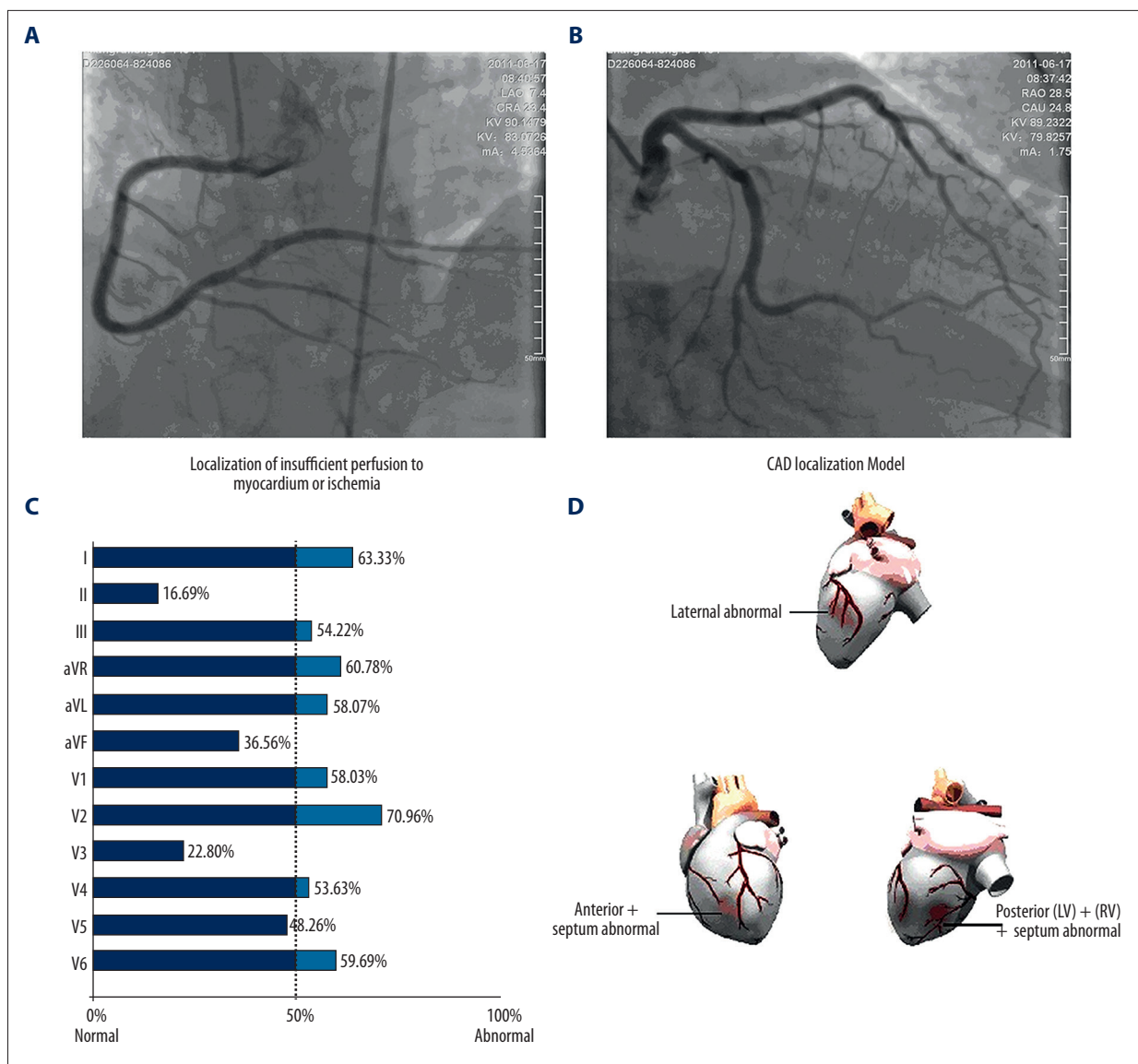


Figure 2. Data from a 46-year-old female diagnosed with acute myocardial infarction. (A, B) The coronary angiography results indicated that the degree of stenosis was not severe. (C) Detection of abnormalities in the signals from the various ECG leads, indicative of insufficient perfusion to the myocardium or myocardial ischemia. Note that abnormalities were detected in numerous leads, despite the lack of severe stenosis on coronary angiography. (D) The 3D model of coronary artery disease generated by CQS analysis of the data in panel C allowed localization of insufficient myocardial perfusion or ischemia to specific regions of the heart, providing important information about the coronary vessels underlying the inadequate perfusion.

Advantages of the CQS technique in the diagnosis of coronary artery disease

The sensitivity of the CQS method for the identification of CAD was far superior to that of the standard 12-lead ECG, suggesting that CQS analysis could potentially improve the early diagnosis of myocardial ischemia. The CQS technique showed good agreement with coronary angiography, consistent with previous results [3,4]. The CQS disease evaluation score, obtained

by combining the CQS data with other coronary heart disease risk factors, showed reasonable correlation with the degree of coronary artery stenosis identified by angiography, although this could potentially be improved by further studies designed to optimize the calculation of the CQS evaluation score. An important advantage of CQS analysis may be the early diagnosis of CAD, especially since this technique can potentially detect minor pathologic changes that result on only small decreases in myocardial perfusion. Furthermore, by employing

mathematical analyses of different leads and quantum spectra, the CQS method can preliminarily identify the range and location of myocardial ischemia and hence identify which coronary vessels show stenosis; this represents important information that is of great relevance to subsequent coronary interventional therapy.

Although coronary angiography is regarded as the “gold standard” in the diagnosis of CAD, it is nonetheless limited in that the anatomic degree of stenosis does not always equate with the extent of the myocardial ischemia or cardiac dysfunction [7,8]. CQS can reflect the changes in myocardial function, and in most patients diagnosed as positive by CQS analysis, the CQS risk level showed good correlation with the degree of coronary stenosis. Furthermore, CQS analysis was able to identify all seven patients who exhibited the coronary slow flow phenomenon and had mild stenosis on angiography, indicating that this noninvasive technique has the potential to detect ischemic changes in the heart that occur in the absence of severe coronary artery stenosis. In two patients with clinically confirmed myocardial infarction, CQS analysis was able to successfully identify previous myocardial injury or scarring (shown by a depressed main peak in the frequency power spectrum, and the combination of P51 and P21 abnormalities i.e. peaks 5 and 2 in the frequency power spectrum were higher than peak 1, which should not be the case), whereas coronary angiography showed no or only very mild coronary artery stenosis (Figure 2). The patient described in Figure 2 had experienced a previous acute myocardial infarction, but the thrombus had been successfully dissolved by pharmacologic therapy. Consequently, coronary angiography did not identify any major pathological changes of the coronary arteries. Therefore, the CQS technique may have certain advantages in the diagnosis of CAD from the perspective of identifying disturbances in myocardial function. In addition, since the CQS is a 90-sec ECG, all conventional ECG measurements can be obtained from the CQS data.

Disadvantages of the CQS technique

Compared with coronary angiography, CQS analysis has a relatively low specificity for the diagnosis of CAD. Indeed, the CQS technique failed to diagnose two of the eight patients with three-vessel CAD. A possible reason for this is that CQS reflects deviations from the normal electrical activity of the heart as a whole, such that insufficient blood flow to multiple regions of the heart secondary to three-vessel CAD may result in only small deviations between the various regions, precluding CQS analysis from detecting an abnormality. Thus, further development of this technique is warranted to improve its specificity.

Exploration of the clinical application of CQS analysis

The CQS technique, used in combination with other traditional noninvasive investigations, could potentially be applied in the clinic to identify patients suitable for coronary angiography. CQS analysis could potentially play an even greater role in the noninvasive screening and examination of coronary heart disease. Although coronary angiography provides important information about coronary artery vascular morphology, CQS analysis may be capable of identifying myocardial ischemia in asymptomatic patients. Furthermore, in patients who undergo coronary artery stenting, the CQS method could be used to evaluate noninvasively the improvement in myocardial blood supply after surgery, and thus could play a beneficial role in long-term prognosis and follow-up.

Limitations

This study is not without limitations. The sample size was relatively small. In addition, since we only recruited patients with symptoms of CAD, only a small number of patients with normal angiography were recruited. Additional studies are necessary to validate these results.

Conclusions

The participants in this study were all patients with a preliminary clinical diagnosis of CAD. This may have introduced a certain level of positive bias, as comparison with an asymptomatic cohort was not undertaken. This could also have contributed to the low specificity of CQS analysis, as compared with coronary angiography. In future studies, it would be useful to include other indices of myocardial ischemia and function, such as fractional flow reserve (FFR), myocardial scintigraphy, and myocardial MRI, to further explore the value of the CQS technique in the prediction of myocardial ischemia.

Acknowledgements

The authors thank for the statistics analysis accomplished by Pro. Zhao YuSheng and instrument supported by the Biophysics Laboratory.

Conflict of interest

The authors declare that they have no conflict of interest.

References:

1. Salerno SM, Alguire PC, Waxman HS: Competency in interpretation of 12-lead electrocardiograms: a summary and appraisal of published evidence. *Ann Intern Med*, 2003; 138: 751–60
2. Ammar KA, Kors JA, Yawn BP, Rodeheffer RJ: Defining unrecognized myocardial infarction: a call for standardized electrocardiographic diagnostic criteria. *Am Heart J*, 2004; 148: 277–84
3. Anthony D: Diagnosis and screening of coronary artery disease. *Prim Care*, 2005; 32: 931–46
4. Esunge PM, Jin HK, Hassan H et al: Improved ECG interpretation using the early ECG multiphase diagnostic system for angina and myocardial infarction. International Congress IX on Endovascular Interventions, Arizona Heart Institute Foundation. Arizona February, 1997; 1–13
5. Puddu PE, Schiariti M, Ciavarella GM, Dan QF: Frequency-domain analysis of left ventricular hypertrophy by cerebrotocardiogram is an accurate new tool. *Ital Heart J*, 2004; 5: 178–84
6. Noera G, Oueida F: Cardiac ultra-phase information diagnosis (CUPID): New method and instrumentation, new possibilities for early diagnosis of coronary artery disease in the elderly. *J Arterioscler*, 1999; 24: 81–84
7. Tonino PA, Fearon WF, De Bruyne B et al: Angiographic versus functional severity of coronary artery stenoses in the FAME study: Fractional flow reserve versus angiography in multivessel evaluation. *J Am Coll Cardiol*, 2010; 55: 2816–21
8. Tonino PA, De Bruyne B, Pijls NH et al: Fractional flow reserve versus angiography for guiding percutaneous coronary intervention. *N Engl J Med*, 2009; 360: 213–24