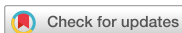

Research Article
Implant Science



A retrospective comparison of 3 approaches of vestibuloplasty around mandibular molar implants: apically positioned flap versus free gingival graft versus modified periosteal fenestration

Won-Pyo Lee , Kyoung-Hoon Lee , Sang-Joun Yu , Byung-Ock Kim *

Department of Periodontology, School of Dentistry, Chosun University, Gwangju, Korea



Received: Nov 19, 2020
Revised: May 16, 2021
Accepted: May 28, 2021

*Correspondence:

Byung-Ock Kim

Department of Periodontology, School of Dentistry, Chosun University, 309 Pilmun-daero, Dong-gu, Gwangju 61452, Korea.
E-mail: bobkim@chosun.ac.kr
Tel: +82-62-220-3850
Fax: +82-62-224-4664

Copyright © 2021. Korean Academy of Periodontology
This is an Open Access article distributed under the terms of the Creative Commons Attribution Non-Commercial License (<https://creativecommons.org/licenses/by-nc/4.0/>).

ORCID iDs

Won-Pyo Lee
<https://orcid.org/0000-0003-1911-3454>
Kyoung-Hoon Lee
<https://orcid.org/0000-0003-1445-2692>
Sang-Joun Yu
<https://orcid.org/0000-0001-8818-549X>
Byung-Ock Kim
<https://orcid.org/0000-0001-8952-617X>

Funding

This study was supported by a research fund from Chosun University, 2018.

Author Contributions

Conceptualization: Won-Pyo Lee; Formal analysis: Kyoung-Hoon Lee; Investigation: Kyoung-Hoon Lee; Methodology: Won-Pyo Lee; Project administration: Won-Pyo Lee,

ABSTRACT

Purpose: This study aimed to clinically evaluate the efficacy of vestibuloplasty around lower molar implants using 3 different modalities: apically positioned flap alone (APF), APF with a free gingival graft (FGG), and APF with modified periosteal fenestration (mPF).

Methods: Three different vestibuloplasty procedures during second-stage implant surgery were performed at the mandibular molar area in 61 patients with a shallow vestibule and insufficient keratinized tissue (KT). The clinical measurements of KT width were recorded at baseline, immediately after surgery (T0), 6 months after surgery (T6), and 12 months after surgery (T12). Soft tissue esthetic scores were measured.

Results: An additional KT width gain from baseline to T12 of approximately 2 mm was obtained with FGG and mPF compared to that with APF. Shrinkage of the re-established tissue was lower with mPF and FGG than with APF, whereas the esthetic profile was better with APF and mPF than with FGG.

Conclusions: Within the limitations of this study, mPF showed potential as a promising approach for vestibuloplasty around the lower molar implants compared to the traditional APF and FGG.

Keywords: Dental implants; Retrospective study; Vestibuloplasty

INTRODUCTION

Many studies have focused on the relationship between the width of keratinized tissue (KT) and peri-implant health. Several reports have presented associations between improved esthetic results, peri-implant health, implant survival, and adequate KT width [1-3]. However, other reports have found that there were minimal or no associations among involution of the peri-implant tissue, implant survival, and the width of KT [4,5]. Therefore, the association between KT width and peri-implant health remains controversial, although insufficient KT width was found to be correlated with a shallow vestibule [6-8]. Management of oral hygiene in patients with inadequate KT width or a shallow vestibule at the molar area could result in severe plaque accumulation, and consequently, a higher prevalence of peri-implant mucositis and peri-implantitis [9,10].

Sang-Joun Yu, Byung-Ock Kim; Writing - original draft: Won-Pyo Lee; Writing - review & editing: Kyoung-Hoon Lee, Sang-Joun Yu, Byung-Ock Kim.

Conflict of Interest

No potential conflict of interest relevant to this article was reported.

Various vestibuloplasty procedures to attain adequate vestibular depth and KT width have been introduced, the most common of which are the apically positioned flap (APF) [11] and APF combined with a free gingival graft (FGG) [12]. APF is a relatively simple technique that does not involve a secondary donor site; however, it has the disadvantage of an increased risk of relapse due to wound contraction [13]. FGG is the most common mucogingival surgical procedure used to increase KT width [14], but it involves a secondary donor site for supplying the graft, which increases the patient's discomfort, operation time, and risk of complications [15].

In the 1960s, various periosteal fenestration techniques were introduced to overcome the tendency of relapse after APF and to increase the KT width [16-18]. Yadav et al. [19] reported that periosteal fenestration in a patient with narrow KT and shallow vestibule around the mandibular anterior teeth achieved results comparable to those with FGG. Recently, Lee and Kwon [20] reported that the modified periosteal fenestration (mPF) procedure, which builds upon the traditional method suggested by Corn [17], could be an alternate treatment modality for vestibuloplasty around dental implants.

The current retrospective study aimed to compare the clinical outcomes of 3 approaches—APF only, FGG, and mPF—around lower molar implants.

MATERIALS AND METHODS

Study design

This was a retrospective cohort study; patients who visited the Department of Periodontology of Chosun University Dental Hospital between January 2014 and December 2018 were screened according to the selection criteria. The inclusion criteria were as follows: 1) patients who underwent treatment with APF, APF with FGG, or APF with mPF along with second-stage implant surgery at the mandibular molar sites; 2) patients with a shallow vestibule and insufficient KT width (≤ 2 mm in the apico-coronal direction from the middle crest) at baseline, and 3) patients whose KT width measurements were recorded on the electronic medical record (EMR) chart and whose clinical pictures were taken during the postoperative follow-up period. In total, 61 patients (23 men and 38 women) aged between 35 and 79 years (mean age, 58.7 ± 10.4 years) were identified. Each patient was allocated to the APF, FGG, or mPF group according to the vestibuloplasty procedure performed. The research protocol was approved by the Institutional Review Board of Chosun University Dental Hospital (CUDHIRB-1806-004).

Surgical procedure

All vestibuloplasty procedures during second-stage implant surgery were performed by an experienced periodontal surgeon (WPL). In the APF group, intra-oral gargling with 0.1% chlorhexidine solution (Hexamedine solution, Bukwang Pharm. Co., Seoul, Korea) was performed 1 minute prior to surgery. Under local anesthesia, a partial-thickness flap was prepared with a 1-mm width of KT at the coronal boundary of the APF, if possible. Periosteal sutures were used to stabilize the apical region. Subsequently, an inner mucoperiosteal flap was elevated from the alveolar ridge or the punching technique was performed to fix the healing abutment to the implant fixture. After fixation, the buccolingual full-thickness flap was secured with interrupted sutures if needed. In the FGG group, 1.5-mm-thick FGG was harvested from the palate after preparation of the periosteal recipient bed as in the APF group. FGG was secured at the recipient site with interrupted sutures and crossed mattress sutures. After stabilizing the graft, a wet gauze was firmly applied for several minutes to

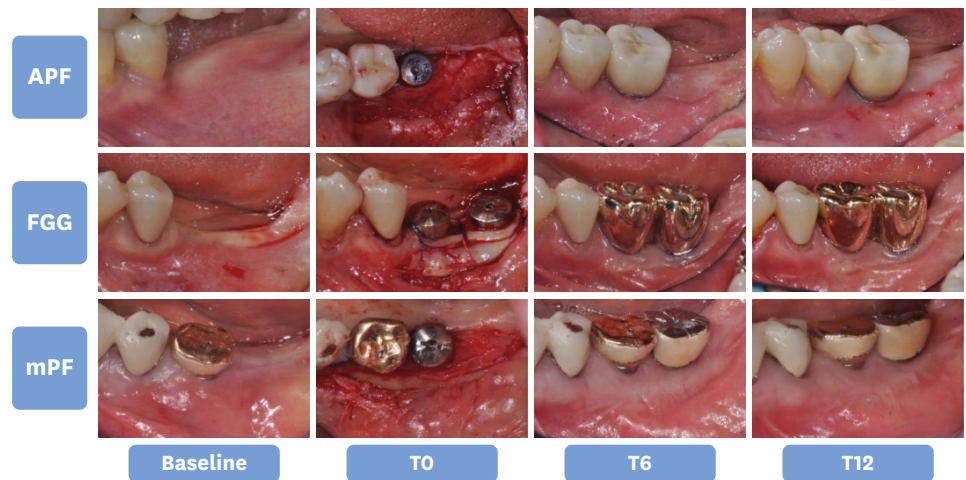


Figure 1. Representative clinical photographs at each measurement time point for each group. APF: apically positioned flap, FGG: free gingival graft, mPF: modified periosteal fenestration, T0: immediately after surgery, T6: 6 months after surgery, T12: 12 months after surgery.

allow only a thin layer of fibrin clot under the donor tissue. In the mPF group, the same procedure as in the APF group was performed. Subsequently, a horizontal parallel periosteal fenestration incision was made from the coronal border of the APF toward the crown of the tooth at 2 mm, using a No. 15c blade. A full-thickness flap was elevated in the apical direction with a periosteal elevator from the incision site to create an osseous exposure of ≥ 2 mm in the form of a linear island of denuded bone (Figure 1). The wound was covered with a resorbable periodontal pack (Reso-Pac®, Hager & Werken GmbH & Co. KG, Duisburg, Germany).

After surgery, the patients were instructed to gargle with 0.1% chlorhexidine solution twice daily for 2 weeks. Additionally, antibiotics (Augmentin [625 mg], Ilsung Pharm. Co., Seoul, Korea) 3 times daily and analgesics (aceclofenac [100 mg], Dong-A ST, Seoul, Korea) twice daily for 1 week were prescribed. The non-absorbable sutures were removed after 7 days.

Outcome measures

KT width

In this study, KT width was defined as the distance from the mucogingival junction (MGJ) to the free KT margin [21]. At baseline, KT width was defined as the distance from the MGJ to the middle crest. In each implant crown, KT width was measured at the mid-buccal level using a periodontal probe (UNC 15, Osung MND Co., Seoul, Korea) with a 1-mm gradation. The measurement values were obtained at baseline, immediately after surgery (T0), 6 months after surgery (T6), and 12 months after surgery (T12) by a single clinician (WPL). The MGJ was identified by the rolling technique comprised of rolling the mucosa until the non-movable part of the KT was visualized. Each patient was regarded as a statistical unit for each statistical analysis. The mean KT width was calculated at each time point (baseline, T0, T6, and T12). KT width gain from baseline was defined as the difference in KT width between baseline and each time point. In addition, the percentage of KT width relative to T0 (100%) and shrinkage rate (%) of KT width relative to T0 (0%) were calculated [13].

Evaluation of esthetics

Color matching, contour, and texture were evaluated on clinical photographs acquired at T12 by 2 independent investigators (WPL and KHL). The scoring method of Lim et al. [22], which

Table 1. Demographic and clinical characteristics of the study population

Characteristics	APF group (n = 19)	FGG group (n = 20)	mPF group (n = 22)
Age (yr)	59.5±10.9	58.2±11.5	58.5±9.4
Sex (male/female)	6/13	7/13	10/12
Implant sites (first molar/second molar)	27 (19/8)	30 (19/11)	33 (22/11)

Data are expressed as mean±standard deviation.

APF: apically positioned flap, FGG: free gingival graft, mPF: modified periosteal fenestration.

comprises 4 grades (1, poor; 2, fair; 3, good; and 4, perfect) was used. Both investigators performed calibration before the assessment using 5 randomly selected clinical photographs. Cohen's kappa was calculated for all parameters, and a kappa value of 0.656 was considered to indicate moderate agreement according to the revised interpretation of Cohen's kappa proposed by McHugh [23].

Statistical analysis

Quantitative parameters were expressed as mean±standard deviation and median. Data analysis was performed using SPSS software (version 20.2, IBM Corp., Armonk, NY, USA). The Shapiro-Wilk test was used for the normality of data distribution. The Kruskal-Wallis test was used for intergroup comparisons, and the Wilcoxon signed-rank test was used for intragroup comparisons (T0 vs. T6; T6 vs. T12). The Bonferroni correction was used as a *post hoc* test, and the Mann-Whitney *U* test was used repeatedly. The χ^2 test was used to evaluate intergroup differences in soft-tissue esthetic scores. Pairwise comparisons were performed using the Fisher exact test with the Bonferroni correction (0.05/3 = 0.0167). A *P* value <0.05 was considered to indicate statistical significance. The methodology was reviewed by an independent statistician.

RESULTS

Of the 61 patients (90 sites), 19 (27 sites), 20 (30 sites), and 22 (33 sites) patients were included in the APF, FGG, and mPF groups, respectively (Table 1). In the course of the study, wound healing was uneventful in all groups.

Change of KT width

The KT width data are presented in Table 2. At baseline, KT width was 1.21±0.42, 1.13±0.36, and 1.05±0.53 mm in the APF, FGG, and mPF groups, respectively. No statistically significant

Table 2. Quantitative (mm) change of KT width in the APF, FGG, and mPF groups

Variables	APF group (n = 19)	<i>P</i> value	FGG group (n = 20)	<i>P</i> value	mPF group (n = 22)	<i>P</i> value
Baseline (mm)	1.21±0.42 (1.00)		1.13±0.36 (1.00)		1.05±0.53 (1.00)	
<i>P</i> value	0.708 (vs. FGG)		0.708 (vs. APF)		0.332 (vs. APF)	
	0.332 (vs. mPF)		0.599 (vs. mPF)		0.599 (vs. FGG)	
T0 (mm)	6.24±1.01 (6.00)		6.35±1.01 (6.50)		6.39±0.95 (6.00)	
<i>P</i> value	0.749 (vs. FGG)		0.749 (vs. APF)		0.679 (vs. APF)	
	0.679 (vs. mPF)		0.878 (vs. mPF)		0.878 (vs. FGG)	
T6 (mm)	2.63±0.96 (2.50)	<0.001 (vs. T0)	4.35±1.15 (4.00)	<0.001 (vs. T0)	4.09±1.10 (4.00)	<0.001 (vs. T0)
<i>P</i> value	<0.001 (vs. FGG)		<0.001 (vs. APF)		<0.001 (vs. APF)	
	<0.001 (vs. mPF)		0.600 (vs. mPF)		0.600 (vs. FGG)	
T12 (mm)	1.72±0.79 (2.00)	<0.001 (vs. T6)	3.65±1.09 (3.50)	0.001 (vs. T6)	3.52±1.02 (3.00)	0.001 (vs. T6)
<i>P</i> value	<0.001 (vs. FGG)		<0.001 (vs. APF)		<0.001 (vs. APF)	
	<0.001 (vs. mPF)		0.669 (vs. mPF)		0.669 (vs. FGG)	

Data are expressed as mean±standard deviation (median).

KT: keratinized tissue, APF: apically positioned flap, FGG: free gingival graft, mPF: modified periosteal fenestration, T0: immediately after surgery, T6: 6 months after surgery, T12: 12 months after surgery.

differences were observed among the groups. At T0, KT width due to surgical interventions was 6.24 ± 1.01 , 6.35 ± 1.01 , and 6.39 ± 0.95 mm in the APF, FGG, and mPF groups, respectively. No statistically significant differences were observed among the groups.

A trend of decrease in KT width was observed at T6 and T12, and with regard to intragroup changes in KT width, the decrease in KT width between each time point was statistically significant in all groups.

At T12, KT width was 1.72 ± 0.79 , 3.65 ± 1.09 , and 3.52 ± 1.02 mm in APF, FGG, and mPF groups, respectively, with statistically significant differences between the APF group and other groups. The relative change in KT width was $28.85\% \pm 14.69\%$ for the APF group, $57.05\% \pm 11.84\%$ for the FGG group, and $55.76\% \pm 15.89\%$ for mPF. This indicates that the APF group achieved a significant loss of the re-established tissue as compared to the other groups. However, no statistically significant difference was observed between the FGG and mPF groups. A similar trend was observed at T6 (Figure 2).

Evaluation of esthetics

The esthetic data for all subjects are presented in Table 3. After 12 months of healing, the esthetic scores of the re-established tissue were lower in the FGG group than in the other groups in terms of color, contour, and texture. However, an overall excellent esthetic score was attained in the APF group, and a comparable score was attained in the mPF group except for texture.

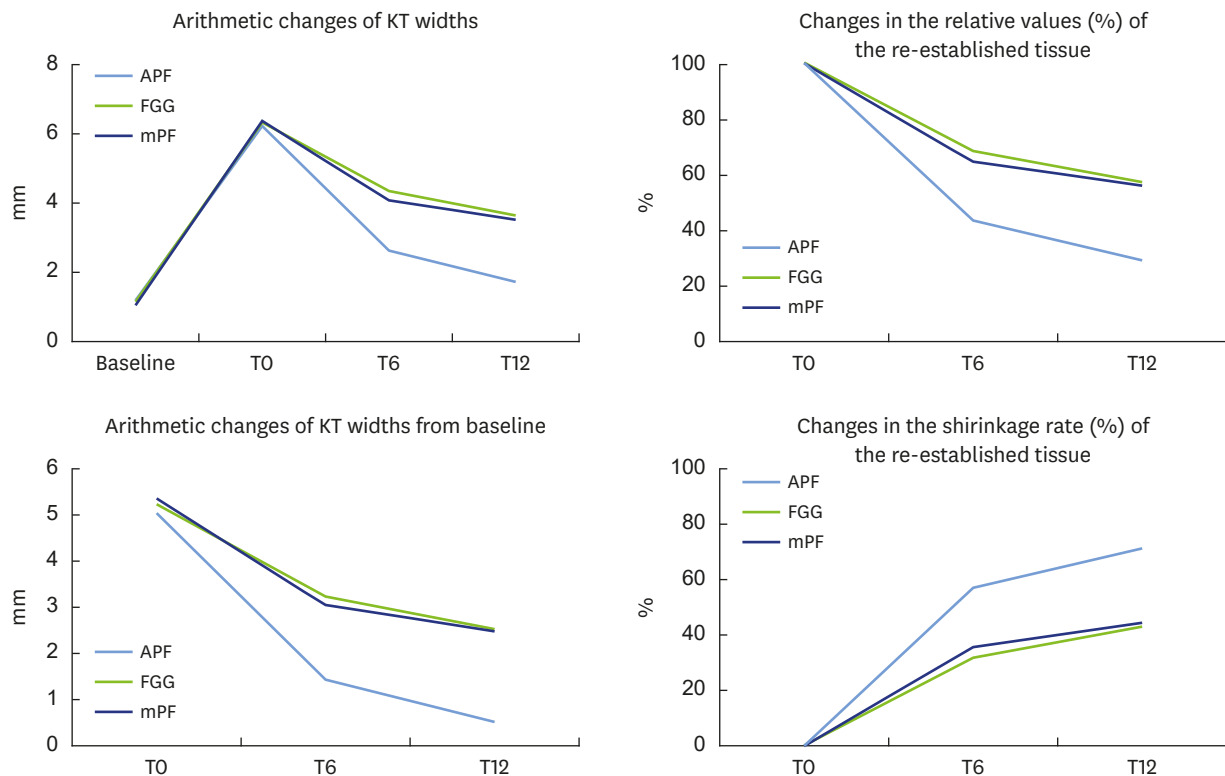


Figure 2. Changes in KT width in the APF, FGG, and mPF groups.

KT: keratinized tissue, APF: apically positioned flap, FGG: free gingival graft, mPF: modified periosteal fenestration, T0: immediately after surgery, T6: 6 months after surgery, T12: 12 months after surgery.

Table 3. Soft tissue esthetic scores

Variables	APF group	FGG group	mPF group
Color	3.4±0.5	2.3±0.7	3.3±0.7
<i>P</i> value	<0.001 (vs. FGG) 0.577 (vs. mPF)	<0.001 (vs. APF) <0.001 (vs. mPF)	0.577 (vs. APF) <0.001 (vs. FGG)
Contour	2.9±0.6	2.0±0.7	2.7±0.7
<i>P</i> value	0.001 (vs. FGG) 0.461 (vs. mPF)	0.001 (vs. APF) 0.006 (vs. mPF)	0.461 (vs. APF) 0.006 (vs. FGG)
Texture	2.6±0.5	1.8±0.6	2.0±0.6
<i>P</i> value	<0.001 (vs. FGG) 0.002 (vs. mPF)	<0.001 (vs. APF) 0.182 (vs. mPF)	0.002 (vs. APF) 0.182 (vs. FGG)

Data are expressed as mean±standard deviation.

APF: apically positioned flap, FGG: free gingival graft, mPF: modified periosteal fenestration.

DISCUSSION

This study retrospectively evaluated the effectiveness of 3 approaches of vestibuloplasty (APF only, FGG, and mPF) to increase the KT width around lower molar implants. To the best of our knowledge, this is the first study to report the results of a comparison of these 3 modalities. Moreover, we focused on the clinical and patient benefits of mPF [20], which we recommend over conventional APF alone and FGG. At the 12-month follow-up, the mPF group showed a significantly lower likelihood of relapse of the re-established tissue than the APF group. In addition, although mPF is a simpler and quicker surgical procedure than FGG, the mPF group showed comparable changes in KT width to the other groups and achieved superior esthetic outcomes as compared to the FGG group.

Earlier studies reported that APF alone resulted in minimum KT gain because of high wound contraction and muscle reattachment [14]. Basegmez et al. reported a gain of 2 mm at 3 months after surgery with APF, which subsequently decreased to 1.15 mm after 12 months [24]. Lim et al. [22] reported that APF achieved a shrinkage rate of 65% at T12. Our results indicated an approximately 0.5-mm increase in KT width from baseline and a 71% shrinkage rate at 12 months after surgery with APF (Figure 2). In the present study, the proximity of the buccinator muscle insertion to the recipient site may have been a contributing factor to relapse, as it included only the lower molar sites with shallow vestibules [22,25].

Conversely, APF combined with FGG [13,22,24] or periosteal fenestration techniques [16-18] achieved higher KT gains. In this study, the mPF group achieved an increase in the KT width of 2.5 mm at baseline and a shrinkage rate of approximately 44% after 12 months of healing. This indicates that by adding a simple procedure such as mPF to APF, the additional KT width gain increased by approximately 2 mm, with a reduction in the tendency to relapse (Figure 2). Despite no clear conclusion on the clinical benefits of gaining greater KT, investigators should consider using a minimum KT width of 2 mm [26-28]. mPF achieved an additional 2 mm gain in KT width compared to APF alone, and this finding may have important clinical implications in implant dentistry. Moreover, the FGG group showed a similar tendency to the mPF group.

FGG has been considered the gold standard based on its high success rate, predictability, and a lack of comparable alternatives [13,29,30]. However, as presented in Table 3, the FGG group showed a less favorable esthetic tissue profile of color, contour, and texture than the other groups [22]. To overcome this, Urban et al. [31] conducted vestibuloplasty with a combined strip gingival graft at the apical part of the recipient bed and a xenogenic collagen matrix

at the coronal level. The strip gingival graft at the apical part of the recipient bed acted as a mechanical barrier against mucosal and/or muscular re-attachment similar to the role of scar formation in periosteal fenestration surgery. In our study, the mPF procedure achieved a comparable esthetic outcome to that of the APF group, except for texture. This suggests that mPF is an effective potential alternative to the conventional FGG procedure, especially in cases of implantation at the posterior maxilla that present with difficulty in periosteal suturing, or at the anterior region, which has a high esthetic impact.

This study has some limitations inherent to its retrospective design. The selection of the patient population may have been biased. There was no control over other conditions that affect the results of soft tissue healing, such as the soft tissue phenotype. A surgical stent was not used to reproduce clinical measurements made using a periodontal probe, which may affect the reliability of the measurements. A prospective clinical study with a robust design is needed to confirm the findings of the present study.

Within the study's limitations, mPF achieved an additional KT width gain of approximately 2 mm and showed a lower tendency for relapse after vestibuloplasty around molar implants in comparison to APF alone. Compared to the FGG procedure, mPF was simpler to perform and showed superior esthetic outcomes, but a comparable change of KT width. For vestibuloplasty around lower molar implants, mPF is a potential alternative treatment modality to conventional APF alone or FGG procedures.

ACKNOWLEDGEMENTS

The authors thank Dong-Su Lee (Professor, Department of Computer Science and Statistics, Chosun University, Gwangju, Korea) for statistical consulting and some of the data analysis.

REFERENCES

1. Longoni S, Tinto M, Pacifico C, Sartori M, Andreano A. Effect of peri-implant keratinized tissue width on tissue health and stability: systematic review and meta-analysis. *Int J Oral Maxillofac Implants* 2019;34:1307-17.
[PUBMED](#) | [CROSSREF](#)
2. Kungsadalpipob K, Supanimitkul K, Manopattanasoontorn S, Sophon N, Tangsathian T, Arunyanak SP. The lack of keratinized mucosa is associated with poor peri-implant tissue health: a cross-sectional study. *Int J Implant Dent* 2020;6:28.
[PUBMED](#) | [CROSSREF](#)
3. Tavelli L, Barootchi S, Avila-Ortiz G, Urban IA, Giannobile WV, Wang HL. Peri-implant soft tissue phenotype modification and its impact on peri-implant health: a systematic review and network meta-analysis. *J Periodontol* 2021;92:21-44.
[PUBMED](#) | [CROSSREF](#)
4. Dalago HR, Schuldt Filho G, Rodrigues MA, Renvert S, Bianchini MA. Risk indicators for peri-implantitis. A cross-sectional study with 916 implants. *Clin Oral Implants Res* 2017;28:144-50.
[PUBMED](#) | [CROSSREF](#)
5. Romandini M, Lima C, Pedrinaci I, Araoz A, Soldini MC, Sanz M. Prevalence and risk/protective indicators of peri-implant diseases: a university-representative cross-sectional study. *Clin Oral Implants Res* 2021;32:112-22.
[PUBMED](#) | [CROSSREF](#)
6. Allen PF, McMillan AS. A longitudinal study of quality of life outcomes in older adults requesting implant prostheses and complete removable dentures. *Clin Oral Implants Res* 2003;14:173-9.
[PUBMED](#) | [CROSSREF](#)

7. Heberer S, Nelson K. Clinical evaluation of a modified method of vestibuloplasty using an implant-retained splint. *J Oral Maxillofac Surg* 2009;67:624-9.
[PUBMED](#) | [CROSSREF](#)
8. Kao SY, Yeung TC, Hung KF, Chou IC, Wu CH, Chang RC. Transpositioned flap vestibuloplasty combined with implant surgery in the severely resorbed atrophic edentulous ridge. *J Oral Implantol* 2002;28:194-9.
[PUBMED](#) | [CROSSREF](#)
9. Lin GH, Chan HL, Wang HL. The significance of keratinized mucosa on implant health: a systematic review. *J Periodontol* 2013;84:1755-67.
[PUBMED](#) | [CROSSREF](#)
10. Halperin-Sternfeld M, Zigdon-Giladi H, Machtei EE. The association between shallow vestibular depth and peri-implant parameters: a retrospective 6 years longitudinal study. *J Clin Periodontol* 2016;43:305-10.
[PUBMED](#) | [CROSSREF](#)
11. Friedman N. Mucogingival surgery: the apically repositioned flap. *J Periodontol* 1962;33:328-40.
[CROSSREF](#)
12. Björn H. Free transplantation of gingival propria. *Odontol Revy* 1963;14:323.
13. Schmitt CM, Moest T, Lutz R, Wehrhan F, Neukam FW, Schlegel KA. Long-term outcomes after vestibuloplasty with a porcine collagen matrix (Mucograft®) versus the free gingival graft: a comparative prospective clinical trial. *Clin Oral Implants Res* 2016;27:e125-33.
[PUBMED](#) | [CROSSREF](#)
14. Hillerup S. Healing reactions of relapse in secondary epithelization vestibuloplasty on dog mandibles. *Int J Oral Surg* 1980;9:116-27.
[PUBMED](#) | [CROSSREF](#)
15. Fröschl T, Kerscher A. The optimal vestibuloplasty in preprosthetic surgery of the mandible. *J Craniomaxillofac Surg* 1997;25:85-90.
[PUBMED](#) | [CROSSREF](#)
16. Robinson R. Periosteal fenestration in mucogingival surgery. *J West Soc Periodont* 1961;9:107-11.
17. Corn H. Periosteal separation—its clinical significance. *J Periodontol* 1962;33:140-53.
[CROSSREF](#)
18. Wilderman MN. Repair after a periosteal retention procedure. *J Periodontol* 1963;34:487-503.
[CROSSREF](#)
19. Yadav N, Khattak BP, Misra S, Sharma A. Comparative evaluation of the relative efficacy of the free mucosal graft and periosteal fenestration for increasing the vestibular depth - a clinical study. *Contemp Clin Dent* 2014;5:366-70.
[PUBMED](#) | [CROSSREF](#)
20. Lee WP, Kwon YS. Vestibuloplasty around dental implants using modified periosteal fenestration (mPF): case series. *Implantology* 2020;24:22-30.
[CROSSREF](#)
21. Thoma DS, Alshihri A, Fontollet A, Hämmerle CHF, Jung RE, Benic GI. Clinical and histologic evaluation of different approaches to gain keratinized tissue prior to implant placement in fully edentulous patients. *Clin Oral Investig* 2018;22:2111-9.
[PUBMED](#) | [CROSSREF](#)
22. Lim HC, An SC, Lee DW. A retrospective comparison of three modalities for vestibuloplasty in the posterior mandible: apically positioned flap only vs. free gingival graft vs. collagen matrix. *Clin Oral Investig* 2018;22:2121-8.
[PUBMED](#) | [CROSSREF](#)
23. McHugh ML. Interrater reliability: the kappa statistic. *Biochem Med (Zagreb)* 2012;22:276-82.
[PUBMED](#) | [CROSSREF](#)
24. Başeğmez C, Ersanli S, Demirel K, Bölükbasi N, Yalcin S. The comparison of two techniques to increase the amount of peri-implant attached mucosa: free gingival grafts versus vestibuloplasty. One-year results from a randomised controlled trial. *Eur J Oral Implantology* 2012;5:139-45.
[PUBMED](#)
25. Eufinger H, Gellrich NC, Sandmann D, Dieckmann J. Descriptive and metric classification of jaw atrophy. An evaluation of 104 mandibles and 96 maxillae of dried skulls. *Int J Oral Maxillofac Surg* 1997;26:23-8.
[PUBMED](#) | [CROSSREF](#)
26. Ueno D, Nagano T, Watanabe T, Shirakawa S, Yashima A, Gomi K. Effect of the keratinized mucosa width on the health status of periimplant and contralateral periodontal tissues: a cross-sectional study. *Implant Dent* 2016;25:796-801.
[PUBMED](#) | [CROSSREF](#)

27. Chiu YW, Lee SY, Lin YC, Lai YL. Significance of the width of keratinized mucosa on peri-implant health. *J Chin Med Assoc* 2015;78:389-94.
[PUBMED](#) | [CROSSREF](#)
28. Schrott AR, Jimenez M, Hwang JW, Fiorellini J, Weber HP. Five-year evaluation of the influence of keratinized mucosa on peri-implant soft-tissue health and stability around implants supporting full-arch mandibular fixed prostheses. *Clin Oral Implants Res* 2009;20:1170-7.
[PUBMED](#) | [CROSSREF](#)
29. Bassetti RG, Stähli A, Bassetti MA, Sculean A. Soft tissue augmentation around osseointegrated and uncovered dental implants: a systematic review. *Clin Oral Investig* 2017;21:53-70.
[PUBMED](#) | [CROSSREF](#)
30. Thoma DS, Buranawat B, Hämmerle CH, Held U, Jung RE. Efficacy of soft tissue augmentation around dental implants and in partially edentulous areas: a systematic review. *J Clin Periodontol* 2014;41 Suppl 15:S77-91.
[PUBMED](#) | [CROSSREF](#)
31. Urban IA, Lozada JL, Nagy K, Sanz M. Treatment of severe mucogingival defects with a combination of strip gingival grafts and a xenogeneic collagen matrix: a prospective case series study. *Int J Periodontics Restorative Dent* 2015;35:345-53.
[PUBMED](#) | [CROSSREF](#)