

A Clinico-Pathologic Study of 82 Intraoral Minor Salivary Gland Tumors

Z Jaafari-Ashkavandi^{1*}, MJ Ashraf², N Afandak³

¹Department of Oral Pathology, School of Dentistry, Shiraz University of medical Sciences, Shiraz, Iran

²Department of Pathology, Khalili Hospital, Shiraz, Iran ³Dentistry School, Shiraz University of medical Sciences, Shiraz, Iran

Abstract

Background: Intraoral minor salivary glands tumors (MSGT) are uncommon, with geographic variations in frequency and distribution. This study analyzed the clinic-pathologic features of these tumors in Shiraz, southern Iran.

Methods: All of cases histopathologically recorded as epithelial MSGT in Pathology Department of Khalili Hospital from 2002 to 2009 were evaluated with regard to patient's age and gender, tumor location and type, retrospectively.

Results: Out of 82 cases of MSGT, 53.7% were benign and 46.3% were malignant. Pleomorphic adenoma and adenoid cystic carcinoma were the most common benign and malignant tumors, respectively. The palate was the most common site of involvement (64.6%). Male to female ratio was 1:1.27. The mean age of the patients was 35.0±17.2 years for benign and 48.8±18.2 years for malignant tumors.

Conclusion: MSGTs in the present study represent many characteristics of other studies. However, our patients who were affected by benign tumors were young.

Keywords: Salivary gland; Minor; Tumor; Iran

Introduction

Minor salivary glands are functional structures located in the submucosa of the upper aerodigestive tract.¹ The importance of the lesions lies in the fact that lesions are more likely to be malignant.² Studies from other countries report that 13.9-51.4% of all salivary gland tumors (SGTs) arise from an intraoral area and 34.7-67.1% of them are benign.³⁻⁶ It was shown that incidence of SGTs is influenced by geographic and racial factors.^{7,8} Up to now, a large series of MSGTs were reported in Iran. The aim of this study was to determine clinic-pathological features of 82 cases of benign and malignant intraoral MSGT in this region.

Materials and Methods

All of 82 histopathological approved cases recorded as epithelial SGT in the oral mucosa and jaws location in Pathology Department of Khalili Hospital, ENT center affiliated to Shiraz University of Medical Sciences in Southern Iran, from 2005 to 2009 were enrolled. Recurrent, metastatic and non-epithelial neoplasms were excluded. The cases were evaluated with regard to patient's age and gender, tumor location and histopathologic type according to the 2005 WHO classification, through a retrospectively review of the patients' medical files. They were analyzed using SPSS software (version 11.5, Chicago, IL, USA).

Results

Among 356 SGTs, 82 cases (23%) were recorded as epithelial SGT in the oral mucosa and jaws. Forty four (53.7%) were benign and 38 cases (46.3%) were

*Correspondence: Zohreh Jaafari-Ashkavandi, DMD, MSc, Department of Oral pathology, School of Dentistry, Shiraz University of Medical Sciences, Shiraz, Iran. Tel: +98-711-6263194, Fax: +98-711-6270325, e-mail: jaafariz@sums.ac.ir
Received: January 10, 2011 Accepted: April 25, 2011

malignant (Table 1). The patients were between 13 to 80 years, with a mean of 41.4±18.9. The palate was the most common site of involvement in both benign and malignant types, corresponding to 64.6% of all cases (Figure 1). Five cases of tumors (7.4%), including one case of pleomorphic adenoma (PA), one case of polymorphous low-grade adenocarcinoma (PLGA) and 3 cases of mucoepidermoid carcinoma (MEC) were centrally located in the maxilla and mandible. Overall male to female (M/F) ratio was 1:1.27. Table 1 shows the type, age and gender distribution of tumors.

Discussion

To the present time, little data is available on the clinic-pathologic presentation of MSGTs in Iran. We

studied these cases in an ENT center during a 5 years period. Among 9700 cases, MSGTs were uncommon, representing 0.84% of all the biopsy specimens. Intraoral MSGTs accounted for 0.28-1.9% of the specimens, as reported by other authors in USA, Japan, Venezuela and Thailand.^{4,9-11}

In our series, malignant neoplasms constituted 46.3% of the cases which is in agreement with the results of the most previous studies.^{5,9,12} However, some have shown a predominance of malignant tumors.^{6,9,13-15} Most of these researches performed in special situations such as cancer registry and cancer treatment centers. In the current study, PA was the most common tumor, representing 43.9% of all and 81.8% of the benign tumors, which is comparable with other series that reported the incidence of this entity from 15.8¹⁴ to 78%¹⁶ of cases (Figure 2).^{2,6,9-11,14,16}

Table 1: Type, age and gender distribution of minor salivary glands^a.

Tumor type	Frequency (%)	M:F	Mean age±SD	Age range
Benign tumors	44 (53.7)	22:22	35±17.25	13-72
PA	36 (43.9)	16:20	34.5±2.7	13-72
Myoepithelioma	7 (8.5)	6:1	39±8.5	19-71
Monomorphic adenoma	1 (1.2)	0:1	23	23
Malignant tumors	38 (46.3)	36:46	48.8±18.1	13-80
MEC	10 (12.2)	3:7	43.7±5.2	15-63
ACC	1 (1.2)	0:1	60	60
AdCC	23 (28.0)	10:13	50.8±4	13-80
ca.ex.PA	1 (1.2)	0:1	67	67
PLGA	3 (3.7)	1:2	41±7.6	26-51
Total	82 (100.0)	58:68	41.4±18.9	13-80

^a PA: pleomorphic adenoma, MEC: mucoepidermoid carcinoma, ACC: acinic cell carcinoma, AdCC: adenoid cystic carcinoma, ca.ex.PA: carcinoma ex pleomorphic adenoma, PLGA: polymorphous low-grade carcinoma

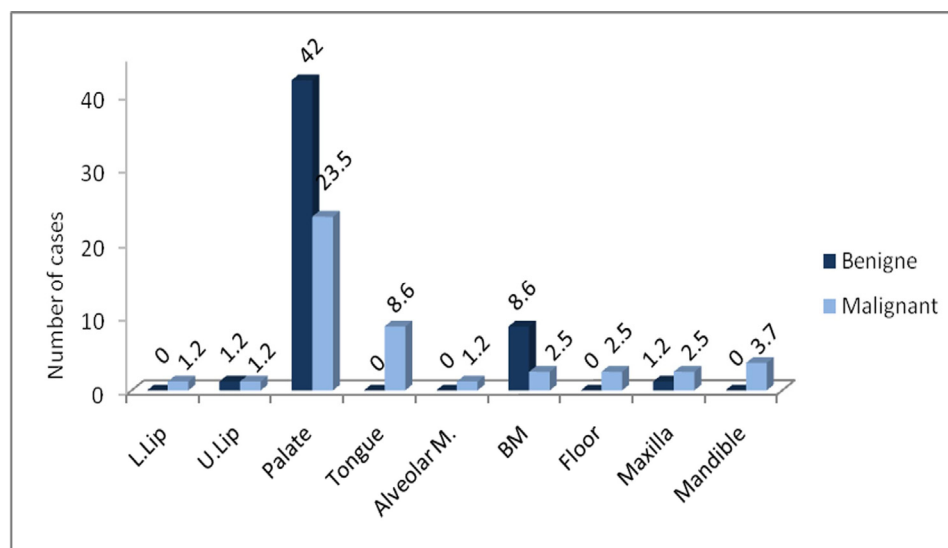


Fig. 1: Location of benign and malignant tumors. L: lower, U: upper, M: mucosa, BM: Buccal mucosa

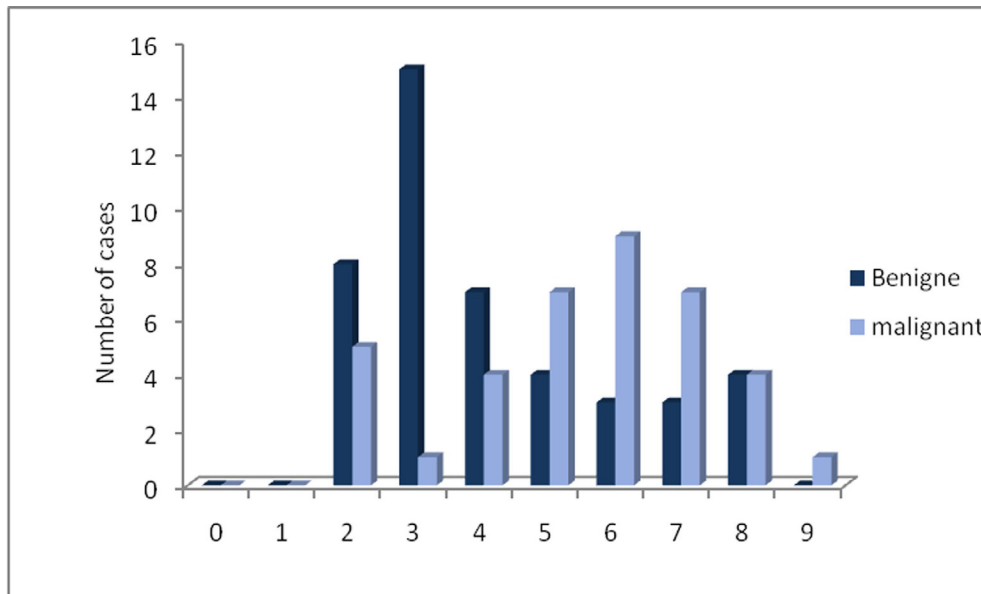


Fig. 2: Incidence of benign and malignant tumors in each decade

Among malignant tumors, Ad CC was the most common. Figure 2 is similar to some reports,^{14,15,17} but the authors in USA, Brazil, Venezuela, Australia, China and Ansari on 18 cases of MSGTs in central Iran, reported that MEC was the most frequent.^{6,10,16,18-21} According to these data, there is a geographic variation in relative frequency of Ad CC versus MEC. However, these two neoplasms are the first and second malignant tumors in the most series.

The palate was the most common site of involvement in our findings (64.6%), followed by buccal mucosa. The palate accounted for 34.6²¹- 82.9%¹¹ of cases in previous studies. This location was the most commonly affected site for both benign and malignant neoplasms, but benign tumors were predominant. This finding is in agreement with other studies.^{3,4,11,20} Our results showed that the tongue (8.5%) and jaws (7.3%) were the next sites. Similar to our findings, Dhanuthai *et al.*, and Jabber *et al.* reported 6.5% and 5.2% of MSGTs in the jaws.^{11,21}

The peak prevalence of benign tumors occurred in the third decade of life and that of malignant types were in the 6th and 7th. Really, the mean age of malignant tumors was 13.8 years later than benign ones. This difference was higher in our population than the previous studies, reporting a range from 2.9 years in Thais to 13.3 years in African population.^{11,22} This finding is due to the fact that in our series, patients

with benign tumors were younger (mean age: 35) while others have stated that the mean age of the affected patients with these neoplasms was from 40 in Chinese to 49 in Japanese.^{3,4}

Overall, the incidence of MSGTs was higher in females (M/F ratio was 1:1.27). This ratio was reported from 1:1.02¹⁵ to 1:2.¹⁰ It has been suggested that gender distribution in SGTs is related to ethnic variations.^{4,22}

In conclusion, in the present population, PA was the most common neoplasm, the palate was the most commonly affected site, and female tendency of MSGTs was seen. Ad.CC was the most common malignancy as some other Asian nations. However, our patients affected by benign tumors were younger. Our findings could help us to perform better diagnosis and early treatment for this group of patients.

Acknowledgment

The Authors would like to thank the Office of Vice Chancellor for Research of Shiraz University of Medical Sciences for language consults. Research performed in: Department of Oral Pathology, School of Dentistry, Shiraz University of Medical Sciences, Shiraz, Iran.

Conflict of interest: None declared.

References

- 1 Ma'a'ita JK, Al-Kaisi N, Al-Tamimi S, Wraikat A. Salivary gland tumors in Jordan: a retrospective study of 221 patients. *Croat Med J* 1999;**40**:539-42. [10554362]
- 2 Beckhardt RN, Weber RS, Zane R, Garden AS, Wolf P, Carrillo R, Luna MA. Minor salivary gland tumors of the palate: clinical and pathologic correlates of outcome. *Laryngoscope* 1995;**105**:1155-60. [7475867] [<http://dx.doi.org/10.1288/00005537-199511000-00003>]
- 3 Wang D, Li Y, He H, Liu L, Wu L, He Z. Intraoral minor salivary gland tumors in a Chinese population: a retrospective study on 737 cases. *Oral Surg Oral Med Oral Pathol Oral Radiol Endod* 2007;**104**:94-100. [17577550] [<http://dx.doi.org/10.1016/j.tripleo.2006.07.012>]
- 4 Toida M, Shimokawa K, Makita H, Kato K, Kobayashi A, Kusunoki Y, Hatakeyama D, Fujitsuka H, Yamashita T, Shibata T. Intra-oral minor salivary gland tumors: a clinico-pathological study of 82 cases. *Int J Oral Maxillofac Surg* 2005;**34**:528-32. [16053873] [<http://dx.doi.org/10.1016/j.ijom.2004.10.010>]
- 5 Auclair PL, Ellis GL, Gnepp DR, Wenig BM, Janney CG. Salivary gland neoplasms: general considerations. In: Ellis GL, Auclair PL, Fnepp DR, eds. *Surgical pathology of the salivary glands*. Philadelphia, PA: W.B. Saunders Co, 1991; p. 135-164.
- 6 Lopes MA, Kowalski LP, da Cunha Santos G, Paes de Almeida O. A clinicopathologic study of 196 intra-oral minor salivary gland tumours. *J Oral Pathol Med* 1999;**28**:264-7. [10426199] [<http://dx.doi.org/10.1111/j.1600-0714.1999.tb02036.x>]
- 7 Vuhahula EA. Salivary gland tumors in Uganda: clinical pathological study. *Afr Health Sci* 2004;**4**:15-23. [15126188]
- 8 Kayembe MK, Kalengayi MM. Salivary gland tumours in Congo (Zaire). *Odontostomatol Trop* 2002;**25**:19-22. [12430350]
- 9 Buchner A, Merrell PW, Carpenter WM. Relative frequency of intra-oral minor salivary gland tumors: a study of 380 cases from northern California and comparison to reports from other parts of the world. *J Oral Pathol Med* 2007;**36**:207-14. [17391298] [<http://dx.doi.org/10.1111/j.1600-0714.2007.00522.x>]
- 10 Rivera-Bastidas H, Ocanto RA, Acevedo AM. Intra-oral minor salivary gland tumors: a retrospective study of 62 cases in a Venezuelan population. *J Oral Pathol Med* 1996;**25**:1-4. [8850349] [<http://dx.doi.org/10.1111/j.1600-0714.1996.tb01214.x>]
- 11 Dhanuthai K, Boonadulyarat M, Jaengjongdee T, Jirudee K. A clinico-pathologic study of 311 intra-oral salivary gland tumors in Thais. *J Oral Pathol Med* 2009;**38**:495-500. [19594840] [<http://dx.doi.org/10.1111/j.1600-0714.2009.00791.x>]
- 12 Eveson JW, Cawson RA. Salivary gland tumors. A review of 2410 cases with particular reference to histological types, site, age and sex distribution. *J Pathol* 1985;**146**:51-8. [4009321] [<http://dx.doi.org/10.1002/path.1711460106>]
- 13 Luna MA, Stimson PG, Bardwil JM. Minor salivary gland tumors of the oral cavity. A review of sixty-eight cases. *Oral Surg Oral Med Oral Pathol* 1968;**25**:71-86. [5235660] [[http://dx.doi.org/10.1016/0030-4220\(68\)90201-6](http://dx.doi.org/10.1016/0030-4220(68)90201-6)]
- 14 Spiro RH, Koss LG, Hajdu SI, Strong EW. Tumors of minor salivary origin. A clinicopathologic study of 492 cases. *Cancer* 1973;**31**:117-29. [4345606] [[http://dx.doi.org/10.1002/1097-0142\(197301\)31:1<117::AID-CNCR2820310116>3.0.CO;2-7](http://dx.doi.org/10.1002/1097-0142(197301)31:1<117::AID-CNCR2820310116>3.0.CO;2-7)]
- 15 van der Wal JE, Snow GB, van der Waal I. Histological reclassification of 101 intra-oral salivary gland tumours (new WHO classification). *J Clin Pathol* 1992;**45**:834-5. [1401223] [<http://dx.doi.org/10.1136/jcp.45.9.834>]
- 16 Yih WY, Kratochvil FJ, Stewart JC. Intra-oral minor salivary gland neoplasms: review of 213 cases. *J Oral Maxillofac Surg* 2005;**63**:805-10. [15944978] [<http://dx.doi.org/10.1016/j.joms.2005.02.021>]
- 17 Rippin JW, Potts AJ. Intra-oral salivary gland tumours in the West Midlands. *Br Dent J* 1992;**173**:17-9. [1320388] [<http://dx.doi.org/10.1038/sj.bdj.4807925>]
- 18 Chau MN, Radden BG. Intra-oral salivary gland neoplasms: a retrospective study of 98 cases. *J Oral Pathol* 1986;**15**:339-42. [3020212] [<http://dx.doi.org/10.1111/j.1600-0714.1986.tb00636.x>]
- 19 Ansari MH. Salivary gland tumors in an Iranian population: a retrospective study of 130 cases. *J Oral Maxillofac Surg* 2007;**65**:2187-94. [17954313] [<http://dx.doi.org/10.1016/j.joms.2006.11.025>]
- 20 Pires FR, Pringle GA, de Almeida OP, Chen SY. Intra-oral minor salivary gland tumors: a clinicopathological study of 546 cases. *Oral Oncol* 2007;**43**:463-70. [16979373] [<http://dx.doi.org/10.1016/j.oraloncology.2006.04.008>]
- 21 Jaber MA. Intraoral minor salivary gland tumors: a review of 75 cases in a Libyan population. *Int J Oral Maxillofac Surg* 2006;**35**:150-4. [16181771] [<http://dx.doi.org/10.1016/j.ijom.2005.07.006>]
- 22 van Heerden WF, Raubenheimer EJ. Intraoral salivary gland neoplasms: a retrospective study of seventy cases in an African population. *Oral Surg Oral Med Oral Pathol* 1991;**71**:579-82. [1646427] [[http://dx.doi.org/10.1016/0030-4220\(91\)90366-K](http://dx.doi.org/10.1016/0030-4220(91)90366-K)]