

Diagnosis of *Aspergillus fumigatus* endophthalmitis from formalin fixed paraffin-embedded tissue by polymerase chain reaction-based restriction fragment length polymorphism

Jyotirmay Biwas, MS; R Bagyalakshmi, MSMLT;
Lily K Therese, Ph.D

New molecular biological technique of Polymerase Chain Reaction (PCR) based Restriction Fragment Length Polymorphism (RFLP) can identify the species from paraffin-embedded tissue section. We demonstrated *Aspergillus fumigatus* fungus by PCR-based RFLP technique from paraffin section of an eyeball of an eight-month-old child removed for endogenous endophthalmitis.

Key words: *Aspergillus fumigatus*, endophthalmitis, restriction fragment length polymorphism

Indian J Ophthalmol 2008;56:65-6

Endogenous infection of the globe is rare in an immunocompetent patient. Identification of the organism is quite important in the management of such patients. Histopathological examination with special stain can identify the etiological agent. However, identification of the species is not possible from histopathological examination.

We report a case of endogenous endophthalmitis in an eight-month-old child. The histopathological examination of the enucleated globe revealed granulomatous inflammation and subsequent staining by Gomori's methanamine silver staining revealed the presence of multiple fungal filaments in the globe. As the species identification was not possible by histology, nucleic acid based amplification method of Polymerase Chain Reaction (PCR) targeting Internal Transcribed Spacer (ITS) region was applied on the tissue sections. PCR detected the presence of fungal genome in the tissue specimen. However, to characterize the fungus, the technique of PCR-based restriction fragment length polymorphism (RFLP) using *Hae*-III enzyme was applied on the ITS amplified products. PCR based RFLP revealed a cleavage pattern similar to that of *Aspergillus fumigatus*.

Case History

An eight-month-old male child was brought by his parents in March 2006. The child had history of severe cough four months

ago. Subsequently, he developed severe redness, watering and discharge in the right eye. His birth history revealed the child was a full-term normal delivery. There was no history of prenatal infection.

The child could not fixate or follow light with right eye whereas the left eye could fixate and follow the light. Right eye had conjunctival congestion, hazy cornea, an exudative mass in the anterior chamber. There was iris atrophy. Intraocular pressure was low in the right eye and normal in the left eye digitally. Fundus examination revealed no view in the right eye. Ultrasonography of the right eye showed vitreous cavity filled with moderately reflective dot echoes. There was no evidence of intraocular calcification. Choroid was grossly thickened (3.0 mm). No mass lesion or intraocular foreign body was seen. Axial length of the eyeball was 13.3 mm. Computerized tomography (CT) scan showed the right globe smaller in size with hyperdense vitreous without any calcification. Ultrasound and CT scan finding was suggestive of endophthalmitis in the right eye. Left eye was normal in all aspects.

As there was no visual potential, the right eye was enucleated. The globe measured 12 mm anteroposteriorly, 13

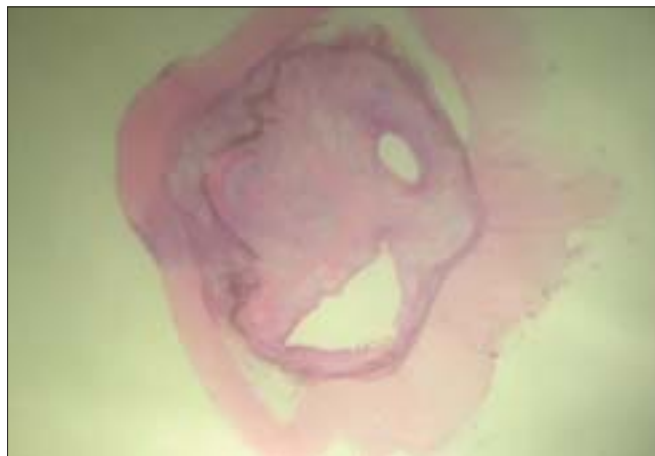

Figure 1: Intraocular inflammation in the vitreous cavity (1x)

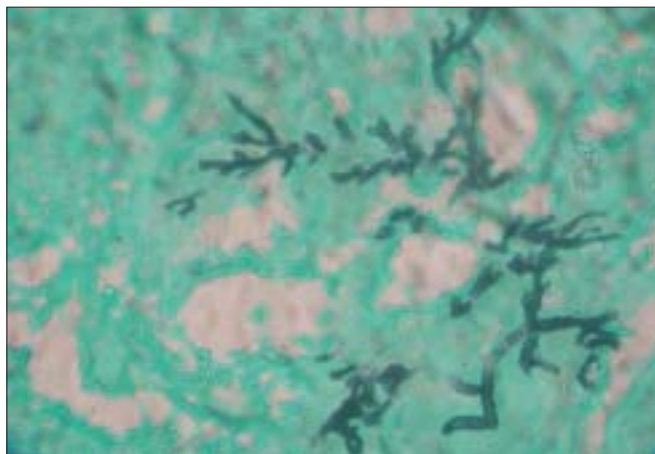


Figure 2: Gomori methanamine silver stain showing fungal filaments in the vitreous cavity (x 200)

Medical and Vision Research Foundations, Sankara Nethralaya, 18, College Road, Chennai - 600 006, India

Correspondence to Dr. Jyotirmay Biswas, Medical and Vision Research Foundations, Sankara Nethralaya, 18, College Road, Chennai - 600 006, Tamil Nadu, India. E-mail: drjb@snmail.org

Manuscript received: 8.9.2006; Revision accepted: 19.04.07

mm horizontally and 12 mm vertically. Cross-section showed shrunken globe with disorganized internal structure. Choroid and sclera were thickened. Optic nerve head could not be seen. Central callote was submitted for histopathological examination which showed a shrunken eyeball with thickening of the sclera [Fig. 1]. Sclera was infiltrated by inflammatory cells at the limbus, which was composed of lymphocytes and multiple histiocytes. Iris showed dense infiltration of lymphocytes, plasma cells and histiocytes. Lens was found to be shrunken with ruptured and folded lens capsule. Vitreous cavity showed extensive granulomatous inflammation with multiple Langerhan's giant cells. Retina could not be identified. Histopathological diagnosis was consistent with endophthalmitis. Special stains for the fungus by Gomori methenamine silver stain showed multiple septate fungi with 90° branching suggestive of *Aspergillus* species [Fig. 2]. The PCR-based RFLP for species identification revealed a cleavage pattern similar to *Aspergillus fumigatus* [Fig. 3]. Child was examined by an internist. There was no evidence of systemic involvement due to *Aspergillus* infection. No risk factor, intake of oral steroid or immunosuppressive agent and malignancy was found. The child was doing well after six months.

Molecular microbiological investigations

DNA extraction from paraffin section was carried out by Qiamp kit (Qiagen, Germany) according to manufacturer's instructions.

PCR targeting ITS region: The PCR was carried out according to the method of Ferrer *et al.*¹ For a 50 µl reaction, 8 µl of 200 µM dNTPs, 5 µl of 10 X PCR buffer (5 mM MgCl₂, 50 mM KCl, 100 mM Tris Cl, 0.01% gelatin), 6 µl of 10 mM MgCl₂, 10 picomoles of forward primer, forward primer ITS₁ - 5' tcc gta

ggt gaa cct gcg g 3' and reverse primer ITS₄ - 5' tcc tcc gct tat tat gc 3' targeting ITS region. Ten µl of template DNA was used. Amplification was carried out in Perkin Elmer thermal cycler (Model 2700) consisting of initial denaturation at 95°C for 5 min followed by 35 cycles of denaturation at 95°C for 30 sec, annealing at 55°C for 1 min and final extension at 72°C for 1 min and a final extension of 72°C for 7 min. The amplification yielded 520 to 611 bp product according to different fungal species for ITS region.

The PCR-based RFLP was carried out on ITS amplified products using *Hae*-III enzyme. For a 25 µl reaction, 2.5 µl of Buffer (10 µl of amplified product) and 1 µl of *Hae*-III enzyme was added and incubated at 37°C for 3 h. The restriction enzyme digested products were resolved using 4% agarose gel electrophoresis.

Discussion

The application of nucleic acid-based amplification techniques facilitated the detection of fungal etiology in tissue specimens in our case. This technique has several advantages, it is rapid (within 24 h), sensitive to pick up a lower threshold of etiological agent and is specific. Moreover, this technique can be applied to cases in which histopathological study is given the first preference to determine the etiological agent. To apply this technique the organism need not be viable, the mere presence of fungal DNA would suffice to determine the specific etiology. Alexandrakis *et al.*² have used PCR technology to detect the presence of *Fusarium* species from a panophthalmitis case. There are several nucleic acid-based amplification methods to determine the etiology from paraffin sections. These include PCR, PCR-based RFLP, DNA hybridization and DNA sequencing. Of these techniques, if PCR and DNA hybridization have to be applied, then specific primers or probes for each medically important fungus has to be used. It might include several runs of PCR to detect the etiological agent. On the other hand, amplification using a broad range of primers targeting the ITS region followed by subsequent RFLP analysis proves to be a cost-effective method to detect the specific etiological agent. The results are specific as the cleavage pattern is unique for each type of fungus. Hence in this study PCR-based RFLP has proved to be a rapid and reliable tool in detection and identification of the etiological agents from paraffin sections.

References

1. Ferrer C, Colom F, Frases S, Mulet E, Abad JL, Alio JL. Detection and identification of fungal pathogens by PCR and by ITS 2 AND 5.8 s ribosomal DNA typing in ocular infections. *J Clin Microbiol* 2001;39:2873-9.
2. Alexandrakis G, Sears M, Gloor P. Postmortem diagnosis of *Fusarium* panophthalmitis by the polymerase chain reaction. *Am J Ophthalmol* 1996;121:221-3.

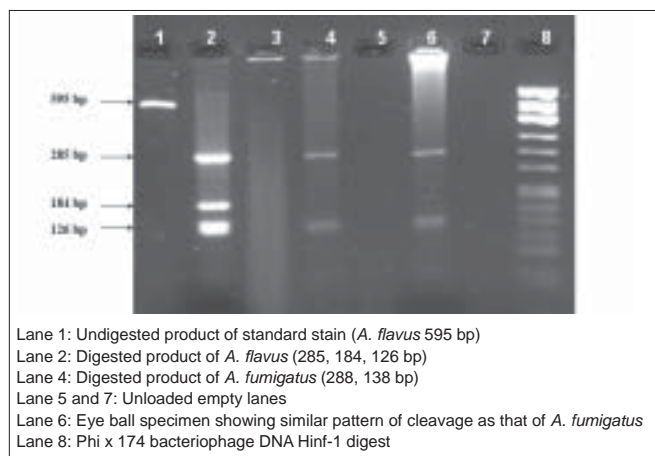


Figure 3: Electrophoretogram of PCR based RFLP on Internal Transcribed Spacer amplified products for species identification of fungus from paraffin section