

Conflicts of interest

None declared.

References

1. De Capitani EM, Vieira RJ, Bucaretychi F, Fernandes LC, Toledo AS, Camargo AC. Human accidents involving *Rhinocricus* spp., a common millipede genus observed in urban areas of Brazil. *Clin Toxicol (Phila)*. 2011;49:187–90.
2. Haddad V Jr, Cardoso JLC, Rotta O, Eterovic A. Acidentes provocados por Millipede com manifestações dermatológicas: relato de dois casos. *An Bras Dermatol*. 2000;75:471–4.
3. Lima CA, Cardoso JL, Magela A, Oliveira FG, Talhari S, Haddad Junior V. Exogenous pigmentation in toes feigning ischemia of the extremities: a diagnostic challenge brought by arthropods of the Diplopoda Class (“millipedes”). *An Bras Dermatol*. 2010;85:391–2.
4. Radford AJ. Millipede burns in man. *Trop Geogr Med*. 1975;27:279–87.
5. Haddad V Jr, Cardoso JL, Lupi O, Tying SK. Tropical dermatology: venomous arthropods and human skin: Part II. Diplopoda Chilopoda, and Arachnida. *J Am Acad Dermatol*. 2012;67:347, e1–e9.

Silmara Navarro Pennini ^{ID a,b,*},
 Paula Frassinetti Bessa Rebello ^{ID b},
 Maria das Graças Vale Barbosa Guerra ^{ID a},
 Sinésio Talhari ^{ID a}

^a Post-graduate Program in Tropical Medicine, Fundação de Medicina Tropical Dr. Heitor Vieira Dourado e Universidade do Estado do Amazonas, Manaus, AM, Brazil

^b Fundação de Dermatologia Tropical e Venereologia Alfredo da Matta, Manaus, AM, Brazil

*Corresponding author.

E-mail: pennini.sn@gmail.com (S.N. Pennini).

Received 7 March 2019; accepted 24 May 2019;

Available online 6 November 2019

<https://doi.org/10.1016/j.abd.2019.10.003>

0365-0596/ © 2019 Sociedade Brasileira de Dermatologia.

Published by Elsevier España, S.L.U. This is an open access article under the CC BY license (<http://creativecommons.org/licenses/by/4.0/>).

Primary diffuse cutaneous plasmacytoma: when a correct clinico-pathologic approach is mandatory for the patient's health ☆☆☆

Dear Editor,

A 76-year-old woman presented with multiple purplish plaques located on the arms (Fig. 1), deltoid region, elbows, wrist, mammary region, and legs. Lesions were painful at the touch without itching. Clinically, a diagnosis of eczema was suspected and a skin biopsy of the left arm was conducted.

Histological examination of hematoxylin & eosin-stained sections showed the presence of diffuse clusters of atypical oval-shaped cells with abundant cytoplasm, eccentric nuclei, “clock face” chromatin, and sometimes prominent nucleoli, infiltrating the medium and deep dermis (Fig. 2). Mitotic figures were seen. Neoplastic cells were morphologically similar to mature plasma cells, so a specific immunohistochemical panel was performed: they were diffusely positive for CD79a, CD138, CD56, MUM-1, and EMA, and totally negative for CD20. Immunohistochemical studies

for kappa and lambda light chains revealed a monoclonal expression of immunoglobulin kappa lights chains (Fig. 3).

To complete the diagnostic process, a bone marrow biopsy was performed; it was negative for multiple myeloma (MM) localization (less than 10% plasma cells; no clonal restriction). There were no Bence-Jones proteins in the urine. Hemogram and biochemical blood analysis revealed a normal value of hemoglobin and normal serum creatinine and calcium. Serum protein electrophoresis highlighted a lambda light chain spike.

Once the absence of other sites of disease was confirmed, a clinico-pathologic diagnosis of primary diffuse cutaneous plasmacytoma (PDCP) was rendered. Considering the extensive dissemination of the cutaneous involvement, the patient received systemic therapy. It consisted of bortezomib at the dosage of 1.3 mg/m² subcutaneously at day 1, 8, 15, and 22, melphalan given orally at the dosage of 14 mg at day 1, 2, 3, and 4, and dexamethasone at the dosage of 20 mg at day 1–2–8–9–15–16–22–23 (regimen). After nine cycles, fluorodeoxyglucose positron emission tomography-computed tomography showed complete disappearance of the skin lesions and absence of the lambda immunoglobulin G spike at the serum protein electrophoresis.

The patient completed therapy without adverse effects and, to date, after one year and eight months of follow-up, no recurrence of disease has been detected.

PDCP is a rare disease¹ that arises primarily in the skin, so it can be considered as a localized cutaneous extramedullary plasmacytoma (EMP) and should not be confused with secondary cutaneous plasmacytoma (SCP) in the context of MM.² According to a recent systematic review, only 68 cases of primary cutaneous plasmacytomas (PCPs) have been

☆ How to cite this article: Broggi G, Martino E, Calafiore V, Caltabiano R. Primary diffuse cutaneous plasmacytoma: when a correct clinico-pathologic approach is mandatory for the patient's health. *An Bras Dermatol*. 2019;94:767–9.

☆☆ Study conducted at the Azienda Ospedaliero-Universitaria Policlinico-Vittorio Emanuele, Catania, Italy.

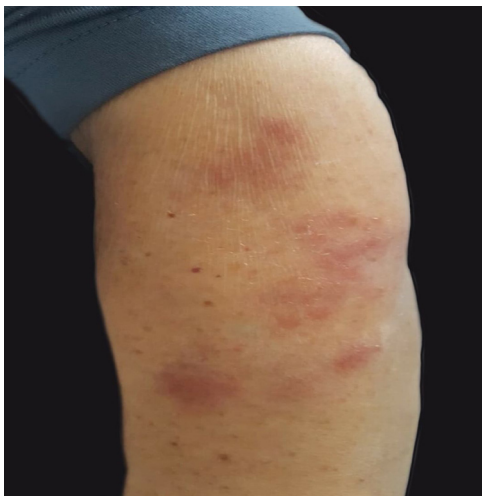

Figure 1 Multiple, painful, non-itching, purplish cutaneous plaques located on the left arm.

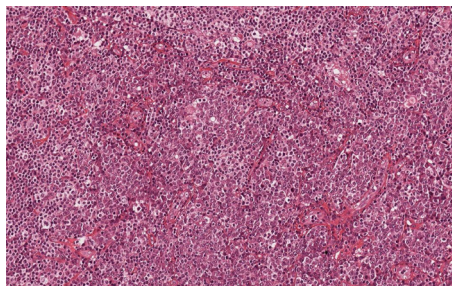


Figure 2 Clusters of oval-shaped cells with abundant cytoplasm, eccentric nuclei, and "clock face" chromatin (Hematoxylin & eosin, x200).

reported in literature, the majority of which were solitary lesions.³

PDCP usually arises as purplish-blue cutaneous nodules with a predilection for the face, trunk, and extremities.^{1,2} Histologically, a diffuse or nodular infiltration pattern can be recognized in PCPs and neoplastic cells may show different stages of plasma cells maturation process, from well differentiated to pleomorphic (similar to plasmablasts) features.^{4,5} PCPs with plasmablast-like features are composed of neoplastic cells with higher nuclear/cytoplasmic ratio, finely dispersed chromatin, and more prominent nucleoli.⁴ Epidermotropism is usually absent in PCPs.⁵

The main prognostic factor is clinical presentation (solitary vs. multiple lesions),³ but is also important to consider patient's performance status and comorbidities which can impair compliance in the treatment. Tsang et al., in their systematic review,³ showed that the only clinical variable associated with recurrence free survival (RFS) and overall survival was the number of lesions (solitary vs. multiple); in particular, they observed a large difference in median survival and RFS between patients with solitary lesions and those with multiple lesions.³ In the latter subset of patients, systemic chemotherapy is necessary due to the high rate of evolution to MM and the poor prognosis.¹

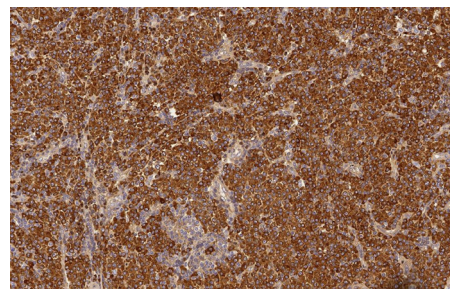


Figure 3 Mono-clonal expression of immunoglobulin kappa light chains (Immunoperoxidase, x200).

Differential diagnosis of PCP includes MM with SCP, EMP with secondary cutaneous involvement, other B-cell lymphomas of the skin, in particular marginal-zone lymphoma with marked plasma cell differentiation, and infective diseases such as *Borrelia* infections.

It is crucial to emphasize that neoplastic plasma cells in PCPs can be cytologically indistinguishable from reactive ones in infectious diseases, representing a potential diagnostic pitfall for pathologists, thus immunohistochemical evaluation of mono- or polyclonal expression of immunoglobulin light chains,⁴ combined with the absence of an evocative history of infection or causal agent identification, are crucial for a diagnosis of malignancy.⁵

MM rarely involves the skin and because of the absence of distinctive histological features, only with clinical and laboratory examinations is it possible distinguish between SCP in MM and PCP.²

Finally, PCDP is a rare disease that requires a wide multidisciplinary approach, which is strongly recommended to achieve a certain diagnosis of "true" PCP, in order to choose the optimal treatment.

Financial support

None declared.

Authors' contribution

Giuseppe Broggi: Approval of the final version of the manuscript; conception and planning of the study; composition of the manuscript.

Enrica Martino: Conception and planning of the study; composition of the manuscript.

Valeria Calafiore: Collection, analysis, and interpretation of data; intellectual participation in the propaedeutic and/or therapeutic conduct of the studied cases.

Rosario Caltabiano: Approval of the final version of the manuscript; critical review of the manuscript.

Conflicts of interest

None declared.

References

1. Malissen N, Fabre C, Joux JM, Bourquard P, Dandurand M, Marque M, et al. Multiple primary cutaneous plasmacytoma. *Ann Dermatol Venereol*. 2014;141:364–8.
2. Kazakov DV, Belousova IE, Müller B, Palmedo G, Samtsov AV, Burg G, et al. Primary cutaneous plasmacytoma: a clinicopathological study of two cases with a long-term follow-up and review of the literature. *J Cutan Pathol*. 2002;29:244–8.
3. Tsang DS, Le LW, Kukreti V, Sun A. Treatment and outcomes for primary cutaneous extramedullary plasmacytoma: a case series. *Curr Oncol*. 2016;23:e630–46.
4. Requena L, Kutzner H, Palmedo G, Calonje E, Requena C, Pérez G, et al. Cutaneous involvement in multiple myeloma: a clinicopathologic, immunohistochemical, and cytogenetic study of 8 cases. *Arch Dermatol*. 2003;139:475–86.
5. Rongioletti F, Patterson JW, Rebora A. The histological and pathogenetic spectrum of cutaneous disease in monoclonal gammopathies. *J Cutan Pathol*. 2008;35:705–21.

Giuseppe Broggi ^{a,*}, Enrica Martino ^b,
Valeria Calafiore ^b, Rosario Caltabiano ^a

^a Department Gian Filippo Ingrassia, Section of Anatomic Pathology, University of Catania, Catania, Italy

^b Division of Hematology, Azienda Ospedaliero-Universitaria Policlinico-Vittorio Emanuele, Catania, Italy

* Corresponding author.

E-mail: giuseppe.broggi@gmail.com (G. Broggi).

Received 30 November 2018; accepted 1 April 2019;

Available online 7 November 2019

<https://doi.org/10.1016/j.abd.2019.04.004>

0365-0596/ © 2019 Sociedade Brasileira de Dermatologia.

Published by Elsevier España, S.L.U. This is an open access article under the CC BY license (<http://creativecommons.org/licenses/by/4.0/>).

Perforating necrobiosis lipoidica: good response to adalimumab^{☆,☆☆}

Dear Editor,

Necrobiosis lipoidica (NL) is a rare granulomatous dermatosis of unknown origin, often related to diabetes mellitus (DM).^{1,2} The perforating form of necrobiosis lipoidica (PNL) is even more infrequent, affecting mainly adults between 30 and 60 years, particularly women. The clinical lesion consists of coalescing plaques, of various diameters, in the classical localization of NL. The presence of keratotic “plugs,” which leave small depressions in the tissue when removed, is characteristic.² Histologically, there is the elimination of the necrobiotic material through the follicular canal, in addition to the “palisade” granulomas with collagen necrobiosis.

This report details the case of a male patient, 65 years old, who referred to the appearance of papules and plaques initially in the right forearm a year ago, and three months later, in the scapular region and right leg, with pustules, edema, and erythema to proximal third of the right leg, accompanied by discreet pruritus and local discomfort. The patient has arterial hypertension and depressive disorder, and uses losartan, fluoxetine, and diosmin. He is a former smoker, while denying alcoholism and other comorbidities. The dermatological examination showed erythematous, infiltrated, annular-like plaques with ulcerated areas and fibrin on the inside of both legs, the right foot, and right arm (Fig. 1). Serological tests were negative and fasting glycemia was within normal limits. The bacilloscopy

was negative for leprosy. The culture was negative for *Histoplasma capsulatum*, *Paracoccidioides brasiliensis*, and other fungi. The chest X-ray was unaltered, as were the right leg and foot X-ray. Histopathological examination revealed palisade granuloma, consisting of epithelioid histiocytes and multinucleated giant cells, centered by fibrinoid necrosis, with some neutrophils and signs of vascular damage in the dermis (Fig. 2). In the sample of the left scapular region, there was an area of epidermal perforation that communicated to the granuloma area. The search for fungi and BAAR by histochemical staining of PAS, Grocott and Ziehl-Neelsen and *M. tuberculosis* by polymerase chain reaction (PCR) were negative. The patient used rifampicin 300 mg 12/12 h and clindamycin 300 mg 12/12 h for ten weeks, presenting partial improvement of the lesions. Therefore, it was decided to start prednisone 20 mg per day, methotrexate 20 mg per week, folic acid 10 mg per week, and moisturizing dressing with calcium alginate and sodium and clobetasol daily. In two months of evolution, he presented little improvement, thus it was decided to initiate injections of adalimumab 40 mg weekly; after five months of evolution, the patient presented significant improvement of the lesions, remaining only with scars (Fig. 3).

The treatment of NL and PNL is difficult and often frustrating,² based on reports of few cases, due to the rarity of the disease. The literature describes a broad therapeutic arsenal, ranging from local treatments such as tacrolimus, in addition to PUVA, photodynamic therapy, and systemic anti-inflammatory drugs and immunomodulators; in this context, TNF- α inhibitors show good effectiveness in controlling the formation of granulomas.^{1,2} Adalimumab is a monoclonal antibody that binds to soluble TNF- α to prevent its interaction with TNF receptors on cell surfaces, thereby fixing the complement and inducing apoptosis in cells expressing TNF *in vitro*.³ A case study by Zhang et al. treated NL in a 29-year-old woman for 12 months using etanercept and injectable adalimumab, but they recorded more significant improvement with etanercept, with no reported side effects. Chung et al. presented a case of a rheumatoid arthritis patient who developed an NL lesion even

[☆] How to cite this article: Mattos ABN, Brummer CF, Funchal GD, Nunes DH. Perforating necrobiosis lipoidica: good response to adalimumab. *An Bras Dermatol*. 2019;94:769–71.

^{☆☆} Study conducted at the Hospital Universitário Polyodoro Ernani de São Thiago, Universidade Federal de Santa Catarina, Florianópolis, SC, Brazil.