

Combined Retrosigmoid-paramedian Supracerebellar Transtentorial Approach as an Alternative to Classical Transtemporal Approaches: A Technical Note

Abstract

Epidermoid tumors are rare benign neoplasms. They commonly occur in the parasellar region and the cerebellopontine angle but may sometimes present in the so-called petroclival region, or beyond the boundaries of this location. For those that are localized in multiple compartments, staged surgeries, extensive transtemporal approaches, or somewhat limited extended middle fossa approach are generally performed. Although a good resection can be achieved by these approaches, they carry relatively high morbidity and mortality. We report a case of epidermoid tumor with infra- and supratentorial extensions, and propose a combined retrosigmoid-paramedian supracerebellar transtentorial approach as an alternative to classical transtemporal approaches.

Keywords: *Complication, epidermoid tumor, lateral skull base, petroclival, retrosigmoid, surgical approach, transtentorial*

Introduction

Surgical management of epidermoid tumors might be challenging. Those primarily located in the cerebellopontine angle (CPA) could extend into the neighboring compartments such as petroclival (PC) region, foramen magnum, or middle fossa, by penetrating through anatomical barriers.^[1] They cause displacement of cerebellum, brainstem, and neurovascular structures. Because of slow growth pattern, they reach significant size and extension at the time of clinical presentation. Cranial nerve deficits and signs related to compression to the brainstem and cerebellum develop in advanced stages of the tumor growth. Main goal in surgical resection is to achieve complete tumor removal without causing additional neurological deficit as these tumors tend to adhere to the cranial nerves and brainstem.

Approach to epidermoid tumors in this region is determined by the extension of lesion. Lateral skull base approaches are generally preferred by experienced neurosurgeons for the lesions strictly confined to this region. Once the lesions have marked extensions into the other compartments, these approaches are

planned in their most extensive forms with significant morbidity and mortality and may necessitate multistaged surgery for the complete removal of the lesion. Here, we present a combined surgical technique to a complex epidermoid cyst in a case, as a safer and more versatile alternative to the classical transtemporal approaches.

Case Report

A 40-year-old patient with no prior medical history was referred to our clinic with a diagnosis of intracranial mass revealed by magnetic resonance imaging (MRI). His complaints were numbness on the left side and difficulty walking. Neurological examination was normal except for a slight left hemiparesis and ataxic walking. On the MRI obtained at an outside hospital, there was a mass with restricted diffusion located in the right PC area extending to the premedullary cistern, inferiorly; the middle fossa, anteriorly; and the subthalamic area, superiorly, occupying the entire ambient cistern [Figure 1]. A magnetic resonance angiography was taken to assess the neurovascular structures, preoperatively.

Patient underwent surgery through a combined right retrosigmoid and lateral supracerebellar transtentorial approach.

Tamer Altay, Cem Akkurt

*Neurosurgery Clinic,
Haydarpasa Numune Training
and Research Hospital, Istanbul,
Turkey*

Address for correspondence:

*Dr. Tamer Altay,
Neurosurgery
Clinic, Haydarpasa
Numune Training and Research
Hospital, Istanbul, Turkey.
E-mail: altaytamer@hotmail.
com*

Access this article online

Website: www.asianjns.org

DOI: 10.4103/1793-5482.185062

Quick Response Code:



How to cite this article: Altay T, Akkurt C. Combined retrosigmoid-paramedian supracerebellar transtentorial approach as an alternative to classical transtemporal approaches: A technical note. *Asian J Neurosurg* 2018;13:161-4.

This is an open access article distributed under the terms of the Creative Commons Attribution-NonCommercial-ShareAlike 3.0 License, which allows others to remix, tweak, and build upon the work non-commercially, as long as the author is credited and the new creations are licensed under the identical terms.

For reprints contact: reprints@medknow.com

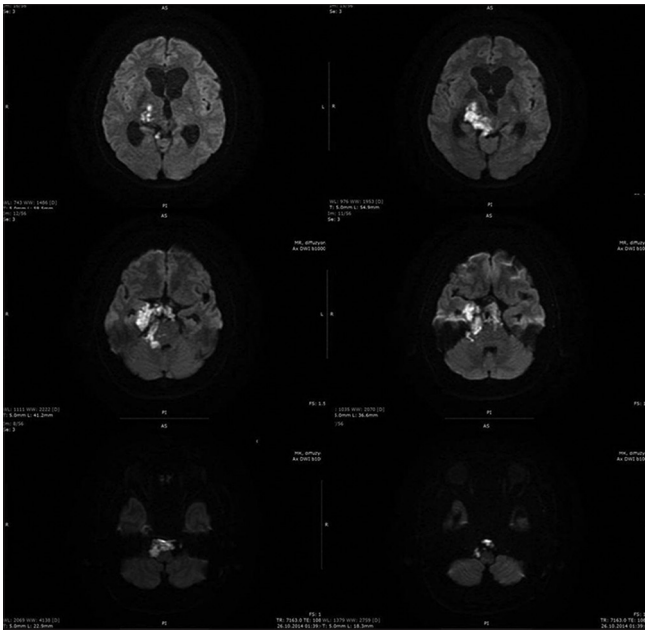


Figure 1: Preoperative diffusion-weighted imaging displaying rostral-to-caudal extension of the mass with restricted diffusion

Briefly, the patient was placed in the lateral oblique position, and a hockey stick skin incision beginning at the tip of the mastoid process traversing 3 cm above the superior nuchal line and descending to the midline was made. Following dissection of the muscular layers, a right retrosigmoid suboccipital craniotomy was performed. The bone flap extended 2 cm above the transverse sinus, superiorly; 2 cm over sigmoid sinus, laterally; and to the midline, medially. Mastoid cellular that were opened during the drilling for the skeletonization of the sigmoid sinus were sealed with bone wax. Under the operative microscope, the dura was opened right below the transverse sinus from the midline down to the inferolateral corner of the bone flap. After exposing the cisterna magna and draining cerebrospinal fluid (CSF), cerebellum was retracted medially, and the tumor was encountered in the typical appearance of epidermoid tumors. Cranial nerves VII and VIII, and the lower cranial nerves were identified. The tumor was initially debulked internally piecemeal. The entire segments of the seventh and the eighth cranial nerves were exposed and visualized tumor free. However, the tumor capsule was somewhat adherent to the lower cranial nerves. The tumor was chased down to the perimedullary cistern along the lower cranial nerves. The capsule was meticulously dissected off the adherent segments as much as possible. The anatomical integrity of all the lower cranial nerves was preserved at the end of the gross total resection of the tumor located at the lower part of the CPA. Then, the operative microscope was directed to the upper half of the CPA. The fifth cranial nerve was identified partly surrounded and displaced upward by the tumor that was entering the middle fossa by way of Meckel's cave, and extending up to the perimesencephalic cisterns through

tentorial hiatus. The contralateral component of the tumor residing in the prepontine cistern was accessible all around up to the interpeduncular cistern. Once the tumor in this compartment was resected, the pons was decompressed anterolaterally, and the verteobasilar system as well as the CN VI was exposed in their integrity. The CN V was freed of the tumor all around up to the Meckel's cave. At this point, the operative microscope was repositioned for the supratentorial portion of the tumor. The cerebellum was slightly retracted inferiorly. The bridging veins were taken. The tentorium was cut using 15 blades from posterior to anterior and to direction. The edge of the tentorium was carefully dissected off the CN IV and then divided. The CN IV was preserved throughout the procedure. The tentorial leaf was folded laterally, and the supratentorial compartment with the tumor filling in was exposed. The tumor including the part that extended into the ipsilateral middle fossa was resected piecemeal with preservation of the galenic system veins, medially, and distal posterior cerebral artery, superior cerebellar artery, and the basal vein of Rosenthal, anterolaterally. Satisfactory decompression of the posterolateral mesencephalon was achieved. However, tumor capsule was adherent to the mesencephalon. Because the tumor dissection at this point was considered to be unsafe, no further attempts were made to remove the capsule as well. Optimal hemostasis was obtained before the closure. Patient was kept intubated and sedated overnight in the Intensive Care Unit. Since the postoperative course was uneventful within the next 24 h, he was gradually awakened, extubated, and taken to the floor. He complained about neck pain, moderate hoarseness, and difficulty swallowing due to the pain in the throat. On neurological examination, he was fully awake, able to verbalize, and oriented to person and place. Other than a moderate decrease in the gag reflex on the right side, no cranial nerve dysfunction was noted. Fiberoptic endoscopic evaluation of swallowing indicated mild paresis in the right vocal cord. His preoperative left-sided weakness persisted. A noncontrast postoperative cranial computed tomography revealed complete decompression of the brainstem. The distortions and expansions in the anatomical structures and spaces improved, which suggested that there was no significant residual tumor left behind [Figure 2]. The patient was fed by an N/G tube within the first 2 postoperative weeks, which was until it was considered that his swallowing was safe upon reexamination by speech physiotherapy and by ENT using fiberoptic endoscopy. Although he was able to mobilize several times a day by the end of the 1st postoperative week, he was kept on enoxaparin for deep vein thrombosis prophylaxis. He developed aspiration pneumonia at the postoperative day 4 and was placed on appropriate antibiotics treatment. His swallowing of solids first, and then liquids improved gradually. He was transferred to the infectious diseases services to complete the rest of his antibiotics treatment, as he was able to feed and mobilize by himself, satisfactorily.

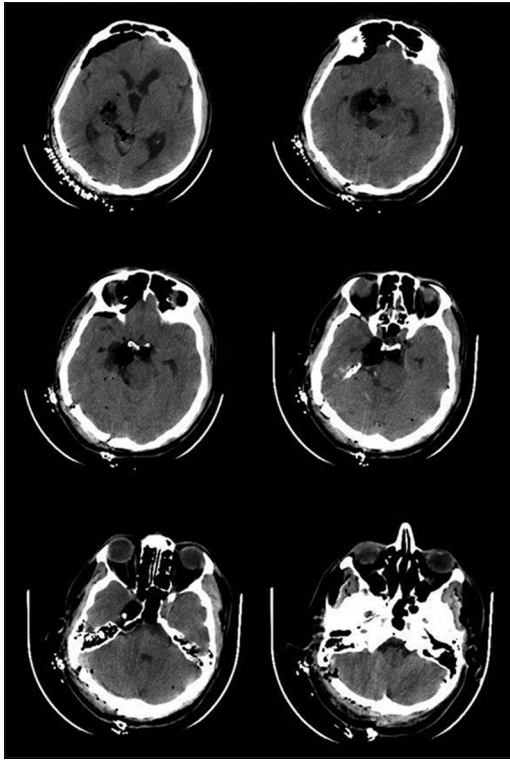


Figure 2: Postoperative computed tomography revealing gross total removal of the lesion

On postoperative day 24, the patient developed an acute respiratory failure with no impairment in his consciousness. His blood pressure was remarkably low. While he was being intubated by the cardiopulmonary resuscitation (CPR) team immediately, cardiac arrest ensued. The patient did not respond to CPR and expired. His death was considered due to a massive acute pulmonary embolism.

Discussion

Epidermoid tumors are nonneoplastic lesions, and prevalently involve or extend to the posterior fossa.^[2] They are notorious for indolent clinical courses due to the pattern of slow growth because of which they may reach substantial size with multicompartmental extensions, and surround neural and vascular elements at the time of diagnosis.^[3]

Tumors originating at or medial to the foramina of cranial nerves in the posterior fossa are generally classified as PC lesions.^[4] These lesions have historically posed a significant surgical challenge with high morbidity and mortality, and many of them were considered to be inoperable until the last few decades. With the development of microsurgical techniques as well as sophisticated skull base approaches, their removal has become relatively safer. Nonetheless, potential tradeoffs intrinsic to extensive skull base approaches may complicate intra- or post-operative outcome depending on the surgical route to be followed.

Numerous surgical approaches have been developed to attack these formidable lesions. Extended middle fossa and

transtemporal approaches have gained wide acceptance in the hands of experienced neurosurgeons.^[5-8]

Transtemporal approaches are generally defined as retrolabyrinthine (posterior petrosal), translabyrinthine, transcochlear, or total petrosectomy. Although they are highly versatile, they carry surgical morbidity as high as 41%.^[9] The main disadvantage of these approaches relates to hearing loss following the drilling of the labyrinth or cochlea. Injury to the vein of Labbe is still an issue in transtemporal approaches. Risk of the CN VII palsy is not uncommon if its transposition is required. Furthermore, inadvertent injury to or planned section of the sigmoid sinus in a patient with limited or no patency of the contralateral sinus may lead to catastrophic consequences. Finally, dural closure is not always possible following transtemporal approaches. Despite packing a dural defect with fat and fascia, CSF leak may complicate the postoperative course up to 16% in some reports.^[10] Extended middle fossa approach, also known as anterior petrosal approach, is suitable for the lesions that do not extend lateral and inferior to the internal acoustic meatus. It requires somewhat temporal lobe retraction with potential injury to the vein of Labbe and the cranial nerves within the cavernous sinus, and more manipulation of the trigeminal nerve. Furthermore, main limitation to using this approach in our case was that the tumor extended down into the posterior fossa beyond the reach of the approach.

In our case, we used a combined right retrosigmoid and right paramedian supracerebellar transtentorial approach. The reasons we chose retrosigmoid approach for the portion of the lesion lying in the posterior fossa were that it was easy to access without significant bone removal except for skeletonization of the sigmoid sinus that the tumor had extended as far down as perimedullary cistern, which is beyond the reach of the classical transtemporal approaches, and finally, that the tumor had pushed the pons posterolaterally and widened the CPA, providing a straight route to the tumor on the contralesional side of the prepontine cistern essentially with no need for retraction to the cerebellum. Raza and DeMonte used retrosigmoid approach for the successful removal of an epidermoid cyst within the CPA and the PC region with involvement of the cranial nerves V through XI and the verteobasilar system.^[11] Yamahata *et al.* reported their retrosigmoid approach with a modification of tentorial incision for PC epidermoid cysts predominantly lying in the posterior fossa.^[12] On the other hand, Mannion *et al.* reported a retrolabyrinthine middle fossa transtentorial approach to the tumors of the PC region mainly located around upper CPA, upper clivus, and petrous apex.^[13]

Our combined technique also included a right paramedian supracerebellar transtentorial approach for the supratentorial perimesencephalic component of the tumor.

Once the tentorium was cut and folded, the entire tumor was encountered and chased along the mediobasal aspect of the temporal lobe to the Meckel's cave and the middle cranial fossa, anteriorly, and along the basal occipital region to the pulvinar and tectum, superiorly. This route also enabled us to fully decompress the ipsilateral cerebral peduncle. Working angles were enhanced, and the mobility of the instruments was increased through this approach. Ansari *et al.* reported the similar benefits from the so-called "extended" version of this approach for medial tentorial meningiomas in addition to the early access to the base of the tumor for devascularization^[14] Uchiyama *et al.* also used the paramedian supracerebellar transtentorial approach for the medial tentorial meningiomas, especially, with supratentorial component without complication.^[15] Endoscopic assistance, which we did not use in our case, would have been helpful for the assessment of a possible residual tumor, especially in the supratentorial region.

One of our limitations in this approach was lower cranial nerves transpassing the tumor in the perimedullary cistern. The working distance and angle, which would have been be slightly less demanding with a far lateral approach, required us to work above and below the nerves to preserve their anatomical integrity while resecting the tumor anterolateral to the medulla. Postoperatively, the patient had mild to moderate lower cranial nerve dysfunction that improved over the next 2 weeks. The other limitation was a relatively longer working distance, especially, for the component in the middle cranial fossa. This was overcome by using longer surgical equipment. Finally, we do not have a postoperative MRI to better assess the extent of the tumor resection since the patient did not survive a probable pulmonary embolism.

Conclusion

Epidermoid cysts in the PC region are surgically challenging compared to the other locations. Combined retrosigmoid-paramedian supracerebellar transtentorial approach to this location is an option for neurosurgeons that are not familiar with classical transtemporal approaches. It obviates the risks and most complications expected from these approaches, with a better scope, especially for the lesions with marked extensions in multiple compartments.

Financial support and sponsorship

Nil.

Conflicts of interest

There are no conflicts of interest.

References

1. Kwiek S, Bazowski P, Slusarczyk W, Kukier W, Suszynski K, Szajkowski S, *et al.* Epidermoid cysts of the posterior fossa and petroclival region: Treatment and outcome. *Skull Base* 2009;19:A262.
2. Thomalske G, Kienow-Rieg I, Mohr G. Critical observations concerning the diagnosis and clinical features in 100 cases of tumors of the cerebellopontine region. *Adv Neurosurg* 1973;1:252-9.
3. Yasargil MG, Abernathy CD, Sarioglu AC. Microneurosurgical treatment of intracranial dermoid and epidermoid tumors. *Neurosurgery* 1989;24:561-7.
4. Couldwell WT, Weiss MH. Surgical approaches to petroclival meningiomas part I: Upper and midclival approaches. *Contemp Neurosurg* 1994;16:1-6.
5. Hakuba A, Nishimura S, Jang BJ. A combined retroauricular and preauricular transpetrosal-transtentorial approach to clivus meningiomas. *Surg Neurol* 1988;30:108-16.
6. Kawase T, Shiobara R, Toya S. Anterior transpetrosal-transtentorial approach for sphenopetroclival meningiomas: Surgical method and results in 10 patients. *Neurosurgery* 1991;28:869-75.
7. Cho CW, Al-Mefty O. Combined petrosal approach to petroclival meningiomas. *Neurosurgery* 2002;51:708-16.
8. Pieper DR, Al-Mefty O. Total petrosectomy approach for lesions of the skull base. *Oper Tech Neurosurg* 1999;2:62-8.
9. Roberti F, Sekhar LN, Kalavakonda C, Wright DC. Posterior fossa meningiomas: Surgical experience in 161 cases. *Surg Neurol* 2001;56:8-20.
10. Shukla D, Behari S, Jaiswal AK, Banerji D, Tyagi I, Jain VK. Tentorial meningiomas: Operative nuances and perioperative management dilemmas. *Acta Neurochir (Wien)* 2009;151:1037-51.
11. Raza SM, DeMonte F. Retrosigmoid craniotomy for cerebellopontine angle/petroclival epidermoid cyst. *Neurosurg Focus* 2014;36 1 Suppl:1.
12. Yamahata H, Tokimura H, Hirahara K, Ishii T, Mori M, Hanaya R, *et al.* Lateral suboccipital retrosigmoid approach with tentorial incision for petroclival meningiomas: Technical note. *J Neurol Surg B Skull Base* 2014;75:221-4.
13. Mannion R, Patel P, Gaastra B, Axon P, Donnelly N, Moffat D, *et al.* Combined retrolabyrinthine middle fossa transtentorial approach to tumors of the petroclival region: Clinical outcome and hearing preservation. *J Neurol Surg B* 2012;73:A341.
14. Ansari SF, Young RL, Bohnstedt BN, Cohen-Gadol AA. The extended supracerebellar transtentorial approach for resection of medial tentorial meningiomas. *Surg Neurol Int* 2014;5:35.
15. Uchiyama N, Hasegawa M, Kita D, Yamashita J. Paramedian supracerebellar transtentorial approach for a medial tentorial meningioma with supratentorial extension: Technical case report. *Neurosurgery* 2001;49:1470-3.