

Available online at www.sciencedirect.com

ScienceDirect

journal homepage: www.elsevier.com/locate/radcr

Case Report

Gallstone ileus – a well-known, but rarely encountered cause for small bowel obstruction [☆]

Philipp Roesslhuemer^{a,*}, Thomas D. Ruder^a, Nesti Cédric^b, Beat Schnueriger^b, Johannes T. Heverhagen^a

^aDepartment of Diagnostic, Interventional and Pediatric Radiology, Inselspital, Bern University Hospital, University of Bern, Freiburgstrasse 18, 3010, Bern, Switzerland

^bDepartement of Visceral Surgery and Medicine, Inselspital, Bern University Hospital, University of Bern, Freiburgstrasse 18, 3010, Bern, Switzerland

ARTICLE INFO

Article history:

Received 29 September 2023

Revised 10 November 2023

Accepted 15 November 2023

Available online 6 December 2023

Keywords:

Gallstone ileus

small bowel obstruction

Rigler triad

ABSTRACT

Gallstone ileus is a well-known cause of small bowel obstruction in the radiological literature. In the experience of these authors, gallstone ileus occurs more often in quiz cases for registrars than in the everyday casework of a radiologist. The here presented case of a gallstone ileus provides a good opportunity to summarize cause, clinical presentation, radiological findings, and treatment options for both those studying for the specialist examinations and those whose specialist examinations are long past.

© 2023 The Authors. Published by Elsevier Inc. on behalf of University of Washington.

This is an open access article under the CC BY-NC-ND license

(<http://creativecommons.org/licenses/by-nc-nd/4.0/>)

Case history and imaging findings

A 77-year-old male patient with a 3-day history of vomiting was referred for a CT from accident and emergency department (A&E) with a query of ileus. Point of care ultrasound (POCUS) had revealed nonpropulsive peristalsis and dilated, liquid filled small bowel loops. Due to impaired renal function (eGFR <15 mL/min, creatinine >400 μmol/L) nonenhanced CT (NECT) was performed.

NECT revealed pneumobilia (Fig. 1A), small bowel obstruction, a gallstone (18 mm diameter) in the terminal ileum (Fig. 1B), and evidence of a cholecystoenteric fistula (Fig. 1C).

The presence of a radiopaque gallstone within the gallbladder on a previous NECT 7 months prior (Fig. 1D) was helpful in confirming the diagnosis of gallstone ileus.

The patient was admitted to surgery. Laparoscopy findings included distended small bowel loops without evidence of ischemia. However, the obstructive gallstone was not found. The following day, the gallstone reappeared in the patient's stool, after natural excretion (Fig. 2).

The patient was discharged after a fortnight. Follow-up magnetic resonance imaging (MRI), 4 months after surgery, revealed persistence of the cholecystoduodenal fistula and evidence of choledocholithiasis, which was confirmed by gastroscopy and removed by subsequent endoscopic retrograde

[☆] Competing Interests: The authors declare that they have no known competing financial interests or personal relationships that could have appeared to influence the work reported in this paper.

* Corresponding author.

E-mail addresses: philipp.roesslhuemer@insel.ch, p.roesslhuemer@gmx.at (P. Roesslhuemer).

<https://doi.org/10.1016/j.radcr.2023.11.042>

1930-0433/© 2023 The Authors. Published by Elsevier Inc. on behalf of University of Washington. This is an open access article under the CC BY-NC-ND license (<http://creativecommons.org/licenses/by-nc-nd/4.0/>)

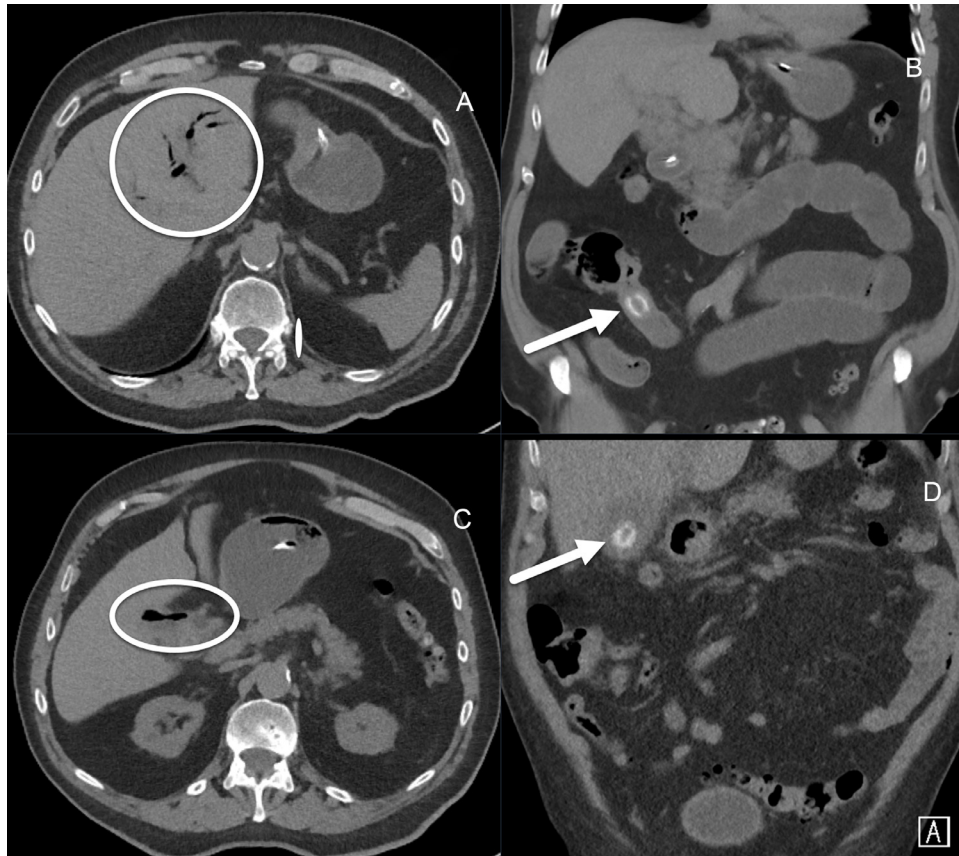


Fig. 1 – (A–C) Findings of gallstone ileus on NECT with pneumobilia (circle on (A), axial view), presence of ectopic gallstone in the terminal ileum (arrow on (B), coronal view) causing small bowel obstruction, and evidence of cholecystoenteric fistula (circle on (C), axial view). (D) evidence of gallstone in gallbladder (arrow on (D), coronal view) in previous study, 7 months earlier.



Fig. 2 – Evacuated gallstone.

cholangiopancreatography. The cholecystoenteric fistula was still visible on the second MRI follow-up, 8 months after discharge, but there was no recurrence of gallstones. In view of

the patient's general health and absence of complaints regarding the fistula, the conservative treatment of the fistula was continued.

Discussion

This case reports the classic, but rare radiologic diagnosis of gallstone ileus. In the experience of these authors, gallstone ileus occurs more often in quiz cases for registrars than in the everyday casework of a radiologist.

In this regard, the present case provides a good opportunity to summarize cause, clinical presentation, and radiological findings of the gallstone ileus for both those studying for the specialist examinations and those whose specialist examinations are long past.

Gallstones are estimated to be present in >10% of adults in the UK [1], but <0.1% of patients with gallstones develop gallstone ileus [2]. A gallstone ileus is a mechanical gastrointestinal obstruction due to an impacted large (>2.5 cm) gallstone [2,3]. The typical pathogenesis from cholelithiasis to gallstone ileus is as follows: (i) chronic irritation and compression of gallbladder wall by the gallstone, (ii) progression

to chronic inflammation, vascular insufficiency, and erosion of the gallbladder wall, (iii) formation of cholecystoenteric fistula, usually to the duodenum, (iv) elimination of the gallstone via the fistula into the gastrointestinal tract, (v) and passage of the gallstone through the intestine until impaction occurs, usually in the terminal ileum [2–4].

Clinical findings of gallstone ileus are nonspecific and include abdominal pain and distension, nausea and vomiting, and high-pitched or absent bowel sounds [2–4]. Most patients are elderly and present with comorbidities, often patients have a history of chronic cholecystitis, and women are more often affected than men [2–4]. The clinical picture of patients with gallstone ileus was already succinctly summarized in Junor's report from 1856 [5].

In contrast to the clinical findings, the radiological findings are highly specific. The 3 key imaging findings of gallstone ileus are pneumobilia, small bowel obstruction, and ectopic gallstone; referred to as Rigler triad, after the radiologists who first described these findings on plain film in 1941 [2,6]. All 3 findings were also present on NECT in this case. The presence of pneumobilia is a sign of a bilioenteric fistula. Here, the presence of a previous CT documenting the stone in the gallbladder facilitated the final diagnosis of gallstone ileus in the acute setting.

Treatment generally involves surgical stone removal (enterolithotomy) since spontaneous expulsion of gallbladder stones occurs rarely. In the case of this patient, it remains unclear if the stone had progressed from the terminal ileum to the colon prior to, during, or after the attempted surgical enterolithotomy. Due to the risk of recurrent cholangitis, surgical treatment normally includes closure of the cholecystoenteric fistula (either during enterolithotomy or in the post-acute phase) [2,4]. Surgical fistula closure was considered, however in view of the patient's comorbidities conservative management was favoured. The patient had no biliary symptoms during the first 5 months after discharge from hospital and was regularly monitored through follow-up visits to the outpatient surgical clinic.

Conclusion

NECT in combination with prior images and the highly specific Rigler triad (pneumobilia, small bowel obstruction, and ectopic, radiopaque gallstone) were sufficient for diagnosis of gallstone ileus in this case. Although of rather small size, the gallstone lead to mechanical obstruction.

The subsequent formation of a bilioenteric fistula, which is a common complication of gallstone ileus, has not lead to further complications so far.

Learning points

- Gallstone ileus is a rare mechanical gastrointestinal obstruction caused by an impacted large gallstone.
- Patients are usually elderly and present with nonspecific symptoms such as abdominal pain, nausea and vomiting, and often, with underlying comorbidities.
- The radiologic findings of gallstone ileus are highly specific and include pneumobilia, small bowel obstruction, and ectopic gallstone, known as the Rigler triad.
- Treatment usually involves surgical stone removal and closure of the cholecystoenteric fistula, but depending of patient health, conservative management of cholecystoenteric fistulas may be attempted.

Patient consent

The patient gave written informed consent for the publication of the case report.

REFERENCES

- [1] NHS. Gallstones: NHS; 2021 [updated 19.11.2021. Available from: <https://www.nhs.uk/conditions/gallstones/>. [accessed 25.11.22].
- [2] Inukai K. Gallstone ileus: a review. *BMJ Open Gastroenterol* 2019;6(1):e000344.
- [3] Lassandro F, Romano S, Ragozzino A, Rossi G, Valente T, Ferrara I, et al. Role of helical CT in diagnosis of gallstone ileus and related conditions. *AJR Am J Roentgenol* 2005;185(5):1159–65.
- [4] Ploneda-Valencia CF, Gallo-Morales M, Rinchon C, Navarro-Muniz E, Bautista-Lopez CA, de la Cerda-Trujillo LF, et al. Gallstone ileus: an overview of the literature. *Rev Gastroenterol Mex* 2017;82(3):248–54.
- [5] Junor JB. Notes of a case of ileus, caused by a large gallstone impacted in the ileum; death from rupture of the heart. *Edinb Med J* 1858;3(11):1004–5.
- [6] Rigler LG, Borman CN, Noble JF. Gallstone obstruction pathogenesis and roentgen manifestations. *J Am Med Assoc* 1941;117(21):1753–9.