

Echo-endoscopic analysis of variceal hemodynamics in patient with isolated gastric varices

Hidemichi Imamura¹, Atsushi Irisawa², Goro Shibukawa², Tadayuki Takagi¹, Takuto Hikichi³, Katsutoshi Obara³, Hiromasa Ohira¹

¹Department of Gastroenterology and Rheumatology, Fukushima Medical University School of Medicine, Fukushima,

²Department of Gastroenterology, Fukushima Medical University Aizu Medical Center, Aizuwakamatsu, ³Department of Endoscopy, Fukushima Medical University Hospital, Fukushima, Japan

ABSTRACT

Background: It is considered that gastric varices (GVs) which have the large form in endoscopic view should be treated because they are regarded as having high blood flow volume and the risky varices of hemorrhage. However, there is no data of the correlation among the endoscopic view, diameter of GV, and blood flow volume in GV. The aim of this study was to investigate whether GV diameter correlates to blood flow volume or not. In addition, the correlation between the endoscopic findings of GV, patient status, and blood flow volume was assessed. **Materials and Methods:** In this study, 24 patients were enrolled. Variceal form and its location were observed using flexible GI endoscopes. Assessment of variceal form and location was according to Japanese society of portal hypertension. Then, the GV diameter (the maximum short axis), the GV flow velocity, and the GV flow volume were measured by echo-endoscope with curved linear array or with electronic radial array. **Results:** Nineteen of 24 enrolled patients were analyzed. There was strong correlation between the GV diameter and the GV flow volume ($r_s = 0.85$, $P < 0.01$). No significant difference in the GV diameter and the GV flow volume was found between each location. However, there was no significant difference in the GV diameter between each variceal form. In addition, no significant difference was found among Child–Pugh classifications, and in cases associated with or without hepatocellular carcinoma. **Conclusions:** Strong correlation was found between GV diameter and flow volume of GV, regardless of the location. However, since there was no significant difference in the GV diameter between each variceal form in endoscopic view, measuring GV diameter is important to understand its hemodynamics for further treatment.

Key words: Endoscopic ultrasound, flow volume, gastric varices hemodynamics

INTRODUCTION

Even today, hemorrhage of gastric varices (GVs) is one of the mortal events in the patients with portal hypertension. Although GV has a lower risk of rupture than esophageal varices (EV),^[1] massive hemorrhage from GV can be a life-threatening event in patients with portal hypertension because GV has

a large blood flow volume. Until date, some kinds of therapy for GV, endoscopically^[2–4] and by interventional radiology (IVR),^[5–9] have been undergone. Endoscopic treatment is the most favored approach for the control of active variceal bleed worldwide.^[10]

In 1986, Soehendra *et al.* used a tissue adhesive substance endoscopically, isobutyl-2-cyanoacrylate, to stanch three esophagogastric variceal re-bleedings and reported its usefulness.^[11] Then, in 1987 they reported that they used n-butyl-2-cyanoacrylate for four isolated GV; it was useful for them.^[12] Obara *et al.* used α -cyanoacrylate monomer for GV and reported its efficacy in 1989.^[13] Because these tissue adhesive substances injected into

Access this article online

Quick Response Code:



Website:

www.eusjournal.com

DOI:

10.4103/2303-9027.144542

Address for correspondence

Dr. Atsushi Irisawa, E-mail: irisawa@fmu.ac.jp

Received: 2014-03-28; Accepted: 2014-04-29

GVs polymerize immediately if they touch blood, they physically block the inside of blood vessels and control blood flow without injuring endothelial cells and making a thrombus such as mechanisms of sclerosants.^[14]

On the other hand, whether isolated GVs should be treated prophylactically or not is controversial. No randomized comparative trial of prophylactic treatment for isolated GV has been reported to date. An opinion has been formed that GV should be treated if they have the large findings (F2/F3 in endoscopic view), red color (RC) sign, and erosion.^[15] Certainly, GV having a large size seems the risky varices of hemorrhage because of its high-blood volume. However, there is no data of the correlation between the endoscopic view, diameter of GV, and blood flow volume in GV. The aim of this study was to investigate whether GV diameter correlates to blood flow volume or not. In addition, the correlation between the endoscopic findings of GV, patient status, and blood flow volume was assessed.

MATERIALS AND METHODS

Patients

In this study, 24 patients who had isolated GV caused by portal hypertension were enrolled. Exclusion criteria included GV, which were bleeding or palliative because of preventing them from re-bleeding. Those connected with EV were excluded, too.

The protocol of this study was prepared according to the declaration of Helsinki and approved by the Ethics Committee of Fukushima Medical University School of Medicine. Written informed consent was obtained from all patients.

PROCEDURE

Endoscopy and endoscopic findings

After local anesthesia of the pharynx, a spasmolytic and a sedative were administered via an intravenous

route. Supplemental oxygen (2 L/min via nasal cannula) was also administered. Blood pressure, heart rate, and degree of oxygen saturation of peripheral artery were monitored.

Location and Form of GV were observed under a retroflex view using flexible GI endoscopes. The GV location (L) and form (F) were classified on the basis of endoscopic findings according to the Japan Society for Portal Hypertension.^[10] In this criteria, variceal location was endoscopically divided into two categories; Lg-f (fundus locally) and Lg-cf (from cardia to fundus) [Figure 1]. On the other, variceal form was endoscopically divided into three categories; F1 (linear small varices), F2 (beaded medium-sized varices), and F3 (nodular or tumorous large varices) [Figure 2].

Echo-endoscopic analysis of variceal hemodynamics

The GV were detected with B mode using an echo-endoscope with a curved linear array (GF-UCT240-AL5; Olympus Medical Systems, Tokyo, Japan) or with an electronic radial array (GF-UE260-AL5; Olympus Medical Systems, Tokyo, Japan), and ultrasonic diagnostic device (SSD-5500; Aloka Co. Ltd., Tokyo, Japan). The maximum minor axis of GV was measured and regarded as the GV diameter. Then blood flow was detected with color Doppler mode; its maximum flow velocity (V_{\max}) was measured using pulse Doppler mode [Figure 3].

In steady laminar flow, the following geometric relation existed between mean flow velocity (V_{mean}) and V_{\max} : $V_{\text{mean}} = 0.5 V_{\max}$. However, as a practical matter, V_{\max} multiplied by a coefficient (0.57), which Moriyasu *et al.*

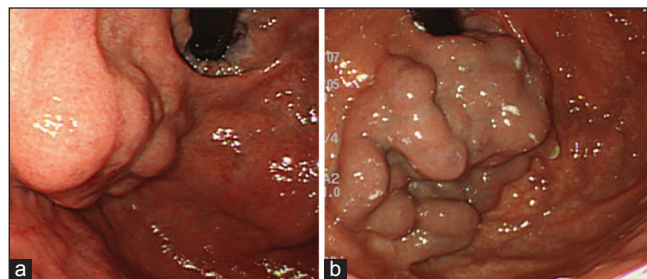


Figure 1. Location of gastric varices (GV). (a) GV in fundus locally (Lg-f). (b) GV of cardia to fundus (Lg-cf)

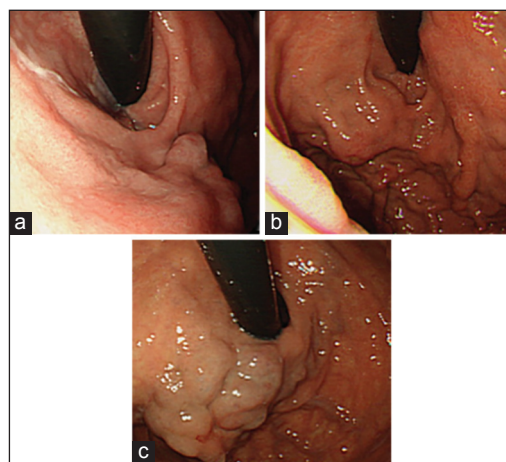


Figure 2. Form of gastric varices. (a) Linear small varices (F1). (b) Beaded medium-sized varices (F2). (c) Nodular or tumorous large varices (F3)

had reported based on experiments using blood flow model,^[16] was V_{mean} [Figure 4]. When we measured blood flow velocity, we noticed that the angle of the Doppler beam to the bloodstream became $<60^\circ$.^[17] Because the GV was curved, an error of about 5° might be brought about between the direction of flow and the measured value if measured in a relatively straight part. This error of about 5° was reflected about 5% in the error of flow velocity and flow volume when the Doppler beam to the bloodstream was 30° . However, it expanded at an increasing tempo: 10% in 50° , 15% in 60° , 24% in 70° , and 53% in 80° , as Gill had reported, if the angle of the Doppler beam to the bloodstream became large^[18] [Figures 3-5]. A cross section multiplied by the mean blood flow velocity was the blood flow volume, although we regarded a cross section as a circle [Figure 3]. The blood flow velocity and blood flow volume of GV were measured five times in each patient. Definite data were fixed using an average and excluding the maximum and minimum.

Statistical analysis

Results were given as the mean \pm standard deviation (SD) to compare mean differences between two groups, if the unpaired data were in a normal distribution, Student's *t*-test or Welch's *t*-test was used (the former was used if it could be assumed that the variances of unpaired data were equal; the latter was if it could not). Mann-Whitney's U-test for unpaired data was used if the unpaired data were not in a normal distribution. One-factor ANOVA was used in case that each data of three groups were in a normal distribution and the variances of them were equal to compare mean

differences among three groups. Kruskal-Wallis test was used in case that they were not in a normal distribution or the variances of them were not equal. Pearson's correlation coefficient test or Spearman's correlation coefficient by Rank test was performed to test the correlation between two variables (the former was used if each data were in a normal distribution; the latter was used if they were not). A $P < 0.05$ was inferred as statistically significant.

RESULTS

Baseline characteristics

Five of 24 enrolled patients were excluded because their Doppler beam to the bloodstream became more than 60° , therefore, flow volume of GV were investigated in remaining 19 patients. In all, 15 men and 4 women 62 ± 11.9 years of age (mean \pm SD) (range: 39-81 years) participated. The cause of portal hypertension was liver cirrhosis for 15 patients, fibrosis of bone marrow with splenomegaly because of extramedullary hemopoiesis for 2, and Budd-Chiari syndrome and Caroli's disease for 1 each. The causes of liver cirrhosis were, respectively, alcohol for 7 patients, hepatitis C virus (HCV) for 5, and nonalcoholic steroid hepatitis, alcohol and HCV, and hepatitis B virus for 1. Hepatocellular carcinoma (HCC) which did not invade the portal vein was complicated in 4 patients. According to the Child-Pugh classification, 14 patients were in class A, 4 in class B, and 1 in class C. Location: Eight patients were classified as Lg-f, and 11 as Lg-cf. Form: Two patients were classified as F1, 10 as F2, and 7 as F3. In addition, only 1 GV had erosion on the surface. These baseline characteristics were shown as Table 1.

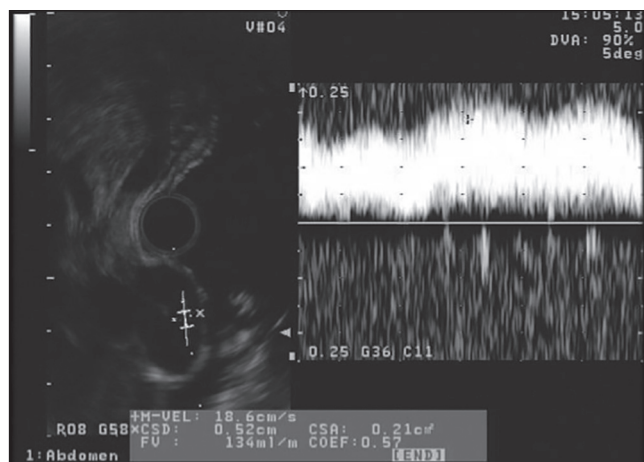


Figure 3. Measuring flow velocity and flow volume of gastric varices by echo-endoscope. In the presented case, flow velocity and flow volume were, respectively, 18.6 cm/s and 134 mL/min

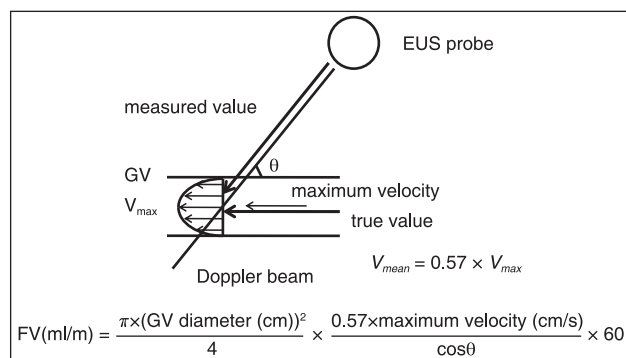


Figure 4. Methodology of measuring flow volume of gastric varices. The following relation existed between V_{mean} and V_{max} : $V_{\text{mean}} = 0.57 V_{\text{max}}$. A cross section multiplied by V_{mean} indicated the blood flow volume

Table 1. Baseline characteristics (n = 24)

Characteristics	Data
Mean age \pm SD (range)	63.0 \pm 11.4 (39-81)
Gender (men/women)	16/8
Cause of portal hypertension	
Liver cirrhosis	20
Alcohol	8
HCV	7
NASH	2
Alcohol with HCV	1
HBV	1
Unknown	1
Fibrosis of bone marrow	2
Budd-Chiari syndrome	1
Carolis' disease	1
Hepatocellular carcinoma (with/without)	5/19
Child-Pugh classification (A/B/C)	17/5/2
Location of GV (Lg-f/Lg-cf)	9/15
Form of GV (F1/F2/F3)	3/13/8

SD: Standard deviation, HCV: Hepatitis C virus, NASH: Nonalcoholic steatohepatitis, HBV: Hepatitis B virus, GV: Gastric varice

Relation of gastric varices (GVs) diameter and flow velocity of GV, and of GV diameter and flow volume

Gastric varices diameter was 5.6 ± 1.8 mm (2.4-9.0 mm) as examined using an echo-endoscope. There was no correlation between GV diameter and flow velocity of GV. On the other hand, strong correlation was found between GV diameter and flow volume of GV ($r_s = 0.85$, $P < 0.01$) [Figure 6].

The diameter of Lg-f was 5.8 ± 2.2 mm (3.5-9.0 mm), and Lg-cf was 5.4 ± 1.6 mm (2.4-7.2 mm). No significant difference in the GV diameter was found between Lg-f and Lg-cf. Moreover, the flow volume of Lg-f was 261.9 ± 323.5 mL/min (71.4-1023.5 mL/min) and Lg-cf was 169.0 ± 27.9 mL/min (14.7-395.8 mL/min). There was also no significant difference in the GV flow volume between Lg-f and Lg-cf.

Correlation was found between GV diameter and flow volume of GV in Lg-f ($r_s = 0.81$, $P < 0.05$) [Figure 7]. In addition, correlation was found between GV diameter and flow volume of GV in Lg-cf ($r = 0.76$, $P < 0.01$) [Figure 8].

Comparison in each endoscopic gastric varices form and endosonographic diameter

Gastric varices diameter in each endoscopic GV form as follows: F1 was 4.5 ± 1.3 mm (3.5-5.4 mm), F2

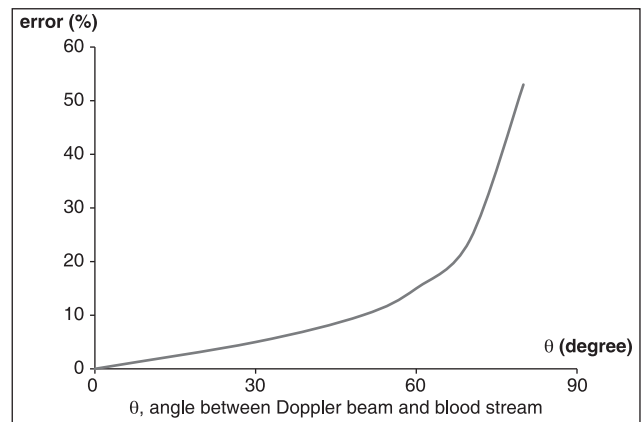


Figure 5. Error in flow measurement because of a 5° error in θ . θ , angle between the Doppler beam and the bloodstream

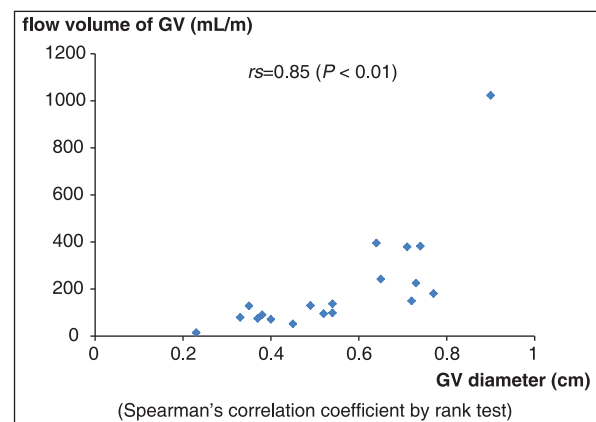


Figure 6. Relation of gastric varices (GV) diameter and flow volume of GV. Strong correlation was found between GV diameter and flow volume of GV measured using an echo-endoscope ($r_s = 0.85$, $P < 0.01$)

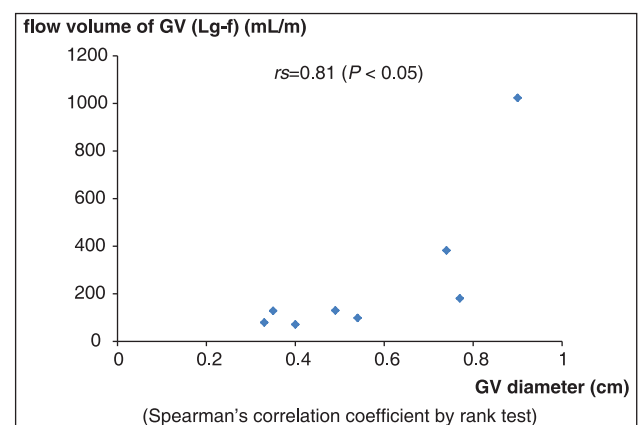


Figure 7. Relation of gastric varices (GV) diameter and flow volume of GV (Lg-f). Correlation was found between GV diameter and flow volume of GV in Lg-f ($r = 0.81$, $P < 0.05$)

was 5.0 ± 1.3 mm (3.6-7.3 mm), and F3 was 6.5 ± 2.1 mm (2.4-9.0 mm). No significant difference was found between F1 and F2, F2 and F3, and F1 and F3.

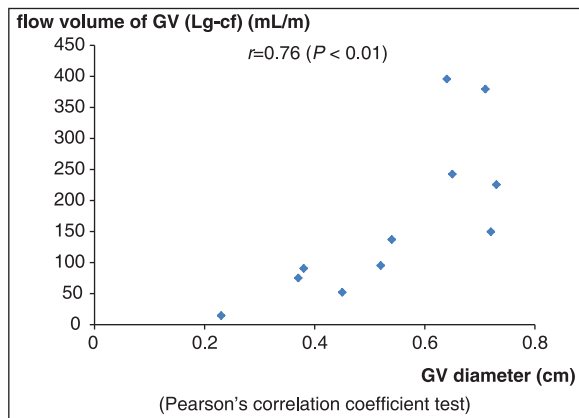


Figure 8. Relation of gastric varices (GV) diameter and flow volume of GV (Lg-cf). Correlation was found between GV diameter and flow volume of GV in Lg-cf ($r = 0.76$, $P < 0.01$)

Relations of factors of status in the patients and gastric varices (GVs) diameters, and of factors of status in the patients and the flow volume of GV

1. Child-Pugh classification: Child-Pugh A was 5.4 ± 1.8 mm (2.4-9.0 mm) in the GV diameter, Child-Pugh B plus C was 6.2 ± 1.9 mm (4.0-8.4 mm). No significant difference in the GV diameter was found between Child-Pugh A and Child-Pugh B plus C. In the flow volume of GV, Child-Pugh A was 219.5 ± 256.8 mL/min (14.7-1023.5 mL/min). Child-Pugh B plus C was 176.3 ± 134.2 mL/min (52.2-382.4 mL/min). There is no significant difference between Child-Pugh A and Child-Pugh B plus C in the flow volume of GV, too.
2. Association with HCC: The GV diameter in cases complicated with HCC was 4.7 ± 2.1 mm (2.4-7.2 mm) and without HCC was 5.8 ± 1.7 mm (3.5-9.0 mm). Significant differences were not found in GV diameter between cases associated with HCC and those without HCC. The flow volume of GV in cases complicated with HCC was 104.7 ± 88.3 mL/min (14.7-225.6 mL/min) and without HCC was 235.7 ± 247.6 mL/min (52.2-1023.5 mL/min). There is no significant difference between cases associated with HCC and those without HCC in the flow volume of GV, too.

DISCUSSION

If rupture of GV occurs, then massive hemorrhage resulting in death caused by bleeding or hepatic insufficiency can occur because isolated GV has more blood flow than EV.^[1,19] Therefore, it is considered that risky varices^[5] (large GV (F2/F3 in endoscopic view) and/or GV with RC sign and/or erosion)

should be treated aggressively. Although several therapies (endoscopic therapy,^[2-4] applied IVR,^[5-9] and surgery^[20,21]) are available at present, endoscopic therapy is recommended as the first choice for treatment in the case of GV bleeding because cyanoacrylates injected into the varices can arrest the bleeding immediately.

In this study, the variceal blood flow volume was measured using echo-endoscopy and the correlations between the blood flow volume and GV diameter were investigated. Consequently, a strong correlation was found between GV diameter and the flow volume of GV ($r_s = 0.85$, $P < 0.01$), as well as reported in EV.^[22] However, there was no correlation between GV diameter and flow velocity of GV in this study although Sato *et al.*^[23] had reported its correlation. This may be on the ground that diameter of GV was unequal in all points; a part of small diameter has higher flow velocity than large in a GV. Moreover, even given a different location (Lg-f, Lg-cf), strong correlation was found between the GV diameter and the flow volume for each location. Although the large GV was inferred to have had high-blood flow volume, no evidence has been presented to date. Results of this study show that large GV have a large flow. No report has described evaluation of prophylactic endoscopic injection sclerotherapy using cyanoacrylate for GV; it remains controversial whether nonbleeding GVs that accompany bleeding EV, or nonbleeding isolated GVs should be treated prophylactically. Although the data in this study are insufficient to indicate the risk of GV hemorrhage, they support the necessity of prophylactic treatment for large GV because hemostasis can be difficult to achieve, as a result, of high-flow volume if large varices rupture.

Results of this study show that important findings related to the strategy of treatment for GV. In general, the therapeutic indication is decided based on the endoscopic view, GV form, and/or existence of RC sign, erosion. Previous reports in the literature describe that large fundal varices (Lg-f) with red signs are even more likely to bleed.^[15] First, no significant difference was found in the GV diameter between F1 and F2, F2 and F3, and F1 and F3. Therefore, the large form of GV does not always have a large diameter. Indeed, in one case, a GV was recognized as F3, but its diameter measured using echo-endoscope was only 2.4 mm because the microvarices were

piled up. Measuring the GV diameter using an echo-endoscope, including mini-probes through the accessory channel (this method is easy to perform during regular esophagogastroduodenoscopy), is recommended for accurate assessment of GV. Second, the present data show no differences in the diameter and flow volume of GV between Lg-f and Lg-cf. From these results, it is considered that Lg-cf will be risky in the variceal hemorrhage as same as Lg-f. Although assessment of natural history of GV is necessary to investigate risky signs of GV hemorrhage, this new knowledge will be added for establishing a therapeutic strategy for GV.

In this study, no significant difference in GV diameter was detected using the Child–Pugh classification, association with HCC. The hepatic status and association with HCC are considered as important factors of developing varices: Not only gastric but also esophageal. Because the objective patients in this study had no advanced HCC (existence of portal invasion; VP factor), no difference in the GV diameter between associations with and without HCC was found. However, aggravation of hepatic status would not necessarily be associated with developing GV. In general, development of EV might be correlated to hepatic status. Regarding this contradiction, variceal hemodynamic differences in gastric and EV might be associated. In fact, GV frequently have a large porto-systemic shunt, such as gastro-renal shunt, unlike EV. Because this collateral will act for developing GV with restraint, aggravation of hepatic status might not be associated.

Only 1 GV had erosion on the surface in this study. This may be due to excluding GV which were bleeding or palliative. If diameter and flow volume of GV having RC sign and/or erosion can be investigated, more knowledge about the risky varices of hemorrhage may be able to be got.

At the author's institution, endoscopic treatment using cyanoacrylate mixed with a contrast medium at a mixture ratio of 62.5% is performed for GV as initial treatment.^[14,24] Most GV are associated with porto-systemic shunt, an excretion vein from the left renal vein, the left inferior phrenic vein and pericardial vein.^[25] Therefore, leakage of cyanoacrylate injected into GV can travel through the porto-systemic shunt and into the inferior vena cava,^[14] possibly causing thrombosis of these vessels and eventually, embolism

in the lung.^[26] Based on results of investigating past cases, if the GV diameter measured more than 10 mm using an echo-endoscope, then cyanoacrylate at a mixture ratio of 75% was used to prevent the leakage of injected cyanoacrylate.^[27] The present study provides some support for our methodology of endoscopic therapy for GV using cyanoacrylate. For the future, the usage of cyanoacrylate at different concentrations depending on the variceal size should be indicated clearly in the experimental study with the GV model.^[28]

CONCLUSION

Strong correlation was found between the GV diameter and flow volume of GV measured using the echo-endoscope, irrespective of the location. Furthermore, the large GV form does not always have a large diameter. Thus, measuring the GV diameter is important for understanding its hemodynamics for further treatment.

REFERENCES

1. Sarin SK, Lahoti D, Saxena SP, et al. Prevalence, classification and natural history of gastric varices: A long-term follow-up study in 568 portal hypertension patients. *Hepatology* 1992;16:1343-9.
2. Toyonaga A. Current concept of treatment for esophageal and gastric varices. *Gastroenterol Endosc* 1997;39:1347-57.
3. Stiegmann GV, Sun JH, Hammond WS. Results of experimental endoscopic esophageal varix ligation. *Am Surg* 1988;54:105-8.
4. Yoshida T, Hayashi N, Suzumi N, et al. Endoscopic ligation of gastric varices using a detachable snare. *Endoscopy* 1994;26:502-5.
5. Yoshida T, Harada T, Shigemitsu T, et al. Endoscopic management of gastric varices using a detachable snare and simultaneous endoscopic sclerotherapy and O-ring ligation. *J Gastroenterol Hepatol* 1999;14:730-5.
6. Lunderquist A, Vang J. Transhepatic catheterization and obliteration of the coronary vein in patients with portal hypertension and esophageal varices. *N Engl J Med* 1974;291:646-9.
7. Olson E, Yune HY, Klatte EC. Transrenal-vein reflux ethanol sclerosis of gastroesophageal varices. *AJR Am J Roentgenol* 1984;143:627-8.
8. Richter GM, Palmaz JC, Nöldge G, et al. The transjugular intrahepatic portosystemic stent-shunt. A new nonsurgical percutaneous method. *Radiology* 1989;29:406-11.
9. Kanagawa H, Mima S, Kouyama H, et al. Treatment of gastric fundal varices by balloon-occluded retrograde transvenous obliteration. *J Gastroenterol Hepatol* 1996;11:51-8.
10. The Japan Society for Portal Hypertension. The General Rules for Study of Portal Hypertension. 2nd ed. Tokyo: Kinbara; 2004. p. 37-50.
11. Soehendra N, Nam VC, Grimm H, et al. Endoscopic obliteration of large esophagogastric varices with bucrylate. *Endoscopy* 1986;18:25-6.
12. Soehendra N, Grimm H, Nam VC, et al. N-butyl-2-cyanoacrylate: A supplement to endoscopic sclerotherapy. *Endoscopy* 1987;19:221-4.
13. Obara K, Ohira H, Sakamoto H, et al. Endoscopic injection sclerotherapy with α -cyanoacrylate monomer for emergent bleeding from isolated gastric varices — Report of 3 cases. *Gastroenterol Endosc* 1989;31:3209-16.
14. Irisawa A, Obara K, Sato Y, et al. Adherence of cyanoacrylate which leaked from gastric varices to the left renal vein during endoscopic injection sclerotherapy: A histopathologic study. *Endoscopy* 2000;32:804-6.
15. Kim T, Shijo H, Kokawa H, et al. Risk factors for hemorrhage from gastric fundal varices. *Hepatology* 1997;25:307-12.

16. Moriyasu F, Ban N, Igarashi A, *et al.* A new method of transcutaneous measurement of portal blood flow by an ultrasonix "Duplex" system composed of a pulsed Doppler flowmeter and a linear-type real time B mode electroscanner. *Acta Hepato Jpn* 1983;24:537-44.
17. Kawasaki T, Moriyasu F, Kimura T, *et al.* Accuracy of measurement of portal and superior mesenteric arterial flow using ultrasonic doppler flowmeters. *Jpn J Med Ultrason* 1991;18:71-6.
18. Gill RW. Pulsed Doppler with B-mode imaging for quantitative blood flow measurement. *Ultrasound Med Biol* 1979;5:223-35.
19. Chikamori F, Shibuya S, Takase Y, *et al.* Transjugular retrograde obliteration for gastric varices. *Abdom Imaging* 1996;21:299-303.
20. Kitano S, Yoshida T, Bando T, *et al.* Laparoscopic injection sclerotherapy for esophagogastric varices. *Surg Endosc* 1994;8:252.
21. Hashizume M, Tanoue K, Morita M, *et al.* Laparoscopic gastric devascularization and splenectomy for sclerotherapy-resistant esophagogastric varices with hypersplenism. *J Am Coll Surg* 1998;187:263-70.
22. Nemoto Y, Murata Y, Mitsunaga A, *et al.* Substantial analysis of esophagocardiac varices by endoscopic ultrasonography. *Gastroenterol Endosc* 1998;40:763-62.
23. Sato T, Yamazaki K, Toyota J, *et al.* Observation of gastric variceal flow characteristics by endoscopic ultrasonography using color Doppler. *Am J Gastroenterol* 2008;103:575-80.
24. Obara K, Sakamoto H, Takiguchi F, *et al.* Emergency and palliative sclerotherapy for variceal hemorrhage of the gastric cardia. *Endoscopia Dig* 1991;3:1435-43.
25. Chikamori F, Kuniyoshi N, Shibuya S, *et al.* Correlation between endoscopic and angiographic findings in patients with esophageal and isolated gastric varices. *Dig Surg* 2001;18:176-81.
26. Roesch W, Rexroth G. Pulmonary, cerebral and coronary emboli during bucrylate injection of bleeding fundic varices. *Endoscopy* 1998;30:S89-90.
27. Obara K. Endoscopic treatment of gastric varices. *Gastroenterol Endosc* 2005;47:356-65.
28. Suga T, Akamatsu T, Kawamura Y, *et al.* Actual behaviour of N-butyl-2-cyanoacrylate (histoacryl) in a blood vessel: A model of the varix. *Endoscopy* 2002;34:73-7.

How to cite this article: Imamura H, Irisawa A, Shibukawa G, Takagi T, Hikichi T, Obara K, *et al.* Echo-endoscopic analysis of variceal hemodynamics in patient with isolated gastric varices. *Endosc Ultrasound* 2014;3:238-44.

Source of Support: Nil. **Conflict of Interest:** None declared.