

Available online at [www.sciencedirect.com](http://www.sciencedirect.com)

ScienceDirect

journal homepage: [www.elsevier.com/locate/radcr](http://www.elsevier.com/locate/radcr)

## Case Report

# Medical-type peritoneal mesothelioma leading to death two months after onset of fever of unknown origin ☆,☆☆

Kosuke Ishizuka, MD<sup>a,\*</sup>, Takanori Uehara, MD, PhD<sup>a</sup>, Makoto Arai, MD, PhD<sup>b</sup>, Junichiro Ikeda, MD, PhD<sup>c</sup>, Yuta Hirose, MD, PhD<sup>d</sup>, Masatomi Ikusaka, MD, PhD<sup>a</sup>

<sup>a</sup> Department of General Medicine, Chiba University Hospital, Japan

<sup>b</sup> Department of Gastroenterology, Tokyo Women's Medical University Yachiyo Medical Center, Japan

<sup>c</sup> Department of Pathology, Chiba University Hospital, Japan

<sup>d</sup> Department of General Medicine, Funabashi Futawa Hospital, Japan

## ARTICLE INFO

## Article history:

Received 28 October 2021

Revised 22 November 2021

Accepted 22 November 2021

## Keywords:

Fever of unknown origin

Mesenteric panniculitis

Peritoneal mesothelioma

## ABSTRACT

In malignant mesotheliomas, cases involving the peritoneum as the primary site are rare, accounting for approximately 10% of all mesothelioma cases. We report a case of medical-type peritoneal mesothelioma leading to death 2 months after the onset of fever of unknown origin, along with a review of the literature. A 76-year-old man presented with a fever of unknown origin over 4 weeks. Thoracoabdominal computed tomography (CT) scan showed increased mesenteric adipose tissue density. 18F-fluorodeoxyglucose positron emission tomography/computed tomography (FDG-PET/CT) scan showed diffuse hyperaccumulation in the mesentery and hyperaccumulation in the intraperitoneal and parasternal lymph nodes. A thoracoscopic biopsy of the parasternal lymph nodes revealed metastatic peritoneal mesothelioma. The treatment plan was discussed with him and his family, and the best supportive care was provided. 2 months later, he died from multiple organ failure. Underlying malignant tumors cause 38% of mesenteric panniculitis cases. Symptoms accompanied by lymphadenopathy within the area of mesenteric panniculitis are highly suggestive of malignancy. Peritoneal mesothelioma can be classified as (1) classical, which is accompanied by abdominal pain, ascites, and abdominal masses; (2) surgical, which is accompanied by hernia incarceration and intestinal occlusion; and (3) medical, wherein systemic symptoms, such as fever and weight loss, are primarily observed. The medical-type peri-

☆ Acknowledgement: None.

☆☆ Competing Interest: None.

\* Corresponding author.

E-mail address: [e103007c@yokohama-cu.ac.jp](mailto:e103007c@yokohama-cu.ac.jp) (K. Ishizuka).

<https://doi.org/10.1016/j.radcr.2021.11.064>

1930-0433/© 2021 The Authors. Published by Elsevier Inc. on behalf of University of Washington. This is an open access article under the CC BY-NC-ND license (<http://creativecommons.org/licenses/by-nc-nd/4.0/>)

toneal mesothelioma, wherein systemic symptoms are primarily observed, has a poorer prognosis than the other types. FDG-PET/CT is an effective diagnostic modality for peritoneal mesothelioma and typically shows diffuse hyperaccumulation along the peritoneal surface.

© 2021 The Authors. Published by Elsevier Inc. on behalf of University of Washington.

This is an open access article under the CC BY-NC-ND license

(<http://creativecommons.org/licenses/by-nc-nd/4.0/>)

## Introduction

Malignant mesotheliomas, their most frequent primary site being the pleura, [1] rarely involve the peritoneum as the primary site, accounting for approximately 10% of all mesothelioma cases. [2] Owing to the rarity of the disease, only a few papers on malignant peritoneal mesothelioma have reported a consistent number of cases; most studies have reported small case series or single cases, sometimes with an unusual clinical presentation or course. The incidence and mortality of malignant peritoneal mesothelioma may be underestimated owing to the difficulty in diagnosis. [3] Radiological assessment is usually performed using computed tomography (CT) and echotomography, but more recently, magnetic resonance imaging, positron emission tomography (PET), and PET/CT have also been used. [4] Histology of an adequate specimen, as well as cytology, is important for its diagnosis. [4] However, the prognosis of malignant peritoneal mesothelioma remains poor, with a median survival of <1 year. [5] A new clinical classification of malignant peritoneal mesothelioma, based on the clinical presentation, into 3 clinical types (classic, medical, and surgical) is characterized by the clinical course of the tumor. [6] We report a case of medical-type peritoneal mesothelioma leading to death 2 months after the onset of fever of unknown origin, along with a review of the literature. We believe that the clinical course in this case makes a valuable contribution to available knowledge about peritoneal mesothelioma.

## Case report

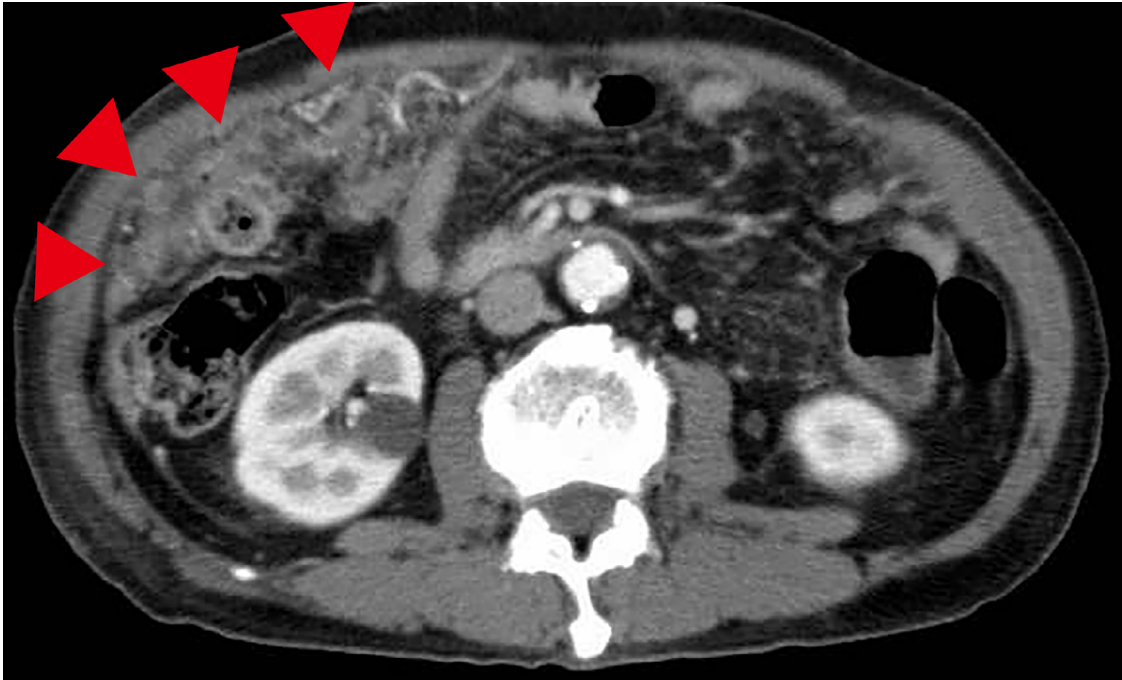A 76-year-old man presented with a fever of unknown origin (FUO) before the beginning of the COVID-19 pandemic. After feeling a sensation of heat 4 weeks before, developing a fever of 38°C or higher, and experiencing hypophagia 2 weeks before, he consulted a local clinic. His course was observed after prescribing medications for common cold. As the fever persisted, he was referred to our department. He lost 2 kg (56 kg to 54 kg) of body weight in 1 month. His medical history and family history were unremarkable. There was no history of asbestos exposure. Physical examination revealed a temperature of 37.9°C, pulse rate of 100/minute (regular), blood pressure of 132/61 mmHg, respiratory rate of 18 breaths/minute, and SpO<sub>2</sub> of 98% (room air). No abnormal findings were observed, including abdominal examination findings. Laboratory tests showed the following: white blood cell count, 15,600/ $\mu$ L; hemoglobin level, 7.7g/dL; platelet count, 67.2  $\times$  10<sup>4</sup>/ $\mu$ L; total protein level, 6.2g/dL; serum albumin level, 1.6g/dL; as-

partate aminotransferase level, 163U/L; alanine aminotransferase level, 178U/L; alkaline phosphatase level, 593U/L;  $\gamma$ -glutamyl transpeptidase level, 107U/L; C-reactive protein level, 29.36mg/dL; serum iron level, 6 $\mu$ g/dL; serum ferritin level, 863.3ng/mL; CA-125 level, 197.9U/mL; soluble interleukin-2 receptor level, 1,880U/mL; red blood cell count in urine, 10–19/High Power Field; and urinary protein to creatinine ratio, 16.2g/g creatinine (a urinalysis performed one week before showed a negative result for urinary protein). Thoracoabdominal CT scan showed increased mesenteric adipose tissue density (Fig. 1). 18F-fluorodeoxyglucose PET/CT (FDG-PET/CT) scan showed diffuse hyperaccumulation in the mesentery (Figs. 2 and 3) and hyperaccumulation in the intraperitoneal and parasternal lymph nodes. A thoracoscopic biopsy of the parasternal lymph nodes with hematoxylin and eosin staining was performed. An alveolar and sheet-like proliferation of relatively abundant atypical cells accompanied by internal necrosis was observed in the lymph nodes. Immunohistochemically, the atypical cells were positive for calretinin, cytokeratin 5/6, D2-40, cytokeratin AE1/AE3, and cytokeratin 7, partially positive for WT-1, and negative for TTF-1, napsin A, p40, CEA, cytokeratin 20, PAX8, GATA3, S-100, and BAP-1. Based on these findings, he was diagnosed with metastatic peritoneal mesothelioma. Chemotherapy with carboplatin (600 mg/body (AUC5), day 1) and pemetrexed (500 mg/m<sup>2</sup>, day 1) was administered every 3 weeks. Cerebral infarction occurred 2 days after commencing the first chemotherapy treatment cycle. Consequently, a new treatment plan was discussed with him and his family. Chemotherapy was discontinued, and the best supportive care was provided. 2 months after the onset of symptoms, he died from multiple organ failure because his general condition deteriorated.

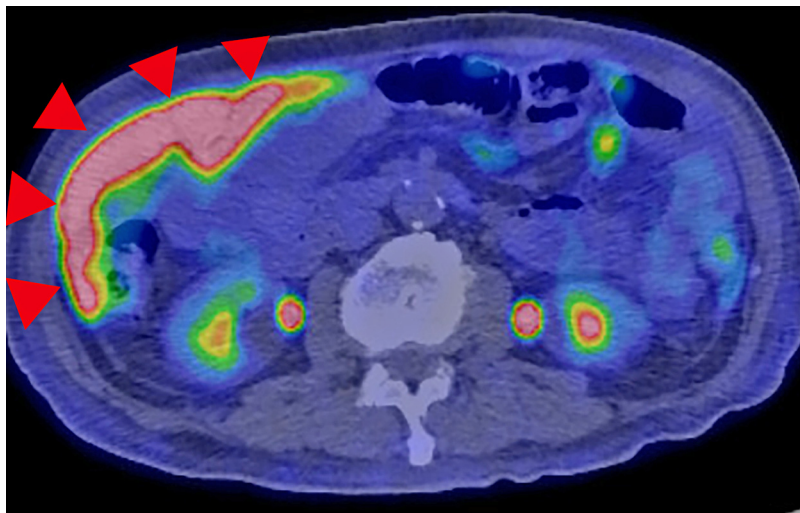
## Discussion

Underlying malignant tumors cause 38% of mesenteric panniculitis cases. [7] Symptoms accompanied by lymphadenopathy within the area of mesenteric panniculitis are highly suggestive of malignancy. [7] 10% of nephrotic syndrome cases have a malignant tumor complication, and peritoneal mesothelioma complications have also been reported. [8]

There is a new clinical classification of peritoneal mesothelioma based on the clinical presentation into 3 clinical types characterized by different clinical courses as follows: (1) classical, which is accompanied by abdominal pain, ascites, and abdominal masses; (2) surgical, which is accompanied by hernia incarceration and intestinal occlusion; and (3) medical, wherein systemic symptoms, such as fever and weight loss, are primarily observed. [4,6] Using this classification (classic,



**Fig. 1 – Thoracoabdominal computed tomography scan showing mesenteric panniculitis**

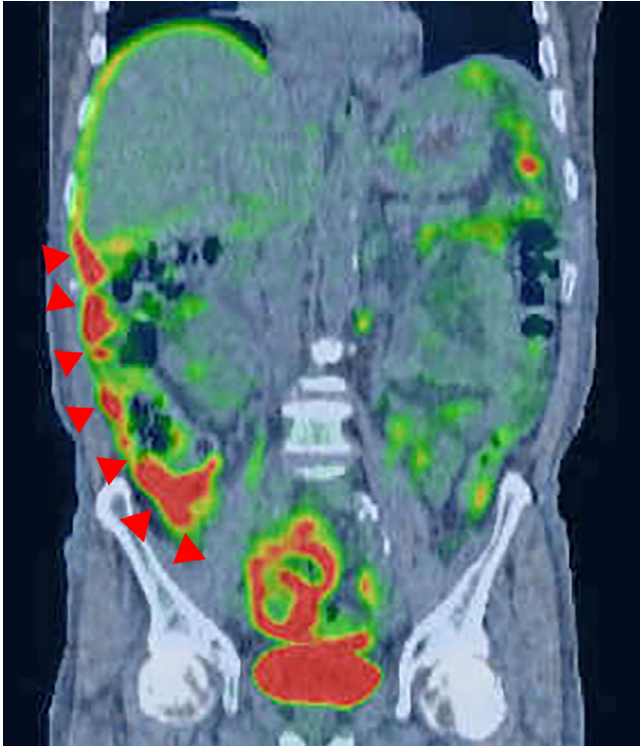


**Fig. 2 – 18F-fluorodeoxyglucose positron emission tomography/computed tomography scan showing diffuse hyperaccumulation in the mesentery**

medical and surgical), the disease was identified as classic in 73% of cases, surgical in 16%, and medical in 11% in a previous study. [4] Compared to the classical and surgical types, the medical type is reported to have a poorer prognosis, with a median survival of 6 months post-diagnosis. [4] The patient in this report had no abdominal specific symptoms, only sys-

temic symptoms such as fever and weight loss; thus, he was diagnosed to have medical-type peritoneal mesothelioma.

In conclusion, if the FUO patient has only non-specific symptoms, FDG-PET/CT is an effective diagnostic modality, and diffuse hyperaccumulation is typically seen along the peritoneal surface for peritoneal mesothelioma. [1]



**Fig. 3 – <sup>18</sup>F-fluorodeoxyglucose positron emission tomography/computed tomography scan showing diffuse hyperaccumulation in the mesentery**

### Authorship

All authors had access to the data and a role in writing the manuscript.

### Patient consent statement

Written informed consent for publication was obtained from the patient.

### Supplementary materials

Supplementary material associated with this article can be found, in the online version, at [doi:10.1016/j.radcr.2021.11.064](https://doi.org/10.1016/j.radcr.2021.11.064).

### REFERENCES

- [1] Moertel CG. Peritoneal mesothelioma. *Gastroenterology* 1972;63:346–50.
- [2] Jr Alexander HR, AP Burke. Diagnosis and management of patients with malignant peritoneal mesothelioma. *J Gastrointest Oncol* 2016;7:79–86.
- [3] Antman K, Hassan R, Eisner M, Ries LA, Edwards BK. Update on malignant mesothelioma. *Oncology* 2005;19:1301–9 *Williston Park*.
- [4] Manzini VP, Recchia L, Cafferata M, et al. Malignant peritoneal mesothelioma: a multicenter study on 81 cases. *Ann Oncol* 2010;21:348–53.
- [5] Yan TD, Hassan R, Welch L, Sugarbaker PH. Advances in diffuse malignant peritoneal mesothelioma. *Oncol Rev* 2007;1:53–64.
- [6] de Pangher Manzini V. Malignant peritoneal mesothelioma. *Tumori* 2005;91:1–5.
- [7] Wilkes A, Griffin N, Dixon L, Dobbs B, Frizelle FA. Mesenteric panniculitis: a paraneoplastic phenomenon? *Dis Colon Rectum* 2012;55:806–9.
- [8] Dogan M, Ozal G, Savas B, Gungor M, Utkan G, Yalcin B, et al. Malign peritoneal mesothelioma with nephrotic syndrome. *Bratisl Lek Listy* 2012;113:43–5.