

Clinical Article



Diagnostic Roots Radiofrequency Sensory Stimulation Looking for Symptomatic Injured Roots in Multiple Lumbar Stenosis

Jun Mo Kim¹, Suk-Hyung Kang ¹, Steve Sungwon Cho², Peter D. Chang³, Jin Seo Yang ¹, Jin Pyeong Jeon ¹, and Hyuk Jai Choi ¹



Received: Jan 21, 2022
Revised: Mar 29, 2022
Accepted: Apr 1, 2022
Published online: May 4, 2022

Address for correspondence:

Suk-Hyung Kang

Department of Neurosurgery, Chuncheon Sacred Heart Hospital, Hallym University Medical Center, Hallym University College of Medicine, 77 Sakjuro, Chuncheon 24253, Korea.
Email: nscharisma@hanmail.net

Copyright © 2022 Korean Neurotraumatology Society

This is an Open Access article distributed under the terms of the Creative Commons Attribution Non-Commercial License (<https://creativecommons.org/licenses/by-nc/4.0/>) which permits unrestricted non-commercial use, distribution, and reproduction in any medium, provided the original work is properly cited.

ORCID iDs

Suk-Hyung Kang
<https://orcid.org/0000-0002-1130-9754>
Jin Seo Yang
<https://orcid.org/0000-0003-4883-7224>
Jin Pyeong Jeon
<https://orcid.org/0000-0001-8543-6855>
Hyuk Jai Choi
<https://orcid.org/0000-0002-3774-5941>

Conflict of Interest

The authors have no financial conflicts of interest.

¹Department of Neurosurgery, Chuncheon Sacred Heart Hospital, Hallym University Medical Center, Hallym University College of Medicine, Chuncheon, Korea
²The Barrow Neurological Institute, Phoenix, AZ, USA
³Department of Radiological Sciences, Center for Artificial Intelligence in Diagnostic Medicine, University of California, Irvine, CA, USA

ABSTRACT

Objective: We present how to perform radiofrequency sensory stimulation (RFSS) and whether RFSS could be helpful in identifying symptomatic injured roots in multilevel lumbar stenosis.

Methods: Consecutive patients who underwent RFSS from 2010 to 2012 were enrolled. To identify pathologic lesions, RFSS was performed for suspicious roots, as determined using lumbar magnetic resonance imaging (MRI). The RFSS procedure resembled transforaminal root block. During RFSS of the suspicious root, patients could indicate whether stimulation induced their usual pain and/or sensory changes and could indicate whether the same leg area was affected. The number of possible symptomatic roots on MRI was evaluated before and after RFSS. Based on the RFSS results, we confirmed the presence of symptomatic nerve root(s) and performed surgical decompression. Surgical results, such as numeric rating scale (NRS) scores for low back pain (LBP) and leg pain (LP), and Oswestry disability index (ODI), were evaluated.

Results: Ten patients were enrolled in the study. Their mean age was 70.1±9.7 years. Clinically, NRS-LBP, NRS-LP, and ODI before surgery were 5.1%, 7.5%, and 53.2%, respectively. The mean number of suspicious roots was 2.6±0.8. After RFSS, the mean number of symptomatic roots was 1.6±1.0. On average, 1.4 lumbar segments were decompressed. The follow-up period was 35.3±12.8 months. At the last follow-up, NRS-LBP, NRS-LP, and ODI were 3.1%, 1.5%, and 35.3%, respectively. There was no recurrence or need for further surgical treatment for lumbar stenosis.

Conclusion: RFSS is a potentially helpful diagnostic tool for verifying and localizing symptomatic injured root lesions, particularly in patients with multilevel spinal stenosis.

Keywords: Neurologic diagnostic technique; Radiculopathy; Radiofrequency therapy; Spinal stenosis; Transcutaneous electric nerve stimulation

INTRODUCTION

The spine is commonly afflicted by degenerative joint disorders. Patients with spinal pathologies requiring surgical interventions are increasing in our aging society. These patients often have multiple lesions on radiographic images.¹³⁾

Advanced diagnostic techniques enable more accurate diagnoses for spinal pathologies. Developments in optical science enhance surgical microscopes and surgical endoscope, which can then improve surgical outcomes of spine disorders. However, clinical presentations are not always correlated with radiological findings. The frequent inconsistencies between the symptoms and the images may lead to poor surgical outcome.¹⁾

Hence, several diagnostic methods have been introduced to aid in the definite diagnosis and treatment of spinal pathologies. For instance, clinical trials have been conducted on selective nerve root blocks (SNRB). However, the specificity of SNRB is somewhat low.^{4,12)}

Radiofrequency sensory stimulation (RFSS) is a part of radiofrequency (RF) ablations. RFSS is a safe, provocative test that stimulates sensory nerves before RF ablations and does not make irreversible organic damage (**FIGURE 1**) RF has been used for surgical instrument since the 1930s. RF ablation such as RF facet rhizotomy, has been used to control chronic back and neck pain.^{2,17)} Low temperature (42°C) pulsed RF (PRF) is known to cause minimal tissue damage and generate therapeutic benefit.^{3,16)} Clinically, dorsal root ganglion (DRG) RF ablation for lumbosacral radicular pain has been reported with therapeutic effect.¹⁶⁾ DRG stimulation for the management of chronic pain applied to prime sensory neurons.⁷⁾

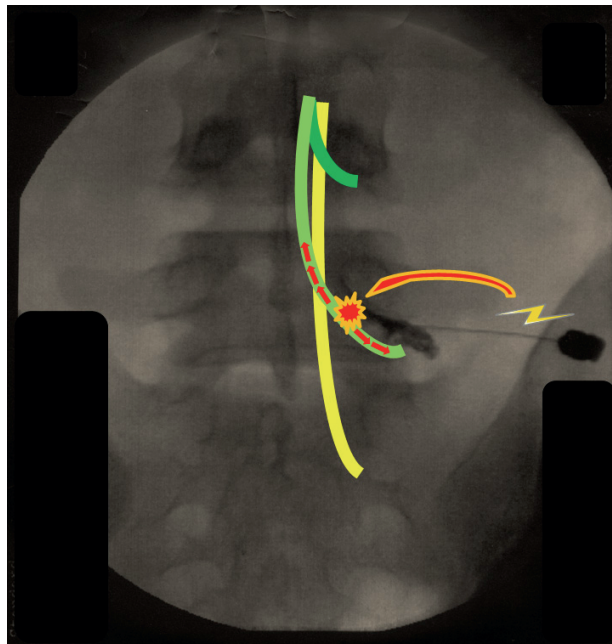


FIGURE 1. Schematic illustration of RF sensory stimulation. Through the RF sensory stimulation on the corresponding and suspicious roots, the patient could feel altered sense and could tell the difference between symptomatic and non-symptomatic stimulations. RF: radiofrequency.

From 2010 to 2012, total 930 spinal surgeries were undergone in my hospital. Ten patients got RFSS before surgery to get symptom correlative information. The patients had severe comorbidity or extremely old age. Preoperative RFSS was done as a part of epidural pain control and used to determine symptomatic lumbar root(s) in multi-level lumbar stenosis patients. The RFSS results were informative to authors to identify symptomatic root(s).

The objective of this study is to show how to do RFSS and to determine the diagnostic value of RFSS for choosing symptomatic roots in elderly patients presenting with multiple lumbar spinal lesions on magnetic resonance imaging (MRI). Surgical outcomes after spine surgery were determined based on RFSS use.

MATERIALS AND METHODS

Inclusion criteria

From 2010 to 2012, consecutive patients undergoing RFSS and spine surgery for MRI-confirmed multi-level spinal stenoses in a single institute were enrolled retrospectively. Main presenting symptoms were lower back pain and radiating leg pain. Patients gave informed consent for the procedures. RFSS was performed in patients with multiple lumbar stenoses based on the hypothesis that RFSS could detect the nerve roots causing the patients' symptoms. At the same time, diagnostic block after RFSS was done to control the pain. In specific patients, minimal invasive surgical approach was required because of their medical illness such as rheumatoid arthritis, bone marrow transplanted state, or aplastic anemia. This study was approved by Chuncheon Sacred Heart Hospital Institutional Ethics Review Board(2012-74 & 2018-20) as a case series in 2012.

Percutaneous RFSS method

To determine the symptomatic lesions, RFSS was performed on suspected nerve roots seen on MRI. RFSS is a similar procedure to the Pulsed RF DRG stimulation, which is used to treat chronic lumbosacral radicular pain.⁹⁾ RFSS also resembles transforaminal steroid injection.¹⁶⁾ Detailed processes are as follows. Before RFSS, the painful area on the leg was marked with pen (**FIGURE 2**). With the patient prone, the lumbosacral area was prepped and draped in the appropriate sterile fashion. After selecting an appropriate intervertebral foramen oblique view under fluoroscopy, a 22-gauge RF spinal needle was inserted into the intervertebral foramen near the cephalo-lateral aspect of the DRG. Then one or more RF needle was inserted into the suspected nerve roots as described above (**FIGURE 2**). RFSS was initially applied minimally to one root (**FIGURE 3**). Stimulation power was then gradually increased until the patient felt a sensory change under the RF sensory mode. During this process, the impedance range was 250–300 Ω , the pulse rate was 50 Hz, and the pulse duration was 1.0 msec. When the patient felt a sensory change during stimulation, the patient was asked to localize the affected area. We then confirmed whether the affected area overlapped the area of the original pain felt by the patient. After this process, RFSS was performed for the next root. RFSS was likewise systematically repeated for each suspected nerve root. These procedures were repeated two or three times to confirm the symptomatic roots. After the RFSS procedure was completed, nerve roots that matched the patients' presenting pain were anesthetized with 1% lidocaine for pain control. (**SUPPLEMENTARY VIDEO 1**)

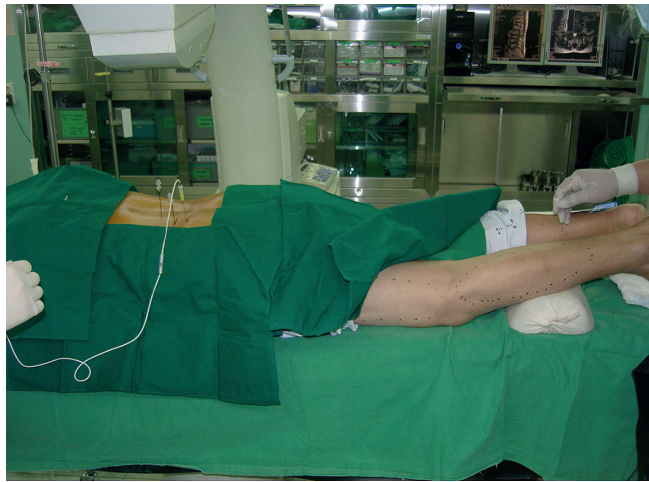

FIGURE 2. Photograph during RF sensory stimulation (case #4). SMK needles are inserted, and RF probe is inserted at S1 level. Skin marking indicates the original pain area at left leg. RF needles are inserted near left L4, L5, and S1 roots.
RF: radiofrequency.

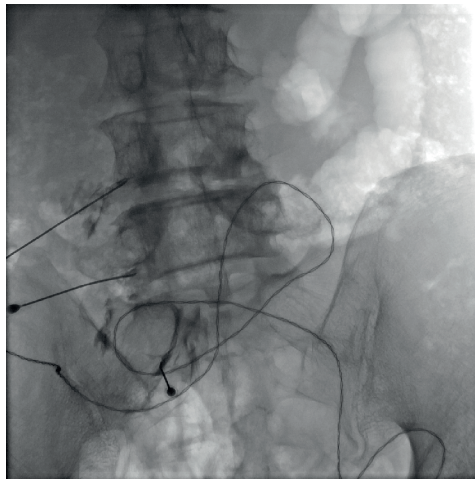

FIGURE 3. C arm view during RF sensory stimulation to search for symptomatic root of left leg pain. RF probe was inserted at left L4 RF needle to make sensory stimulate.
RF: radiofrequency.

Determination of symptom related lesion using RFSS

Patients were evaluated on whether they could distinguish the sensory changes from stimulation of different nerve roots. The number of nerve roots on MRI that could be related to the patient's original symptoms was determined. The number of roots identified using RFSS was then determined. The difference between the two numbers was compared for analysis.

Surgical results using RFSS

Based on the RFSS results, symptomatic roots were chosen for surgical decompression. Surgical methods were different depending on the patients' conditions and the spinal alignment. Decompressive partial hemilaminectomy, transforaminal lumbar interbody fusion (TLIF), and microscopic lumbar discectomy were executed by 3 different surgeons. Pain severity such as The numeric rating scales of low-back pain (NRS-LBP) and leg pain (NRS-LP), and The Oswestry disability index (ODI) were checked before surgery and at the last follow-up.

Case presentation to how to do RFSS

An 84-year-old man who had complaint right calf pain and intermittent claudication visited (case #1). He had no prior back pain history. The symptoms began 10 months before; he diagnosed on multiple lumbar spinal stenosis and got conservative management for 6 months.

He complained pain, paresthesia and tingling on the lateral aspect of right calf and dorsal foot. Moderate right leg weakness including right foot drop and limping gait was seen. After about walking 30-m, neurogenic intermittent claudication occurred. NRS-LBP and NRS-LP were 0 and 9, respectively. The ODI was 60%.

On the imaging study, mild spondylolisthesis including generalized degenerative spondylosis were seen in the X-ray. On MRI, multiple spinal stenosis including foraminal stenosis were seen at the level of bilateral L3/4/5 (**FIGURE 4**).

We wanted to know if the L3/4 segment should be included in the surgical treatment. To get more information, we tried RFSS of the right L4 and 5 roots before epidural root block.

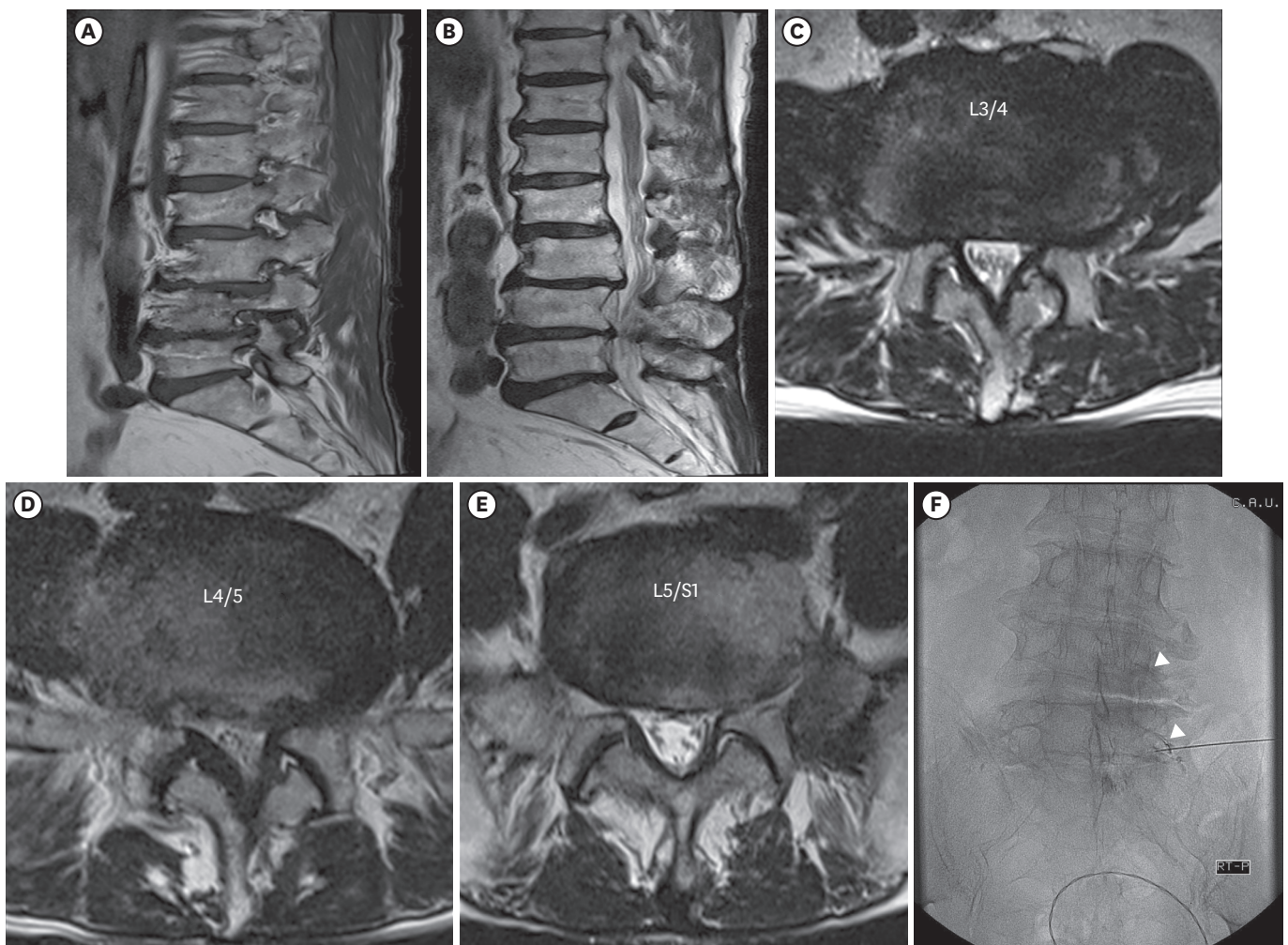


FIGURE 4. Magnetic resonance images of case. (A) Sagittal section at the right foramen showing multiple foraminal stenosis. (B) Mid sagittal section showing spondylolisthesis at the L3/4 level. Axial sections at (C) L3/4, (D) 4/5, and (E) 5/S1 showing stenosis with facet hypertrophy. (F) Radiograph of radiofrequency sensory stimulation; the right L5 root (lower arrow head) after right L4 root (upper arrow head) stimulation.

Like transforaminal epidural steroid injection, we selected appropriate intervertebral foramen oblique view under biplane fluoroscope. We had inserted 22-gauge RF spinal needle (SMK-C10 cannular; Radionics, Burlington, MA, USA) into spinal foramen to the point of cephalo-lateral aspect of lumbar dorsal root ganglion. Through epidurography with water-soluble contrast, we could identify the needle tip near the exiting root. RFSS with RF generator (RFG-1A radiofrequency generator; Cosman Medical, Burlington, MA, USA) started with little stimulation and gradually increased the stimuli till patients felt the corresponding sensory change. The impedance range was 250–300 Ω . Pulse rate was 50 Hz, and pulse duration was 1.0 msec.

In the case of L4 root, there was no response till the RF stimuli reached the 1.4 V/mA. The sensory changed area during RFSS differed from the original pain location, indicated more cephalad area. In the case of L5 root, when sensory stimulus reached 0.4 V/mA, the patients felt sensory change in the right buttock area. When the stimulus reached 0.8 V/mA, he felt the sensory change of the corresponding area. S1 root stimulation was executed because the radiologic finding was far from the clinical manifestation. After stimulation, L5 root block was done with 1% lidocaine 1 mL. The patients experienced the right leg pain was completely improved after the root block, but the pain was recurred next morning.

After RFSS, we decided to decompress right L5 nerve root; L4 root RF stimulation was not significant, L5 root RF stimulation presented corresponding sensory result. The MRI of neural foramen at right L5/S1 showed high-signal intensity of perineural fat and axial section of L5/S1 do not have presented severe stenosis. The patient got TLIF and percutaneous pedicle screw fixation at L4/5. The preoperative right leg pain and gait disturbance was improved. 48 months after surgery, the NRS-LBP and NRS-LP were 2 and 1. The ODI was 12%. There was no additional spinal surgery.

RESULTS

Three male and seven female patients were undertaken surgical treatment with RFSS results. The mean age at the time of RFSS was 70.1 \pm 9.7 years. There were 27 suspicious roots on MRI, 16 of which were confirmed to be symptomatic using RFSS (TABLE 1).

TABLE 1. Demographic data and symptom related roots in RFSS group

No	Sex	Age (yr)	Diagnosis	Radiologically suspicious roots	RFSS positive roots	Sensory discrimination
1	Male	84	Stenosis	L4 & 5	L5	Clearly
2	Male	70	Stenosis & HNP	L4, 5 & S1	L5	Clearly
3	Female	69	Stenosis & HNP	L5 & S1	S1	Not distinguish L4 from L5 Distinguish L5 from S1
4	Female	72	Fracture & Stenosis	L3, 4 & 5	L5	Clearly
5	Female	82	Fracture & Stenosis	L2, 3, 4 & 5	L2, 3, 4 & 5	Not distinguish L1 from L2 Distinguish L5 from S1
6	Female	67	Stenosis & HNP	L5	L5 & S1	Clearly
7	Female	54	Stenosis & HNP	L3, 4 & 5	L4 & 5	Clearly
8	Female	57	HNP L4/5, 5/S1	L5 & S1	L5	Clearly
9	Male	78	Stenosis & HNP	L3, 4 & 5	L3 & 4	Clearly
10	Female	68	Stenosis	L3, 4 & 5	L5	Clearly
Average		70.1 \pm 9.7		2.6 \pm 0.8 roots	1.6 \pm 1.0 roots	

RFSS: radiofrequency sensory stimulation, HNP: herniated nucleus pulposus.

TABLE 2. Surgical results with RFSS

No.	Operation	Decompression level	PreOP NRS-LBP	PreOP NRS-LP	PreOP ODI	FU months	Last NRS-LBP	Last NRS-LP	Last ODI	Odom's criteria	Event during FU
1	TLIF	L4/5	5	10	60	48	2	1	12	Good	
2	TLIF	L5/S1	5	9	52	45	4	1	26	Good	Stroke
3	MD	L4/5/S1	4	4	40	25	0	0	10	Good	TKA
4	VP (L4) & PHL	L4/5	4	4	40	24	2	2	2	Good	
5	PSF L1/2/3 & PHL	L4/5/S1	8	8	60	44	6	4	27	Fair	
6	PHL	L4/5	6	8	40	47	1	1	5	Fair	
7	PHL	L3/4/5	7	8	60	42	3	0	2	Good	RA, C1/2 instability
8	TLIF	L4/5	6	8	60	24	5	0	66	Fair	Anaplastic anemia, ICH, expire
9	TLIF	L3/4	4	8	80	12	2	2	3	Good	SAH, expire
10	PHL	L4/5	2	8	40	42	6	4	27	Faire	
Average			5.1	7.5	53.2	35.3	3.1	1.5	18.0		

RFSS: radiofrequency sensory stimulation, PreOP: preoperative, NRS: numeric rating scale, LBP: low back pain, LP: leg pain, ODI: Oswestry disability index, FU: follow-up, TLIF: transforaminal lumbar interbody fusion, MD: microdiscectomy, TKA: total knee arthroplasty, PHL: partial hemilaminectomy, VP: vertebroplasty, PSF: pedicle screw fixation, RA: rheumatoid arthritis, BMT: bone marrow transplantation, ICH: intracerebral hemorrhage, SAH: subarachnoid hemorrhage.

The mean number of suspicious roots on MRI was 2.6 ± 0.8 per patient. After RFSS, the average number of symptomatic roots decreased to 1.6 ± 1.0 . All patients except two reported sensory differences between symptomatic and non-symptomatic areas during RFSS. Two patients could not discriminate sensory changes for two cranial roots but could differentiate between two caudal roots.

The ten patients underwent spinal surgery after obtaining RFSS results. NRS-LBP, NRS-LP, and ODI before surgery were $5.1\% \pm 1.7\%$, $7.5\% \pm 2.0\%$, and $53.2\% \pm 13.3\%$ respectively. Average follow-up period was 35.3 ± 12.8 months, with a minimal period of 12 months. On the final follow-up, NRS-LBP, NRS-LP, and ODI were $3.1\% \pm 2.1\%$, $1.5\% \pm 1.5\%$, and $18.0\% \pm 19.8\%$, respectively. There were no reported complications associated with the RFSS procedure or spine surgery. There was no additional spinal surgery for their multiple lumbar stenosis. During follow-up, two patients died from subarachnoid hemorrhage and pneumonia, two patients were diagnosed with stroke, one patient underwent total knee arthroplasty, and one patient was diagnosed with rheumatoid arthritis leading to C1/2 instability (TABLE 2).

DISCUSSION

Lumbar stenosis, one of the degenerative spinal diseases, is a major health problem in the aging society.³⁾ There is still insufficient information on the natural course of lumbar stenosis. There are disagreements about surgical indications because radiographic findings are not always consistent with the patients' symptoms.^{10,11)} Reaching a precise diagnosis is essential before spine surgery and is becoming increasingly important in the aging society.¹³⁾

Surgical treatments for radiographic findings that correspond to clinical symptoms have better outcomes. Since proper use of minimal invasive spine surgery can reduce normal tissue damage while securing optimal surgical visualization, correctly identifying symptomatic lesions becomes more important, especially in the elderly.⁸⁾ In an effort to obtain more precise diagnoses, different methods, such as psychiatric evaluations, electrophysiological studies, and pain distribution chart are being employed.⁶⁾

SNRB have been used to locate pathologic lesions in patients with multiple lumbar lesions on imaging studies. The idea of selectively targeting the pain using local anesthetics is

attractive to many physicians. Many surgeons are utilizing diagnostic SNRB to decide the optimal treatment strategy for multi-level spinal lesions. However, contrary opinions have been published regarding the specificity of SNRB.^{4,12)} In particular, large amounts of local anesthetics can influence neighboring roots in addition to the targeted roots, leading to specificity.⁴⁾ Unfortunately, little information is available concerning the minimum amount of local anesthetic agent required to block an individual symptomatic root. Furthermore, multi-level blocks cannot be used to confirm the identity of a primary symptomatic lesion. Thus, several iterations of SNRB are needed for multi-level lesions.

RFSS could be essential to confirm precise targeting and to avoid iatrogenic nerve injury. In this study, we used RFSS to search for and identify the main symptomatic lesion without using tissue ablation. Furthermore, RFSS provides some benefits compared to diagnostic SNRB. Specifically, RFSS provides real-time information, as physicians can obtain negative or positive results immediately after nerve stimulation. In addition, many roots can be stimulated simultaneously. Finally, this procedure can be easily repeated.

However, RFSS also has its limitations. RFSS requires RF generator and RF needles, basically. And patient cooperation and doctor-patient relationship are essential. Sometimes, RFSS alone cannot identify the compression of one nerve root by 2 or more different sites as encountered in the “double crush syndrome.” There is little information about the maximal radiofrequency amount to avoid permanent tissue damage.

Some limitations were also seen in this case series. In one case, more than 2 roots seemed to be irritated at one stenosis site (case #6). And in others, one roots seemed to be irritated at more than 2 sites (case #3 & 5). Surgeries were undertaken reflecting these points.

As mentioned earlier, lumbar stenosis is a degenerative disease. In elderly patients, the number of lesions may increase on imaging, but not all of these lesions will cause symptoms. Since surgery always carries a risk, unnecessary surgical interventions should be avoided. Specifically, multi-level spinal surgeries are known to have higher morbidity rates than single-level surgeries.¹⁴⁾ Furthermore, spinal fusions cause higher morbidity than simple neural decompressions.¹⁵⁾ When there is insufficient evidence for the origin of the patient’s pain, the surgeon might have to operate on all visible lesions, which obviously increases the extent of surgery and the corresponding risk. In this regard, RFSS can be used to identify the appropriate surgical target and provide valuable information to the surgeons, who could then minimize the extent of surgery, benefiting the patient.

RFSS is currently unavailable due to insurance issues. Thus, the number of this study is relatively small. The authors think that RFSS is helpful for specific patients presenting multi-level degenerative pathology or having comorbidity requiring minimally invasive treatment.

CONCLUSION

In this study, we describe how to use of RFSS as a diagnostic method for multi-level lumbar spinal stenoses. Our results suggest that RFSS has diagnostic potential to verify symptomatic lesions, especially in patients with multiple spinal lesions on radiographic studies. Prospective, controlled studies are necessary to further evaluate the diagnostic value of RFSS in spinal pathologies.

SUPPLEMENTARY MATERIAL

SUPPLEMENTARY VIDEO 1

Example of how to RFSS.

[Click here to view](#)

REFERENCES

1. Brinjikji W, Luetmer PH, Comstock B, Bresnahan BW, Chen LE, Deyo RA, et al. Systematic literature review of imaging features of spinal degeneration in asymptomatic populations. *AJNR Am J Neuroradiol* 36:811-816, 2015
[PUBMED](#) | [CROSSREF](#)
2. Cho TG, Hwang SN, Park SW, Nam TK, Hong HJ, Kim YB. Percutaneous radiofrequency facet rhizotomy for cervical dorsal ramus syndrome. *J Korean Neurosurg Soc* 40:419-422, 2006
3. Choi HJ, Oh IH, Choi SK, Lim YJ. Clinical outcomes of pulsed radiofrequency neuromodulation for the treatment of occipital neuralgia. *J Korean Neurosurg Soc* 51:281-285, 2012
[PUBMED](#) | [CROSSREF](#)
4. Furman MB, Lee TS, Mehta A, Simon JI, Cano WG. Contrast flow selectivity during transforaminal lumbosacral epidural steroid injections. *Pain Physician* 11:855-861, 2008
[PUBMED](#) | [CROSSREF](#)
5. Jackson RP, McManus AC, Moore J. Lumbar spinal stenosis: treatment options for an aging population. *Mo Med* 109:466-469, 2012
[PUBMED](#)
6. Jung JH, Kim HI, Shin DA, Shin DG, Lee JO, Kim HJ, et al. Usefulness of pain distribution pattern assessment in decision-making for the patients with lumbar zygapophyseal and sacroiliac joint arthropathy. *J Korean Med Sci* 22:1048-1054, 2007
[PUBMED](#) | [CROSSREF](#)
7. Kent AR, Min X, Hogan QH, Kramer JM. Mechanisms of dorsal root ganglion stimulation in pain suppression: a computational modeling analysis. *Neuromodulation* 21:234-246, 2018
[PUBMED](#) | [CROSSREF](#)
8. Kim HS, Paudel B, Jang JS, Oh SH, Lee S, Park JE, et al. Percutaneous full endoscopic bilateral lumbar decompression of spinal stenosis through uniportal-contralateral approach: techniques and preliminary results. *World Neurosurg* 103:201-209, 2017
[PUBMED](#) | [CROSSREF](#)
9. Lee DG, Cho YW, Ahn SH, Chang MC. The effect of bipolar pulsed radiofrequency treatment on chronic lumbosacral radicular pain refractory to monopolar pulsed radiofrequency treatment. *Pain Physician* 21:E97-E103, 2018
[PUBMED](#)
10. Manchikanti L, Boswell MV, Singh V, Derby R, Fellows B, Falco FJ, et al. Comprehensive review of neurophysiologic basis and diagnostic interventions in managing chronic spinal pain. *Pain Physician* 12:E71-E120, 2009
[PUBMED](#) | [CROSSREF](#)
11. Mounce K. Back pain. *Rheumatology (Oxford)* 41:1-5, 2002
[PUBMED](#) | [CROSSREF](#)
12. North RB, Kidd DH, Zahurak M, Piantadosi S. Specificity of diagnostic nerve blocks: a prospective, randomized study of sciatica due to lumbosacral spine disease. *Pain* 65:77-85, 1996
[PUBMED](#) | [CROSSREF](#)
13. Thomas K, Wong KH, Steelman SC, Rodriguez A. Surgical risk assessment and prevention in elderly spinal deformity patients. *Geriatr Orthop Surg Rehabil* 10:2151459319851681, 2019
[PUBMED](#) | [CROSSREF](#)
14. Ulrich NH, Burgstaller JM, Held U, Winklhofer S, Farshad M, Pichierri G, et al. The influence of single-level versus multilevel decompression on the outcome in multisegmental lumbar spinal stenosis: analysis of the Lumbar Spinal Outcome Study (LSOS) data. *Clin Spine Surg* 30:E1367-E1375, 2017
[PUBMED](#) | [CROSSREF](#)

15. Ulrich NH, Burgstaller JM, Pichierri G, Wertli MM, Farshad M, Porchet F, et al. Decompression surgery alone versus decompression plus fusion in symptomatic lumbar spinal stenosis: a Swiss prospective multicenter cohort study with 3 years of follow-up. *Spine (Phila Pa 1976)* **42**:E1077-E1086, 2017
[PUBMED](#) | [CROSSREF](#)
16. Van Boxem K, Cheng J, Patijn J, van Kleef M, Lataster A, Mekhail N, et al. 11. Lumbosacral radicular pain. *Pain Pract* **10**:339-358, 2010
[PUBMED](#) | [CROSSREF](#)
17. van Kleef M, Liem L, Lousberg R, Barendse G, Kessels F, Sluijter M. Radiofrequency lesion adjacent to the dorsal root ganglion for cervicobrachial pain: a prospective double blind randomized study. *Neurosurgery* **38**:1127-1131, 1996
[PUBMED](#) | [CROSSREF](#)