

Factors Influencing Graft Endothelial Cell Density after Descemet Stripping Automated Endothelial Keratoplasty

Mohammad Ali Javadi¹, MD; Sepehr Feizi^{1,2,3}, MD, MS; Roya Jafari¹, MD; Seyed Bagher Hosseini⁴, MD
Sharareh Safapour¹, MD

¹Ophthalmic Research Center, Shahid Beheshti University of Medical Sciences, Tehran, Iran

²Ocular Tissue Engineering Research Center, Shahid Beheshti University of Medical Sciences, Tehran, Iran

³Department of Ophthalmology, Labbafinejad Medical Center, Shahid Beheshti University of Medical Sciences, Tehran, Iran

⁴Central Eye Bank of Iran, Tehran, Iran

Abstract

Purpose: To determine the factors that influence the endothelial cell density (ECD) of donor grafts after Descemet stripping automated endothelial keratoplasty (DSAEK).

Methods: This retrospective, interventional case series comprised 77 eyes of 64 patients who underwent DSAEK. Confocal microscopy was performed at the final follow-up examination to evaluate the endothelial cell count, cell morphology, and graft thickness. Univariate and multiple linear regression analyses were used to investigate recipient-, donor-, surgical-, and postoperative related variables capable of influencing graft endothelial cell counts after DSAEK.

Results: The mean patient age was 62.3 ± 15.6 years; patients were followed-up for 26.2 ± 20.9 months postoperatively. Forty-six eyes (59.7%) underwent stand-alone DSAEK; 31 eyes (40.3%) underwent DSAEK combined with cataract surgery. The donor trephination size was 8.0 ± 0.21 mm. The mean donor age was 30.4 ± 11.2 years, and the mean preoperative endothelial cell density was 3127.4 ± 315.1 cells/mm², which decreased to 1788.6 ± 716.5 cells/mm² postoperatively ($P < 0.001$). The mean postoperative central graft thickness was 102.4 ± 31.6 μ m. Univariate analysis revealed that postoperative ECD was significantly associated with death to preservation time ($P = 0.046$), graft thickness ($P = 0.016$), follow-up duration ($P = 0.005$), and graft non-attachment ($P = 0.049$). Multiple regression analyses identified graft thickness ($\beta = 10.62$, $P = 0.003$) and follow-up duration ($\beta = -22.09$, $P = 0.001$) as the significant characteristics influencing postoperative ECD.

Conclusion: The primary predictors of ECD after DSAEK were graft thickness and duration of follow-up. Surgeons' requests for ultrathin DSAEK donor grafts to improve visual outcomes might not have the desired postoperative outcome with respect to ECD.

Keywords: Descemet Stripping Automated Endothelial Keratoplasty; Influencing Factors; Postoperative Endothelial Cell Density

J Ophthalmic Vis Res 2018; 13 (1): 10-16

Correspondence to:

Mohammad Ali Javadi, MD. Ophthalmic Research Center, Shahid Beheshti University of Medical Sciences, No. 23, Paidarfard St., Boostan 9 St., Pasdaran Ave., Tehran 16666, Iran.

E-mail: ma_javadi@yahoo.com

Received: 29-10-2016

Accepted: 29-04-2017

INTRODUCTION

With recent developments in corneal transplantation, a diseased corneal layer may be selectively replaced, and Descemet stripping automated endothelial

This is an open access article distributed under the terms of the Creative Commons Attribution-NonCommercial-ShareAlike 3.0 License, which allows others to remix, tweak, and build upon the work non-commercially, as long as the author is credited and the new creations are licensed under the identical terms.

For reprints contact: reprints@medknow.com

How to cite this article: Javadi MA, Feizi S, Jafari R, Hosseini SB, Safapour S. Factors influencing graft endothelial cell density after Descemet stripping automated endothelial keratoplasty. *J Ophthalmic Vis Res* 2018;13:10-6.

Access this article online

Quick Response Code:



Website:

www.jovr.org

DOI:

10.4103/jovr.jovr_213_16

keratoplasty (DSAEK) is the gold standard treatment for various types of endothelial failure.^[1] Currently, 89% of patients with Fuchs' endothelial dystrophy and 55% of patients with post-cataract corneal edema are treated with this technique.^[2] This selective approach has several advantages compared to penetrating keratoplasty (PK), including faster visual rehabilitation, less severe surgically induced astigmatism, lower incidence of graft rejection, and preservation of biomechanical properties.^[1] Additionally, DSAEK decreases the risk of traumatic wound dehiscence.^[1] Despite these advantages, some complications, including initial endothelial cell loss, graft non-attachment, and interface abnormalities, have been encountered after DSAEK.^[3,4]

Endothelial cell loss is a leading cause of graft failure after both DSAEK and PK, but the causes can differ. The risk factors for postoperative endothelial cell loss after PK include donor and recipient age, graft diameter, lens status, the presence of glaucoma and peripheral anterior synechiae, graft rejection, and peripheral corneal diseases.^[5-7] However, the relative contributions of these factors to endothelial cell loss after DSAEK are poorly understood. Our study investigated the influence of potential predictors including recipient-, donor-, surgery-, and postoperative related variables on endothelial cell density after anatomically successful DSAEK.

METHODS

This retrospective, interventional case series enrolled consecutive eyes that underwent DSAEK between April 2006 and September 2015 and had clear grafts at the final follow-up examination. The patients had endothelial decompensation from Fuchs' endothelial dystrophy or pseudophakic bullous keratopathy. Fuchs' endothelial dystrophy was diagnosed in pseudophakic eyes when the unoperated fellow eye demonstrated stromal edema and central guttata. A minimum 3-month postoperative follow-up was required for inclusion. Patients with other ocular comorbidities, with the exception of the indication for corneal transplantation, were excluded. In addition, none of the eyes had anterior chamber intraocular lenses, filtering blebs, or tubes. This study was approved by the Institutional Ethics Committee of the Ophthalmic Research Center, which affiliated to Shahid Beheshti University of Medical Sciences, Tehran, Iran.

Donor Examinations and Preparation

All donor corneas had a qualitative grading of very good or excellent and were procured from the Central Eye Bank. The donor data obtained from the Eye Bank included age and sex, cause of death, death to preservation time (hours), and storage time (days). For statistical analysis, the death to preservation time was

divided into 3 time intervals (<20 hours, 20 - <30 hours, and 30-40 hours). Contact ultrasonic pachymetry (A/B scan; Sonomed Inc., Lake Success, NY, USA) was used to measure the central corneal thickness. Precut corneal tissue was prepared on whole globes by the same eye bank using a CB-microkeratome (Moria Inc., Doylestown, PA, USA). The microkeratome head size (350 or 400 μm) was chosen based on the central donor corneal thickness. For central thicknesses ≤ 520 μm ($n = 55$; 71.4%), the 350- μm microkeratome head was used; the 400- μm head was used for thicker donor corneas ($n = 22$; 28.6%). After lamellar dissection, corneoscleral buttons were separated and preserved at 4°C in Optisol medium (Optisol-GS preservative; Chiron Vision, Irvine, CA, USA). A noncontact specular microscope (Topcon SP-3000P; Topcon Corporation, Tokyo, Japan) was used to photograph the central section of the donor corneal endothelium, and the specular photomicrographs were evaluated for endothelial cell density (ECD), mean cell area, coefficient of variation of the endothelial cell area, and percentage of hexagonal cells. The quality of the donor cornea was graded as very good or excellent based on the specular microscopy results.

Surgical Technique

All DSAEK procedures were performed by the same surgeon under retrobulbar or general anesthesia. The central recipient epithelium was marked to outline where to strip the Descemet membrane and place the donor tissue. The anterior chamber was filled with air through a paracentesis incision, and the recipient Descemet membrane was scored in a circular pattern under the marked epithelial area using a reverse Sinskey hook. The Descemet membrane and endothelium were stripped using a Descemet stripper and removed through a 5.0-mm clear corneal incision; the anterior chamber was formed using an anterior chamber maintainer.

The donor tissue was cut from the endothelial side using a Barron donor punch (Katena, Denville, NJ, USA) before removing the anterior stroma. No orientation marks were made on the graft stroma. The trephine selected was 3 mm smaller than the horizontal corneal diameter to yield the largest diameter graft possible that would also avoid overlap with the anterior chamber angle. The donor lamella was inserted into the anterior chamber using the pull-through technique with a Busin glide and forceps (Moria Inc.). An air bubble was introduced to unfold and attach the donor lamella to the posterior stromal surface. After securing the wound with interrupted 10-0 nylon sutures, a reverse Sinskey hook was inserted from the paracentesis incision to center the donor lamella. The anterior chamber was filled with air completely for 10 minutes, then reduced to approximately 60% of the anterior chamber volume. No

venting incisions were created in the recipient cornea. In eyes with significant lens opacity, DSAEK was combined with phacoemulsification using the divide-and-conquer technique and implantation of a posterior chamber intraocular lens (IOL). Cataract extraction was performed before DSAEK surgery through a 2.8-mm clear corneal incision. The incision was then enlarged to 5.0 mm for donor graft insertion. Postoperatively, patients rested in the supine position for 12 hours.

Postoperative Course

Patients were examined at postoperative days 1, 2, 3, 7, and 30. Subsequent follow-up examinations were performed at months 3 and 6, and every 6 months thereafter. The patients had free access to the surgeon when complications developed. All patients received postoperative topical chloramphenicol and topical hypertonic 5% sodium chloride eye drops every 6 hours for 14 days and topical 0.1% betamethasone eye drops every 6 hours for 4 weeks, which were then tapered over 2-3 months. Pseudophakic patients received long-term treatment with 1 steroid drop/day to prevent graft rejection. If indicated, topical lubricants were added to hasten epithelial healing. Acute endothelial rejection reactions of the corneal transplants were treated by frequent topical 0.1% betamethasone eye drops. High intraocular pressure (IOP, >21 mmHg) was treated by steroid reduction and topical anti-glaucoma medications (with the exception of carbonic anhydrase inhibitors).

Ophthalmic Examinations and Measurements

Preoperative ocular examinations included uncorrected visual acuity (UCVA) and best spectacle-corrected visual acuity (BSCVA) using a Snellen acuity chart (in logMAR), keratometry and manifest refraction when possible, slit-lamp biomicroscopy, Goldmann applanation tonometry, and dilated funduscopy. The same examinations were conducted at each follow-up. The preoperative and postoperative examinations and measurements were performed at the same location with the same equipment during the study period. All sutures were removed by the final examination; central recipient and donor corneal thickness, ECD, and cell morphology were measured using confocal microscopy (Confoscan 3; NIDEK Technology, Padova, Italy). The full thickness of the central cornea was scanned from the endothelium to the epithelial surface, and up to 350 digital images (25 images per second) were taken using a digital video camera. The total central corneal thickness (distance between the epithelial and endothelial reflectivity peaks) and central graft thickness (distance between the interface and endothelial reflectivity peaks) were calculated and averaged from three Z-scan graphs of each cornea. The central recipient corneal thickness was

measured by subtracting the graft thickness from the total corneal thickness. A clear image of the endothelial layer was selected for endothelial evaluation. Automatic cell count processing within a 0.1-mm² standardized region of interest in the central cornea was performed to determine the postoperative endothelial cell density, mean cell area, percentage of hexagonality, and coefficient of variation.

Statistical Analysis

Data were analyzed using SPSS Statistics for Windows, Version 21.0 (IBM Corp., Armonk, NY, USA). Data were expressed as means, standard deviations, ranges, and percentages. The normal distribution of continuous variables was verified using the Kolmogorov-Smirnov test and a Q-Q plot. A paired *t*-test was used to compare pre- and postoperative values. Spearman's correlation coefficient was used to analyze the influence of donor features (age, sex, death to preservation time, storage time, endothelial cell density and hexagonality, and donor quality), recipient parameters (age, sex, indications for keratoplasty, and lens status at DSAEK), procedure related factors (central graft thickness, trephination size, and surgical technique of stand-alone DSAEK versus DSAEK combined with phacoemulsification and IOL implantation), and postoperative variables (follow-up duration, postoperative complications) on postoperative ECD. Variables selected by Spearman's correlation coefficient based on a 0.10 significance threshold were included in a multiple linear regression model and a backward elimination linear regression model to evaluate the simultaneous effects of the variables. A *P* value <0.05 was considered significant. All reported *P* values were two-sided.

RESULTS

Recipient and Donor Characteristics

Seventy-seven eyes (38 right eyes) of 64 patients (34 female subjects) were included in this study; 38 eyes (49.4%) were diagnosed with Fuchs' endothelial dystrophy; 39 (50.6%) had pseudophakic bullous keratopathy. All eyes in the latter group had a posterior chamber IOL. The mean patient age at DSAEK surgery was 62.3 ± 15.6 years (range, 19-86 years) and the mean follow-up period was 26.2 ± 20.9 months (range, 3-77 months). Forty-six eyes (59.7%) underwent DSAEK alone; 31 (40.3%) received DSAEK combined with cataract surgery. At the time of corneal transplantation, 32 eyes (41.6%) were phakic and 45 (58.4%) were pseudophakic. The mean donor trephination size was 8.0 ± 0.21 mm (range, 7.50-8.25 mm). Additional relevant donor data are presented in [Table 1].

Table 1. Donor corneas transplanted using Descemet stripping automated endothelial keratoplasty into eyes with Fuchs' endothelial dystrophy or pseudophakic bullous keratopathy

Donor features	Mean±standard deviation	Range
Age (years)	30.4±11.2	5-51
Sex (male/female)	69/8	
Death to preservation time (n%)		
<20 h	16 (20.8)	
20 to <30 h	27 (35.1)	
30 to 40 h	34 (44.1)	
Storage time (days)	1.38±0.58	1-3
Endothelial cell density (cells/mm ²)	3127.4±315.1	2584-4587
Mean cell area (µm ²)	329.0±30.1	270.0-387.0
Hexagonality (%)	63.0±11.7	51.0-86.0
Coefficient of variation	33.7±6.5	18.0-45.0
Donor quality (n%)		
Excellent	16 (20.8)	
Very good	61 (79.2)	

Clinical Outcomes and Complications

The mean preoperative BSCVA was 1.21 ± 0.65 logMAR, which significantly improved to 0.43 ± 0.30 logMAR postoperatively ($P < 0.001$). At the final follow-up examination, the mean spherical equivalent refractive error was $+0.09 \pm 1.50$ D (range, -4.50 - +3.75 D); the mean refractive astigmatism was 1.47 ± 1.16 D (range, 0.0-4.0 D).

No complications occurred intraoperatively. Postoperatively, localized graft non-attachment was observed in 2 eyes (2.6%) and resolved spontaneously. Graft decentration not requiring repositioning was observed in 3 eyes (3.9%). Interface haziness (1 eye) and graft folding (1 eye) were also observed. One eye had a fixed, dilated pupil (Urrets-Zavalía syndrome). Iridocorneal adhesion developed in 3 eyes (3.9%). Fifteen eyes (19.5%) had high IOP, which resolved with the use of anti-glaucoma eye drops and steroid reduction. Twenty-five eyes (32.5%) experienced endothelial graft rejection, which occurred once in 17 eyes, twice in 6 eyes, four times in 1 eye, and five times in 1 eye. All episodes of endothelial graft rejection were successfully treated with frequent topical 0.1% betamethasone eye drops, and all corneal grafts were clear at the final postoperative examination.

Confocal Scan Findings

The mean central corneal thickness was 579.5 ± 43.1 µm (range, 502.0-666.0 µm). The mean central recipient and graft thicknesses were 477.1 ± 47.2 µm (range, 328.0-594.0 µm) and 102.4 ± 31.6 µm (range, 51.0-174.0 µm),

respectively. The mean postoperative ECD was 1788.6 ± 716.5 cells/mm² (range, 612.0-3213.0 cells/mm²). The mean decrease in ECD was 1353.7 ± 704.4 cells/mm² (range, 318-2880 cells/mm²; $P < 0.001$), a mean cell loss of $43.3 \pm 21.4\%$. Compared to the preoperative values, there was a significant increase in the postoperative mean cell area (684.2 ± 349.2 µm²; range, 311.2-1633.9 µm²; $P < 0.001$) and the coefficient of variation (36.7 ± 7.2 ; range, 27.8-57.9; $P = 0.03$). A significant decrease in postoperative hexagonality was observed ($52.2 \pm 11.9\%$; range, 16.7-78.4%; $P < 0.001$).

Correlations

Univariate analysis revealed that postoperative ECD was significantly and negatively associated with death to preservation time ($r = -0.31$, $P = 0.046$), central graft thickness ($r = 0.36$, $P = 0.016$), follow-up duration ($r = -0.56$, $P = 0.005$), and graft non-attachment ($r = -0.31$, $P = 0.049$). Postoperative ECD demonstrated a borderline association with donor quality ($r = 0.29$, $P = 0.065$) and postoperative IOP ($r = -0.30$, $P = 0.054$). Variables with no significant influence on postoperative ECD at the univariate level included recipient age ($P = 0.68$), sex ($P = 0.95$), presenting diagnosis ($P = 0.74$), lens status at the time of DSAEK ($P = 0.35$), donor age ($P = 0.89$) and sex ($P = 0.77$), preoperative donor ECD ($P = 0.89$) and hexagonality ($P = 0.31$), storage time ($P = 0.50$), trephination size ($P = 0.14$), type of operation ($P = 0.63$), graft decentration ($P = 0.63$), IOP increase ($P = 0.57$), and endothelial graft rejection ($P = 0.22$).

Multiple regression analysis revealed that the central graft thickness had a significant positive association with the postoperative ECD ($\beta = 10.62$; 95% CI, 4.1 to 17.1; $P = 0.003$; [Figure 1]). The follow-up duration significantly and negatively influenced the postoperative ECD ($\beta = -22.09$; 95% CI, -33.94 to -10.23; $P = 0.001$; [Figure 2]). Death to preservation time ($P = 0.56$), graft non-attachment ($P = 0.64$), donor quality ($P = 0.36$), and postoperative IOP ($P = 0.70$) were not significant in the multiple regression model.

To further investigate the effect of follow-up on postoperative ECD, patients were categorized into subgroup 1 (follow-up of ≤ 24 months) or subgroup 2 (follow-up of > 24 months). Postoperative ECD was significantly higher in subgroup 1 (1935.8 ± 596.7 cells/mm²) than subgroup 2 (1696.1 ± 608.9 cells/mm², $P = 0.02$).

DISCUSSION

Despite DSAEK having some advantages over PK, endothelial cell loss after corneal transplantation remains a problem with this technique.^[1] Comparative studies have shown that DSAEK results in greater initial endothelial cell loss primarily caused by intraoperative

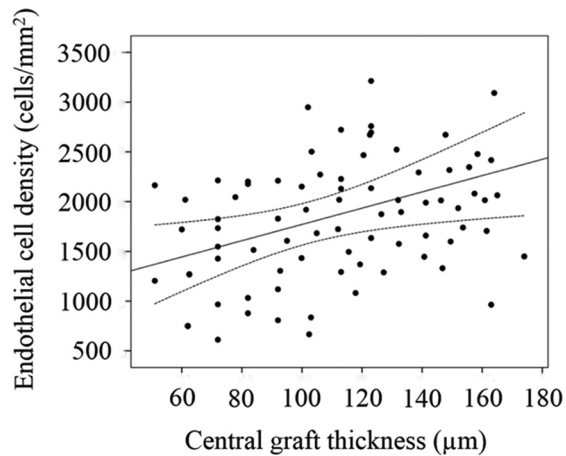


Figure 1. A scattergram illustrating the relationship between central graft thickness and postoperative endothelial cell density in eyes undergoing Descemet stripping automated endothelial keratoplasty ($r = 0.36$, $P = 0.016$). Dotted lines indicate the 95% confidence intervals for the regression line.

tissue manipulation, but the subsequent cell loss occurs more slowly than PK.^[3,4] The rate of endothelial cell loss after DSAEK in the present study (43.3%) was almost identical to that previously reported in other DSAEK studies.^[1,4,8] A wide range of endothelial cell loss occurred in the current study, although all the procedures were performed by a single experienced surgeon using a uniform DSAEK technique. This outcome indicated that, in addition to the endothelial damage caused by the initial surgery, other predisposing factors might have existed regarding the recipients' eyes, the donors, or postoperative complications, which could also affect the postoperative ECD. Previous reports have shown that endothelial cell loss after endothelial keratoplasty might be correlated with donor quality,^[9-14] preoperative ECD,^[9,10,13,14] graft diameter,^[13,15-17] graft thickness,^[18] incision size, instruments used for donor insertion, and graft detachment.^[4,19] We evaluated the complex relationships among the donor and recipient characteristics, surgery, and postoperative complications that may have been associated with the risk of lower postoperative ECD. The strength of this study was that it included only subjects with preoperative diagnoses of Fuchs' endothelial dystrophy and pseudophakic bullous keratopathy, without the accompanying risks of anterior-chamber IOLs, filtering blebs, shunt tubes, or other anterior-segment abnormalities that could influence postoperative endothelial survival.

Our results suggest that graft thickness was an influential factor and had a positive, significant correlation with postoperative ECD. For each 1.0- μm increase in central graft thickness, the postoperative ECD increased by 10.6 cells/ mm^2 . This association could be explained by decreased endothelial damage possibly occurring while inserting the thick donor tissue through

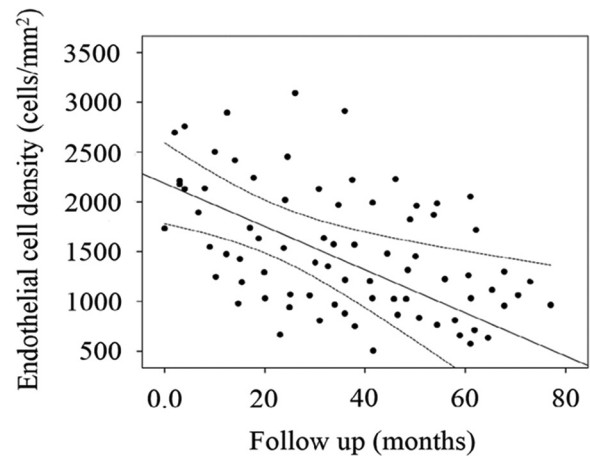


Figure 2. A scatter-gram illustrating the relationships between the follow-up length and postoperative endothelial cell density in eyes undergoing Descemet stripping automated endothelial keratoplasty ($r = -0.56$, $P = 0.005$). Dotted lines indicate the 95% confidence intervals for the regression line.

the corneal tunnel incision due to increased stromal support, which acts as a cushion. Additionally, thicker donor grafts generally unfold more easily, whereas thin grafts can be more difficult. There is no consensus on the effect of graft thickness on endothelial cell loss.^[18,20] Some authors have suggested that eyes with thin grafts had a significantly smaller loss of ECD compared with thick grafts because delivering thick grafts through the surgical wound can squeeze the tissue, resulting in greater endothelial cell loss.^[20] However, the current study indicated that DSAEK grafts <175 μm thick could be delivered through a 5-mm clear cornea incision using a Busin glide without damage to the donor tissue. Van Cleynenbreugel et al^[18] found no association between intraoperative donor lamella pachymetry and ECD at postoperative month 6. Our results and theirs could not be accurately compared because they used intraoperative donor lenticule thickness to assess the relationship between donor graft thickness and ECD.^[18] A moderate correlation between intraoperative and postoperative graft thickness values was reported.^[12]

Our results suggest that postoperative ECD after DSAEK was not influenced by recipient factors, including age, sex, presenting diagnosis, and lens status at keratoplasty. Similarly, Price et al^[13] reported no significant association between preoperative diagnosis and 5-year ECD. However, they observed a significantly higher 5-year graft survival rate for patients with Fuchs' endothelial dystrophy (95%) than for patients with pseudophakic bullous keratopathy (76%).^[13] The significantly higher postoperative endothelial cell loss in patients with pseudophakic bullous keratopathy could not be confirmed in the present series, which showed that the expected duration of endothelial cell survival did not differ between the two diagnoses. The difference in graft

survival rate observed by Price et al^[13] was attributed to 28% of eyes in the pseudophakic group having undergone prior glaucoma shunt and trabeculectomy surgeries.

The other well-known influential recipient factor in ECD is lens status; eyes with anterior-chamber IOLs have a poor prognosis.^[5,7] In the current study, all pseudophakic eyes had posterior chamber IOLs, and there was no correlation between lens status and postoperative ECD.

This study also evaluated procedure-related factors (trephination size and surgical technique) influencing postoperative ECD. Larger donor diameters are commonly used in endothelial keratoplasty procedures compared to PK because the posterior corneal diameter is greater than the anterior. Larger grafts provide a larger reservoir of healthy endothelial cells, which explains the reduced rate of postoperative endothelial cell loss. Despite these factors, no influence of graft size (7.5-8.25 mm) on postoperative ECD was observed. Similarly, previous reports on DSAEK based on graft sizes of 8.5-9.0 mm reported no association between graft size and endothelial cell survival or graft failure.^[13,15,16]

The type of operation (DSAEK versus combined DSAEK and cataract surgery) was another procedure-related variable evaluated as a predictive factor for postoperative ECD. Terry et al^[8] showed that combined DSAEK and phacoemulsification did not significantly increase endothelial cell loss, which agrees with our results. This observation indicated that concurrent phacoemulsification and posterior-chamber IOL implantation did not jeopardize graft endothelial survival. Interestingly, Price and Price^[4] found that mean cell loss was significantly lower in eyes that underwent combined procedures compared with eyes that underwent DSEK/DSAEK alone. They attributed the difference to the incision, which was a 5-mm-wide clear corneal incision in the combined procedure and a 5-mm-wide scleral tunnel in stand-alone surgery.^[4] Graft insertion through a long scleral tunnel incision can result in significantly higher cell loss due to greater compression of the donor tissue. In the current study, all grafts were inserted through a 5-mm-wide clear corneal incision using a Busin glide; no significant association was found between the type of surgery and postoperative ECD.

The evidence indicates that the four most common complications of DSAEK are graft non-attachment, endothelial rejection, graft failure, and glaucoma.^[1] In this study, 25 eyes (32.5%) had episodes of rejection. This rate was higher than those previously reported by Allan et al^[21] (7.5% in the first 2 postoperative years) and Jordan et al^[22] (7.6% in the first postoperative year, 12% after the second year). The difference could be attributed to the longer follow-up period in our study. Despite graft rejection episodes being able to reduce

ECD, we observed no significant association between endothelial graft rejection and postoperative ECD. This lack of association might have been due to the timely diagnosis and treatment of rejection episodes, as well as the continued use of low-dose topical steroids in pseudophakic eyes. Another postoperative complication in this series was high IOP (>21 mmHg), observed in 19.5% of eyes. Other investigators reported rates between 35% and 45%, indicating that increased IOP is common after DSAEK and requires close monitoring to detect and treat ocular hypertension.^[23,24] Although glaucoma and ocular hypertension are risk factors for lower ECD after corneal transplantation,^[5] our results did not reveal any significant correlation between high IOP and postoperative ECD, possibly due to regular follow-ups and close IOP monitoring. The number of other complications was too small to show any interaction with postoperative ECD.

The rate of cell loss over time differs for the DSAEK and PK procedures. DSAEK grafts demonstrate substantially more initial cell loss, but it plateaus more quickly than in eyes with similar indications that undergo PK.^[3] Despite this difference, the current study showed that endothelial cell loss after DSAEK was significantly influenced by the follow-up; for each additional month of follow-up, a decrease of 22.1 cells/mm² was observed. Similarly, Price and Price^[4] reported that the endothelial cell loss was 34% at 6 months, 36% at 12 months, and 41% at 24 months postoperatively. This association indicated that, in addition to the initial endothelial cell loss caused by surgical trauma, cell loss continues for an extended period after DSAEK for reasons that have not yet been fully elucidated. One possible explanation for continued cell loss might be related to gradual cellular redistribution, which helps repopulate adjacent decompensated areas of the recipient cornea. This ongoing reduction in the endothelial cell count could increase the risk of late endothelial failure of DSAEK grafts.

In conclusion, this study examined the effects of several potential factors on postoperative ECD, and identified graft thickness and the length of the follow-up period as predictors of ECD after DSAEK. It can be concluded that thicker grafts might result in greater postoperative ECD, possibly by providing more support for endothelial cells intraoperatively. This concept contradicts the current tendency of obtaining the thinnest possible DSAEK graft to improve visual outcomes. However, the impact of graft thickness on postoperative vision remains unresolved; studies have reached conflicting conclusions regarding its correlation with visual acuity. An investigation is now under way in this study population to elucidate the role of corneal thickness in visual acuity, refraction, and the quality of the interface after DSAEK.

Financial Support and Sponsorship

Nil.

Conflicts of Interest

There are no conflicts of interest.

REFERENCES

- Lee WB, Jacobs DS, Musch DC, Kaufman SC, Reinhart WJ, Shtein RM. Descemet's stripping endothelial keratoplasty: Safety and outcomes: A report by the American Academy of Ophthalmology. *Ophthalmology* 2009;116:1818-1830.
- 2011 Eye Banking Statistical Report. Eye Bank Association of America; Washington DC: 2010.
- Price MO, Gorovoy M, Benetz BA, Price FW Jr, Debanne SM, Lass JH, et al. Descemet's stripping automated endothelial keratoplasty outcomes compared with penetrating keratoplasty from the Cornea Donor Study. *Ophthalmology* 2010;117:438-444.
- Price MO, Price FW Jr. Endothelial cell loss after descemet stripping with endothelial keratoplasty influencing factors and 2-year trend. *Ophthalmology* 2008;115:857-865.
- Bertelmann E, Pleyer U, Rieck P. Risk factors for endothelial cell loss post-keratoplasty. *Acta Ophthalmol Scand* 2006;84:766-770.
- Writing Committee for the Cornea Donor Study Research Group, Lass JH, Benetz BA, Gal RL, Kollman C, Mannis MJ, et al. Donor age and factors related to endothelial cell loss 10 years after penetrating keratoplasty: Specular Microscopy Ancillary Study. *Ophthalmology* 2013;120:2428-2435.
- Lee HS, Kim MS. Influential factors on the survival of endothelial cells after penetrating keratoplasty. *Eur J Ophthalmol* 2009;19:930-95.
- Terry MA, Chen ES, Shamie N, Hoar KL, Friend DJ. Endothelial cell loss after Descemet's stripping endothelial keratoplasty in a large prospective series. *Ophthalmology* 2008;115:488-496.
- Terry MA, Shamie N, Chen ES, Hoar KL, Phillips PM, Friend DJ. Endothelial keratoplasty: The influence of preoperative donor endothelial cell density on dislocation, primary graft failure, and 1-year cell counts. *Cornea* 2008;27:1131-1137.
- Hesham N, Schultze RL. Impact of donor characteristics on 2-year Descemet stripping automated endothelial keratoplasty outcomes in patients with Fuchs endothelial dystrophy. *Cornea* 2015;34:6-10.
- Terry MA, Shamie N, Straiko MD, Friend DJ, Davis-Boozer D. Endothelial keratoplasty: The relationship between donor tissue storage time and donor endothelial survival. *Ophthalmology* 2011;118:36-40.
- Woodward MA, Raoof-Daneshvar D, Mian S, Shtein RM. Relationship of visual acuity and lamellar thickness in descemet stripping automated endothelial keratoplasty. *Cornea* 2013;32:e69-73.
- Price MO, Fairchild KM, Price DA, Price FW Jr. Descemet's stripping endothelial keratoplasty five-year graft survival and endothelial cell loss. *Ophthalmology* 2011;118:725-729.
- Li JY, Wilhelmus KR. Corneal regrafting after endothelial keratoplasty. *Cornea* 2011;30:556-560.
- Terry MA, Li J, Goshe J, Davis-Boozer D. Endothelial keratoplasty: The relationship between donor tissue size and donor endothelial survival. *Ophthalmology* 2011;118:1944-1949.
- Anshu A, Price MO, Price FW Jr. Descemet stripping automated endothelial keratoplasty for Fuchs endothelial dystrophy-influence of graft diameter on endothelial cell loss. *Cornea* 2013;32:5-8.
- Romano V, Tey A, Hill NM, Ahmad S, Willoughby C, Kaye SB, et al. Influence of graft size on graft survival following Descemet stripping automated endothelial keratoplasty. *Br J Ophthalmol* 2015;99:784-788.
- Van Cleynenbreugel H, Remeijer L, Hillenaar T. Descemet stripping automated endothelial keratoplasty: Effect of intraoperative lenticule thickness on visual outcome and endothelial cell density. *Cornea* 2011;30:1195-1200.
- Chaurasia S, Vaddavalli PK, Ramappa M, Garg P, Sangwan VS. Clinical profile of graft detachment and outcomes of rebubbling after Descemet stripping endothelial keratoplasty. *Br J Ophthalmol* 2011;95:1509-1512.
- Busin M, Albé E. Does thickness matter: Ultrathin Descemet stripping automated endothelial keratoplasty. *Curr Opin Ophthalmol* 2014;25:312-318.
- Allan BD, Terry MA, Price FW Jr, Price MO, Griffin NB, Claesson M. Corneal transplant rejection rate and severity after endothelial keratoplasty. *Cornea* 2007;26:1039-1042.
- Jordan CS, Price MO, Trespalacios R, Price FW Jr. Graft rejection episodes after Descemet stripping with endothelial keratoplasty: Part one: Clinical signs and symptoms. *Br J Ophthalmol* 2009;93:387-390.
- Vajaranant TS, Price MO, Price FW, Gao W, Wilensky JT, Edward DP. Visual acuity and intraocular pressure after Descemet's stripping endothelial keratoplasty in eyes with and without preexisting glaucoma. *Ophthalmology* 2009;116:1644-1650.
- Müller L, Kaufmann C, Bachmann LM, Tarantino-Scherrer JN, Thiel MA, Bochmann F. Changes in intraocular pressure after descemet stripping automated endothelial keratoplasty: A retrospective analysis. *Cornea* 2015;34:271-274.