

# Unexpected complication of the transthoracic fine-needle aspiration biopsy: Pneumoperitoneum

Sir,

Transthoracic needle aspiration biopsy (TTNAB) is a frequently used method to obtain diagnostic samples from intrathoracic masses. With the improvement in imaging technologies, performing biopsy procedures with the guidance of the computed tomography (CT) increased the diagnostic value of this procedure.<sup>[1]</sup>

Although it is considered a relatively safe method compared to other interventional diagnostic procedures, several potential life-threatening complications such as pneumothorax, parenchymal hemorrhage, hemoptysis, and air embolism would be seen.<sup>[2]</sup>

In this report, we aim to present a 71-year-old male with partial pneumothorax and unexpected massive pneumoperitoneum seen after TTNAB.

The 71-year-old male was referred to our hospital for incidentally detected 2 cm × 2.5 cm pulmonary nodule located in the right upper lobe. He was known to have a chronic obstructive pulmonary disease and a 30 pack-year history of cigarette smoking. There was no other disease or operation history in the patient's medical history.

The pulmonary nodule had a high F-18 fluorodeoxyglucose uptake in positron emission tomography and because of its peripheric localization, TTNAB was planned.

TTNAB was performed successfully, and sufficient diagnostic material was obtained. In control, posteroanterior chest radiograph, right-sided minimal pneumothorax (<15%–20%) was observed; therefore, O<sub>2</sub> inhalation therapy and close follow-up were planned. Interestingly, a control chest radiogram revealed the new onset of pneumoperitoneum and minimally increased of pneumothorax, especially in the subpulmonic area [Figure 1]. The patient did not have any complaints other than a feeling of bloating in the abdomen, and his vital signs were stable, and pneumothorax was still partial. Therefore, thoracoabdomen CT, ultrasound, and general surgery consultation were planned instead of emerging chest tube placement. Thoraco-abdomen CT was revealed right-sided partial pneumothorax, pleural adhesions, diffuse mediastinal emphysema, and pneumoperitoneum. There was not seen any obvious pathology in the diaphragm and/or abdomen in neither CT nor abdominal ultrasound, that could explain pneumoperitoneum. Finally, a 28-F chest tube was inserted. In the follow-up, both pneumothorax and pneumoperitoneum were regressed. The chest tube was removed on the 10<sup>th</sup> day of drainage [Figure 2].

Pneumoperitoneum is the presence of air in the peritoneal cavity. An erect chest X-ray is a useful and usually sufficient method to detect subdiaphragmatic free air. However, almost always, further investigation is needed to illuminate the etiology.<sup>[3]</sup>

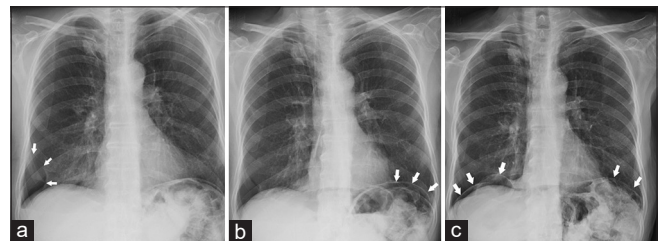
Pneumoperitoneum often occurs due to gastrointestinal perforation. However, as in our case, it can be rarely seen in patients with pneumothorax and pneumomediastinum.<sup>[4-6]</sup>

The relation between pneumothorax, pneumomediastinum, and pneumoperitoneum was observed in several studies before. Maunder *et al.* described continuing soft-tissue planes that permit air passage between the mediastinum and retroperitoneum.<sup>[4]</sup>

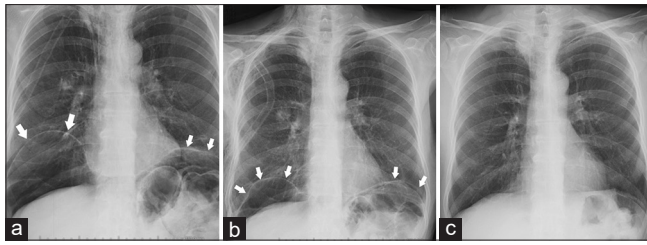
Furthermore, Kirschner described peritoneopleural transphrenic transmission of fluids or gases through congenital or acquired pores in the diaphragm.<sup>[7]</sup> Besides, several reported cases have confirmed these transmissions between mediastinum and peritoneum. Zotos *et al.* reported a case of tension pneumothorax and pneumoperitoneum after mechanical ventilation.<sup>[5]</sup> Pourmand and Shokoohi reported a combination of pneumoperitoneum, pneumothorax, and pneumomediastinum developing after colonoscopy and named this clinical situation as “triple pneumo.”<sup>[6]</sup>

The case of pneumoperitoneum related to spontaneous tension pneumothorax has been also reported in the literature.<sup>[8]</sup>

In our case, because of the pleural adhesions, the amount of pneumothorax remained partially, but this caused an increase in intrapleural pressure and the passage of air through the mediastinum to the peritoneum. This feature makes our case different from its counterparts in the literature.



**Figure 1:** (a) The first chest radiogram after the Transthoracic needle aspiration biopsy (TTNAB). Arrows indicate right-sided partial pneumothorax. (b and c) Shows progression in the pneumoperitoneum over time (Arrows indicate the borders of the diaphragm)



**Figure 2:** (a and b) After the chest tube placement, pneumoperitoneum regressed over time (Arrows indicate the borders of the diaphragm). (c) One month after the removal of the chest tube pneumoperitoneum completely regressed

There was a small amount of pneumothorax in our case, and this observation enables us to infer that the partial or even occult pneumothorax, which is not reflected in the chest X-ray, may be present with isolated pneumoperitoneum.

In conclusion, pneumothorax is a well-known complication of the TTNAB; however, the pneumoperitoneum is not a previously reported complication of this procedure. Besides, while investigating the etiology of the pneumoperitoneum, it should be kept in mind that it may coexist with partial or occult pneumothorax.

#### Statement of informed consent

Informed consent was obtained from the patient for being included in the case study.

#### Declaration of patient consent

The authors certify that they have obtained all appropriate patient consent forms. In the form, the patient has given his consent for his images and other clinical information to be reported in the journal. The patient understand that name and initials will not be published and due efforts will be made to conceal identity, but anonymity cannot be guaranteed.

#### Financial support and sponsorship

Nil.

#### Conflicts of interest

There are no conflicts of interest.

**Güntuğ Batıhan, Şeyda Örs Kaya**

*Department of Thoracic Surgery, Dr Suat Seren Chest Diseases and Chest Surgery Training and Research Hospital, The University of Health Sciences, İzmir, Turkey*

**Address for correspondence:** Dr. Güntuğ Batıhan, Department of Thoracic Surgery, Dr Suat Seren Chest Diseases and Chest Surgery Training and Research Hospital, University of Health Sciences,

35110 Yenisehir, Gaziler Street 331, İzmir, Turkey.  
E-mail: gbatihan@hotmail.com

**Submitted:** 18-Jul-2020 **Accepted:** 03-Aug-2020

**Published:** 30-Oct-2020

## REFERENCES

1. Yoon SH, Park CM, Lee KH, Lim KY, Suh YJ, Im DJ, et al. Analysis of complications of percutaneous transthoracic needle biopsy using CT-guidance modalities in a multicenter cohort of 10568 biopsies. *Korean J Radiol* 2019;20:323-31.
2. Lang D, Reinelt V, Horner A, Akbari K, Fellner F, Lichtenberger P, et al. Complications of CT-guided transthoracic lung biopsy: A short report on current literature and a case of systemic air embolism. *Wien Klin Wochenschr* 2018;130:288-92.
3. Sureka B, Bansal K, Arora A: Pneumoperitoneum: What to look for in a radiograph? *J Fam Med Prim Care* 2015;4:477-8.
4. Maunder RJ, Pierson DJ, Hudson LD. Subcutaneous and mediastinal emphysema. Pathophysiology, diagnosis, and management. *Arch Intern Med* 1984;144:1447-53.
5. Zotos PG, Kontogiannis AG, Dimakopoulos AD, Tzamali EK. Tension pneumoperitoneum in association with tension pneumothorax. *Am J Respir Crit Care Med* 2012;186:1306.
6. Pourmand A, Shokoohi H. Tension pneumothorax, pneumoperitoneum, and cervical emphysema following a diagnostic colonoscopy. *Case Rep Emerg Med* 2013;2013:583287.
7. Kirschner PA. Porous diaphragm syndromes. *Chest Surg Clin North Am* 1998;8:449-72.
8. Akoglu H, Coban E, Guneysel O. Tension pneumoperitoneum complicated with tension pneumothorax in a patient with diaphragmatic eventration. *BMJ Case Rep*. 2012;2012:bcr0120125512. Published 2012 Apr 4.

This is an open access journal, and articles are distributed under the terms of the Creative Commons Attribution-NonCommercial-ShareAlike 4.0 License, which allows others to remix, tweak, and build upon the work non-commercially, as long as appropriate credit is given and the new creations are licensed under the identical terms.

#### Access this article online

##### Quick Response Code:



##### Website:

www.lungindia.com

##### DOI:

10.4103/lungindia.lungindia\_594\_20

**How to cite this article:** Batıhan G, Kaya S. Unexpected complication of the transthoracic fine-needle aspiration biopsy: Pneumoperitoneum. *Lung India* 2020;37:555-6.

© 2020 Indian Chest Society | Published by Wolters Kluwer - Medknow