



Contents lists available at ScienceDirect

International Journal of Surgery Case Reports

journal homepage: www.casereports.com

Hypertrophic spinal pachymeningitis associated with human T-cell lymphotropic virus-1 infection and Sjogren's syndrome: A case report and brief literature review

Costansia A. Bureta^{a,d,*}, Masahiko Abematsu^a, Hiroyuki Tominaga^a, Yoshinobu Saitoh^a, Ichiro Kawamura^a, Satoshi Nagano^a, Takao Setoguchi^b, Yasuhiro Ishidou^c, Takuya Yamamoto^a, Setsuro Komiya^a

^a Department of Orthopaedic Surgery, Graduate School of Medical and Dental Sciences, Kagoshima University, Kagoshima, Japan

^b Near-Future Locomotor Organ Medicine Creation Course(Kusunoki Kai), Graduate School of Medical and Dental Sciences, Kagoshima University, 8-35-1 Sakuragaoka, Kagoshima 890-8520, Japan

^c Medical Joint Materials, Graduate School of Medical and Dental Sciences, Kagoshima University, 8-35-1 Sakuragaoka, Kagoshima 890-8520, Japan

^d Department of Neurosurgery, Muhimbili Orthopaedic and Neurosurgical Institute, P.O. Box 65474, Dar es Salaam, Tanzania

ARTICLE INFO

Article history:

Received 5 December 2017

Received in revised form 27 February 2018

Accepted 11 March 2018

Available online 15 March 2018

Keywords:

Hypertrophic spinal pachymeningitis

HTLV-1 infection

Sjogren's syndrome

ABSTRACT

INTRODUCTION: Reports of hypertrophic spinal pachymeningitis associated with human T-cell lymphotropic virus-1 (HTLV-1) infection and Sjogren's syndrome in the English literature are still very rare.

PRESENTATION OF CASE: We hereby present a case of a 78-year-old female with a history of lower extremity weakness after a fall, which fully resolved after conservative treatment. However, the symptoms recurred 4 years later, and the patient became unable to walk. The patient had no superficial or deep sensation below the level of T9, and she also had urinary retention. Magnetic resonance imaging showed that hypertrophic dura mater was compressing the spinal cord from T2 to T10. Blood testing revealed increased anti-HTLV-1 antibody, rheumatoid factor, elevation of anti-SS-A antibody and antinuclear antibody. The cerebrospinal fluid contained markedly elevated levels of total protein and cell numbers. Biopsy of the labial gland of the lip revealed chronic sialadenitis.

DISCUSSION: In collaboration with a neurologist, we diagnosed this patient with hypertrophic spinal pachymeningitis associated with HTLV-1 infection and Sjogren's syndrome. We performed laminectomy at the affected spinal levels, resected the thickened dura, and maintained the patient on steroid therapy. The patient attained a marked recovery; she could walk with a cane and her urinary retention was improved.

CONCLUSION: For the management of HSP associated with HTLV-1 and SS, we recommend surgical decompression with subsequent prolonged steroid therapy and prolonged close monitoring to achieve a good long-term outcome.

© 2018 Published by Elsevier Ltd on behalf of IJS Publishing Group Ltd. This is an open access article under the CC BY-NC-ND license (<http://creativecommons.org/licenses/by-nc-nd/4.0/>).

1. Introduction

Abbreviations: ANA, antinuclear antibody; FTA Abs, fluorescent treponema antibody absorption test; HCP, hypertrophic cranial pachymeningitis; HSP, hypertrophic spinal pachymeningitis; HTLV-1, human T-cell lymphotropic virus 1; MRI, magnetic resonance imaging; SS, Sjogren's syndrome; HAM, HTLV-1 associated myelopathy; TSP, Tropical spastic paraparesis.

* Corresponding author at: Department of Orthopaedic Surgery, Graduate School of Medical and Dental Sciences, Kagoshima University, Kagoshima, Japan.

E-mail addresses: k4280205@kadai.jp (C.A. Bureta), masa@m3.kufm.kagoshima-u.ac.jp (M. Abematsu), hiro-tom@m2.kufm.kagoshima-u.ac.jp (H. Tominaga), Yoshinobu0501@gmail.com (Y. Saitoh), kichirochan@yahoo.co.jp (I. Kawamura), naga@m2.kufm.kagoshima-u.ac.jp (S. Nagano), setoro@m2.kufm.kagoshima-u.ac.jp (T. Setoguchi), ishidou@m2.kufm.kagoshima-u.ac.jp (Y. Ishidou), tyamamo@m2.kufm.kagoshima-u.ac.jp (T. Yamamoto), skomiya@m3.kufm.kagoshima-u.ac.jp (S. Komiya).

<https://doi.org/10.1016/j.ijscr.2018.03.010>

2210-2612/© 2018 Published by Elsevier Ltd on behalf of IJS Publishing Group Ltd. This is an open access article under the CC BY-NC-ND license (<http://creativecommons.org/licenses/by-nc-nd/4.0/>).

1. Introduction

Hypertrophic pachymeningitis (HP) is a rare disease that is characterized by inflammatory fibrosis and thickening of the dura mater [1,2]. Hypertrophy of the dura mater can involve both the cranial dura and the spinal cord dura; the former is referred to as hypertrophic cranial pachymeningitis (HCP) and is the most common type, while the latter is referred to as hypertrophic spinal pachymeningitis (HSP) [3], with the majority of reported cases involving the intracranial dura [4]. Although the majority of HP cases have no identifiable cause and are referred to as idiopathic hypertrophic pachymeningitis [3], various causes of HP have been identified, including infections such as tuberculosis [5], syphilis [2], neurocysticercosis [6], human T-cell lymphotropic virus 1 (HTLV-1) [7], metabolic disease [8], intrathecal injections [9], autoimmune dis-

eases [4,10–12], vasculitis [4], and malignancy. Rarely has HSP been reported in association with both HTLV-1 infection and Sjogren's syndrome (SS). There have only been a few cases reported in the English literature of HP associated with HTLV-1 infection [7] and SS [10,11] and all of which involved the cranial dura (HCP) [10,11] and none of which had an association with both HTLV-1 infection and SS.

We report a case of thoracic spine HP associated with both HTLV-1 infection and SS; this caused severe spinal cord compression, which responded well to surgery and steroid therapy. The work has been reported in line with the SCARE criteria [13].

2. Presentation of case

A 78-year-old Asian female sustained a back injury after a fall. She presented with muscle weakness of the lower extremities, was treated conservatively, and recovered fully to being able to walk unaided. Four years later, the weakness of the lower limbs recurred and progressed to inability to walk within a 1-year period. She attended a peripheral hospital, where MRI revealed hypertrophied dura mater at the T2–T10 vertebrae levels. The patient was then referred to our hospital for further evaluation and treatment.

On presentation at our hospital, the patient had normal vital signs and no alteration of consciousness. Neurological examination revealed deterioration during manual muscle testing of the lower limbs (iliopsoas muscle: 2/1, gluteus maximus muscle: 3/1, quadriceps muscle: 2/1, tibialis anterior muscle: 2/1, gastrocnemius: 3/3). The deep tendon reflexes of the lower limbs were increased, and the pathological plantar reflex was positive bilaterally. There was an absence of superficial and deep sensation below the level of T9. The patient also had urinary retention.

Examination for infection revealed elevation of anti-HBs antibody, HBc antibody, HCV antibody, and anti-HTLV-1 antibody, but there was no evidence of other viral, bacterial, and/or fungal infection. Also there was no elevation of inflammatory markers except for an elevated erythrocyte sedimentation rate (ESR) of 50 mm/hour (normal: <20 mm/hour). Rheumatoid factor was 36.6 IU/mL (normal: <20 IU/mL), immunoglobulin (Ig) G was 2447 mg/dL (normal: 700–1600 mg/dL), IgA was 787 mg/dL (normal: 70–400 mg/dL), and IgM was 95 mg/dL (normal: 40–230 mg/dL). There was also elevation of anti-SS-A antibody (81.7 units) and antinuclear antibody (ANA; 640 units), but no elevation of other autoantibodies. Furthermore, PR3-ANCA, MPO-ANCA, and IgG4 were not elevated. Liver and renal function were normal.

Head MRI showed no abnormalities, but spinal MRI showed a hypointense mass-like lesion (hypertrophic dura) compressing the spinal cord and extending from T2 to T10 on both T1-weighted and T2-weighted imagery (Fig. 1A–C). Examination of cerebrospinal fluid (CSF) revealed substantial elevation of total protein to 1882 mg/dL (normal: 15–60 mg/dL) and cell number to 95 cells/ μ L (normal: 0–5 cells/ μ L). Biopsy of the lip was performed by an otorhinologist and showed features associated with chronic sialadenitis. Based on these findings, we diagnosed the patient with HSP associated with HTLV-1 infection and SS.

We performed laminectomy from T2 to T10. The yellowish-coloured thickened dura was resected from T2–T10. The adhesion between the dura mater and the arachnoid was slight, and the resection was relatively easy (Fig. 2A). The resulting extensive defect in the dura mater was repaired by Gore-Tex patch (Fig. 2B). The excised dura was thickened, measuring almost 17 cm in length and 6 mm in width at the widest point (Fig. 2C, D). Examination of a biopsied section of the resected dura revealed fibrous tissue, lymphocytes, and plasmocytic invasion. Immunohistologic examination revealed that the invaded cells contained a large number of CD138 and IgG-positive plasma cells. Hence, our diagnosis was

confirmed. The number of IgG4-positive cells was 10 cells/HPF, but the ratio was not higher than 40%.

In collaboration with a neurologist, the patient was treated with intravenous pulse steroid therapy at 1 g/day for 3 days, which was then tapered down to 20 mg/day; the patient is currently still on steroid therapy 2 years postoperatively. The muscle strength and sensation of the lower limbs gradually improved, and she was able to walk with a cane 12 weeks postoperatively. There have been no signs of recurrence in the 2 years following surgery (Fig. 3A, B).

3. Discussion

HSP is a very rare cause of spinal cord compression; it usually involves only a few levels of the spinal cord, but it can also occur throughout the entire spine [9]. HSP has been more often reported to involve the posterior canal [5] than the ventral. Most HSP cases are idiopathic, but secondary HSP can occur following trauma, articular rheumatism, or infections such as syphilis and tuberculosis [2,12]. HSP has very rarely been reported in the English literature to be associated with HTLV-1 infection or SS; two cases reported HP associated with HTLV-1 infection [7], and two cases reported HP associated with SS [10,11]. None of these cases of HP associated with HTLV-1 or SS involved the spine, they all involved the intracranial dura (HCP). HSP initially presents with progressive radicular symptoms, followed by muscle weakness, paraplegia, and sometimes also loss of bladder and bowel control [9,12].

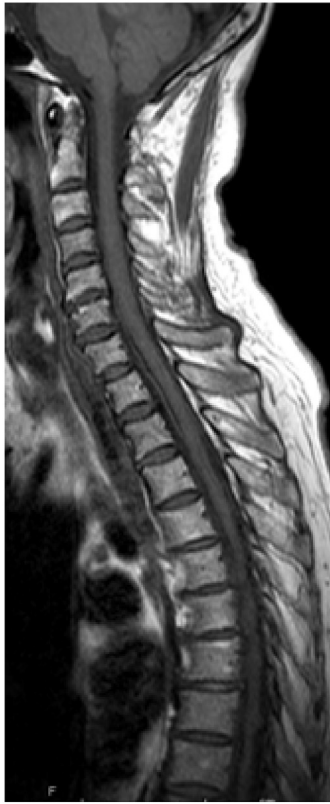Of the two potential aetiologies identified in the present case, HTLV-1 and SS, it is very difficult to determine which one caused the HSP; however, there is an established relationship between HTLV-1 infection and primary SS which strongly suggest that HTLV-1 is involved in the pathogenesis of the disease in a subset of patients with Sjögren's syndrome in endemic areas [2,14–16]. SS being an autoimmune disease caused by a combination of genetic and environmental factors such as viral infection [14]. A high HTLV-1 viral load in situ is supposed to promote the production of cytokines, especially TGF- β , resulting in the fibrous change of LSG in ACA-seropositive SS patients [15]. Salivary IgA antibodies to HTLV-1 were common among seropositive patients with Sjögren's syndrome (5/7), which might be due to increased viral activity in the salivary glands [16]. HTLV-1 has also been associated with myelopathy HAM/TSP [17].

Similarly to the present case, the two previously reported cases of HCP associated with SS had elevated ESR, rheumatoid factor, SS-A antibodies, and ANA [10,11]. In contrast, the two previously reported cases of HCP associated with HTLV-1 infection [7] had normal ESR, and were negative for rheumatoid factor, ANA, SS-A, and SS-B, except for the presence of HTLV-1 antibody detected in both serum and CSF (Table 1).

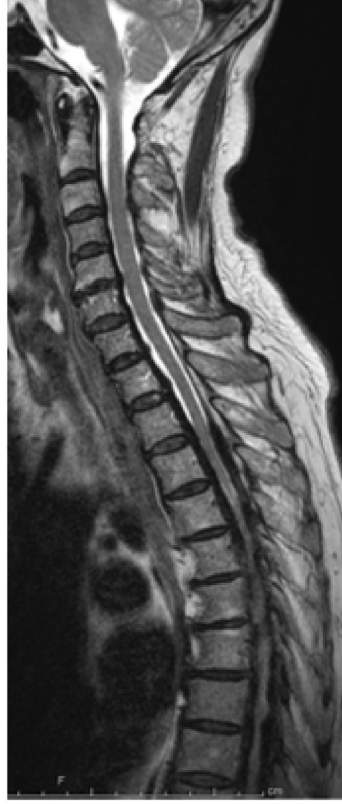In the present case, elevation of anti-SS-A antibody, ANA, and anti-HTLV-1 antibody in serum, led us to the diagnosis of HSP; furthermore, a lip biopsy showed features associated with chronic sialadenitis, and dural biopsy showed chronic inflammation and fibrosis. Hence, the diagnosis of HSP was confirmed, and other differential diagnoses such as tuberculosis, syphilis, granulomatous lesions, and malignancies were excluded. Recently HP has been considered as an IgG4-associated disease [18], but in the present case the proportion of IgG4-positive plasma cells in the dura was less than 40%.

Plain radiographs are usually less helpful in diagnosing HP [5], while MRI is considered the best radiological diagnostic tool [1]. Hence, MRI was used in the present case to identify thoracic HP. The extensive meningeal thickening resulting in severe spinal cord compression from T2 to T10 was hypointense on both T1- and T2-weighted images.

A) T1 weighted



B) T2 weighted



C) Gd enhanced

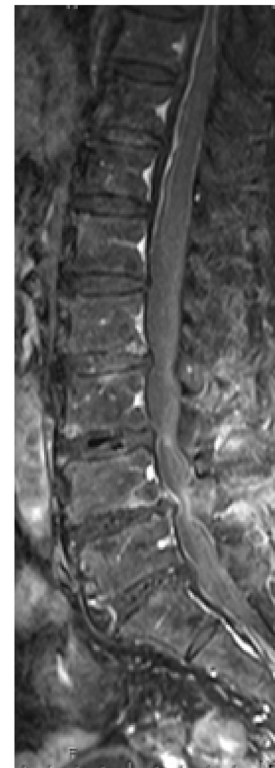
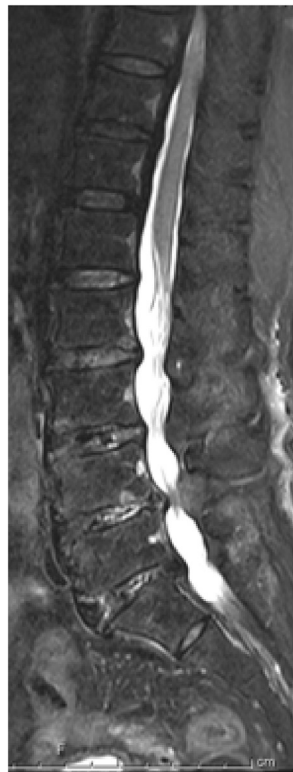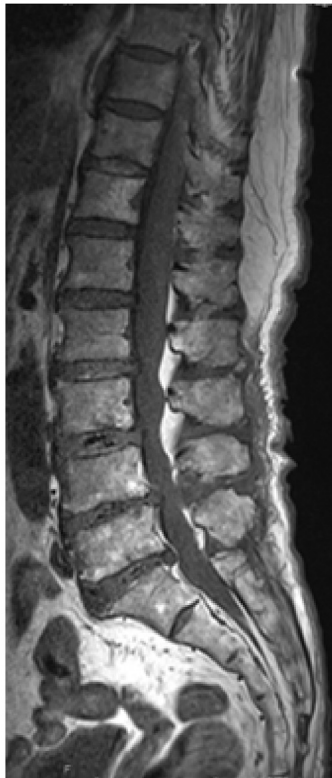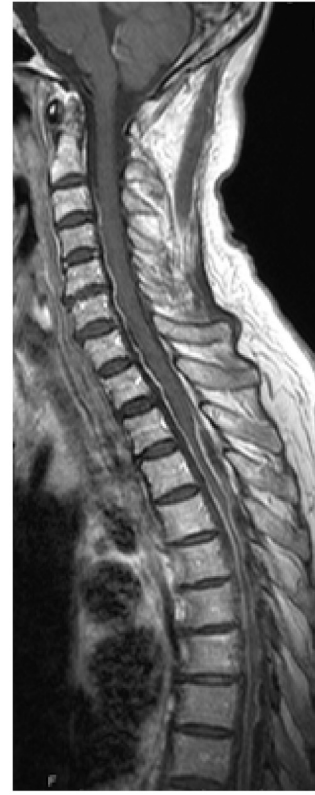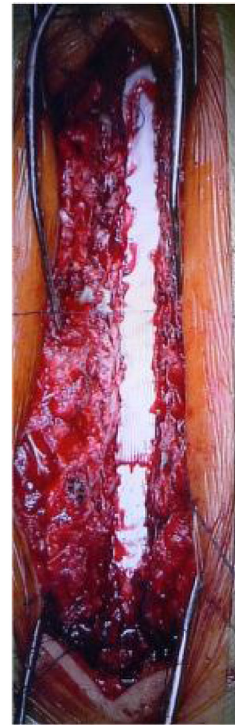
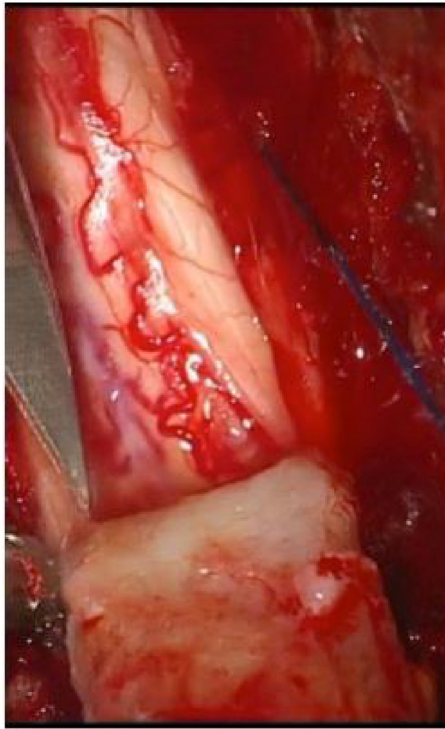


Fig. 1. Sagittal view of spine MRI showing A) T1-weighted images, B) T2-weighted images, and C) gadolinium-enhanced images. Hypertrophied dura is seen in the anterior and posterior canal, with severe compression of the spinal cord from T2 to T10.

A)

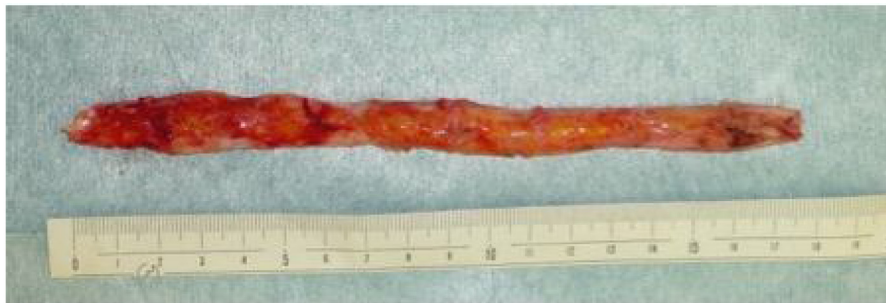B)

cranial



caudal

C)



D)

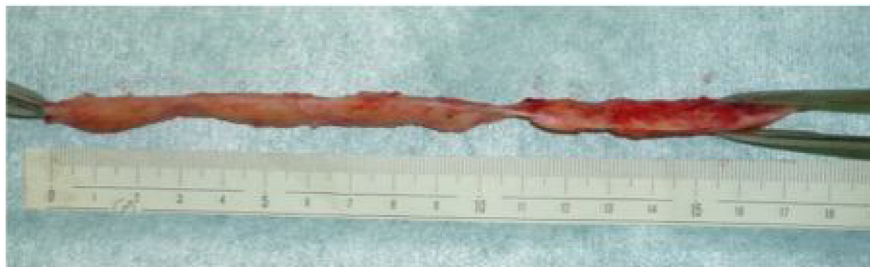

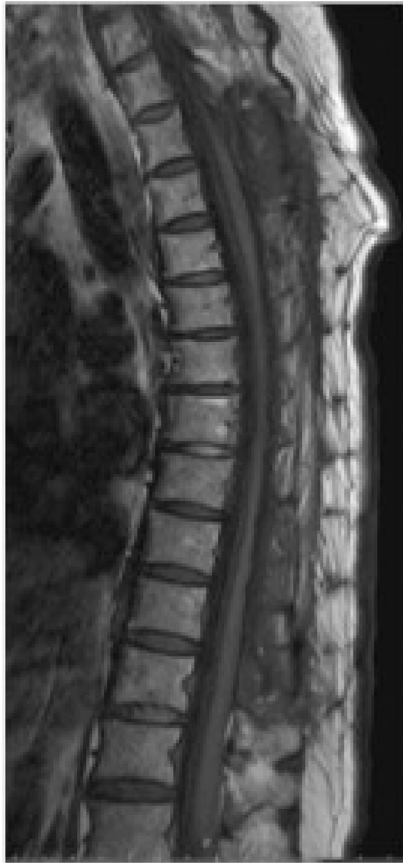Fig. 2. A) Intraoperative photograph showing the slight adhesion between the dura mater and the arachnoid. B) Intraoperative photograph showing the duraplasty conducted from T2 to T10. C, D) Photograph showing the resected sections of thickened dura.

Table 1
Characteristics of hypertrophic pachymeningitis associated with human T-cell lymphotropic virus-1 infection and/or Sjogren's syndrome

Reference	Patient age (years)/sex	Clinical features	Laboratory examination	Cerebrospinal fluid examination	Location on brain MRI	Biopsy	Treatment	Outcome	Follow-up
Kawano et al. [7]	36/M	Fascial weakness, double vision, headache	+ anti-HTLV1 antibody	+ anti-HTLV-1 antibody	Dura thickening in the falx, cranial convexity of the skull base, and cerebellar tentorium	–	Steroid therapy	Improved	–
Kawano et al. [7]	63/M	Blurry vision and a decrease in visual acuity	+ anti-HTLV-1 antibody	+ anti-HTLV-1 antibody	Dura thickening in the falx and cerebellar tentorium	–	–	–	–
Ashraf et al. [10]	47/F	Dry eyes and mouth, polyarthralgia, hearing loss, and later fascial palsy	+ SS-A, + SS-B, elevated rheumatoid factor	–	Dura mater thickening on falx and cerebellar tentorium	–	Steroid therapy	Multiple recurrences, all treated with steroid therapy	3 years
Li et al. [11]	72/M	Previously diagnosed with primary Sjogren's syndrome, headache, dizziness, general malaise, polydypsia and polyuria	Elevated erythrocyte sedimentation rate, rheumatoid factor, and IgG levels.	Negative findings	Dura thickening on the falx and cerebral tentorium	Dense, hyalinised collagen tissues, and patchy infiltrations	Steroid therapy	Improved, although pituitary functions did not recover.	Not well documented
Present study	78/F	Lower limb paresis	+ antinuclear antibody, + APCA, + AMA, + ASMA Elevated erythrocyte sedimentation rate, rheumatoid factor, IgG, and IgA + SS-A, + antinuclear antibody, + anti-HTLV-1 antibody	Elevated protein levels	T2 to T10	Lip biopsy indicated chronic sialadenitis. Dura mater biopsy showed chronic inflammation and fibrosis	Laminectomy and resection of the thickened dura, steroid therapy	Improved	2 years postoperatively

HTLV1: human T-cell lymphotropic virus-1, SS: Sjogren's syndrome.

A) T1 weighted



B) T2 weighted

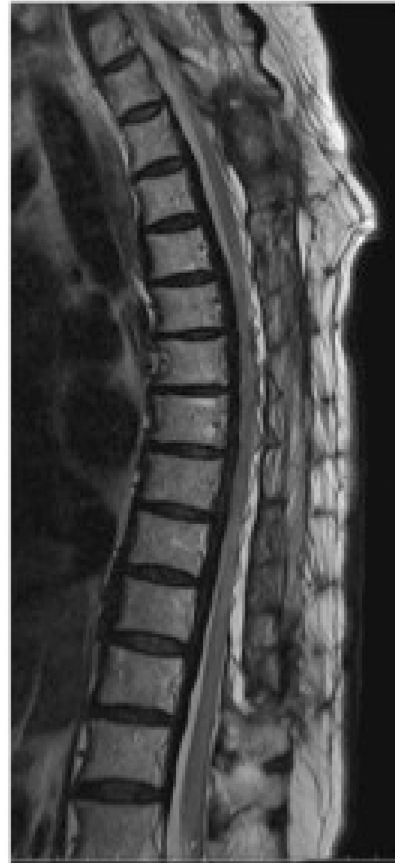

Fig. 3. Postoperative sagittal view of spine MRI showing A) T1-weighted image, and B) T2-weighted image. Spinal atrophy was improved.

Although it is recommended that whenever there is an identifiable disease it should be treated medically [4], because of the presence of paresis and urinary retention, we performed a T2–T10 surgical decompression by laminectomy and resected the thickened dura. Surgical treatment is becoming the first choice in recent reports of HSP [10]. Laminectomy and excision of the thickened dura has shown to be the best mode of treatment [5,8]. Guidetti et al. also suggested removing the entire posterior surface of the hypertrophied dura beyond the apparent limit of the lesion, as this might aid in preventing recurrence of the disease [5]. The patient in the present case is still currently on steroid therapy, although the role of steroid therapy in HSP has been criticized by others [19].

Due to the risk of recurrence, long-term follow-up is very important for correct evaluation of surgical treatment of HSP [5]. In the present case, this is currently the patient's 2 years after surgery, and we have not found any manifestations of recurrence. The patient has recovered from the sensory impairment, and can walk with a cane.

4. Conclusion

Although HSP associated with HTLV-1 infection and SS is a very rare clinical entity, this condition can be diagnosed by the presence of motor weakness, inability to walk, thickened dura on spinal MRI, and thorough laboratory testing. For the management of HSP associated with SS and HTLV-1, we recommend surgical decompression with subsequent prolonged steroid therapy and prolonged close monitoring to achieve a good long-term outcome.

Conflicts of interest

None.

Funding

None.

Ethical approval

Because it is a case report approval was exempted by our university.

Consent

Written informed consent was obtained from the patient for publication of this case report and accompanying images. A copy of the written consent is available for review by the Editor-in-Chief of this journal on request.

Author contribution

1. CB, HT, YS; – Primary authors.
2. MA, HT, IK, TY, YI, SN, TS; – Were involved in the clinical management of this patient.
3. SK; – Supervised and edited the final manuscript. All authors have approved the final article.

Guarantor

Dr. Costansia Bureta.
Dr. Hiroyuki Tominaga.
Prof. Setsuro Komiya.

References

- [1] Y. Mikawa, R. Watanabe, Y. Hino, K. Hirano, Hypertrophic spinal pachymeningitis, *Spine* 19 (5) (1994) 620–625, <http://dx.doi.org/10.1097/00007632-199403000-00021>.
- [2] T.C. Vale, T.E.C. Moraes, A. Lara, G.F. Cota, P.P. Christo, Hypertrophic cervical spinal cord pachymeningitis due to *Treponema pallidum* infection, *Neurol. Sci.* 33 (2) (2012) 359–362, <http://dx.doi.org/10.1007/s10072-011-0738-6>.
- [3] L.X. Qin, C.Y. Wang, Z.P. Hu, L.W. Zeng, L.M. Tan, H.N. Zhang, Idiopathic hypertrophic spinal pachymeningitis: a case report and review of literature, *Eur. Spine J.* 24 (Suppl. 4) (2015) S636–S643, <http://dx.doi.org/10.1007/s00586-015-3958-2>.
- [4] X. Li, J. Zhao, Q. Wang, Y. Fei, Y. Zhao, ANCA-associated systemic vasculitis presenting with hypertrophic spinal pachymeningitis: a report of 2 cases and review of literature, *Medicine (Baltimore)* 94 (46) (2015) e2053, <http://dx.doi.org/10.1097/MD.0000000000002053>.
- [5] B. Guidetti, E. La Torre, Hypertrophic spinal pachymeningitis, *J. Neurosurg.* 26 (5) (1967) 496–503, <http://dx.doi.org/10.3171/jns.1967.26.5.0496>.
- [6] T.C. Vale, H. Duani, D.L. Macedo, P.P. Christo, Cranial hypertrophic pachymeningitis secondary to neurocysticercosis, *Neurol. Sci.* 34 (3) (2013) 401–403, <http://dx.doi.org/10.1007/s10072-012-1002-4>.
- [7] Y. Kawano, J. Kira, Chronic hypertrophic cranial pachymeningitis associated with HTLV-1 infection, *J. Neurol. Neurosurg. Psychiatry* 59 (4) (1995) 435–437.
- [8] G.W. Paulson, J.N. Meagher, J. Burkhart, Spinal pachymeningitis secondary to mucopolysaccharidosis. Case report, *J. Neurosurg.* 41 (5) (1974) 618–621, <http://dx.doi.org/10.3171/jns.1974.41.5.0618>.
- [9] J.L. Bernat, C.H. Sadowsky, F.M. Vincent, R.E. Nordgren, G. Margolis, Sclerosing spinal pachymeningitis. A complication of intrathecal administration of Depo-Medrol for multiple sclerosis, *J. Neurol. Neurosurg. Psychiatry* 39 (11) (1976) 1124–1128.
- [10] V.V. Ashraf, R. Bhasi, R.P. Kumar, A.S. Girija, Primary Sjogren's syndrome manifesting as multiple cranial neuropathies: MRI findings, *Ann. Indian Acad. Neurol.* 12 (2) (2009) 124–126, <http://dx.doi.org/10.4103/0972-2327.53083>.
- [11] J.Y. Li, P.H. Lai, H.C. Lam, L.Y. Lu, H.H. Cheng, J.K. Lee, et al., Hypertrophic cranial pachymeningitis and lymphocytic hypophysitis in Sjogren's syndrome, *Neurology* 52 (2) (1999) 420–423.
- [12] K. Yunokawa, Y. Hagiya, Y. Mochizuki, N. Tanaka, M. Ochi, Hypertrophic spinal pachymeningitis associated with heavy-chain disease. Case report, *J. Neurosurg. Spine* 7 (4) (2007) 459–462, <http://dx.doi.org/10.3171/SPI-07/10/459>.
- [13] R.A. Agha, A.J. Fowler, A. Saeta, I. Barai, S. Rajmohan, D.P. Orgill, et al., The SCARE statement: consensus-based surgical case report guidelines, *Int. J. Surg.* 34 (2016) 180–186, <http://dx.doi.org/10.1016/j.ijssu.2016.08.014>.
- [14] A. Hida, M. Imaizumi, N. Sera, M. Akahoshi, M. Soda, R. Maeda, et al., Association of human T lymphotropic virus type I with Sjogren syndrome, *Ann. Rheum. Dis.* 69 (11) (2010) 2056–2057, <http://dx.doi.org/10.1136/ard.2010.128736>.
- [15] H. Nakamura, Y. Horai, A. Tokuyama, S. Yoshimura, H. Nakajima, K. Ichinose, et al., HTLV-1 virological and histopathological analysis in two cases of anti-centromere-antibody-seropositive Sjogren's syndrome, *Mod. Rheumatol.* 23 (1) (2013) 133–139, <http://dx.doi.org/10.1007/s10165-012-0641-x>.
- [16] K. Terada, S. Katamine, K. Eguchi, R. Moriuchi, M. Kita, H. Shimada, et al., Prevalence of serum and salivary antibodies to HTLV-1 in Sjogren's syndrome, *Lancet* 344 (8930) (1994) 1116–1119.
- [17] I. Kitajima, M. Osame, S. Izumo, A. Igata, Immunological studies of HTLV-1 associated myelopathy, *Autoimmunity* 1 (2) (1988) 125–131.
- [18] K.M. Lindstrom, J.B. Cousar, M.B. Lopes, IgG4-related meningeal disease: clinico-pathological features and proposal for diagnostic criteria, *Acta Neuropathol.* 120 (6) (2010) 765–776, <http://dx.doi.org/10.1007/s00401-010-0746-2>.
- [19] S.B. Senapati, S.S. Mishra, S. Das, D.K. Parida, M.C. Satapathy, Cranio cervical tuberculous hypertrophic pachymeningitis, *Surg. Neurol. Int.* 5 (2014) 52, <http://dx.doi.org/10.4103/2152-7806.130907>.

Open Access

This article is published Open Access at sciedirect.com. It is distributed under the [IJSCR Supplemental terms and conditions](#), which permits unrestricted non commercial use, distribution, and reproduction in any medium, provided the original authors and source are credited.