

Received: 2013.04.08  
Accepted: 2013.05.16  
Published: 2013.08.14

## L-asparaginase fatal toxic encephalopathy during consolidation treatment in an adult with acute lymphoblastic leukemia

Authors' Contribution:  
Study Design A  
Data Collection B  
Statistical Analysis C  
Data Interpretation D  
Manuscript Preparation E  
Literature Search F  
Funds Collection G

ABCDEF 1 **Frantzeska Frantzeskaki**  
ABCD 1 **Michalis Rizos**  
ABC 2 **Matilda Papathanassiou**  
ABC 1 **Nikitas Nikitas**  
AB 1 **Maria Lerikou**  
AB 1 **Apostolos Armaganidis**  
AB 1 **George Dimopoulos**

1 2<sup>nd</sup> Department of Critical Care, University Hospital Attikon, Athens, Greece  
2 Department of Radiology, University Hospital Attikon, Athens, Greece

**Corresponding Author:** George Dimopoulos, e-mail: [gdimop@med.uoa.gr](mailto:gdimop@med.uoa.gr)

**Patient:** Male, 51  
**Final Diagnosis:** Encephalopathy toxic  
**Symptoms:** Confusion • disorientation • drowsiness • fever  
**Medication:** L-asparaginase  
**Clinical Procedure:** —  
**Specialty:** Oncology

**Objective:** Unknown etiology





**Background:** Novel therapies have improved survival in malignancies of lymphoid origin. This improvement, however, has been at the cost of chemotherapy-related toxicities. L-asparaginase is frequently included in combination chemotherapies for acute lymphoblastic leukemia. Its use is frequently limited by significant adverse effects, such as coagulation abnormalities and cerebrovascular complications. L-asparaginase-associated encephalopathy is most often observed during the induction phase of chemotherapy and usually carries a favorable prognosis.

**Case Report:** We describe the profile of an adult with acute lymphoblastic leukemia treated with L-asparaginase, who developed toxic leukoencephalopathy during the second phase of consolidation treatment. He presented with decreased level of consciousness, which progressed to deep coma and finally brain death. MRI disclosed extensive lesions, consistent with toxic encephalopathy.

**Conclusions:** Even mild neurological symptoms should raise suspicion of these possibly fatal chemotherapy related toxicities.

**Key words:** toxic encephalopathy • L-asparaginase • leukemia

**Full-text PDF:** <http://www.amjcaserep.com/download/index/idArt/889268>

 1402  —  1  17

## Background

Malignancies of lymphoid origin are characterized by the lack of the enzyme catalyzing the transformation of L-aspartic acid to L-asparagine (asparagine synthetase); therefore, their development depends on the exogenous sources of L-asparagine [1]. Asparaginase catalyses the hydrolysis of L-asparagine to L-aspartic acid and reduces the circulating pools of L-asparagine. Because of these catalyzing properties, asparaginase is used as a specific therapy for lymphoid malignancies, such as acute lymphoblastic leukemia in children and adults. However, L-asparaginase therapy is often limited by important toxicities, coagulation abnormalities, hypersensitivity reactions, and CNS complications. L-asparaginase-related central neurotoxicity may include cerebral hemorrhage, cerebral thrombosis, parenchymal edema, and direct toxic effect on white matter, an entity known as toxic encephalopathy [2–4]. The clinical syndromes related to central neurotoxicity of chemotherapy are nonspecific and diagnosis is achieved by appropriate imaging and exclusion of other causes [5]. MRI is useful in the evaluation of CNS complications. Although these encephalopathies are generally reversible, a few fatalities during induction protocol have been reported [3,4].

We describe a fatal case of toxic leukoencephalopathy leading to brain death, possibly related to L-asparaginase, during consolidation treatment in a patient with acute lymphoblastic leukemia.

## Case Report

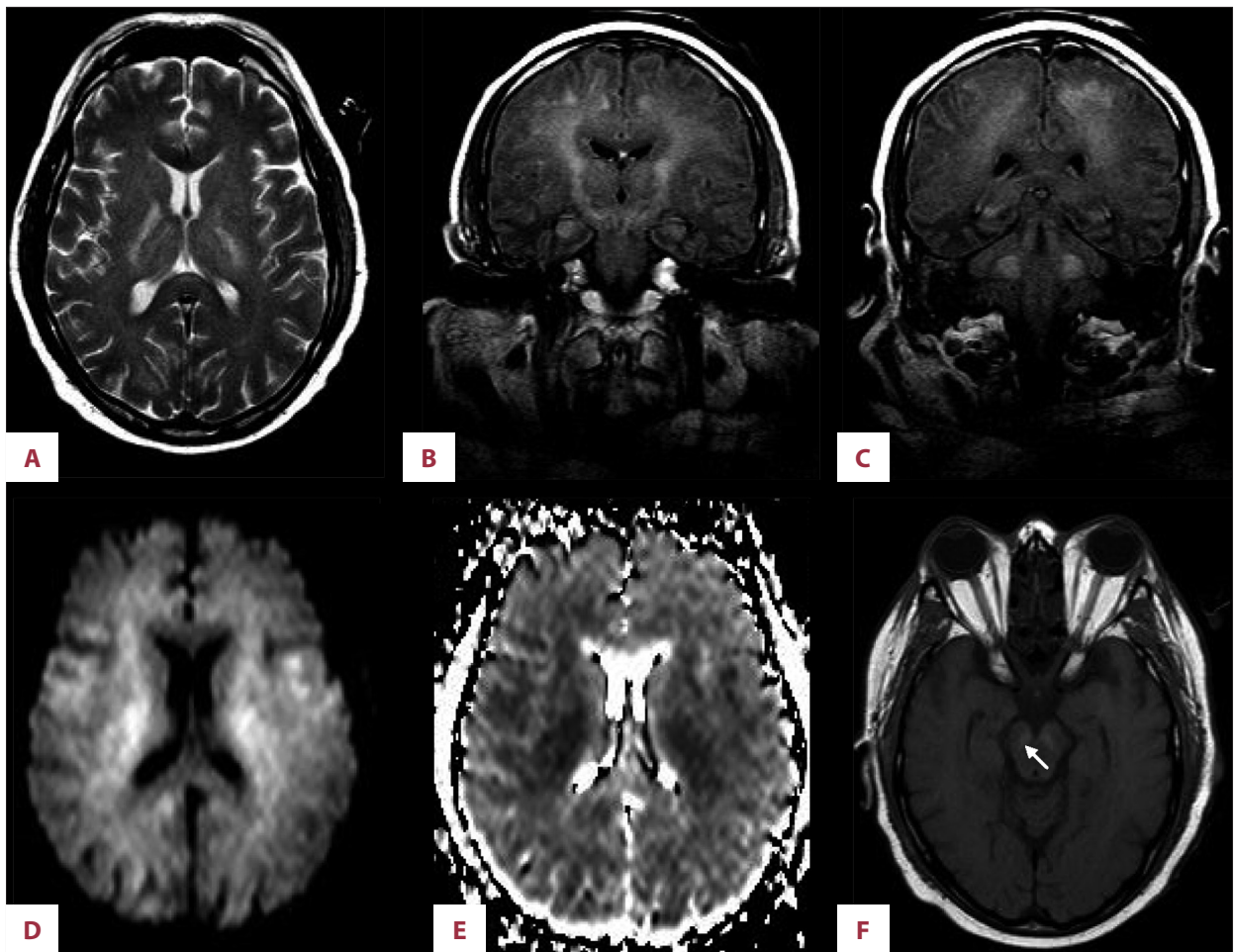
A 51-year-old man was diagnosed with acute T lymphoblastic leukemia. Leukemic central nervous system (CNS) involvement was excluded with lumbar puncture. He was treated by an induction protocol including cyclophosphamide, vincristine, doxorubicin, dexamethasone (HYPER CVAD 11a), intrathecal methotrexate, and 5 doses of L-asparaginase, with a quite good overall tolerance. During the second course of consolidation treatment, 2 days after the fifth dose of vincristine and L-asparaginase, the patient developed fever (38°C) and progressive deterioration of mental status, confusion, and drowsiness. He was lethargic, withdrew from pain, and his speech was confused, showing disorientation and disorganized thinking (GCS: 12). A brain CT revealed no abnormalities. A lumbar puncture was performed and CSF analysis result was normal, excluding infections and leukemic CNS involvement. PCR of CSF for *Neisseria meningitidis*, *Streptococcus pneumoniae*, *Haemophilus influenzae* type B, and *Listeria monocytogenes* were negative. Blood tests showed remarkable hyperammonemia (850  $\mu\text{mol/L}$ ), ALT: 160 mg/dl, AST: 118 mg/dl, fibrinogen: 99 mg/dl, and lactic acid: 6.2 mg/dl. The hyperammonemia was treated with lactulose and rifaximin. Chest x-ray

revealed bilateral opacities. Fever was attributed to hospital-acquired pneumonia and the patient was treated with meropenem (1 g tid), vancomycin (1 g tid) and trimethoprim/sulphamethoxazole (1920 mg qid). Two days later, his neurological status deteriorated and intubation was decided because of impending coma (plasma ammonia level: 232  $\mu\text{mol/L}$ ). A repeat brain CT scan revealed no abnormalities, and no signs of hemorrhage, edema, or infarcts. The patient was transferred to the ICU. His medication included the previously mentioned antibiotics and no depressant drugs. Clinical examination revealed a deeply comatose patient (GSC: 3), with pupils fixed in diameter and unresponsive to bright light. Corneal, oculo-cerebral, gag, and cough reflexes were absent. His blood pressure was 100/60 mmHg, pulse rate was 70 bpm, and body temperature was 37°C. The patient was on a ventilator with no spontaneous breathing efforts. The laboratory data revealed: SGOT: 165, SGPT: 120, LDH: 1324,  $\gamma\text{GT}$ : 596, total bilirubin: 1 mg/dl, ammonia 100  $\mu\text{mol/L}$ , and lactic acid: 2 mg/dl. Arterial blood gases, under assist control ventilation with  $\text{FiO}_2$  60%, tidal volume 500 ml and breathing rate 14, were:  $\text{PO}_2$ : 268 mmHg,  $\text{PCO}_2$ : 31 mmHg, PH: 7.32, and  $\text{HCO}_3$ : 16. MRI of the brain demonstrated high signal intensity on fast fluid attenuated inversion recovery (FLAIR) and T2-weighted images with a restricted diffusion pattern, involving the periventricular and subcortical white matter of both hemispheres, the hippocampi, internal capsules, thalami, pons, cerebral peduncles, substantia nigra and periaqueductal gray, middle and inferior cerebellar peduncles, and dentate nuclei bilaterally. T1-weighted images showed increased signal intensity in the substantia nigra compatible with hemorrhage (Figure 1). The dural sinuses and deep cerebral veins were patent. These findings were consistent with toxic encephalopathy. Over the following 24 hours, relevant clinical tests of brain death were carried out, with positive results. Therefore, brain death was confirmed on day 28 of chemotherapy, 5 days after the start of neurological symptoms.

## Discussion

Toxic leukoencephalopathy is a type of white matter damage leading to altered personality and memory impairment in mild cases and to coma and brain death in severe cases [6,7], which could be the result of exposure to a wide variety of agents, including chemotherapeutics. Among them, L-asparaginase can cause severe, potentially reversible, neurotoxicity, with a few fatal cases reported in the literature [3,4], most of them during the induction phase of therapy. Our patient described above had progressive decline of level of consciousness, leading to brain death as a result of severe toxic leukoencephalopathy, possibly caused by L-asparaginase toxicity during the consolidation period of therapy.

Our patient developed progressive deterioration of level of consciousness 2 days after the administration of L-asparaginase.



**Figure 1.** T2 (A) and FLAIR (B, C) images demonstrate increased signal intensity in the periventricular and subcortical white matter, hippocampi, internal capsules, thalami, pons, cerebral peduncles, midbrain and dentate nuclei bilaterally with restricted diffusion demonstrated on DWI (D) and ADC maps (E). Increased signal in the substantia nigra (arrow), seen on T1 (F) compatible with hemorrhage.

The initial diagnosis was encephalopathy attributed to hyperammonemia. This complication was first described 24 years ago. Asparaginase causes a large accumulation of ammonia in the plasma, caused by the hydrolysis of asparagine to L-aspartic acid and ammonia, and its inherent glutaminase activity, which metabolizes glutamine to glutamic acid and ammonia [1]. According to a recent study [8], MRI findings in acute hepatic encephalopathy, which is an example of hyperammonemic encephalopathy, include thalamic involvement (85%), internal capsule involvement (75%), periventricular white matter (80%), cerebellar white matter involvement (15%), and diffuse cortical involvement (15%). All of these findings are potentially reversible. Nevertheless, acute hyperammonemic encephalopathy can lead to poor neurologic and clinical outcomes, and strong correlations have been described between MRI findings and plasma ammonia levels [8]. However, our patient's neurological status deteriorated despite the decrease of ammonia plasma levels, and brain death occurred when ammonia levels had already normalized.

Various forms of l-asparaginase-related CNS complications have been described in the literature. Among 238 patients treated with this chemotherapeutic drug, cerebral hemorrhages were observed in 2.1% and thromboemboli in 4.2% [2]. According to Nowak-Gottle et al, the incidence of CNS thrombosis was 15% in asparaginase treated children [9]. Another report included 5 children who presented neurological symptoms related to L-asparaginase [1]: 3 of them had venous thrombosis, 1 had parenchymal hemorrhage, and 1 had encephalopathy with cortical and subcortical lesions, similar to our patient's, attributed to focal congestion edema due to peripheral venous thrombosis [2]. All of these 5 children recovered. The restricted diffusion pattern disclosed in our patient's MRI could also be attributed to congestion edema focused to microvasculature, caused by L-asparaginase-related coagulopathy. This toxicity is possibly related to transient liver dysfunction, leading to a decrease of antithrombin111 levels, fibrinogen, protein S, protein C, plasminogen, and alpha-2-antiplasmin [9]. This causes

an imbalance of the pro- and anti-coagulating systems, causing subsequent cerebrovascular complications, such as cortical infarct, intracerebral hemorrhage, hemorrhagic infarct, and dural sinus thrombosis [10,11]. According to another hypothesis, L-asparaginase causes cerebral hypersensitivity reaction [12] or direct neurocytotoxic effect from metabolizing asparagine and glutamine into aspartic acid, glutamic acid, and ammonia [13]. Korinthenberg et al. [14] observed that the increase of glutamate in the CSF during L-asparaginase therapy in rats resulted in important MRI changes in T2-weighted images, comparable to our patient's lesions. Autopsies performed in patients who developed fatal toxic encephalopathy related to other chemotherapeutics showed demyelination, myelin vacuolation, and necrosis of the white matter [15].

Other chemotherapeutic drugs can also become neurotoxic. Vincristine can cause autonomic nervous system dysfunction, peripheral neuropathy, and cranial neuropathy [16]. Although our patient had received vincristine, he did not present any signs or symptoms of peripheral neuropathy nor autonomic nervous system dysfunction. The intrathecal administration of methotrexate could also lead to spinal cord manifestations of

paraplegia, sensory deficits, neurogenic bladder, or paralytic ileus [17]. Our patient had received methotrexate intrathecally 16 days before the initiation of his symptoms, and did not develop spinal cord manifestations. Leukemic CNS involvement and an infection were excluded by lumbar puncture.

## Conclusions

The timing, the clinical signs and symptoms, and the radiological findings of our patient were all consistent with toxic encephalopathy possibly related to L-asparaginase, caused by direct neurotoxicity of the drug. CNS complications are common in patients treated with chemotherapeutics. It is sometimes difficult to differentiate the neurologic complications of chemotherapy from the neurologic complications of malignancy and to identify the responsible chemotherapeutic agent. Among these agents, l-asparaginase can lead to severe cerebrovascular complications. Even mild neurological symptoms should raise suspicion of possible neurotoxicity among clinicians. Early MRI imaging and prompt withdrawal of the offending drug is mandatory because the toxicity could be fatal.

## References:

1. Berg SL, Balis FM, McCully CL et al: Pharmacokinetics of PEG-L-asparaginase and plasma and cerebrospinal fluid L-asparagine concentrations in the rhesus monkey. *Cancer Chemother Pharmacol*, 1993; 32(4): 310-14
2. Fleischhack G, Solymosi L, Reiter A et al: [Imaging methods in diagnosis of cerebrovascular complications with L-asparaginase therapy]. *Klin Padiatr*, 1994; 206(4): 334-41
3. Chen CY, Zimmerman RA, Faro S et al: Childhood leukemia: central nervous system abnormalities during and after treatment. *Am J Neuroradiol*, 1996; 17(2): 295-31
4. Kieslich M, Porto L, Lanfermann H et al: Cerebrovascular complications of L-asparaginase in the therapy of acute lymphoblastic leukemia. *J Pediatr Hematol Oncol*, 2003; 25(6): 484-87
5. Erbetta A, Salmaggi A, Sghirlanzoni A et al: Clinical and radiological features of brain neurotoxicity caused by antitumor and immunosuppressant treatments. *Neurol Sci*, 2008; 29(3): 131-37
6. Moore-Maxwell CA, Datto MB, Hulette CM: Chemotherapy-induced toxic leukoencephalopathy causes a wide range of symptoms: a series of four autopsies. *Mod Pathol*, 2004; 17(2): 241-47
7. Crossen JR, Garwood D, Glatstein E et al: Neurobehavioral sequelae of cranial irradiation in adults: a review of radiation-induced encephalopathy. *J Clin Oncol*, 1994; 12(3): 627-42
8. McKinney AM, Lohman BD, Sarikaya B et al: Acute hepatic encephalopathy: diffusion-weighted and fluid-attenuated inversion recovery findings, and correlation with plasma ammonia level and clinical outcome. *Am J Neuroradiol*, 2010; 31(8): 1471-79
9. Nowak-Gotti U, Wolff JEA, Kuhn. Enhance thrombin generation, P-von Willebrand factor, P-fibrin D-Dimer and P-plasminogen activator 1: predictive for venous thrombosis in asparaginase treated children. *Fibrinolysis*, 1994; 8: 63-65
10. Chen CY, Zimmerman RA, Faro S et al: Childhood leukemia: central nervous system abnormalities during and after treatment. *Am J Neuroradiol*, 1996; 17(2): 295-310
11. Niemeyer CM, Hitchcock-Bryan S, Sallan SE: Comparative analysis of treatment programs for childhood acute lymphoblastic leukemia. *Semin Oncol*, 1985; 12(2): 122-30
12. Larson RA, Fretzin MH, Dodge RK et al: Hypersensitivity reactions to L-asparaginase do not impact on the remission duration of adults with acute lymphoblastic leukemia. *Leukemia*, 1998; 12(5): 660-65
13. Ohnuma T, Holland JF, Freeman A et al: Biochemical and pharmacological studies with asparaginase in man. *Cancer Res*, 1970; 30(9): 2297-305
14. Korinthenberg R, Ullrich K, Ritter J et al: Electrolytes, amino acids and proteins in lumbar CSF during the treatment of acute leukemia in childhood. *Acta Paediatr Scand*, 1990; 79(3): 335-42
15. McKinney AM, Kieffer SA, Paylor RT et al: Acute toxic leukoencephalopathy: potential for reversibility clinically and on MRI with diffusion-weighted and FLAIR imaging. *AJR Am J Roentgenol*, 2009; 193(1): 192-206
16. Sandler SG, Tobin W, Henderson ES: Vincristine-induced neuropathy. A clinical study of fifty leukemic patients. *Neurology*, 1969; 19(4): 367-74
17. Mena H, Garcia JH, Velandia F: Central peripheral myelinopathy associated with systemic neoplasia and chemotherapy. *Cancer*, 1981; 48: 1724-37