



Persistent ventricular preexcitation despite right bundle branch block

Taihei Itoh, Takumi Yamada*

Division of Cardiovascular Disease, University of Alabama at Birmingham, Birmingham, AL, USA

ARTICLE INFO

Article history:

Received 25 December 2017

Accepted 25 January 2018

Available online 31 January 2018

Keywords:

Fasciculoventricular pathway

Preexcitation

Mahaim fiber

Bundle branch block

ABSTRACT

A 44-year-old man with a history of ventricular preexcitation and supraventricular tachycardia was evaluated. The baseline electrocardiogram exhibited ventricular preexcitation with a normal PR interval and a minimally negative delta wave in lead V1 and positive delta waves in the inferior leads. The administration of adenosine resulted in a progressive prolongation of the PR interval with a fixed preexcitation degree, suggesting the presence of antegrade conduction over the fasciculo-ventricular pathway. When complete right bundle branch block occurred, the degree of preexcitation never changed. These findings suggested that the fasciculo-ventricular pathway was likely to be connected to the left-sided His-Purkinje system.

Copyright © 2018, Indian Heart Rhythm Society. Production and hosting by Elsevier B.V. This is an open access article under the CC BY-NC-ND license (<http://creativecommons.org/licenses/by-nc-nd/4.0/>).

1. Introduction

We describe a case with a fasciculo-ventricular (FV) pathway that was suggested to be located in the left ventricle by the electrophysiological findings.

2. Case report

A 44-year-old man with a history of ventricular preexcitation on the 12-lead electrocardiogram (ECG) and palpitation underwent an electrophysiological study (EPS). The baseline ECG exhibited ventricular preexcitation with a normal PR interval (112 msec) and a minimally negative delta wave in lead V1 and positive delta waves in the inferior leads (Fig. 1A). An 18 mg of adenosine was administered, resulting in a progressive prolongation of the PR interval with a fixed preexcitation degree (Fig. 1A).

An EPS was undertaken with multipolar catheters placed in the coronary sinus, His bundle region, and right ventricular apex. The baseline AH and HV intervals were 75 and 29 msec, respectively (Fig. 1B). Programmed atrial stimulation revealed a sudden prolongation of the AH interval followed by an induction of typical atrioventricular (AV) nodal reentrant tachycardia (AVNRT) with the same degree of ventricular preexcitation as that during sinus

rhythm. The slow pathway was then mapped and successfully ablated, and thereafter no tachyarrhythmias were induced by any pacing maneuvers on or off isoproterenol. While mapping the slow pathway, inadvertently complete right bundle branch block (RBBB) occurred without any change to the degree of preexcitation (Fig. 2).

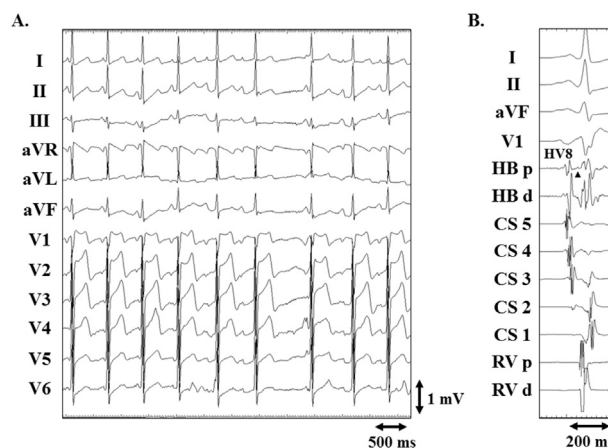


Fig. 1. Twelve-lead electrocardiograms exhibiting the effect of the administration of adenosine (panel A) and intracardiac tracings exhibiting the baseline AH and HV intervals (panel B). During the administration of adenosine, the degree of preexcitation was fixed in spite of the progressive prolongation of the PR interval. The arrowhead indicates a His bundle electrogram.

CS 1 to 5 = the first (distal) to fifth (proximal) electrode pairs of the coronary sinus catheter; HB = His bundle; RV = right ventricle; Xd(p) = the distal (proximal) electrode pair of the relevant catheter.

* Corresponding author. Division of Cardiovascular Disease, University of Alabama at Birmingham, FOT 930A, 510 20th Street South, 1530 3rd AVE S, Birmingham, AL 35294-0019, USA.

E-mail address: takumi-y@fb4.so-net.ne.jp (T. Yamada).

Peer review under responsibility of Indian Heart Rhythm Society.

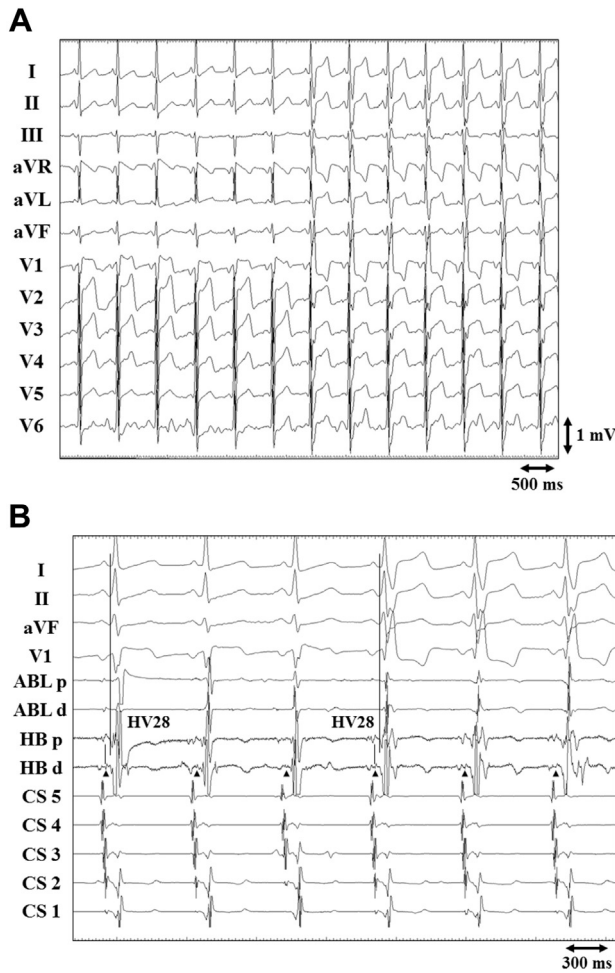


Fig. 2. Twelve-lead electrocardiograms (panel A) and cardiac tracings (panel B) exhibiting a transient complete right bundle branch block (CRBBB) occurring while mapping the slow pathway.

Note that there is no difference in the degree of preexcitation between sinus rhythm and CRBBB.

The arrowheads indicate His bundle electrograms. ABLd(p) = the distal (proximal) electrode pair of the ablation catheter. The other abbreviations are as in Fig. 1.

3. Discussion

In this case, the response to adenosine suggested the presence of antegrade conduction over an FV pathway and excluded the possibility of any antegrade conduction over any other accessory pathways. FV pathways are considered to begin from the His bundle or bundle branches and insert into the ventricular myocardium [1]. For several reasons, it may be difficult to exactly identify the location of the FV pathway, although it may be just a scientific concern, because the FV pathway never causes tachyarrhythmias and thus is only a cosmetic issue. First, on the ECG, the

preexcitation of the FV pathway is similar to that of anteroseptal and midseptal AV pathways [2]. Second, the degree of preexcitation of the FV pathway is more likely to be affected by the conduction properties of the His-Purkinje system than AV pathways because of its anatomical location [3].

An occurrence of bundle branch block may be helpful for predicting the location of the FV pathway. If the preexcitation disappears with the occurrence of RBBB, the FV pathway is suggested to be located on the right side [4]. In this case, the degree of preexcitation was the same before and after the complete RBBB occurred, suggesting that the antegrade conduction over the FV pathway was persistent during the complete RBBB. Two possible locations of the FV pathway might be considered to explain these findings. First, the FV pathway might have been connected to the right-sided His-Purkinje system at a site proximal to the conduction block site that should be located at the proximal portion of the His-Purkinje system to cause the complete RBBB. However, this location was unlikely because a right-sided FV pathway should have pre-excited the right ventricle and masked the RBBB. Therefore, the FV pathway was likely to be connected to the left-sided His-Purkinje system. The FV pathways usually insert into the right ventricle, but very rarely into the left ventricle [5]. The left-sided FV pathway should preexcite the left ventricle and usually cause a RBBB pattern [5]. However, in this case the delta waves in lead V1 were negative. This finding suggested an insertion of the FV pathway into the ventricular septum, but could not predict whether the FV pathway was located on the right or left side. Therefore, in this case the occurrence of RBBB was helpful for predicting the left-sided FV pathway.

4. Conclusion

This report illustrated a case with a left-sided FV pathway that was diagnosed by a persistent ventricular preexcitation despite an administration of adenosine and inadvertent occurrence of RBBB.

Financial support

There was no financial support for this study.

References

- [1] Lev M, Fox 3rd SM, Bharati S, Greenfield Jr JC, Rosen KM, Pick A. Mahaim and James fibers as a basis for a unique variety of ventricular preexcitation. *Am J Cardiol* 1975;36:880–8.
- [2] Sternick EB, Rodriguez LM, Gerken LM, Wellens HJ. Electrocardiogram in patients with fasciculoventricular pathways: a comparative study with anteroseptal and midseptal accessory pathways. *Heart Rhythm* 2005;2:1–6.
- [3] Gallagher JJ, Smith WM, Kasell JH, Benson Jr DW, Sterba R, Grant AO. Role of Mahaim fibers in cardiac arrhythmia in man. *Circulation* 1981;64:176–89.
- [4] Ali H, De Ambroggi G, Foresti S, Cappato R. Mechanical block of a manifested accessory pathway: what is the preexcitation variant?. *J Cardiovasc Electrophysiol*. doi: 10.1111/jce.12843.
- [5] Sternick EB, Gerken LM, Vrandečić MO, Wellens HJ. Fasciculoventricular pathways: clinical and electrophysiologic characteristics of a variant of preexcitation. *J Cardiovasc Electrophysiol* 2003;14:1057–63.