



Cross-sectional Study

Bilateral swollen optic nerve head etiology and management: A cross-sectional study

Mona Abbas^{a,*}, Ali Alahmad^{b,**}, Ghassan Hamzeh^c, Yusra Haddeh^d

^a Neurologist, Damascus University Faculty of Medicine, Internal Medicine Department, Neurology Department: Damascus, Damascus Governorate, Syria

^b Internist, Resident Cardiologist, Damascus University Faculty of Medicine, Internal Medicine Department: Damascus, Damascus Governorate, Syria

^c Neurologist, Head of Department, Damascus University Faculty of Medicine, Internal Medicine Department, Neurology Department: Damascus, Damascus Governorate, Syria

^d Ophthalmologist, Damascus University Faculty of Medicine, Department of Ophthalmology: Damascus, Damascus Governorate, Syria



ARTICLE INFO

Keywords:

Low visual acuity
Tumors
Venous sinus thrombosis
Idiopathic intracranial hypertension
Surgery
Leptomeningeal metastasis

ABSTRACT

Background: The differential diagnosis of optic disc edema varies according to the presence of unilateral or bilateral edema. Papilledema may occur due to benign and life-threatening causes, but even benign causes may leave serious consequences for vision if not treated emergently. This study aimed to find out the prevalence of these causes in two major hospitals in Syria and observing the response of edema to treatment within a month and how visual acuity can be saved if edema is treated urgently.

Methods: This cross-sectional study was conducted in Al-Assad and Al-Mowasat Hospitals in Syria from October 2020 to the beginning of February 2022. It included 50 patients who had bilateral optic disc edema. Then a full study was carried out to reach the diagnosis and management appropriately and to monitor the extent of the efficacy of conservative measure in reducing edema, and how many of them needed surgical intervention.

Results: the study included 50 patients, 13 males and 37 females, the most common diagnosis was venous sinus thrombosis (12 cases with 24%), followed by idiopathic intracranial hypertension and tumors (10 cases each by 20%), infectious meningitis (8 cases by 16%), leptomeningeal metastasis (5 cases by 10%), arterial hypertension (3 cases by 6%) and autoimmune meningitis (2 by 4%). Edema improved after management within a month in most patients (37 patients by 74%) and edema was accompanied by low visual acuity in 21 patients (42%). 20 patients (40%) needed surgical intervention. Visual acuity reduced in 10 patients (20%) despite all treatments.

Conclusion: venous sinus thrombosis is the most common cause of bilateral optic disc edema then idiopathic intracranial hypertension and tumors, and despite the provision of all treatments, the visual acuity of 20% of patients has decreased.

1. Introduction

Optic nerve swelling refers to the abnormal appearance of the intraocular portion of the optic nerve (so-called optic disc) when the nerve is elevated and its borders are difficult to ascertain [1].

Anatomically, optic nerve is divided into several compartments [2]:

- ▶ The intraocular part is only 1–2 mm in length).
- ▶ The intra orbital portion (20–30 mm).
- ▶ The intracanalicular portion (~10 mm) is where the nerve runs through the optic canal in the lesser wing of the sphenoid bone.

- ▶ The intracranial portion (10–15 mm in length), which eventually leads to optic chiasm.

The optic nerve head may swell in response to almost any insult that affects it in the intraocular, intra orbital and sometimes in the intracanalicular compartments) [3].

While the term "papilledema" is often used broadly to denote a swollen optic nerve head, the term "papilledema" should be reserved for optic disc swelling that is due to raised intracranial pressure [3].

Any entity that increases intracranial pressure may lead to papilledema. These include [4,5]:

* Corresponding author.

** Corresponding author.

E-mail addresses: monaabass687@gmail.com (M. Abbas), alialahmad93.md@gmail.com (A. Alahmad), hamzeh_ghassan@yahoo.com (G. Hamzeh), almawla1@hotmail.com (Y. Haddeh).

<https://doi.org/10.1016/j.amsu.2022.104059>

Received 18 May 2022; Received in revised form 19 June 2022; Accepted 21 June 2022

Available online 26 June 2022

2049-0801/© 2022 The Authors. Published by Elsevier Ltd on behalf of IJS Publishing Group Ltd. This is an open access article under the CC BY-NC-ND license (<http://creativecommons.org/licenses/by-nc-nd/4.0/>).

- Intracranial mass lesions (e.g., tumor, hematoma)
- Increased cerebrospinal fluid (CSF) production (e.g., choroid plexus papilloma)
- Decreased CSF absorption (e.g., arachnoid granulation adhesions after bacterial meningitis)
- Obstruction of venous outflow (e.g., venous sinus thrombosis, jugular vein compression, neck surgery)
- Idiopathic intracranial hypertension (pseudotumor cerebri)
- Malignant hypertension: severe systemic hypertension can cause a change in the optic nerve head that resembles papilledema. Thus, all patients with bilateral disc edema should have their blood pressure measured [6,7].

However, we use the term (papillitis) to denote a swollen optic nerve that is due to optic neuropathy.

The main finding in patients with bilateral optic neuropathy (in contrast to those with papilledema) is a varying degree of visual dysfunction.

For papillitis, the most common causes are demyelinating optic neuritis, neuromyelitis optica spectrum disorder and anti-MOG optic neuritis and there are many underlying causes which are much broader [8], including viral syndromes, toxoplasmosis, cat scratch disease, sarcoidosis, syphilis, Lyme disease, systemic lupus erythematosus and granulomatosis with polyangiitis [9,10].

Optic neuropathy occurs in approximately 5% of patients with sarcoidosis and may be the initial manifestation [11,12]. Clinical features are similar to optic neuritis. Bilateral involvement has been reported in 24–64% [12,13].

Diagnostic testing can help differentiate papilledema from other causes of disc edema, follow the course of papilledema, and determine the underlying etiology.

The first step is neuroimaging of the brain. Magnetic resonance imaging (MRI) with gadolinium contrast is generally preferred.

Additional sequences, magnetic resonance venography (MRV), can be used to detect venous obstruction in the dural sinuses and in the neck.

If neuroimaging is normal, lumbar puncture should be done for opening pressure and analysis.

2. Methods

This cross-sectional study included 50 patients older than 18 and have bilateral edema in ALASSAD and ALMOUSAT hospitals in Syria. The data was collected prospectively from October 2020 to the beginning of February 2022 and the study protocol was approved by the Research Ethics Committee of Damascus University and in accordance with the Declaration of Helsinki and in line with the STROCSS criteria [14]. Patients with pseudopapilledema (drusen) were excluded then visual acuity was estimated by ophthalmologist and for each patient who met the inclusion and exclusion criteria, neurologic signs or symptoms (seizures or weakness) was documented.

First, arterial blood pressure was measured as it is one of the causes of bilateral edema, then MRI and MRV (to exclude CVT) was done for all patients. If the cause was not determined, the study was completed by conducting the necessary tests on the cerebrospinal fluid and peripheral blood and by measuring the opening pressure of CSF.

Upon reaching the correct diagnosis, the appropriate treatment was provided either by conservative treatment or by surgery (if the edema did not improve) and finally, we determine the prognosis of each cause of bilateral edema after a month on visual outcome.

3. Statistical analysis

To study the significance of the correlation between any two descriptive variables (to know whether a statistically significant relationship was found between two descriptive variables) by applying the chi-squared statistic.

The estimation of statistical differences was adopted at the level of statistical significance of 0.05, and therefore the statistical decision can be given through the P-value as follows: if p-value is less than 0.05, there are statistical essential differences in the evaluation of differences and relation. we studied the relationship of diagnosis (venous sinus thrombosis, other diagnoses) with each of the variables (gender, age, optic disc edema improvement, visual acuity, associated neurologic signs) using chi-squared statistic.

4. Results

Study included 50 patients, distributed by gender, to 13 males (26%) and 37 females (74%). Most of the patients were between 18 and 35 years old (70%), and 11 cases were between 40 and 50 years old (22%) and 4 cases Their ages ranged between 51 and 60 years (8%). The most common diagnosis was venous sinus thrombosis (12 cases, 24%), followed by idiopathic intracranial hypertension and tumors (10 cases each, 20% each), meningitis (8 cases, 16%), leptomenigeal metastases 5 cases, 10%), arterial hypertension (3 cases, 6%), and finally autoimmune inflammation (2 cases), 4%), as summarized in Figure (1).

Optic disc edema was associated with decreased visual acuity in 21 patients (42%).

The main presenting symptom was headache in (90%) of patients (45 cases), while (10%) of patients returned due to reduced visual acuity (5 cases).

Table No (1) shows the relative distribution of study cases according to age groups and diagnosis.

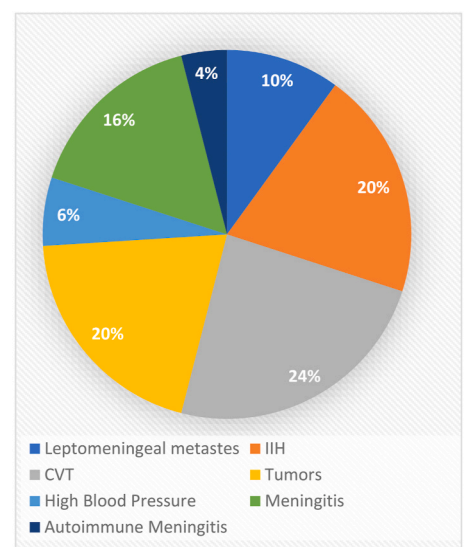
Table No (2) shows the relative distribution of the study cases according to visual acuity and diagnosis.

Conservative management (acetazolamide, anticoagulants and CSF drainage) was sufficient to improve edema in 30 patients (60%), while 20 patients (40%) required surgical intervention.

4.1. Comparison of patients with CVT (cerebral venous sinus thrombosis) vs patients with papilledema from other causes

Compared with patients with papilledema from other causes, the patients.

With CVT are more likely to have other neurologic signs, and optic



IHH: idiopathic intracranial hypertension

CVT: cerebral venous sinus thrombosis

Fig. 1. Distribution of study cases according to diagnosis.

Table 1
Distribution of study cases according to age groups and diagnosis.

Diagnosis		age-group			Total
		18–35	40–50	51–60	
Leptomeningeal metastases	Numbers	3	1	1	5
	%	60%	20%	20%	100%
	Diagnosis				
	% Age	8.6%	9.1%	25%	10%
idiopathic intracranial hypertension	% Total	6%	2%	2%	10%
	numbers	10	0	0	10
	%	100%	0%	0%	100%
	Diagnosis				
cerebral venous sinus thrombosis	% Age	28.6%	0%	0%	20%
	% Total	20.0%	0%	0%	20%
	Numbers	9	3	0	12
	Diagnosis	75%	25%	0%	100%
TUMER	%				
	%Age	25.7%	27.3%	0%	24%
	% Total	18%	6%	0%	24%
	Numbers	5	3	2	10
HIGH BLOOD PRESSURE	%	50%	30%	20%	100%
	Diagnosis				
	% Age	14.3%	27.3%	50%	20%
	% Total	10%	6%	4%	20%
MENINGITIS	numbers	2	1	0	3
	%	66.7%	33.3%	0%	100%
	Diagnosis				
	% Age	5.7%	9.1%	0%	6%
AUTOIMMUNE MENINGITIS	% Total	4%	2%	0%	6%
	Numbers	5	2	1	8
	Diagnosis	62.5%	25.0%	12.5%	100%
	%				
TOTAL	%Age	14.3%	18.2%	25%	16%
	Total %	10%	4%	2%	16%
	Numbers	1	1	0	2
	Diagnosis	50%	50%	0%	100%
TOTAL	%				
	Age%	2.9%	9.1%	0%	4%
	% Total	2.0%	2.0%	0%	4%
	Numbers	35	11	4	50
TOTAL	Diagnosis	70%	22%	8.0%	100%
	%				
	%Age	100%	100%	100%	100%
	%Total	70%	22%	8.0%	100%

disc edema improved in all patients with CVT within month with conservative therapy without need to surgery so it was the best for visual outcome compared with other causes. While most of patients of all reasons were women between (18–35).

There are statistically significant differences between the patients diagnosed with “sinus venous thrombosis” with patients with other diagnoses in the sample of patients whose edema improved within month, as this difference was in favor of patients diagnosed with “sinus venous thrombosis (100% versus 65.8%)

There are no statistically significant differences between the of patients diagnosed with “venous sinus thrombosis” compared with patients with other diagnoses in each of the patient samples (females: p-value 0.376), patients aged between 18 and 30 years (p-value: 0.501), visual acuity reducing (p-value: 0.151) and, patients who have Accompanied neurotic signs: p-value: 0.060).

Table 3 shows the distribution of the study cases for each of (females, age group [18–35], edema improvement, decreased visual acuity, neurologic signs) according to the diagnosis.

Table 4 distribution of the study cases for each of (females, age group [18–35], edema improvement, decreased visual acuity, signs of accompanying neurologic signs) according to diagnosis (sinus thrombosis).and other diagnoses) with the results of the Chi-Square. Test.

CVT was the most important cause of bilateral edema in 12 patients, and it was also the best in terms of edema improvement While 4 out of 10 patients with IIH needed a surgical intervention because their edema didn't improve on other conservative procedures such as acetazolamide

Table 2
Distribution of study cases according to visual acuity.

diagnosis		Reduced visual acuity		Total
		Yes	no	
Leptomeningeal metastases	Numbers	2	3	5
	% Diagnosis	40%	60%	100%
	Visual acuity	9.5%	10.3%	10%
	%			
idiopathic intracranial hypertension	Total %	4%	6%	10%
	Numbers	4	6	10
	% Diagnosis	40%	60%	100%
	Visual acuity%	19.0%	20.7%	20%
cerebral venous sinus thrombosis	Total%	8%	12%	20%
	Numbers	3	9	12
	% Diagnosis	25%	75%	100%
	Visual acuity	14.3%	31%	24%
TUMOR	%			
	Total %	6%	18%	24%
	Numbers	4	6	10
	% Diagnosis	40%	60%	100%
HIGH BLOOD PRESSURE	Visual acuity	19%	20.7%	20%
	%			
	Total %	8%	12%	20%
	Numbers	3	0	3
MENINGITIS	% Diagnosis	100%	0%	100%
	Visual acuity	14.3%	0%	6%
	%			
	Total %	6.0%	0%	6%
AUTOIMMUNE MENINGITIS	Numbers	3	5	8
	% Diagnosis	37.5%	62.5%	100%
	Visual acuity%	14.3%	17.2%	16%
	Total %	6%	10%	16%
TOTAL	Numbers	2	0	2
	% Diagnosis	100%	0%	100%
	Visual acuity	9.5%	0%	4%
	%			
TOTAL	Total %	4.0%	0%	4%
	Numbers	21	29	50
	% Diagnosis	42%	58%	100%
	Visual acuity	100%	100%	100%
TOTAL	%			
	Total %	42.0%	58.0%	100%

and repeated CSF drainage, but the visual outcome was good.

As for the patients with leptomeningeal metastases, which are 5, the edema did not improve without surgical shunting, and the acuity was clearly reduced in 2 of them at the end. Patients with tumors are the second cause, as their number reached 10 out of 50, 6 of them underwent a tumor removal, however, the acuity decreased in 4 of them later.

Patients with autoimmune optic neuritis, two patients, one of whom was sarcoid, and the second was Vog-Koyanagi Harada who's visual acuity didn't improve even with shunting.

The patients with meningitis are 8 patients, 4 of them have tuberculous meningitis, as the acuity decreased in three of the tuberculous meningitis patients despite their installation of the shunt, knowing that it was late.

Figure (2) shows the visual acuity outcome after a month according to the diagnosis.

5. Discussion

Bilateral optic disc edema is an important emergency situation whose cause must be known and managed quickly according to the cause. Our study showed that the most common cause of bilateral optic disc edema is venous sinus thrombosis, which has a wide range of clinical symptoms from headache and blurred vision to convulsions, paralysis and other signs of localization. They were diagnosed with a cerebral MRI with MRV, and their visual acuity outcome was good, as all patients with CVT improved without the need for surgery, while the results of studies Crum, Olivia M et al. [15], Sachedva, Virender et al.

Table 3

The distribution of the study cases for each of (females, age group [18–35], edema improvement, decreased visual acuity, neurologic signs) according to the diagnosis.

	N (%)	diagnosis						
		Autoimmune inflammation	Hypertension	meningitis	Leptomeningeal Metastases	tumor	IIH	CVT
Variables		2 (4)	3 (6)	8 (16)	5 (10)	10 (20)	10 (20)	12 (24)
Gender (women)	37 (74)	1 (50)	1 (33.3)	6 (75)	4 (80)	7 (70)	10 (100)	8 (66.7)
(18–35) age	35 (70)	1 (50)	2 (66.7)	5 (62.5)	3 (60)	5 (50)	10 (100)	9 (75)
Improvement of edema during a month	37 (74)	1 (50)	3 (100)	5 (62.5)	0 (0)	7 (70)	9 (90)	12 (100)
Visual acuity	21 (42)	2 (100)	3 (100)	3 (37.5)	2 (40)	4 (40)	4 (40)	3 (25)
Other neurologic signs	14 (28)	1 (50)	0 (0)	0 (0)	3 (60)	4 (40)	0 (0)	6 (50)

Table 4

Distribution of the study cases for each of (females, age group [18–35], edema improvement, decreased visual acuity, signs of accompanying neurologic signs) according to diagnosis (sinus thrombosis) and other diagnoses) with the results of the Chi-Square test.

Chi-Square Test		Diagnosis No. (% [95%CI])			
P-value	Chi-Square value	Other diagnosis (N = 38)	CVT (N = 12)	total (N = 50)	
0.376	0.441	29 (76.3 [62–90.5])	8 (66.7 [36.4–97])	37 (74 [61.4–85.6])	Gender (women)
0.501	1.384	26 (68.4 [52.9–83.9])	9 (75 [46.3–100])	35 (70 [56.8–83.2])	age (18–35)
0.015*	5.548	25 (65.8 [50–81.6])	12 (100 [100–100])	37 (74 [61.4–86.6])	Edema improvement within month
0.151	1.873	18 (47.4 [30.7–64])	3 (25 [0–53.7])	21 (42 [27.8–56.2])	Visual acuity
0.060	3.791	8 (21.1 [7.5–34.6])	6 (50 [16.8–83.1])	14 (28 [15–41])	Other neurologic signs

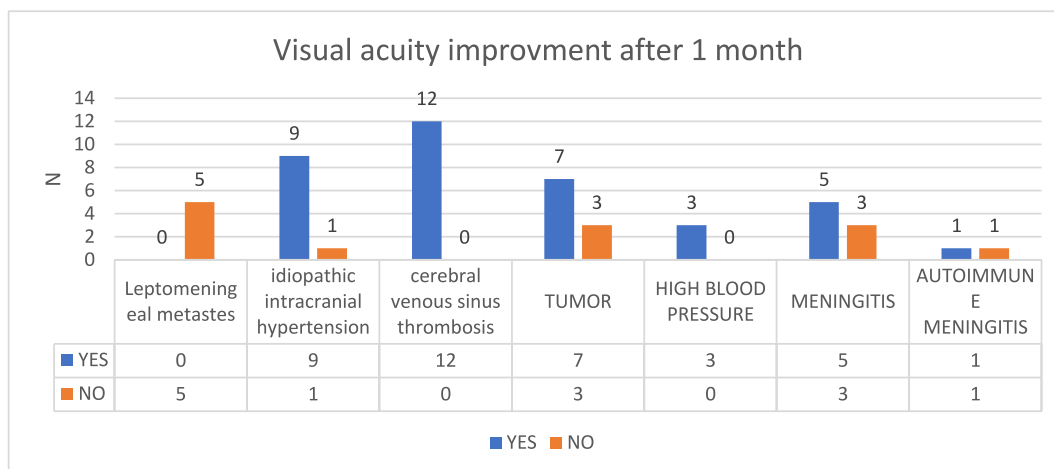


Fig. 2. The visual acuity outcome after a month according to the diagnosis.

[16] and Parajuli et al. [17] showed that the most common cause for them is IIH, which is a diagnosis with excluded, as an MRI and CSF puncture was performed, then the opening pressure was measured to diagnose IIH while in a study by Saoji et al. [18] and a study by Iijima et al. [19], intracranial space occupying lesions and brain tumor were the most common causes of disc edema, respectively.

Most of the patients were young females (74%) in our study due to the prevalence of IIH and CVT in females more than males and that similar to studies from Crum, Olivia M et al. [15] (91%) and Sachedva, Virender et al. [16] (73%) and Parajuli et al. [17] (71%).

Optic disc edema was accompanied by other neurologic signs in 14 of 50 patients in our study accounted for 28%, while in the study Crum, Olivia M et al. [15] and in sachadeva, Virender et al. [16], only 2 patients out of 67 patients and 5 patients of 37 patients accounted for 15% had other neurologic signs, respectively.

Headache was the most common symptom in most studies, present in 90% of the patients of our study and in 54% of the patients of the study (Sachedva, Virender et al. [16]), while it was in 91% of the study (Crum, Olivia M et al.) [15]. In the study Parajuli et al. [17], 38.4% of patients complained of blurred vision and only 28.6% of patients complained of headache.

While patients with CVST had symptoms isolated to raised intracranial pressure in Crum, Olivia M et al. [15] study such headache and papilledema, CVST can also cause venous infarctions, severe neurologic deficits, and seizures which was present in some patients in our study so early diagnosis of CVST is important to minimize the risk of these more severe central nervous system complications through the initiation of anticoagulation.

Finally, 20% of patients in our study had poor visual outcome despite of all treatment including surgery while 16% of patients in Sachadeva, Virender et al. [16] study had poor visual outcome.

6. Limitations

Follow-up of patients for a longer period to know the real prognosis, as the period of a month gave an initial idea and the real prognosis did not appear, so we need to follow up for longer periods to evaluate their real warning. Also, it is necessary to follow up why venous sinus thrombosis is more common than others as a cause of bilateral optic edema and is this attributed to these Certain mutations or the use of contraceptives in a large number of women of childbearing age.

7. Conclusion

In terms of results, the study differed from other studies, where CVT was the most common cause, possibly due to the frequent use of contraceptives as a contraceptive method for most women of childbearing age, and they constitute a good number of study patients, and their prognosis was the best and they improved on anticoagulant and acetazolamide without the need for a shunting. The study also showed the prevalence of tumors as an important cause of optic disc edema in our study, which is also in contrast to the rest of the studies, as they constituted only two patients in the other studies.

Appendix A. Supplementary data

Supplementary data to this article can be found online at <https://doi.org/10.1016/j.amsu.2022.104059>.

References

- [1] J.S. Glaser, Topical diagnosis: prechiasmal visual pathways, in: J.S. Glaser (Ed.), *Neuro-ophthalmology*, JB Lippincott, Philadelphia, 1990, p. 83.
- [2] A.A. Sadun, The afferent visual system: anatomy and Physiology, in: M. Yanoff, J. S. Duker (Eds.), *Ophthalmology*, second ed., Mosby, St. Louis, 2004, p. 186.
- [3] Don C. Bienfang, Overview and differential diagnosis of papilledema, UpToDate (May 10, 2019).
- [4] D.S. Minckler, M.O. Tso, L.E. Zimmerman, A light microscopic, autoradiographic study of axoplasmic transport in the optic nerve head during ocular hypotony, increased intraocular pressure, and papilledema, *Am. J. Ophthalmol.* 82 (5) (1976 Nov) 741–757.
- [5] M.O. Tso, S.S. Hayreh, Optic disc edema in raised intracranial pressure. IV. Axoplasmic transport in experimental papilledema, *Arch. Ophthalmol.* 95 (1977) 1458.
- [6] A.G. Lee, H.A. Beaver, Acute bilateral optic disk edema with a macular star figure in a 12-year-old girl, *Surv. Ophthalmol.* 47 (2002) 42.
- [7] C.G. Spencer, G.Y. Lip, D.G. Beevers, Recurrent malignant hypertension: a report of two cases and review of the literature, *J. Intern. Med.* 246 (1999) 513.
- [8] C. Kennedy, F.D. Carroll, Optic neuritis in children, *Trans. Am. Acad. Ophthalmol. Otolaryngol.* 64 (1960) 700.
- [9] L.J. Balcer, J.M. Winterkorn, S.L. Galetta, Neuro-ophthalmic manifestations of Lyme disease, *J. Neuro Ophthalmol.* 17 (1997) 108.
- [10] R.J. Cinefro, M. Frenkel, Systemic lupus erythematosus presenting as optic neuritis, *Ann. Ophthalmol.* 10 (1978) 559.
- [11] A. Gass, I.F. Moseley, The contribution of magnetic resonance imaging in the differential diagnosis of optic nerve damage, *J. Neurol. Sci.* 172 (Suppl 1) (2000) S17.
- [12] S. Pawate, H. Moses, S. Sriram, Presentations and outcomes of neurosarcoidosis: a study of 54 cases, *QJM* 102 (2009) 449.
- [13] F.G. Joseph, N.J. Scolding, Neurosarcoidosis: a study of 30 new cases, *J. Neurol. Neurosurg. Psychiatry* 80 (2009) 297.
- [14] G. Mathew, R. Agha, S. Group, Stroc 2021 : strengthening the reporting of cohort, cross-sectional and case-control studies in surgery, *Int. J. Surg. Open* 72 (November) (2021).
- [15] Olivia M. Crum, et al., Etiology of papilledema in patients in the eye clinic setting, *JAMA Netw. Open* 3 (1 jun. 2020), 6 e206625.
- [16] Virender Sachedva, et al., Optic nerve head edema among patients presenting to the emergency department, *Neurology* 90 (5) (2018) e373–e379.
- [17] A. Parajuli, A.K. Sharma, S. Sitaula, A clinical study of optic disc edema in a tertiary eye center of Nepal, *Nepal. J. Ophthalmol.* 11 (22) (2019) 112–129.
- [18] C.P. Saoji, S.P. Wadgaonkar, P.A. Patil, et al., The prospective study of clinicoetiological analysis on patients of papilloedema, *Indian J. Clin. Exp. Ophthalmol* 2 (2016) 253–256.
- [19] K. Iijima, K. Shimizu, Y. Ichibe, A Study of the Causes of Bilateral Optic Disc Swelling in Japanese Patients, *Clinical ophthalmology*, Auckland, NZ), 2014.