



CASE REPORT

HPV32-related Heck's disease in a chronic graft-versus-host disease patient with long-term successful KTP laser treatment: A rare case report

Joe Truong Nguyen¹  | Clint T. Allen² | Joshua T. Dodge¹ | Koenraad Van Doorslaer^{3,4} | Alison A. McBride³ | Steven Z. Pavletic⁵ | Jacqueline W. Mays¹ 

¹Oral Immunobiology Unit, National Institute of Dental and Craniofacial Research, National Institutes of Health, Bethesda, MD, USA

²Section on Translational Tumor Immunology, National Institute on Deafness and Other Communication Disorders, National Institutes of Health, Bethesda, MD, USA

³DNA Tumor Virus Section, Laboratory of Viral Diseases, National Institute of Allergy and Infectious Diseases, Bethesda, MD, USA

⁴Virology, School of Animal and Comparative Biomedical Sciences, The University of Arizona, Tucson, AZ, USA

⁵Graft-versus-Host Disease and Late Effects Section, Center for Cancer Research, National Cancer Institute, National Institutes of Health, Bethesda, MD, USA

Correspondence

Jacqueline W. Mays, Oral Immunobiology Unit, National Institute of Dental and Craniofacial Research, National Institutes of Health, Bldg 30, Rm 303; MSC 4340, 30 Convent Drive, 20892 Bethesda, MD, USA. Email: Jacqueline.Mays@nih.gov

Funding information

This work was supported by the Intramural Research Programs of the National Institute of Dental and Craniofacial Research (1ZIADE000747-05), National Institute of Allergy and Infectious Diseases (1ZIAAI001145-10), National Institute on Deafness and Other Communication Disorders (1ZIADC000087-06), and the National Cancer Institute (1ZIABC011743-05, 1ZIABC012017-01) at the National Institutes of Health. We thank the patient and family for kind participation in this study.

Abstract

We recently identified and treated a rare case of oral focal epithelial hyperplasia (FEH) in an adult patient with chronic graft-vs-host disease. This is the first report linking KTP laser therapy to successful long-term treatment HPV32 FEH.

KEYWORDS

cGVHD, graft-versus-host disease, GVHD, human, laser, papillomavirus, transplant, virus

Heck's disease is induced by HPV13 or HPV32 oral infection that results in focal epithelial hyperplasia (FEH). Here, we report a rare case of HPV32 infection that resulted in widespread FEH in the oral cavity of a chronic graft-vs-host

disease patient. Novel KTP laser therapy was an effective long-term treatment.

More than 400 HPV types have been identified,¹ several of which are implicated in cancer.^{2,3} Focal epithelial hyperplasia

This is an open access article under the terms of the Creative Commons Attribution-NonCommercial License, which permits use, distribution and reproduction in any medium, provided the original work is properly cited and is not used for commercial purposes.

© Published 2021. This article is a U.S. Government work and is in the public domain in the USA. *Clinical Case Reports* published by John Wiley & Sons Ltd.

(FEH), or Heck's disease, is a rare benign epithelial proliferation in the oral cavity induced by HPV13 in children or HPV32 in adults.^{4,6} Incidence of Heck's disease has been correlated with the human leukocyte antigen (HLA) DR4 (DRB1*0404).⁷ The same HLA-DR4 was reported in three out of four cases of an Anatolian Turkish family with FEH associated with HPV13, but not HPV32.⁸ Though HPV13 and HPV32 are disproportionately detected in the oral cavity, the underlying etiologic factors have not been identified.^{5,6} Most reported cases are in children or immunocompromised adults, and there have been no reports of Heck's disease in transplant patients with chronic graft-vs-host disease (cGVHD).⁹ This report describes successful long-term interdisciplinary therapy of an unusual case of HPV32 positive proliferative FEH in a cGVHD patient.

1 | CASE REPORT

A 68-year-old post-transplant patient presented to our dental clinic as part of a comprehensive evaluation of his cGVHD with the chief complaint of proliferating white patches in his mouth. During the initial visit, we identified suspicious oral lesions and needed to rule out malignant potential. The patient was a 68-year-old Caucasian man with cGVHD, previously treated for acute myelogenous leukemia (AML, translocation 9:11 and trisomy 8) with an allogeneic matched related donor hematopoietic stem cell transplant. Transplant was preceded by 4 days of busulfan/

fludarabine conditioning and followed by two cyclophosphamide doses. Following treatment of acute skin GVHD, systemic immunosuppression was stopped, and at 9 months post-transplant, the patient developed cGVHD of the lung, oral cavity, skin, and eye. Systemic immunosuppression resumed, and at 18 months post-transplant, a single flat white plaque was noted on the maxillary labial mucosa. It was excised and pathologist evaluated. H&E staining revealed acanthosis with expansion and fusion of the rete ridges along with scattered nuclear fragmentation consistent with FEH. Patient and donor HLA type were HLA DRB1*1501, ruling out genetic links between HLA and HPV-induced FEH in this case. At 5 years post-transplant, the patient presented to our hospital dental clinic during a comprehensive multi-specialty assessment of cGVHD that included consent and research sampling on study NCT00092235 (clinicaltrials.gov) which conforms to the principles of the Declaration of Helsinki. Evaluation of the oral cavity revealed multiple, sessile whitish papules involving the maxillary and mandibular labial and bilateral buccal mucosa (Figure 1). Biopsy of the buccal mucosal from an area of mild lichenoid patterning was read as normal squamous mucosa, supporting the absence of oral mucosal cGVHD. Given the elevated risk of oral squamous cell carcinoma in cGVHD patients, the sentinel maxillary labial mucosal lesion was also biopsied at 5 years post-transplant and was read as hyperplastic squamous mucosa with parakeratosis and few dyskeratotic cells and perinuclear clearing suspicious for HPV viral cytopathic changes (Figure 2A). Rete

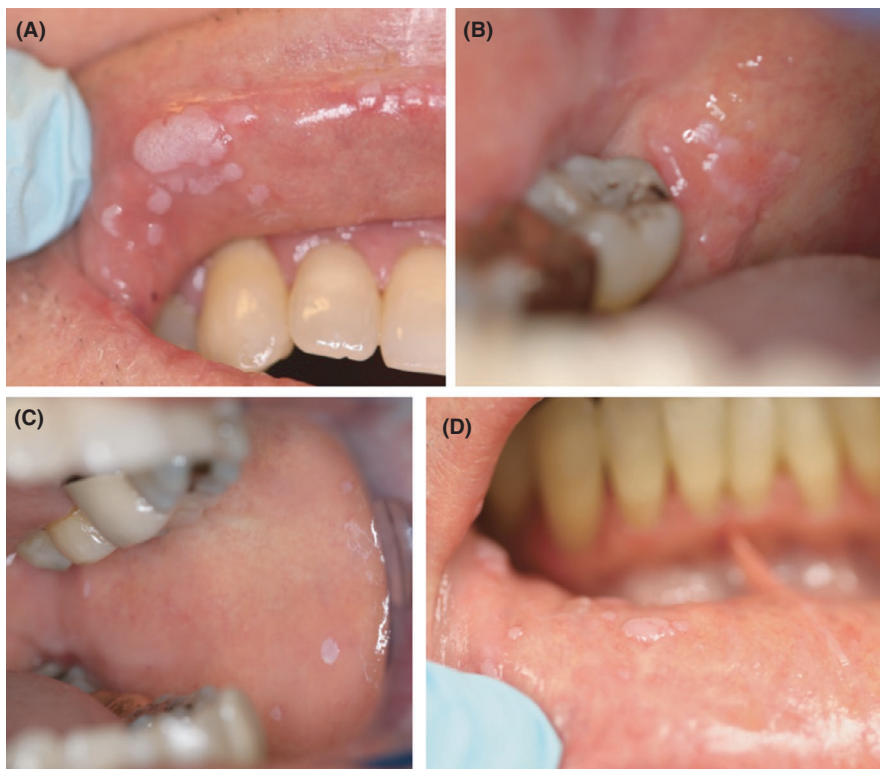

FIGURE 1 Oral photographs of widespread focal epithelial hyperkeratosis or Heck's disease in a patient with cGVHD. (A), upper lip; (B), lower right labial mandibular ridge; (C), left buccal mucosa; (D) lower lip. *Original photographs taken at NIH*

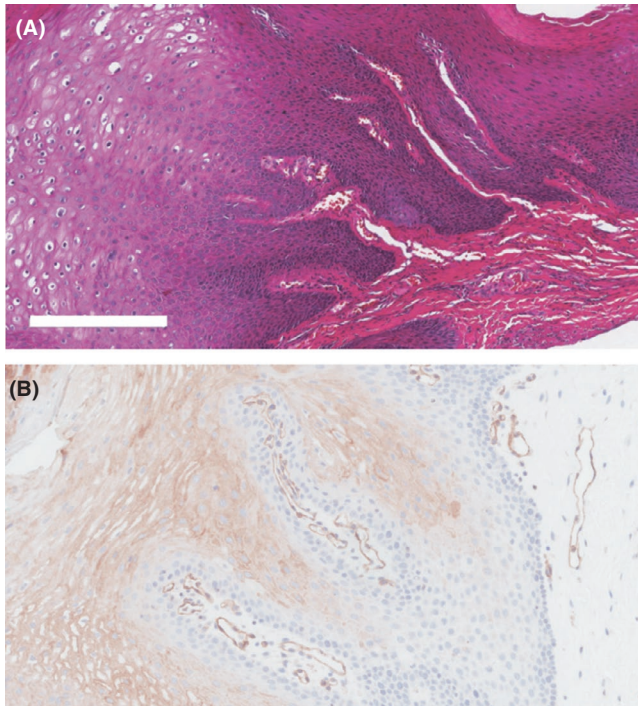


FIGURE 2 Tissue analysis of a biopsy of FEH. (A), Hematoxylin and eosin stain; (B), CD31 positive IHC

ridges were fused with scattered nuclear fragmentation consistent with FEH. Immunohistochemistry staining was positive for endothelial marker CD31 (Figure 2B). Due to the relatively rapid proliferation of these lesions rather

than the occurrence and regression typical of FEH, the differential diagnosis for these lesions included infection or coinfection with more aggressive strains of HPV such as HPV16 that could represent a higher risk of malignant transformation for an already at-risk patient.

In situ hybridization (ISH) testing for high/low-risk HPV was done at the Mayo Clinic and ruled out HPV-16 and HPV-18 while demonstrating inconclusive staining for HPV-6/11 with high background (Figure 3). To determine the true HPV strain, we proceeded to sequence the virus using genomic DNA isolated from tissue using the Qiagen Blood and Tissue kit. DNA was amplified using Rolling Circle Amplification (RCA).¹⁰ The RCA product was digested with BamHI and ligated into the matching pML2d site. The cloned viral DNA was sequenced by primer walking (Eurofins Genomics) and determined to be HPV32, represented as a linear diagram in (Figure 4A). The HPV32 sequence was submitted to GenBank (KT236450.1) and was 99% identical to a previously banked sequence (GenBank X74475.1), along with greater than 99% nucleotide identity to all other banked partial sequences (Figure 4B).

With no standardized treatment protocol specific for HPV32-mediated FEH, initial treatment followed a standard protocol for oral HPV lesions: imiquimod 5% cream applied three times weekly. After 4 weeks of treatment, clinical manifestations appeared unchanged (Figure 5). Due to the presence of blood vessels (Figure 5B) within the structural fronds of the papillomatous lesions, we

FIGURE 3 In situ hybridization results against HPV strains. (A), HPV6 or HPV11 positive staining; (B), HPV16 negative staining

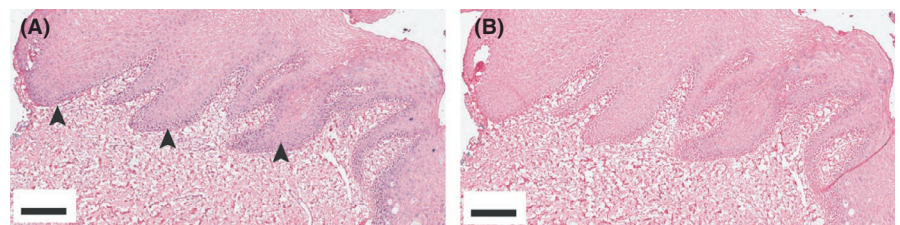
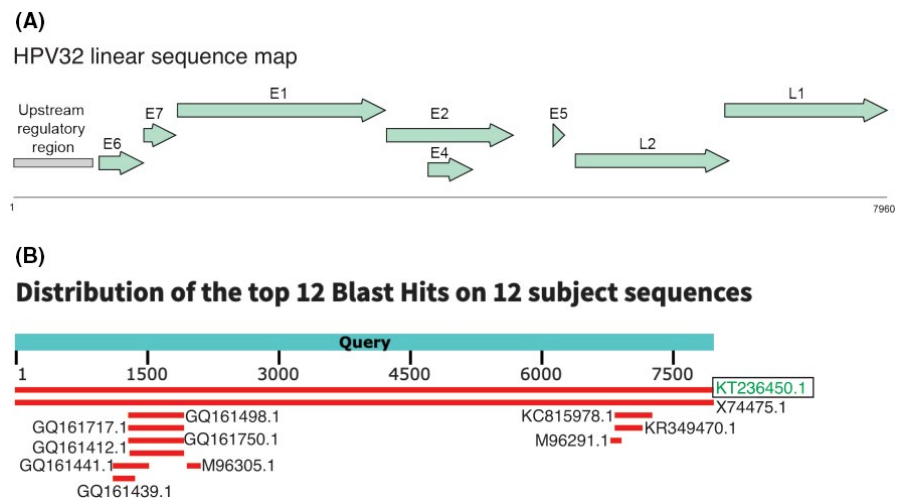


FIGURE 4 HPV32 sequencing results. (A), Linearized depiction of HPV32; (B), Blast results of GenBank HPV32 sequences



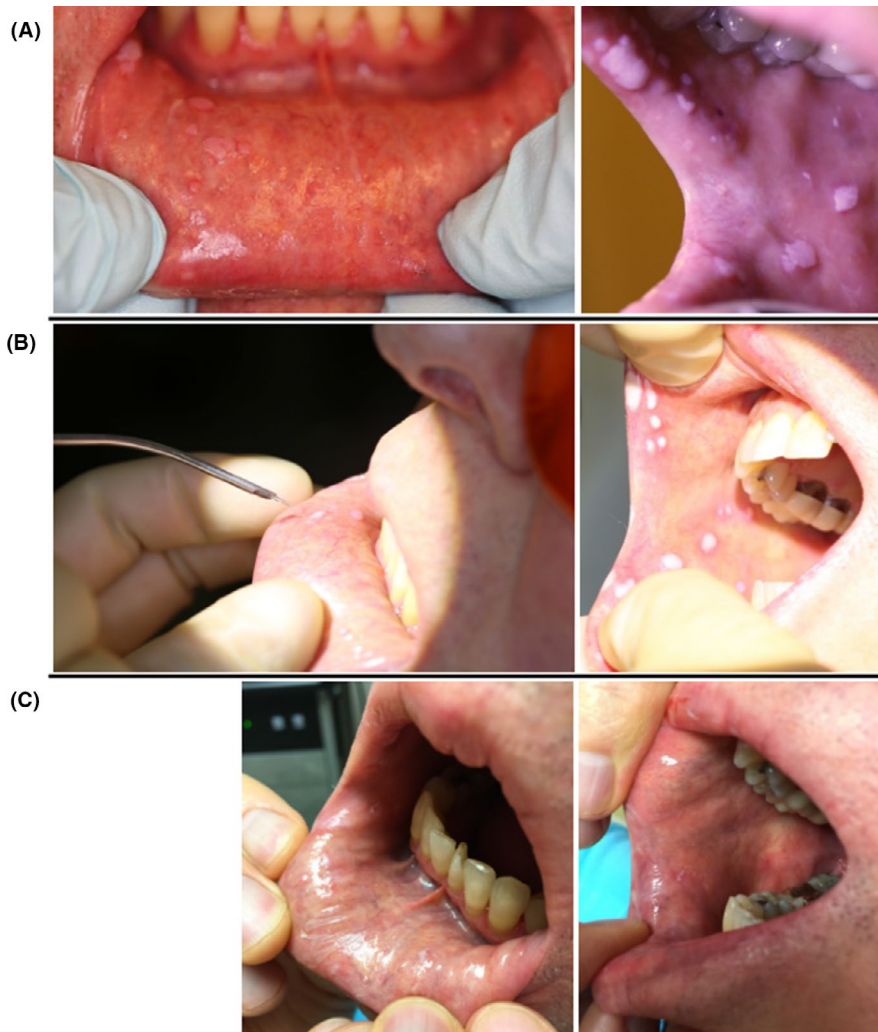


FIGURE 5 Treatment of HPV32 FEH in cGVHD patient. (A), Baseline oral photographs; (B), Active KTP laser therapy; (C), 1-mo post-KTP laser therapy

hypothesized that a 532 nm potassium titanyl phosphate (KTP) laser could be an effective therapy for the lesions.¹¹ Oxyhemoglobin, which absorbs visible light at 542 and 577 nm, is the primary chromophore in blood vessels. Once absorbed by oxyhemoglobin, light energy converts into thermal energy causing photocoagulation, mechanical injury, and finally thrombosis and occlusion of the blood vessel. Thus, delivery of laser energy at or near absorption peaks for oxyhemoglobin may be an effective means to selectively ablate highly vascular tissues. A similar hemostatic laser was reported to be effective in a pediatric case of FEH.¹²

For our patient, one course of 532 nm potassium titanyl phosphate (KTP) laser therapy in the clinic under topical anesthesia was completed (Figure 5B). No adverse effects were noted. FEH lesions had predominately cleared by 1-month post-treatment (Figure 5C) and remained clear through 5 years post-treatment (most recent follow-up). Thus, treatment with a 532 nm KTP laser in this case was safe and effective at clearing HPV32 oral papillomatous lesions in a patient with cGVHD.

2 | DISCUSSION

Focal epithelial hyperplasia is an uncommon disease that follows mucosal HPV13 or HPV32 infection with sessile papule development ranging from minor to severe that affects the oral cavity and anal/genital mucosae. It is more commonly detected in young Native or Indigenous populations of the Americas.⁹ Children with FEH are more likely to be carrying HPV13, but adult FEH cases are more frequently linked to HPV32. Often, FEH is left untreated as, particularly in children, it is often a self-limiting disease.¹³ In cases with cosmetic or other concerns, surgical excision may be done. To date, FEH has not been described in the literature in adult patients with cGVHD, suggesting a previously unreported population susceptible to this uncommon disease. This case includes a patient who was post-transplant, on long-term steroid therapy for severe lung cGVHD, with an altered immune system that likely predisposed the patient to persistent HPV infection.

A clear first line therapeutic has not been developed for patients with FEH. Traditional treatment options include surgery/cryosurgery, Toll-like receptor agonists, and

interferon- β .¹⁴⁻¹⁶ Imiquimod, a topical agent, was shown to successfully treat FEH in three cases but was ineffective here.¹⁶ Topical interferon- β cleared infection in a 4-year-old Turkish boy.¹⁴ While surgical excision has been shown to be effective, it requires removing more healthy tissue than necessary particularly for widespread lesions. Quantum molecular resonance scalpel surgery and diode laser (808 nm) removal have had success with the potential to selectively ablate papillomatous tissue, resulting in reduced scarring.^{15,17}

In conclusion, we report the first KTP laser treatment of a chronic graft-vs-host disease patient with HPV32 positive FEH.

CONFLICT OF INTEREST

The authors report no conflicts of interests.

AUTHOR CONTRIBUTION

JTN, JWM, and JTD: wrote manuscript and prepared figures. KVD and AAM: sequenced HPV32, prepared figures, and edited manuscript. CTA: designed and completed KTP laser treatment. JWM, JTN, and SZP: completed clinical care and workup of case. All authors edited the manuscript and agreed to publication.

ETHICAL APPROVAL

All procedures were in accordance with the ethical standards of the National Institutes of Health and the Helsinki Declaration. Informed consent was obtained from each individual participant involved in the study.

DATA AVAILABILITY STATEMENT

The sequencing data that support the findings of this study are openly available in GenBank reference KT236450.1.

ORCID

Joe Truong Nguyen  <https://orcid.org/0000-0002-6647-0561>

Jacqueline W. Mays  <https://orcid.org/0000-0002-4472-9974>

REFERENCES

1. Van Doorslaer K, Li Z, Xirasagar S, et al. The papillomavirus episteme: a major update to the papillomavirus sequence database. *Nucleic Acids Res.* 2017;45(D1):D499-D506.
2. Brentjens MH, Yeung-Yue KA, Lee PC, Tyring SK. Human papillomavirus: a review. *Dermatol Clin.* 2002;20:315-331.
3. Viens LJ, Henley SJ, Watson M, et al. Human papillomavirus-associated cancers — United States, 2008–2012. *MMWR Morb Mortal Wkly Rep.* 2016;65(26):661-666. <http://dx.doi.org/10.15585/mmwr.mm6526a1>
4. Henke RP, Guerin-Reverchon I, Milde-Langosch K, Koppang HS, Loning T. In situ detection of human papillomavirus types 13 and 32 in focal epithelial hyperplasia of the oral mucosa. *J Oral Pathol Med.* 1989;18:419-421. <http://dx.doi.org/10.1111/j.1600-0714.1989.tb01575.x>
5. Ozden B, Gunduz K, Gunhan O, Ozden FO. A case report of focal epithelial hyperplasia (Heck's disease) with PCR detection of human papillomavirus. *J Maxillofac Oral Surg.* 2011;10(4):357-360. <http://dx.doi.org/10.1007/s12663-011-0184-2>
6. Pereira CM, Melo LG, Correa MM, Souza CA, Corrêa MEP. Oral HPV infection in a bone marrow transplantation patient: a case report with atypical clinical presentation and unexpected outcome. *Braz J Infect Dis.* 2010;14(1):89-91. <http://dx.doi.org/10.1590/s1413-86702010000100018>
7. Garcia-Corona C, Vega-Memije E, Mosqueda-Taylor A, et al. Association of HLA-DR4 (DRB1*0404) with human papillomavirus infection in patients with focal epithelial hyperplasia. *Arch Dermatol.* 2004;140(10):1227-1231.
8. Akoglu G, Metin A, Ceylan GG, Emre S, Akpolat D, Süngü N. Focal epithelial hyperplasia associated with human papillomavirus 13 and common human leukocyte antigen alleles in a Turkish family. *Int J Dermatol.* 2015;54(2):174-178. <http://dx.doi.org/10.1111/ijd.12538>
9. Archard HO, Heck JW, Stanley HR. Focal epithelial hyperplasia: an unusual oral mucosal lesion found in Indian children. *Oral Surg Oral Med Oral Pathol.* 1965;20:201-212. [http://dx.doi.org/10.1016/0030-4220\(65\)90192-1](http://dx.doi.org/10.1016/0030-4220(65)90192-1)
10. Rector A, Tachezy R, Van Ranst M. A sequence-independent strategy for detection and cloning of circular DNA virus genomes by using multiply primed rolling-circle amplification. *J Virol.* 2004;78(10):4993-4998. <http://dx.doi.org/10.1128/jvi.78.10.4993-4998.2004>
11. Imhof BA, Dunon D. Leukocyte migration and adhesion. *Adv Immunol.* 1995;58:345-416. <https://www.sciencedirect.com/science/article/pii/S0065277608606239?via%3Dihub>
12. Nallanchakrava S, Sreebala N, Lnu B, Sindgi F. Laser excision of focal epithelial hyperplasia (Heck's Disease): a rare case report. *Int J Clin Pediatr Dent.* 2018;11(6):526-528.
13. Woods M, Reichart PA. Surgical management of nonmalignant lesions of the mouth. In: Brennan P. A., Schliephake H., Ghali G. E., Cascarini L. eds. *Maxillofacial surgery*, 3rd edn. Elsevier;2017:1319-1334. <https://www.elsevier.com/books/maxillofacial-surgery/brennan/978-0-7020-6056-4>
14. Steinhoff M, Metze D, Stockfleth E, Luger TA. Successful topical treatment of focal epithelial hyperplasia (Heck's disease) with interferon-beta. *Br J Dermatol.* 2001;144(5):1067-1069.
15. Bombeccari GP, Pallotti F, Guzzi G, Spadari F. Diode laser therapy for Heck's disease associated with HPV13 infection. *J Eur Acad Dermatol Venereol.* 2009;23(2):197-198.
16. Yasar S, Mansur AT, Serdar ZA, Goktay F, Aslan C. Treatment of focal epithelial hyperplasia with topical imiquimod: report of three cases. *Pediatr Dermatol.* 2009;26(4):465-468.
17. Sarraj A, Mergoni G, Manfredi M, Meleti M, Vescovi P. A case of Heck's disease treated with quantum molecular resonance scalpel. *Ann Stomatol (Roma).* 2013;4(Suppl 2):38-39.

How to cite this article: Nguyen JT, Allen CT, Dodge JT, et al. HPV32-related Heck's disease in a chronic graft-versus-host disease patient with long-term successful KTP laser treatment: A rare case report. *Clin Case Rep.* 2021;9:e04253. <https://doi.org/10.1002/ccr3.4253>