

**Case Report**

## A salty cause of cough in a 24-year-old man

Neda Naderi<sup>1</sup>, Soheil Peiman<sup>\*,1,2</sup>, Azam Alamdari<sup>1</sup>, Taraneh Dormohammadi Toosi<sup>1</sup> and Foad Taghdiri<sup>1</sup>

<sup>1</sup>Department of General Internal Medicine, ImamKhomeini Hospital Complex, Tehran University of Medical Sciences, Tehran, Iran and <sup>2</sup>Advanced Thoracic Research Center, Tehran University of Medical Sciences, Tehran, Iran

\*Correspondence address. Advanced Thoracic Research Center, Tehran University of Medical Sciences, Tehran, Iran. Fax: +98-21-66939922; E-mail: s-peiman@tums.ac.ir

Received 5 March 2014; revised 2 May 2014; accepted 3 June 2014

With improvement in the diagnosis and treatment of cystic fibrosis cases in recent years, the survival of these cases has been increased. On the other hand, an increasing number of cases are presented during adulthood. Here we report a 24-year-old man with a history of productive cough, bilateral paranasal sinusitis and polyps, and recurrent abdominal pain. Thoracic computed tomography revealed a bilateral scattered tree in bud pattern and some bronchiectatic changes. Semen analysis showed azoospermia. A sweat chloride test was  $>60$  mEq/l in two occasions.

### INTRODUCTION

Cystic fibrosis (CF) is one of the most common inherited diseases worldwide, especially among Caucasians. This autosomal recessive disease is characterized by various mutations in the gene encoding the CF transmembrane conductance regulator (CFTR) that causes abnormalities in epithelial ion transport [1]. These changes lead to pathological changes in organs that express CFTR, including sinuses, lungs, pancreas, liver and reproductive tract. The most prominent clinical problems are seen in airway mucosa [2].

Although most cases are present during childhood, there is an increasing number of CF subjects who are diagnosed during adulthood [3, 4]. In these patients the manifestations of disease are somewhat different from those presented during childhood [5, 6]. Adult patients typically present with mild pulmonary symptoms, rhinosinusitis, recurrent pancreatitis or azoospermia.

### CASE REPORT

On February 2013, a 24-year-old man was referred to the Outpatient clinic of Imam Khomeini Hospital of Tehran University of Medical Sciences, with a history of productive cough and rhinorrhea from 4 years ago. He also reported blood-streaked sputum during the last 5 days. The volume of the sputum was  $<50$  ml per day. The patient also had

low-grade fever, fatigue and sweating. He had undergone functional endoscopic sinus surgery for evaluation of the productive cough and rhinorrhea 2 years ago and bilateral paranasal sinusitis and polyps had been reported. He also had a history of hospital admission about 7 years ago for the evaluation of recurrent abdominal pain; familial Mediterranean fever (FMF) was considered as probable diagnosis and Colchicine was prescribed. He refused to use colchicine and the abdominal pain subsided spontaneously. A review of his previous medical documents revealed cyanosis at the time of birth, sepsis 20 days after that and seizure attacks when he was 2 weeks old. During infancy he underwent a gastroesophageal reflux repair surgery. His growth and development, physical activities at home and at school, learning in school and other activities did not show any significant difference from his other peers. His parents were not relatives. All five of his siblings were healthy. Three of them were married with no history of infertility, and their children were also well.

Physical examination revealed a pulse rate of 88/min with regular rhythm; blood pressure 110/70 mmHg; respiratory rate 18/min; oral temperature 37.8°C at the time of admission; weight 67 kg and height 171 cm. Coarse crackles were heard on lungs auscultation and the examination of heart and abdomen were normal. Examination for cyanosis, clubbing and edema were negative.

Complete blood count revealed Hb of 14.1 g/dl, WBC 6400/ $\mu$ l and Plt of 322000/ $\mu$ l. Blood sugar, urea, creatinine,

electrolytes and liver function tests were all within normal ranges. C-reactive protein of 152 mg/l (normal: 0–10), ESR: 50 mm/h. Sputum culture and sensitivity was negative, including for Ziehl Neelsen. RF, ANA, ANCA, anti-dsDNA, HBsAg, HCV Ab and HIV Ab were all negative. Serum immunoelectrophoresis was normal. Semen analysis showed azoospermia. Urine analysis was normal. ECG and ultrasonography of the abdomen were normal. Spirometry revealed a mild obstructive pattern. On chest X-ray, bilateral peribronchial thickening and suspicious bronchiectatic changes were evident. A high-resolution computed tomography (HRCT) scan of the thorax revealed a bilateral scattered tree in bud pattern, peribronchial thickening and some bronchiectatic changes in the apex and middle zones (Fig. 1).

A para nasal sinus CT scan showed diffuse mucosal membrane thickening. A PPD test was 12 mm. A sweat chloride test was 133 mmol/l and repeated tests confirmed the high values (71 and 137 mmol/l). Unfortunately, the patient refused to do genetic study. He received azithromycin 500 mg three times weekly and inhaled corticosteroid daily. After 2

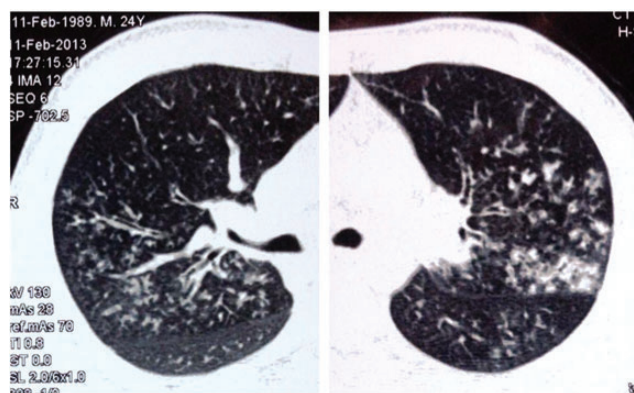
months of follow-up, his sputum amount and general condition markedly improved. Till now he is well and still on regular outpatient visits.

## DISCUSSION

With improvement in the diagnosis and treatment of CF cases over the past few years, the median predicted survival has increased from the mid-teens in the 1970s to fourth decade or even longer today [3].

There is an increasing number of cases showing the diagnosis of CF after age 18. In a review of 9766 cases with CF, 8.3% of them were diagnosed after 18 years of age [5]. Similar to our patient they mostly presented with respiratory symptoms and they were less likely to be pancreatic insufficient. It is not surprising that adult cases generally have milder symptoms than those with presentation during pediatric period [6]. While our patient had increased value of the sweat chloride test, it is not uncommon for adulthood presenting CF to have normal or borderline values of this test. Absence/heterozygosity for the CFTR mutation may be responsible for delayed onset and mild nature of symptoms [4].

CF patients can be classified into two different groups: classic and non-classic (Table 1) [7, 8]. Those with classic or typical CF have one or more characteristic features (chronic sinopulmonary disease, characteristic gastrointestinal disorders and/or obstructive azoospermia) and the associated sweat chloride level of >60 mmol/l. On the other hand, non-classic or atypical CF include patients with a CF-related phenotype in at least one organ system, despite a borderline (30–60 mmol/l) or even normal (<30 mmol/l) sweat chloride concentration [9]. Many cases with adult presentation are categorized into the non-classical group with associated mild symptoms, but even with late presentation of disease, this patient could be classified as the classic group. Past episodes of abdominal pain that did not recur could be due to attacks of pancreatitis that was



**Figure 1:** Thoracic HRCT of the patient showing a scattered tree in bud pattern and associated bronchiectasis.

**Table 1:** Comparison between classical and non-classical cystic fibrosis in the term of clinical and paraclinical problems

Classic vs. non-classic CF		
Classic CF		Non-classic CF
Majority of cases (98%)	Number of cases	Minority of cases (2%)
Meconium ileus and distal ileal obstruction	Perinatal and childhood complications	Less prominent perinatal problems
Chronic rhinosinusitis	Sinuses	Chronic rhinosinusitis
Significant pulmonary disease	Lung	Mild late onset pulmonary disease
Exocrine pancreatic insufficiency	Pancreas	Recurrent acute pancreatitis
Congenital bilateral absence of the vas deferens (obstructive azoospermia)	Vas deferens	Congenital bilateral absence of the vas deferens (obstructive azoospermia)
Partial defect in expression and function (mild mutation)	CFTR	Different classes of mutations
Usually >60 mmol/l	Sweat chloride test	Borderline (30–60 mmol/l) or even normal (<30 mmol/l) values

misdiagnosed as FMF. Considering this problem as the first presentation of disease in this patient, it is amazing to note the patient remained symptom free for a long period of time. Thus, even with symptoms-free period after initial presentations in adults, it is still wise to consider the CF.

In conclusion, it is prudent to consider CF in adults with pulmonary (e.g. chronic cough or sputum, diffuse bronchiectasis, various infiltration such as the tree in bud pattern and recurrent pneumonia), sinus (chronic rhinosinusitis with nasal polyps) or gastrointestinal (recurrent pancreatitis or pancreatic insufficiency) problems. If the test values are  $>60$  mmol/l on two occasions, a definite diagnosis could be made even without any further genetic studies [10].

This report highlights an unusual presentation of a common genetic disease which should never be missed, even during adulthood presentation.

### CONFLICT OF INTEREST

None declared.

### REFERENCES

1. Lobo J, Rojas-Balcazar JM, Noone PG. Recent advances in cystic fibrosis. *Clin Chest Med* 2012;**33**:307–28.
2. Ratjen F, Doring G. Cystic fibrosis. *Lancet* 2003;**361**:681–9.
3. Farrell PM, Lai HJ, Li Z, Kosorok MR, Laxova A, Green CG, *et al*. Evidence on improved outcomes with early diagnosis of cystic fibrosis through neonatal screening: enough is enough! *J Pediatr* 2005;**147**:S30–S6.
4. Widerman E, Millner L, Sexauer W, Fiel S. Health status and sociodemographic characteristics of adults receiving a cystic fibrosis diagnosis after age 18 years. *Chest* 2000;**118**:427–33.
5. Keating CL, Liu X, DiMango EA. Classic respiratory disease but atypical diagnostic testing distinguishes adult presentation of cystic fibrosis. *Chest* 2010;**137**:1157–63.
6. Blau H, Livne M. Cystic fibrosis in adults: a changing scene. *Isr Med Assoc J* 2003;**5**:491–5.
7. Knowles MR, Durie PR. What is cystic fibrosis? *New Engl J Med* 2002;**347**:439.
8. Boyle MP. Nonclassic cystic fibrosis and CFTR-related diseases. *Curr Opin Pulm Med* 2003;**9**:498–503.
9. De Boeck K, Wilschanski M, Castellani C, Taylor C, Cuppens H, Dodge J, *et al*. Cystic fibrosis: terminology and diagnostic algorithms. *Thorax* 2006;**61**:627–35.
10. Farrell PM, Rosenstein BJ, White TB, Accurso FJ, Castellani C, Cutting GR, *et al*. Guidelines for diagnosis of cystic fibrosis in newborns through older adults: Cystic Fibrosis Foundation consensus report. *J Pediatr* 2008;**153**:S4–14.