



Case Report

Mirror meningioma at foramen magnum: Enigma in management of a very rare case

Anil Kumar¹, Subhas Konar², Nighat Hussain³, Jitender Chaturvedi⁴

¹Department of Neurosurgery, ³Department of Pathology, All India Institute of Medical Sciences, Raipur, Chhattisgarh, ²Department of Neurosurgery, National Institute of Mental Health and Neuro Sciences, Bengaluru, Karnataka, ⁴Department of Neurosurgery, All India Institute of Medical Sciences, Rishikesh, Uttarakhand, India.

E-mail: *Anil Kumar - dr.anilsharma02@gmail.com; Subhas Konar - drsubhaskonar@gmail.com; Nighat Hussain - hussain.nighat@gmail.com; Jitender Chaturvedi - drjittu28@gmail.com



***Corresponding author:**

Dr. Anil Kumar, MCh,
Neurosurgery Assistant
Professor, Department of
Neurosurgery, All India
Institute of Medical Sciences,
Raipur, Chhattisgarh, India.

dr.anilsharma02@gmail.com

Received : 23 October 19
Accepted : 09 November 19
Published : 29 November 19

DOI
10.25259/SNI_437_2019

Quick Response Code:



ABSTRACT

Background: We report a very rare case of bilateral foramen magnum mirror meningioma and discuss difficulties in managing the surgical challenge. To the best of our knowledge, mirror foramen magnum meningioma (FMM) has been reported only once in literature. FMMs are rare and also a great challenge for neurosurgeons due to the complex anatomy of this area. The purpose of this article is to illustrate the rare occurrence of bilateral meningioma in the foramen magnum and the difficulties in managing the surgical challenge.

Case Description: A case of a 45-year-old female presented with neck pain, paresthesia in all four limbs, and difficulty in walking for 1 year duration. Magnetic resonance imaging revealed well-defined lobulated dural based mass lesion at foramen magnum on both sides. The left vertebral artery (VA) was encased within the lesion while the right VA was seen abutting it. Tumor was resected gross totally on the right side. However, during the resection of the medial part of the left side tumor, it was found to be adhered to the VA. Since the mass was adherent to the left VA, subtotal resection was done.

Conclusion: There is no single best surgical approach for FMMs and the optimal approach should be defined according to the localization and the extent of the tumor to minimize the extent of resultant morbidity. Although complete excision of the tumor is the aim of surgery, it is safer to leave portions of tumor that is adherent to critical structures which can be managed by Gamma Knife radiosurgery.

Keywords: Foramen magnum, Mirror meningioma, Multiple intracranial meningiomas, Skull base surgery

INTRODUCTION

Meningioma in and around foramen magnum is challenging for neurosurgeons in view of near proximity of brain stem, cranial nerve rootlets, and vertebral artery (VA). Several surgical approaches have been proposed for the removal of foramen magnum meningiomas (FMMs) including the standard midline suboccipital craniotomy and high cervical laminectomy. Although complete excision of the tumor is goal of surgery, it is safer to leave portions of tumor that is adherent to critical structures.^[3] Multiple meningiomas are a rare pathology when not associated with neurofibromatosis (NF). Multiple meningiomas are found in about 1–2% of patients with an already known meningioma and this statistic rises in individuals with NF type 2.^[5] To the best of our knowledge, mirror FMMs has been reported only once in literature.^[3] We report a very

rare case of bilateral foramen magnum mirror meningioma. The purpose of this article is to illustrate the rare occurrence of bilateral meningioma in the foramen magnum and the difficulties in managing the surgical challenge.

CASE REPORT

A case of a 45-year-old female presented with neck pain, paresthesia in all four limbs, and difficulty in walking for 1 year duration. She had no history of headache, seizures, or any other symptoms attributable to intracranial pathology. Neurological examination revealed spasticity with hyperreflexia in bilateral lower limb. She had B/L hand grip weakness. There were no subcutaneous nodules, hypopigmented macules, or other stigmata of NF. Imaging study revealed only multiple meningiomas at foramen magnum and no other intracranial lesions suggestive of NF-2.

Magnetic resonance imaging (MRI) revealed well-defined lobulated dural-based mass lesion at foramen magnum on either side of spinal canal, located posterolateral causing severe compression of spinal cord. The cervicomedullary junction and upper cervical cord were sandwiched between the lesions. On contrast MRI, lesion showed homogenous avid enhancement. The left VA was encased within the lesion while the right vertebral was seen abutting it. The mass measured 14 mm (craniocaudal) \times 12 mm (anterior-posterior) \times 8 mm (width) on the right side and 12 mm (craniocaudal) \times 11 mm (anterior-posterior) \times 7 mm (width) on the left side [Figure 1]. A diagnosis of mirror meningioma at foramen magnum was made and resection was planned. The patient underwent C-1 posterior arch excision, C-2 laminectomy, foramen magnum decompression, and resection of lesions. The tumor was highly vascular with different dural attachments posterior to dentate ligaments, on either side. Tumor was resected gross totally on the right side, in piecemeal. However, during the resection of medial part of the left side tumor, it was found to be adhered to the VA. Since the mass was adherent to the left VA, subtotal resection was done in a piecemeal manner and the dura was closed. Postoperative period was uneventful and the patient improved symptomatically. A contrast-enhanced MRI at follow-up of 6 months showed complete removal of tumor on the right side and small residual lesion on the left side [Figure 2]. Histopathology revealed meningothelial meningioma (WHO-Grade 1) [Figure 3].

The patient was advised Gamma Knife radiosurgery (GKRS) for residual lesion but due to personal financial constraints, it could not be administered. Now, the patient is under regular clinical as well as imaging follow-up for early pick up of increase in size of residual cranial or appearance of new spinal lesion.

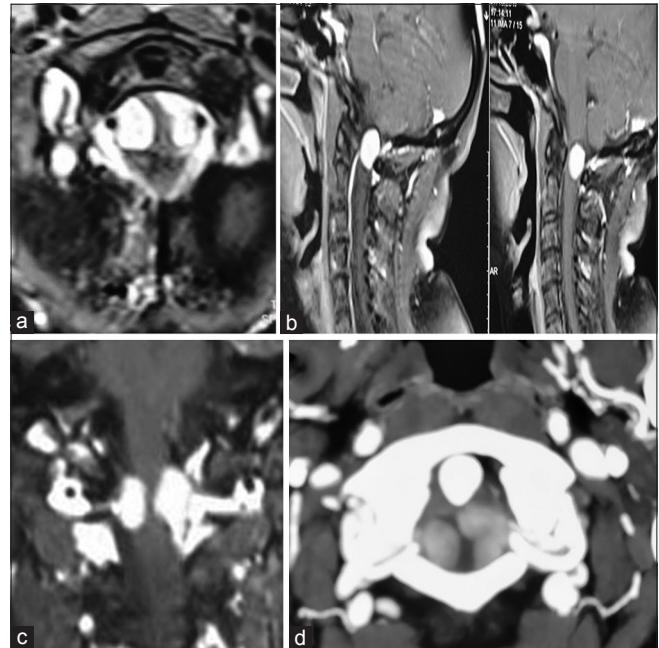


Figure 1: Preoperative contrast-enhanced magnetic resonance imaging (MRI) images showing well-defined bilateral enhancing lesions. The neuraxis is sandwiched between the lesions and severely compressed (a) Axial: bilateral enhancing mass lesion at foramen magnum, (b) Sagittal images MRI, (c) Coronal image MRI, (d) Computed tomography angiography showing relation of lesions with both vertebral arteries.

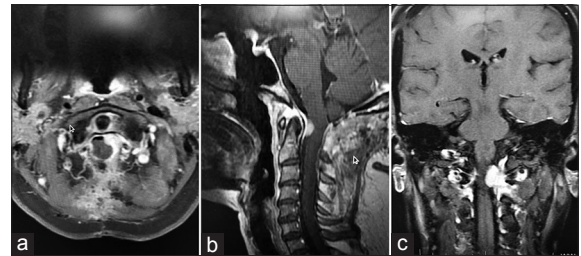


Figure 2: Postoperative contrast-enhanced magnetic resonance imaging (a) axial, (b) sagittal, (c) coronal images showing complete resection of the right-sided meningioma with the left-sided residual tumor.

DISCUSSION

Multiple meningiomas occurring in different neuraxial compartments are distinctly rare. Konar *et al.*^[3] reported the first case in English literature about twin meningioma arising from both sides of ventrolateral dura at foramen magnum; however, two separate lesions with different dural attachment were noted only during the resection. In their patient, since the tumor was encasing right VA, it was approached through the right side far lateral with condylar drilling. The significant adherence to the left VA prohibited tumor resection on the left side in the same sitting and the patient was given GKRS for the left side lesion.^[3]

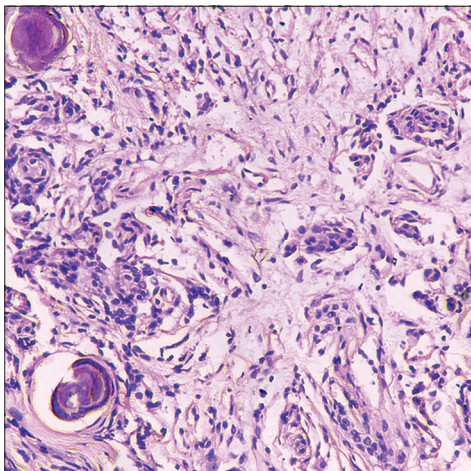


Figure 3: Histopathology illustrating tumor comprised round to oval cells with indistinct cytoplasm arranged in syncytial sheets and whorls along with psammoma bodies. No atypical mitosis or areas of necrosis noted.

There is no single best approach for FMMs and the optimal approach should be defined according to the localization and the extent of the tumor to minimize the extent of resultant morbidity. Early reports of the resection of FMM describe a standard suboccipital craniectomy with or without variations of the standard technique including lateral occipital bone resection and/or C-1 and C-2 laminectomies. This surgical approach proved adequate for lesions located posterior to the dentate ligament. However, anterior or anterolateral lesions were associated with increased surgical morbidity, due to undue brainstem retraction needed for adequate exposure.^[1] Several studies reported gross total resection of anterior or anterolateral FMMs through a conventional posterior suboccipital approach.^[2] The far-lateral modification has considerably expanded the surgical armamentarium by increasing efficacy and minimizing morbidity in the surgical removal of FMMs. Bilateral staged far lateral approach for bilateral mirror tumors may compromise the stability of foramen magnum and risked VA injury.^[3] Samii *et al.* concluded that the relationship of the craniocervical junction tumors to neighboring structures, i.e. the VA in particular, determines its resectability and recommended using extreme caution with en plaque or recurrent meningiomas.^[4] Unilateral approach is insufficient for contralateral tumor; hence, in the present case, midline approach was preferred to reach both side tumors. The significant adherence to the left VA prohibited us from resecting the left side tumor completely in the same sitting. As the right VA was free from the lesion, we were able to resect the right side lesion completely.

Preoperative imaging studies and neurological function should be reviewed carefully to establish an individualized

management strategy to improve long-term outcome. Operative management of multiple meningiomas occupying both cranial and spinal compartments poses special problems. A decision is needed to be made regarding which lesion, or lesions should be removed at first keeping in mind that histologically, each of these tumors may be a dissimilar variant of meningioma. Small or asymptomatic tumors may be followed-up with serial imaging.

FMMs are one of the most surgically complex conditions in neuro-oncologic surgery, requiring special considerations due to the vicinity of the medulla oblongata, the lower cranial nerves, and the VA. The extent of the surgical approach to FMMs must be based on the main point of dural attachment and tailored individually case by case. Regardless of the eventual management decision, such patients must be kept under close follow-up.

CONCLUSION

We report a very rare case of mirror FMMs, which has been reported only once in literature to the best of our knowledge. Meningiomas of foramen magnum are among the most challenging of all skull base lesions. Although complete excision of the tumor is the aim of surgery, it is safer to leave portions of tumor that is adherent to critical structures which can be managed by GKRS.

Declaration of patient consent

The authors certify that they have obtained all appropriate patient consent forms.

Financial support and sponsorship

Nil.

Conflicts of interest

There are no conflicts of interest.

REFERENCES

1. Flores BC, Boudreaux BP, Klinger DR, Mickey BE, Barnett SL. The far-lateral approach for foramen magnum meningiomas. *Neurosurg Focus* 2013;35:E12.
2. Kandenwein JA, Richter HP, Antoniadis G. Foramen magnum meningiomas experience with the posterior suboccipital approach. *Br J Neurosurg* 2009;23:33-9.
3. Konar S, Bir SC, Maiti TK, Kalakoti P, Nanda A. Mirror meningioma at foramen magnum: A management challenge. *World Neurosurg* 2016;85:364.e1-4.
4. Samii M, Klekamp J, Carvalho G. Surgical results for meningiomas of the craniocervical junction. *Neurosurgery* 1996;39:1086-94.

5. Tsermoulas G, Turel MK, Wilcox JT, Shultz D, Farb R, Zadeh G, *et al.* Management of multiple meningiomas. *J Neurosurg* 2018;128:1403-9.

How to cite this article: Kumar A, Konar S, Hussain N, Chaturvedi J. Mirror meningioma at foramen magnum: Enigma in management of a very rare case. *Surg Neurol Int* 2019;10:230.