

# Sinonasal undifferentiated carcinoma presenting as recurrent fronto-ethmoidal pyomucocele

Departments of Neurosurgery,  
SGPGIMS, Lucknow, Uttar Pradesh,  
India

Sushil Kumar Aggarwal, Amit Keshri, Rajkumar

## ABSTRACT

We describe a case of a 53-year-old man presented to our ENT OPD with chief complaints of recurrent right supraorbital swelling for last 6 months, which was associated with bilateral periorbital edema. Contrast-enhanced computerized tomographic scan showed a large frontoethmoidal mucocele with expansion of the bone but there was no erosion. Endoscopic marsupialization along with external frontoethmoidectomy was done to treat the patient and the collected pus, fluid and necrotic tissue was sent for HPE. Biopsy came out to be sinonasal carcinoma, which is a rare occurrence in frontal sinus. Moreover, sinonasal carcinoma presenting as recurrent frontoethmoidal mucocele has not been reported till date in the literature to the best of our knowledge. This case is being reported to make aware among all ENT surgeons and to be cautious about such presentation.

**Key words:** Paranasal sinuses, recurrent pyomucocele, sinonasal carcinoma

### Address for correspondence:

Dr. Sushil Kumar Aggarwal,  
Department of Neurosurgery,  
SGPGIMS, Lucknow – 226 014,  
India.  
E-mail: doc.sushil.pgi@gmail.  
com

## INTRODUCTION

Malignant neoplasms of the paranasal sinuses and nasal cavity are rare, comprising only 3% of all head and neck malignancies.<sup>[1]</sup> This includes both primary sinonasal neoplasms like squamous cell carcinoma, nasopharyngeal carcinoma, lymphoma, esthesioneuroblastoma, primary sinonasal melanoma and adenocarcinoma of minor salivary gland origin<sup>[2]</sup> and metastatic disease. Most of these tumors arise from the maxillary sinus and are predominantly squamous cell carcinoma.<sup>[3,4]</sup>

Exposure to substances such as wood dust, textile or leather dusts, nickel, isopropyl oils, among others, has

been implicated as a predisposing factor to sinonasal malignancies.<sup>[5,6]</sup> The symptoms depend on the site and extent of tumor involvement. Epistaxis often accounts for hospital presentation, though there could be orofacial, ophthalmic and cerebral symptoms in advanced disease.

Sinonasal undifferentiated carcinoma (SNUC) is a rare, highly aggressive malignant tumor, apparently derived from the lining epithelium of the paranasal sinuses and nasal cavity. It was first classified as a separate entity in 1986 based on its distinct histology, immunohistochemical profile and clinical course.<sup>[7]</sup> The etiology of sinonasal carcinomas is unknown. There may be an association with cigarette smoking and a previous history of radiation therapy.<sup>[7]</sup> In contrast to nasopharyngeal carcinoma, an association with Epstein-Barr virus infection has not been demonstrated. No specific occupational exposure has been implicated. At initial diagnosis, the tumor is often quite extensive, with orbital and cranial involvement common.<sup>[8]</sup>

Due to the small number of cases seen, the ideal treatment regimen has not been systematically

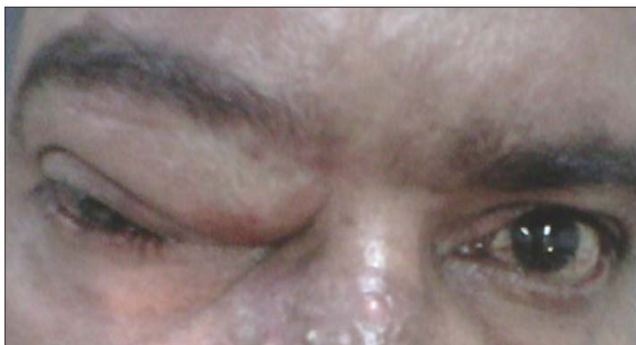| Access this article online   |   |
|--|---|
| <b>Quick Response Code:</b><br> | <b>Website:</b><br>www.njms.in          |
|  | <b>DOI:</b><br>10.4103/0975-5950.102162 |

evaluated. However, treatment generally involves surgical removal of the tumor.<sup>[9]</sup> Patients with SNUC have a high rate of both local–regional recurrence and distant metastasis. Moreover, because of the complex anatomy of the head and neck area, complete removal of the tumor with wide margins is not always possible. Consequently, surgery is commonly combined with radiation or chemotherapy or both. Unfortunately, the prognosis for a patient with SNUC is extremely poor; most patients die of local disease within 1 year of diagnosis.<sup>[10]</sup> Nevertheless, long-term survival has been documented in some patients,<sup>[11]</sup> especially in cases diagnosed early in the disease process.

This case has been reported due to rarity of sinonasal carcinoma occurring in frontal sinus and its unique presentation of recurrent frontoethmoidal mucocele which did not lead us to think of SNUC until HPE report became available.

## CASE REPORT

A 53-year-old male patient presented to ENT OPD of our tertiary care institute with chief complaints of right periorbital swelling and pain for last 2 months [Figure 1]. It was associated with complete closure of right eyelid. There was no complaint in left eye. There was no history of nasal obstruction, sneezing, nasal discharge, fever or decreased vision. Patient was a known case of DM and HTN and was on medication for that. Patient was also a case of psoriasis for which he was taking treatment from a dermatologist. There was no history of trauma. There was two times previous history of incision and drainage done outside for right eye swelling about 1 and 2 months back, respectively, but swelling recurred. On clinical examination, ENT examination was normal. Right periorbital swelling was present with reduced palpebral fissure and overlying skin was tense and erythematous. Vision was normal in both eyes. Bilateral pupils were normal and reacting to light. On palpation, right medial

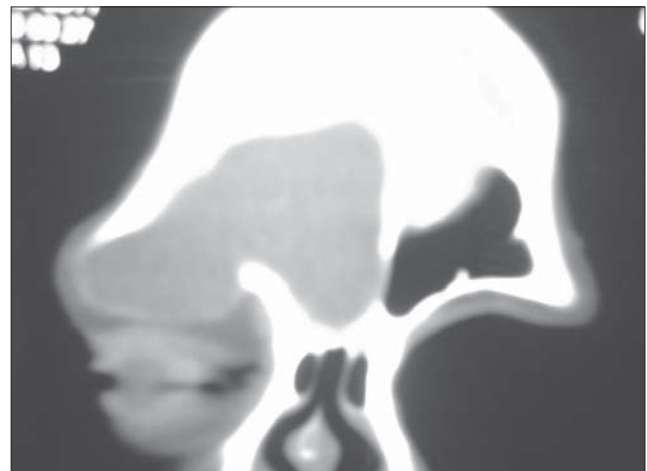


**Figure 1:** Patient presenting with right supraorbital swelling with right eye vision normal. Patient also has got psoriasis and hence multiple maculopapular lesions are seen on the face

supraorbital wall was dehiscent, which may be due to previous surgery. Contrast-enhanced CT scan of PNS, nose and orbit was done to look for the cause of right eye swelling. CT scan showed collection in right frontal sinus with expansion of both anterior and posterior table of frontal sinus. Bone dehiscence was present on right medial part of orbital roof [Figure 2]. Patient was planned for nasal endoscopic marsupialization of right frontal sinus pyomucocele. All investigations required for general anesthesia were done and PAC clearance was done. Endoscopic marsupialization was done along with external frontoethmoidectomy by giving extended Lynch-Howarth incision. Right medial orbital roof was dehiscent with pus draining into right eye. Pus along with necrotic tissue came out which was sent for histopathological examination. Biopsy, to our surprise, came out to be sinonasal undifferentiated carcinoma. Patient was referred to radiotherapy department for post-operative chemo-RT. At present, patient is undergoing chemo-RT with marked reduction of periorbital swelling though the prognosis appears to be gloomy. There is recurrent collection of pus in right frontal sinus for which wide bore aspiration is done after every 2 weeks.

## DISCUSSION

Sinonasal malignancies represent 3% of all head and neck malignancies and 0.2–0.8% of all malignancies in the body.<sup>[12]</sup> Males are involved predominantly compared to females as mentioned in the literature similar to our case.<sup>[5,6]</sup> The average duration at presentation is 8.5 months as mentioned in the literature. Our case presented to us after 3 months of delay. The delay in presentation could be attributed, not only to the nonspecific symptoms of the lesion at an early stage but also to the sociocultural beliefs and practices of the



**Figure 2:** Coronal cut of CECT PNS, nose and orbit showing right frontal pyomucocele with erosion of the surrounding bones

people which leads to delay in presenting to the hospital. In addition, contemporary radiologic examination tools such as computerized tomographic (CT) scan and magnetic resonance imaging (MRI), which are effective tools for early detection of these sinonasal lesions, are not readily available and affordable in most peripheral parts.<sup>[13,14]</sup> Various environmental factors, especially the industrial agents, have been reported as known predisposing factors to sinonasal malignancies.<sup>[15]</sup> In our case, though, there was no environmental predisposing factor present.

The presentation of sinonasal malignant tumor depends on the site involved and direction of spread. Approximately 55% of sinonasal tumors originate from the maxillary sinus, 35% from the nasal cavity, 9% from the ethmoid sinus and the remainder from the frontal and sphenoid sinuses.<sup>[16]</sup> Our case presented with recurrent right supraorbital swelling and the tumor was arising from right frontal sinus, the rare site as well as mode of presentation of sinonasal malignancies.

Early complaints of sinonasal malignancies are often minimal and can mimic those of chronic sinusitis, though in our case, patient presented to us with complaints of recurrent right supra-orbital swelling.<sup>[17]</sup> When pain occurs, it is an indicator of perineural extension of the malignancy or tumor infection and hence this may be the cause of pain in our case also.<sup>[17]</sup>

Under light microscopy, many sinonasal neoplasms appear to be composed of small to medium sized cells that stain blue with conventional hematoxylin and eosin (H and E) staining. The category of round blue-cell tumors is quite large and can include malignant tumors such as an olfactory neuroblastoma, small-cell neuroendocrine carcinoma, SNUC, malignant melanoma, lymphoma, rhabdomyosarcoma and Ewing's sarcoma. Squamous cell carcinoma had been reported to be the predominant epithelial cell type (80%) followed by adenocarcinoma type (10–20%) of all sinonasal malignancies.<sup>[4]</sup>

SNUC is a rare tumor of the paranasal sinuses of unknown cause, most often arising in the nasal cavity and presenting at an advanced stage unlike our case in which the malignancy originated from frontal sinus and patient presented to us at a relatively early stage. It was described less than 25 years ago,<sup>[7]</sup> being previously diagnosed as esthesioneuroblastoma or neuroendocrine carcinoma. Because of the rarity of this disease, prior publications on SNUC represent small case series. These have routinely shown aggressive behavior of the tumor with poor prognosis for survival. Multimodality treatment has been recommended by most authors.<sup>[7]</sup>

Surgical treatment is performed routinely prior to chemoradiation. But experience gained in several studies show that up-front surgical treatment delays the true critical treatment for SNUC (e.g., radiation or chemoradiation).<sup>[18]</sup> It certainly does not support the conclusion that surgery is contraindicated, as many long-term survivors had surgical resection with negative margins prior to chemo-RT. Overall survival in multiple series are consistent with complete surgical resection with negative margins followed by chemo-RT. Hence, if up-front surgery is planned in any case, then aim should be to resect the tumor completely with biopsy proven negative margins followed by post-operative chemotherapy and radiotherapy. Elective treatment of neck is recommended in every case of SNUC whether neck nodes are palpable or not.<sup>[18]</sup> Disease recurrence does not surprisingly portend a dismal prognosis. Death within a year of recurrence appears to be standard in every case of SNUC.

Multiple studies are being done to test the patients for HER2/neu and epidermal growth factor receptor status to assess for possible response to trastuzumab and cetuximab. This is not yet accepted practice, but it is believed that the next step in improving outcomes for SNUC is biologically tailored therapy with complete surgical resection. Research is going on to identify tumor markers that will help to predict prognosis in SNUC. But still there is no breakthrough. Urokinase plasminogen receptor, a marker for tumor invasion and metastases, is expressed in all those cases associated with especially poor prognosis, particularly in patients with positive microscopic margins after resection.

---

## CONCLUSION

SNUC routinely has a poor prognosis, even in patients treated aggressively with multiple modalities. Our current approach continues to be complete resection with negative margins if possible, followed by concurrent chemoradiation. Treatment of the neck, whether surgically or with radiation, is necessary to improve regional control and should be a routine in every case. In the end, we conclude that recurrent frontoethmoidal pyomucocele presentation in an adult patient should be investigated early to rule out the sinister pathology like SNUC underlying such presentation and patient should be managed accordingly.

---

## REFERENCES

1. Franchi A, Moroni M, Massi D, Paglierani M, Santucci M. Sinonasal undifferentiated carcinoma, nasopharyngeal-type undifferentiated carcinoma, and keratinizing and nonkeratinizing squamous cell

- carcinoma express different cytokeratin patterns. *Am J Surg Pathol* 2002;26:1597-604.
2. Goldenberg D, Golz A, Fradis M, Martin D, Netzer A, Joachims HZ. Malignant tumors of the nose and paranasal sinuses: A retrospective review of 291 cases. *Ear Nose Throat J* 2001;80:272-7.
  3. Acheson ED, Pippard EC, Winter PD. Nasal cancer in the Northampton shire boot and shoe industry: Is it declining? *Br J Cancer* 1982;46: 940-6.
  4. Keane WM, Atkins JP Jr, Wetmore R, Vidas M. Epidemiology of head and neck cancer. *Laryngoscope* 1981;91:2037-45.
  5. Weber AL. Tumors of the paranasal sinuses. *Otolaryngol Clin North Am* 1988;21:439-54.
  6. Carter BL. Tumors of the paranasal sinuses and nasal cavity. In: Valvassori GE, Buckingham RA, Carter BL, eds. *Head and neck imaging*. New York, NY: Thieme Medical Publishers; 1988. p. 219-34.
  7. Frierson HF Jr, Mills SE, Fechner RE, Taxy JB, Levine PA. Sinonasal undifferentiated carcinoma. An aggressive neoplasm derived from Schneiderian epithelium and distinct from olfactory neuroblastoma. *Am J Surg Pathol* 1986;10:771-9.
  8. Kim BS, Vongtama R, Julliard G. Sinonasal undifferentiated carcinoma: Case series and literature review. *Am J Otolaryngol* 2004;25:162-6.
  9. Day TA, Beas RA, Schlosser RJ, Woodworth BA, Barredo J, Sharma AK, *et al.* Management of paranasal sinus malignancy. *Curr Treat Options Oncol* 2005;6:3-18.
  10. Jeng YM, Sung MT, Fang CL, Huang HY, Mao TL, Cheng W, *et al.* Sinonasal undifferentiated carcinoma and nasopharyngeal-type undifferentiated carcinoma: Two clinically, biologically, and histopathologically distinct entities. *Am J Surg Pathol* 2002;26:371-6.
  11. Miyamoto RC, Glitch LL, Biddinger PW, Gluckman JL. Esthesioneuroblastoma and sinonasal undifferentiated carcinoma: Impact of histological grading and clinical staging on survival and prognosis. *Laryngoscope* 2000;110:1262-5.
  12. Curtin HD, Tabor EK. Nose, paranasal sinuses, and facial bones. In: Latchaw RE, editor. *MR and CT imaging of the head, neck, and spine*. St. Louis, MO: Mosby Year Book; 1991. p. 947-90.
  13. Lloyd G, Lund VJ, Howard D, Savy L. Optimum imaging for sinonasal malignancy. *J Laryngol Otol* 2000;114:557-62.
  14. Mosesson RE, Som PM. The radiographic evaluation of sinonasal tumors: An overview. *Otolaryngol Clin North Am* 1985;28:1097-115.
  15. Luce D, Leclerc A, Bégin D, Demers PA, Gérin M, Orlowski E, *et al.* Sinonasal cancer and occupational exposures: A pooled analysis of 12 case-control studies. *Cancer Causes Control* 2002;13:147-57.
  16. Lewis JS, Castro EB. Cancer of the nasal cavity and paranasal sinuses. *J Laryngol Otol* 1972;86:255-62.
  17. Komisar A. Nasal obstruction due to benign and malignant neoplasms. *Otolaryngol Clin North Am* 1989;22:351-8.
  18. Lin EM, Sparano A, Spalding A, Eisbruch A, Worden FP, Heth J, *et al.* Sinonasal Undifferentiated Carcinoma: A 13-Year Experience at a Single Institution. *Skull Base* 2010;20:61-7.

**How to cite this article:** Aggarwal SK, Keshri A, Rajkumar. Sinonasal undifferentiated carcinoma presenting as recurrent fronto-ethmoidal pyomucocele. *Natl J Maxillofac Surg* 2012;3:55-8.

**Source of Support:** Nil. **Conflict of Interest:** None declared.