



Surgical technique for arthroscopic onlay suprapectoral biceps tenodesis with an all-suture anchor

Drew A. Lansdown, MD ^{a,*}, Eamon D. Bernardoni, MS ^b, Nikhil N. Verma, MD ^b

^a Department of Orthopedic Surgery, University of California, San Francisco, San Francisco, CA, USA

^b Department of Orthopedic Surgery, Rush University, Chicago, IL, USA

ARTICLE INFO

Keywords:

Biceps tenodesis
Suprapectoral
Arthroscopic biceps tenodesis
Onlay tenodesis
Surgical technique
All-suture tenodesis

Level of evidence: Surgical Technique

The long head of the biceps is a frequent pain generator in the shoulder. Tendinopathy of the long head of the biceps may be treated with biceps tenodesis. There has been great debate about the optimal technique for biceps tenodesis, without a clear distinction between different techniques. Biceps tenodesis fixation may include interference fixation, suspensory fixation, all-suture anchors, and soft tissue fixation. In this technical note, we describe an all-arthroscopic onlay suprapectoral biceps tenodesis with an all-suture anchor.

© 2017 The Authors. Published by Elsevier Inc. on behalf of American Shoulder and Elbow Surgeons. This is an open access article under the CC BY-NC-ND license (<http://creativecommons.org/licenses/by-nc-nd/4.0/>).

The long head of the biceps tendon is a common pain generator in the anterior shoulder, with conditions including tendinopathy, tendon tears, superior labral injuries, and biceps tendon instability. Treatment options for a patient with a painful or injured long head of the biceps tendon include tenotomy and tenodesis. Whereas tenotomy is shown to offer pain relief, this procedure alone may lead to a bothersome cosmetic deformity through the arm.^{7,15} As a result, multiple tenodesis techniques have been developed to transfer the origin of the long head of the biceps to the proximal humerus.

Open^{3,6,9,10} and arthroscopic^{2,4,12,14} techniques have been described that allow the management of long head of the biceps disease. The use of biceps tenodesis has increased recently, with Werner et al reporting a 1.7-fold increase between 2008 and 2011.¹⁶ This same study found a rising incidence of arthroscopic tenodesis during the same time.¹⁶

In this technical note, we describe a novel technique for an arthroscopic biceps tenodesis. Table I offers a summary of key steps for the procedure, and Video S1 demonstrates performance of this technique.

Surgical technique

Positioning of the patient

We prefer to perform the procedure in the beach chair position, although the same steps may be accomplished in the lateral

decubitus position. After an interscalene nerve block, general anesthesia or sedation is induced, and the patient is positioned in the sitting position. The operative arm is held in a pneumatic arm holder (SPIDER2; Smith & Nephew, Andover, MA, USA).

Initial exposure and preparation

Glenohumeral diagnostic arthroscopy is performed through a standard posterior portal (Fig. 1) with a 30° arthroscope. The intra-articular structures are evaluated in a systematic fashion, and disease at the long head of the biceps is confirmed by pulling the extra-articular portion of the tendon into the joint for inspection (Fig. 2). Once the plan for biceps tenodesis is confirmed, a tenotomy is performed with a low-profile basket through a standard anterior rotator interval portal, releasing the biceps flush with the superior labrum. The biceps tendon may be tagged before tenotomy with a suture or with a spinal needle, although we do not routinely perform this step. Any remaining stump of biceps tendon is débrided with a shaver.

Once all other planned procedures are completed, including labral débridement, subacromial decompression, rotator cuff repair, acromioplasty, and distal clavicle excision as indicated, the arm is positioned in 60° of forward flexion and 10°–20° of internal rotation with the elbow flexed to 60°. While viewing through a standard lateral portal, a spinal needle is used to localize an anterolateral portal. This portal is generally located 2 cm inferior and 2 cm lateral to the anterior rotator interval portal. The spinal needle can be used as a probe to find the long head of the biceps tendon and to ensure that the portal location is appropriate. The skin is incised with a No. 11 blade, which can then be used deep to incise along the lateral border of the biceps sheath. Alternatively, a radiofrequency ablation

* Corresponding author: Drew A. Lansdown, MD, Department of Orthopedic Surgery, University of California, San Francisco, 1500 Owens St, San Francisco, CA 94158, USA.

E-mail address: Drew.lansdown@gmail.com (D.A. Lansdown).

Table 1
Key steps for arthroscopic suprapectoral biceps tenodesis with an all-suture anchor

The arm is positioned in 60° of forward flexion, 10°–20° of internal rotation.

An anterolateral portal is localized approximately 2 cm inferior and 2 cm lateral to the standard anterior rotator interval portal.

A lateral portal is used to view in the subacromial space while working through the anterolateral portal.

The sheath around the long head of the biceps is opened with a No. 11 blade or radiofrequency device.

The tendon is pulled from the sheath and then controlled with a tissue grasper.

The groove is exposed distal to the upper border of the pectoralis major. The fibrocartilage transitional zone of the bicipital groove is identified.

An all-suture anchor is placed immediately distal to the fibrocartilage zone.

A cinch stitch is placed around the tendon.

The tendon is tensioned appropriately with the tissue grasper while an arthroscopic knot is tied.

The proximal stump of the tendon is truncated with the radiofrequency device.

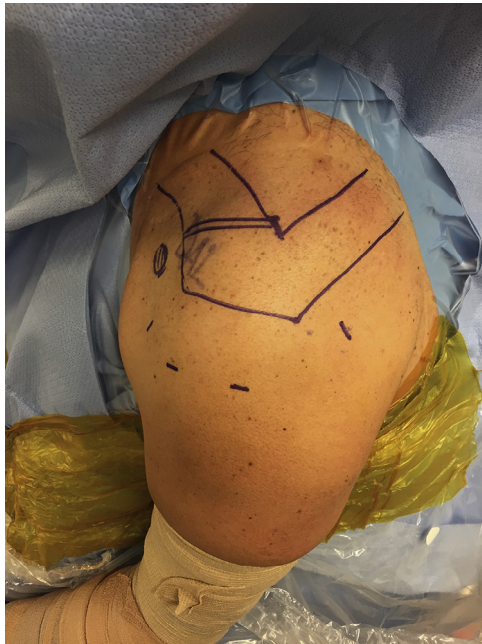

Figure 1 The skin is marked, outlining the clavicle, acromion, and coracoid as well as a standard anterior, posterior, lateral, and anterolateral portal.

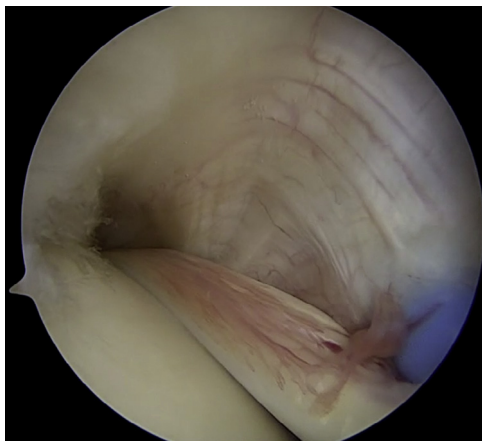


Figure 2 Through a standard posterior portal during diagnostic arthroscopy, the long head of the biceps tendon is identified and tenosynovitis is identified along the course of the biceps tendon.

device may be used through this portal to open the biceps tendon sheath.

Once the sheath is open, the long head of the biceps tendon is pulled out of the sheath using a probe or looped suture retriever.

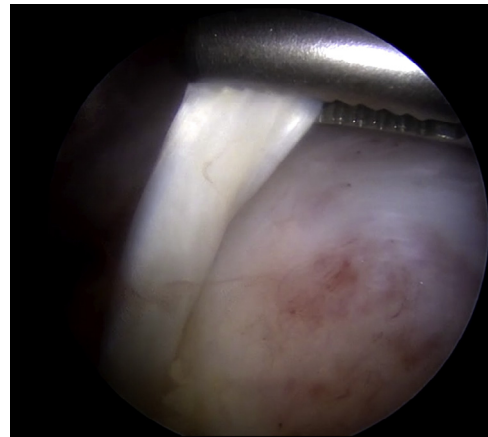


Figure 3 A grasper placed in the posterior portal is used to grasp the proximal aspect of the biceps tendon to manipulate the tendon during the rest of the procedure.

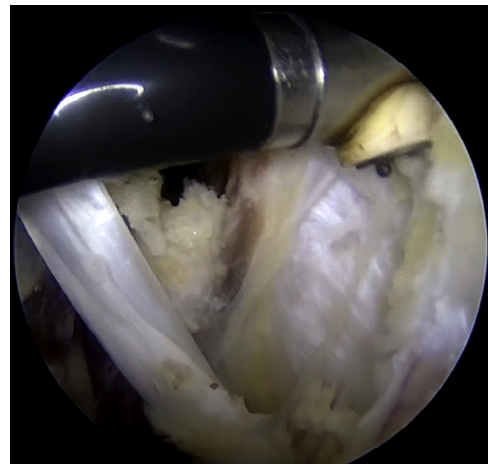


Figure 4 With the biceps tendon moved anteriorly and laterally using the grasper, a radiofrequency ablation device is used to open the biceps tendon sheath and to debride soft tissue. The shiny fibrocartilage signifies the transitional zone of the bicipital groove.

A tissue grasper is inserted through the posterior portal, and the biceps tendon is passed to the tissue grasper. The tendon is held in the grasper for the remainder of the procedure, allowing control of tendon position and eventually length for the tenodesis (Fig. 3).

With the grasper, the tendon is held anteriorly and medially. A radiofrequency device is used through the anterolateral portal to release tissue along the course of the biceps tendon (Fig. 4). This débridement is done carefully distally as crossing vessels are often

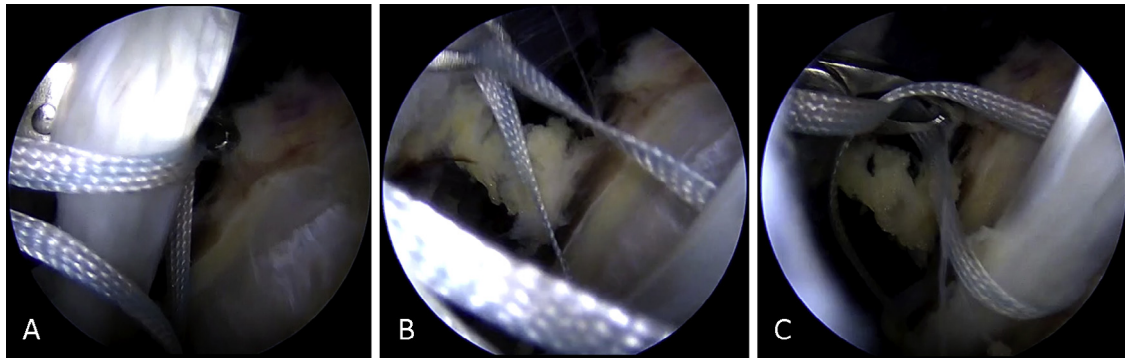


Figure 5 After the suture anchor is placed with the suture limbs posterior to the biceps tendon. (A) a looped suture retriever is used to partially pull one suture limb to the anterior side of the biceps tendon, creating a loop of suture anterior to the biceps tendon. (B) The loop of suture is positioned anterior to the biceps tendon. (C) The looped suture retriever is then passed anterior to posterior through the loop and grasps the free end of the same suture. The free end is then pulled through the loop, creating the cinch stitch.

encountered and cauterized. A transitional zone of fibrocartilage is visualized, marking the end of the bicipital groove. Distally, the upper border of the pectoralis major muscle is visualized.

Anchor placement and completion of tenodesis

An all-suture anchor (FiberTak; Arthrex, Inc., Naples, FL, USA) is inserted through the anterolateral portal immediately distal to the end of the fibrocartilage of the groove. An all-suture implant with either suture or tape would be appropriate for this technique. The tendon is pushed out of the groove with the grasper. A single-loaded or double-loaded anchor may be used. One of the suture limbs is passed deep to the tendon in a loop fashion (Fig. 5). The tendon is then moved back toward the groove with the grasper. The free limb is grabbed through the loop, creating a cinch that encompasses the biceps tendon (Fig. 5). A tissue penetrator is then introduced and passed through the tendon at the level of the anchor; the tissue grasper on the proximal tendon stump is used to pull the tendon over the penetrator (Fig. 6). The free suture limb is then pulled through the tendon with the grasper. The sutures are then pulled through a 5-mm cannula. The limb from the cinch stitch is marked as the non-post limb; the limb through the tendon serves as the post. If a double-loaded implant is chosen, this process is repeated once more.

With the sutures pulled out of a cannula, knots are tied to secure the biceps. The tissue grasper is used to pull on the tendon to reset

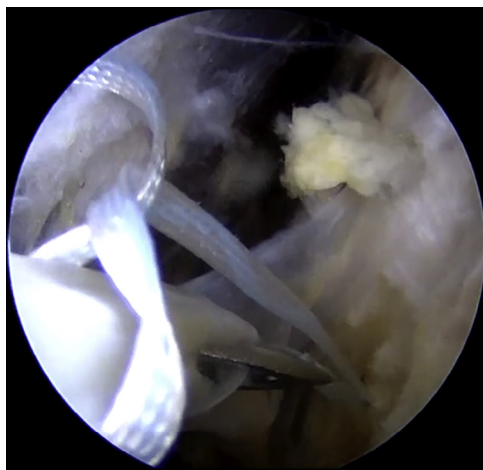


Figure 6 With the biceps tendon held in place, a penetrator is then used to pierce the biceps tendon at the location of the suture anchor and to grab the second suture limb. The previously completed cinch stitch can be seen superior to the penetrator.

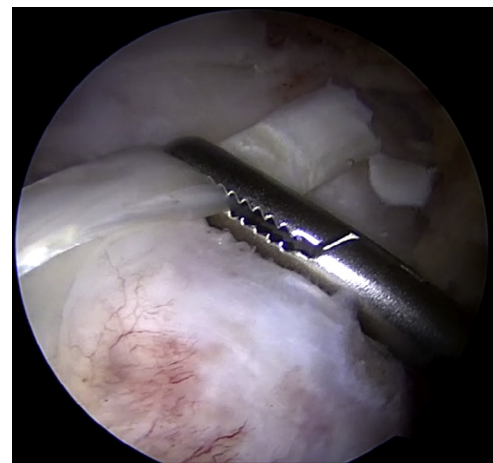


Figure 7 A grasper is used on the proximal end of the biceps tendon to hold the tendon with appropriate tension.

its length-tension relationship (Fig. 7). The appropriate tension is estimated by moving the grasper to be above the normal origin of the biceps tendon at the level of the superior glenoid. When tension is pulling on the post, the tendon is secured down to the anchor. If the cinch is improperly positioned, a looped suture grasper can be used to adjust the height of the cinch before tying (Fig. 8). Alternating half-hitches are placed to secure the tendon in this position (Fig. 9). The tying process is repeated as needed for a double-loaded implant. The suture limbs are cut, and the proximal stump of the biceps tendon is truncated with a radiofrequency ablation device (Fig. 9). The free proximal stump (generally approximately 3–4 cm in length) is then removed through the posterior portal with the tissue grasper.

Closure and rehabilitation

Arthroscopic portals are closed with interrupted 3-0 nonabsorbable suture, and the arm is placed in a shoulder abduction sling. The sling is prescribed for 4 weeks after surgery. During that time, patients perform pendulum exercises and elbow and wrist range of motion exercises. Active biceps exercises are avoided until 6 weeks after surgery, at which point gentle strength training is initiated. Strengthening progresses until 12 weeks, at which point patients are generally ready to return to all activities.

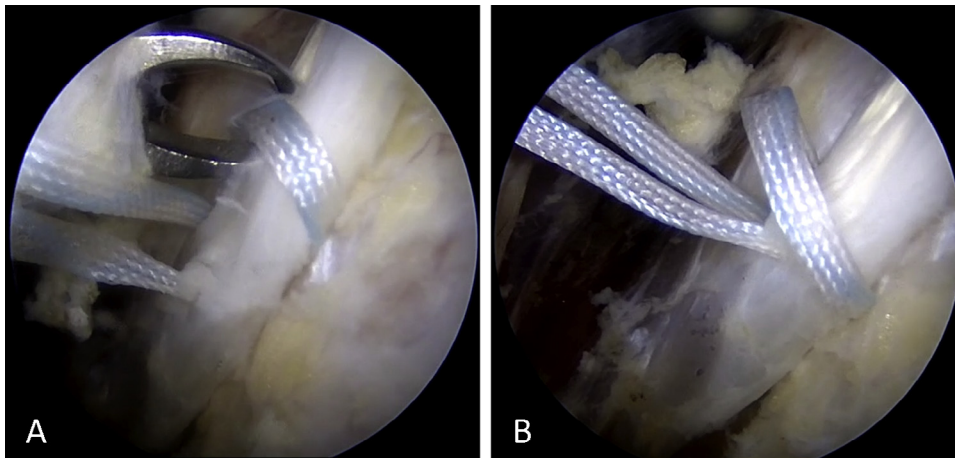


Figure 8 (A) A looped suture retriever is used to position the cinch stitch at the appropriate height, just distal to the transitional zone of the bicipital groove and where the all-suture anchor was inserted. (B) The cinch stitch is placed adjacent to the penetrating suture limb.

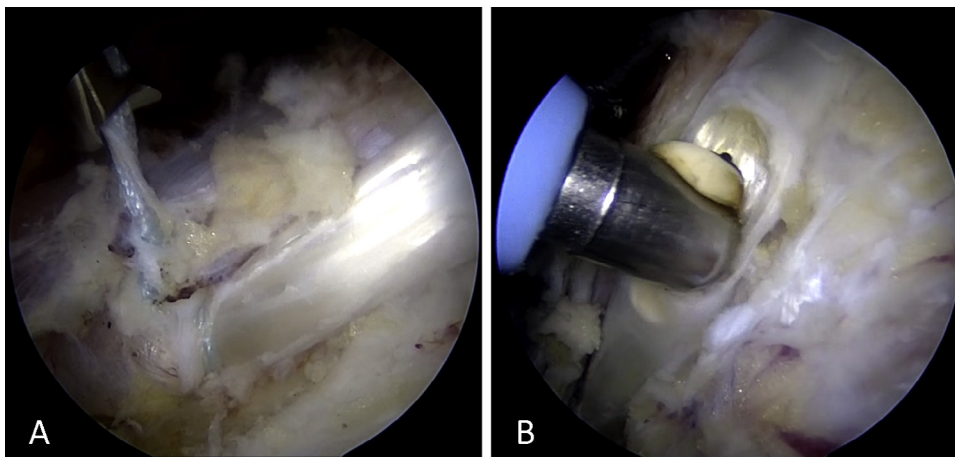


Figure 9 (A) With the tendon held in place, the sutures are then tied securely, holding the tendon in place. (B) A radiofrequency ablation device is used to cut the excess biceps tendon proximal to the knot. The remaining proximal stump is removed with the grasper through the posterior portal.

Potential complications

Two potential concerns exist with this technique that warrant further clinical and biomechanical studies. First, the strength of fixation of the described technique is not defined and may not be adequate in all patients. Second, the tensioning of the biceps may vary and could lead to either overtensioning or undertensioning of the construct. Indications for and contraindications to this procedure are outlined in [Table II](#).

Table II

Indications for and contraindications to arthroscopic suprapectoral biceps tenodesis with an all-suture anchor

Indications
Biceps tendinitis or tendinopathy
Concern about cosmetic implications or potential cramping pain of biceps tenotomy
Desire to avoid subpectoral incision or large tenodesis screw or drill hole
Contraindications
Need for high pullout strength in tenodesis construct—may consider subpectoral tenodesis instead
Distal lesion in the biceps tendon beneath the pectoralis major tendon

Discussion

Biceps tendon disease is frequently encountered in shoulder arthroscopy, and biceps tenodesis offers the advantage of maintaining muscle function and cosmesis. Multiple studies on clinical outcomes have demonstrated no difference in outcomes after either arthroscopic or open subpectoral fashion. We believe that this technique is reproducible and may offer several advantages over previously described methods.

One key to successful biceps tenodesis is the restoration of the anatomic length-tension relationship of the muscle-tendon unit. In the open subpectoral technique, the inferior margin of the pectoralis major tendon is used as a reference, as the muscle belly should begin at this level. There are not similar landmarks in an all-arthroscopic procedure, which can present a challenge, although we believe that positioning the tendon with a tissue grasper allows the appropriate position of the tendon in the groove. Werner et al described overtensioning in an arthroscopic suprapectoral tenodesis by 1.4 cm relative to a subpectoral tenodesis in a cadaveric model.¹⁷ This technique, however, involved pushing the proximal tendon into the tenodesis drill site with a forked implant, which may contribute to the overtensioning, whereas the currently described technique allows holding of tension on the tendon while securing it.

Groove pain has been suggested as a cause of recurrent symptoms after arthroscopic biceps tenodesis. The approach used in this technique places the biceps distal to the fibrocartilaginous groove, which should limit this as a potential postoperative symptom generator. In addition, there has been concern that a proximal biceps tenodesis may miss more distal tendinopathy, a so-called hidden lesion. Moon et al found approximately 80% of biceps disease to be extra-articular.¹¹ This suprapectoral approach could miss a portion of the tendon, although there is visualization past the superior border of the pectoralis major tendon and additional tendon may be pulled proximal into the operative area.

The suture fixation used in this technique is advantageous as the tendon does not need to be externalized at any time. With proximal interference screw fixation, the tendon is externalized for placement of a whipstitch. Externalization of the tendon for arthroscopic fixation with an interference screw and the open subpectoral approach may be more complicated in obese patients. Fixation with an interference screw requires the placement of a large drill hole that creates a stress riser through the proximal humerus fracture, which in turn may increase the risk for a torsional fracture.¹³ The keyhole technique for biceps tenodesis has performed well in biomechanical studies, although there have been fractures reported with this technique and up to 18.5% rate of tendon displacement.^{1,5,8} In patients with poor bone quality or in those expected to return to aggressive overhead activities, the use of an all-suture anchor, as in the current technique, may limit the fracture risk, although this suggestion warrants future biomechanical studies.

This technique is not without possible limitations. First, pullout strength with all-suture fixation may be lower than with interference screw fixation or keyhole tenodesis.¹⁰ In more muscular patients, this technique may not be desirable for this reason. We believe that the strength of the described construct would be comparable to that of other published suture anchor fixation methods, although this would warrant further investigation. If there is an hour-glass biceps tendon, a more distal tenotomy may need to be performed to move the tendon to an extra-articular location, in which case our method for referencing tendon position based on the proximal stump may not be possible.

Conclusion

We present a novel technique for suprapectoral, all-arthroscopic biceps tenodesis with an all-suture anchor. We believe that this surgical technique offers advantages with regard to implant size, tenodesis location, and ability to tension biceps while securing the tendon. Future research should investigate the biomechanical properties of this method.

Disclaimer

The authors, their immediate families, and any research foundations with which they are affiliated have not received any financial

payments or other benefits from any commercial entity related to the subject of this article.

Supplementary data

Supplementary data to this article can be found online at <https://doi.org/10.1016/j.jses.2017.12.001>

References

1. Froimson AI, O I. Keyhole tenodesis of biceps origin at the shoulder. *Clin Orthop Relat Res* 1975;112.
2. Gartsman GM, Hammerman SM. Arthroscopic biceps tenodesis: operative technique. *Arthroscopy* 2000;16:550-2.
3. Golish SR, Caldwell PE, Miller MD, Singanamala N, Ranawat AS, Treme G, et al. Interference screw versus suture anchor fixation for subpectoral tenodesis of the proximal biceps tendon: a cadaveric study. *Arthroscopy* 2008;24:1103-8. <http://dx.doi.org/10.1016/j.arthro.2008.05.005>
4. Green JM, Getelman MH, Snyder SJ, Burns JP. All-arthroscopic suprapectoral versus open subpectoral tenodesis of the long head of the biceps brachii without the use of interference screws. *Arthroscopy* 2017;33:19-25. <http://dx.doi.org/10.1016/j.arthro.2016.07.007>
5. Gyulai M. Humeral fracture after keyhole tenodesis. *Magy Traumatol Orthop Helyreallito Seb* 1990;33:234-6.
6. Hapa O, Günay C, Kömürçü E, Çakıcı H, Bozdağ E. Biceps tenodesis with interference screw: cyclic testing of different techniques. *Knee Surg Sports Traumatol Arthrosc* 2010;18:1779-84. <http://dx.doi.org/10.1007/s00167-010-1180-7>
7. Hsu AR, Ghodadra NS, Provencher MT, Lewis PB, Bach BR. Biceps tenotomy versus tenodesis: a review of clinical outcomes and biomechanical results. *J Shoulder Elbow Surg* 2011;20:326-32. <http://dx.doi.org/10.1016/j.jse.2010.08.019>
8. Kany J, Guinand R, Amaravathi RS, Allassaf I. The keyhole technique for arthroscopic tenodesis of the long head of the biceps tendon. In vivo prospective study with a radio-opaque marker. *Orthop Traumatol Surg Res* 2015;101:31-4. <https://doi.org/10.1016/j.otsr.2014.10.016>
9. Mazzocca AD, Rios CG, Romeo AA, Arciero RA. Subpectoral biceps tenodesis with interference screw fixation. *Arthroscopy* 2005;21:896. <http://dx.doi.org/10.1016/j.arthro.2005.04.002>
10. Millett PJ, Sanders B, Gobezi R, Braun S, Warner JJ. Interference screw vs. suture anchor fixation for open subpectoral biceps tenodesis: does it matter? *BMC Musculoskelet Disord* 2008;9:121. <http://dx.doi.org/10.1186/1471-2474-9-121>
11. Moon SC, Cho NS, Rhee YG. Analysis of "hidden lesions" of the extra-articular biceps after subpectoral biceps tenodesis. *The subpectoral portion as the optimal tenodesis site*. *Am J Sports Med* 2015;43:63-8. <http://dx.doi.org/10.1177/0363546514554193>
12. Romeo AA, Mazzocca AD, Tauro JC. Arthroscopic biceps tenodesis. *Arthroscopy* 2004;20:206-13. <http://dx.doi.org/10.1016/j.arthro.2003.11.033>
13. Sears BW, Spencer EE, Getz CL. Humeral fracture following subpectoral biceps tenodesis in 2 active, healthy patients. *J Shoulder Elbow Surg* 2011;20:e7-11. <http://dx.doi.org/10.1016/j.jse.2011.02.020>
14. Sekiya JK, Elkousy HA, Rodosky MW. Arthroscopic biceps tenodesis using the percutaneous intra-articular transtendon technique. *Arthroscopy* 2003;19:1137-41. <http://dx.doi.org/10.1016/j.arthro.2003.10.022>
15. Slenker NR, Lawson K, Ciccotti MG, Dodson CC, Cohen SB. Biceps tenotomy versus tenodesis: clinical outcomes. *Arthroscopy* 2012;28:576-82. <http://dx.doi.org/10.1016/j.arthro.2011.10.017>
16. Werner BC, Brockmeier SF, Gwathmey FW. Trends in long head biceps tenodesis. *Am J Sports Med* 2015;43:570-8. <http://dx.doi.org/10.1177/0363546514560155>
17. Werner BC, Lyons ML, Evans CL, Griffin JW, Hart JM, Miller MD, et al. Arthroscopic suprapectoral and open subpectoral biceps tenodesis: a comparison of restoration of length-tension and mechanical strength between techniques. *Arthroscopy* 2015;31:620-7. <http://dx.doi.org/10.1016/j.arthro.2014.10.012>