



Cross-sectional Study

Incidence of eye complications among sickle cell disease patients in Jeddah, Saudi Arabia: A cross-sectional study

Eid Ayed Almasoudi^a, Sultan Fahad Maghlah^b, Abubakr Salem Alzwhairi^a,
Abdullah Omar Aljuwaybiri^c, Abdullah Saleh Alqahtani^{d,e,f,*}

^a College of Medicine, University of Jeddah, Jeddah, 21959, Saudi Arabia

^b Department of Family Medicine, King Abdulaziz Medical City, Jeddah, 21423, Saudi Arabia

^c Department of Ophthalmology, King Fahad Armed Forces Hospital, Jeddah, 23311, Saudi Arabia

^d Department of Surgery, Division of Ophthalmology, King Abdulaziz Medical City, Jeddah, 21423, Saudi Arabia

^e King Saud bin Abdulaziz University for Health Sciences, Jeddah, 22384, Saudi Arabia

^f King Abdullah International Medical Research Center, Jeddah, 22384, Saudi Arabia



ARTICLE INFO

Keywords:

Eye complications
Retinopathy
Saudi Arabia
Sickle cell disease
Ophthalmology screening

ABSTRACT

Introduction: Sickle cell disease (SCD) is a heritable blood disorder resulting in deformed, rigid red blood cells, rendering them more prone to vaso-occlusion. Ocular complications are known to affect multiple organs through the body's vasculature. Here, we evaluated the incidence of eye complications in patients with SCD at King Abdulaziz Medical City in Jeddah, Saudi Arabia.

Materials and methods: We used a cross-sectional approach and collected relevant medical data from nine patients with SCD. Ophthalmic assessment included visual acuity and an in-clinic dilated fundus examination. All patients were asked to attend the ophthalmology clinic to undergo optical coherence tomography (OCT) angiography, macular OCT scan, and fundus photography. The results of the imaging tests were interpreted by a certified ophthalmology consultant specializing in retinal diseases. Descriptive analyses of the results were also performed.

Results: The mean age of the nine patients was 24.78 ± 10.9 years. All patients were non-hypertensive, one had type 1 diabetes, and another had type 2 diabetes. Five patients had normal visual acuity, two had slight impairments in at least one eye, and two had moderate impairment in at least one eye. One of the nine patients exhibited retinal ischemia in the right eye despite normal macular thickness (visual acuity, OD, 6/30; OS, 6/21). The remaining eight patients showed no ocular abnormalities.

Conclusion: Of the nine patients with SCD, five showed no symptoms of ocular complications. One patient showed retinal ischemia in the right eye, despite a normal macular thickness. This study's results suggest routine ophthalmologic examination may not be able to detect or monitor macular or retinal abnormalities unless augmented with detailed imaging techniques.

1. Introduction

Sickle cell disease (SCD) is a well-known inherited disorder of red blood cells and one of the most prevalent monogenic disorders globally [1]. It presents itself in different forms, the most common types being the homozygous beta-globin gene mutation (HbSS), heterozygous SC, and heterozygous S beta-thalassemia [2]. HbSS is the most severe form of SCD, with each sickle cell gene "S" inherited from both parents. SCD is multisystemic as its pathophysiology primarily involves sickle hemoglobin polymerization in erythrocytes, which are responsible for

supplying oxygen to different organs in the body [1]. Patients with SCD tend to have sickle-shaped red blood cells, which contribute to the rigidity of erythrocytes, resulting in a higher chance of vaso-occlusion, chronic anemia, hemolysis, and vasculopathy [1]. Globally, SCD is estimated to affect 305,800 newborns in 2010 and is predicted to affect 404,200 newborns in 2050 [3]. Most patients with SCD can be found across sub-Saharan Africa, where 230,000 newborns are affected every year, representing as much as 80% of the global total of SCD cases [1].

Given the chronic and multisystemic nature of SCD, its complications can manifest in multiple ways. These have been reported to include ocular problems resulting from vaso-occlusion of the conjunctiva, retina,

* Corresponding author. Department of Surgery, Division of Ophthalmology, King Abdulaziz Medical City, Jeddah, 21423, Saudi Arabia.

E-mail address: dr-a-saleh@hotmail.com (A.S. Alqahtani).

<https://doi.org/10.1016/j.amsu.2022.103999>

Received 26 April 2022; Received in revised form 10 June 2022; Accepted 12 June 2022

Available online 21 June 2022

2049-0801/© 2022 The Authors. Published by Elsevier Ltd on behalf of IJS Publishing Group Ltd. This is an open access article under the CC BY-NC-ND license (<http://creativecommons.org/licenses/by-nc-nd/4.0/>).

Abbreviations

SCD	sickle cell disease
OCT	optical coherence tomography
PSR	proliferative sickle cell retinopathy
NPSR	non-proliferative sickle cell retinopathy

choroid, and/or iris. The most prevalent among these is sickle cell retinopathy, wherein sickle vasculopathy affects the retinal vasculature [4]. It can be either proliferative sickle cell retinopathy (PSR) or non-proliferative sickle cell retinopathy (NPSR) [5]. The clinical presentation of sickle cell retinopathy is usually asymptomatic until complications, such as retinal detachment or vitreous hemorrhage, emerge [6]. For this reason, routine ophthalmology screening is carried out among children with SCD to detect proliferative changes and address their possible long-term consequences [4].

In Saudi Arabia, a study published in 2007 estimated a prevalence of 0.26% of SCD and 4.20% for SCD traits among 488,315 individuals who took part in the National Premarital Screening Program [7]. Another study employed retinal examination with fluorescein angiography to investigate the prevalence of eye complications in Saudi Arabia in relation to sickle cell disease [8]. Their results revealed that retinal vascular changes are a common occurrence among Saudi patients, independent of their haplotype. Interestingly, the risk associated with PSR was observed to be significantly higher among patients from the southwestern region as an implication of an abnormal vascular border [8]. In Jeddah, a populated city in the western region of Saudi Arabia, the prevalence of SCD was identified to be 0.04% and 3.46% for SCD trait [7]. This study aimed to determine the prevalence of eye complications among patients with SCD in Jeddah, Saudi Arabia. To the author's knowledge, this is the first study to look at the incidence of SCD-related eye complications at an administrative regional level, that is, Jeddah.

2. Methods

2.1. Study design

This study was carried out according to a cross-sectional approach in accordance with the STROCSS 2021 guidelines [9] to assess the incidence of ocular complications among patients with SCD in a particular hospital King Abdulaziz Medical City in Jeddah, Saudi Arabia. The inclusion criteria were as follows: all patients with major sickle cell hemoglobinopathies as diagnosed by a certified hematologist, from all age groups over the period 2018–2020 were enrolled in this study. Patients who were not able to undergo imaging examinations for various reasons were excluded. A total of 9 patients were eligible for inclusion in the study. To maintain patient privacy, each study participant was assigned a serial number instead of a medical record number.

2.2. Data collection

Most of the patients' data were sourced from their electronic medical files through BESTCare using a data collection sheet. The variables included in the sheet were devised from related published literature, as well as from discussions among experts. These included patient serial number, sex, age, diagnosis, ophthalmic assessment results, and presence of comorbidities. All patients were asked to attend the ophthalmology clinic to undergo imaging tests.

2.3. Ophthalmic assessment

Ophthalmic assessments focused on visual acuity, in-clinic dilated

fundus examination, optical coherence tomography (OCT) angiography, macular OCT scan, and fundus photography. Visual acuity was assessed using the tumbling E chart, while the in-clinic dilated fundus examination involved retinal examination with the aid of mydriatic eye drops. Imaging results were interpreted by a certified ophthalmology consultant specializing in retinal diseases with thirteen years of clinical experience.

2.4. Ethical standards

Informed consent was obtained from the patients in accordance with the basic principles of the Declaration of Helsinki. Access to patient data was limited by the authors of this study. Approval from the Institutional Review Board of King Abdullah International Medical Research Center, Riyadh, Saudi Arabia was accomplished prior to the conduct of the study, with Memorandum Reference No. IRB/0453/22.

2.5. Data management and analysis

Data were analyzed using the Statistical Package for the Social Sciences version 23 (IBM Corp., Armonk, NY). Descriptive statistics were used, and normally distributed variables were presented as means and standard deviations.

3. Results

The study variables and their counts are summarized in Table 1.

One of the patients exhibited abnormal findings on OCT angiography. Retinal perifoveal ischemia was observed in the patient's right eye, despite having a normal macular thickness. No abnormalities were observed in the patient's left eye. Visual acuity was 6/30 for the right eye and 6/21 for the left eye. Figs. 1 and 2 show the imaging results.

4. Discussion

In this study, we acquired data from nine patients with SCD to assess the incidence of eye complications. Five patients revealed no signs of ocular impairment based on their visual acuity. One of the patients demonstrated signs of retinal perifoveal ischemia in the right eye even when it had normal macular thickness at the time of observation.

The pathophysiology of SCD has been well studied and dissected. The organs most commonly involved are kidneys, lungs, liver, bones, and

Table 1
Characteristics of the patients.

Variable	N	Min	Max	Mean	SD
Age	9	17	50	24.78	10.9
Sex	Male	4		44.4	
	Female	5		55.6	
Diagnosis	Sickle cell disease	8		88.9	
	Sickle cell trait	1		11.1	
In-clinic dilated fundus exam	Normal Findings	8		88.9	
	Patient did not undergo examination	1		11.1	
	Abnormal Findings	1		11.1	
OCT angiography	Normal Findings	8		88.9	
	Abnormal Findings	1		11.1	
OCT macula	Normal Findings	9		100.0	
Fundus photography	Normal Findings	9		100.0	
Hypertension	No	29		100.0	
Diabetes mellitus	Type 2	1		11.1	
	Type 1	1		11.1	
	No	7		77.8	

OCT, optical coherence tomography; Min, minimum; Max, maximum; SD, standard deviation.

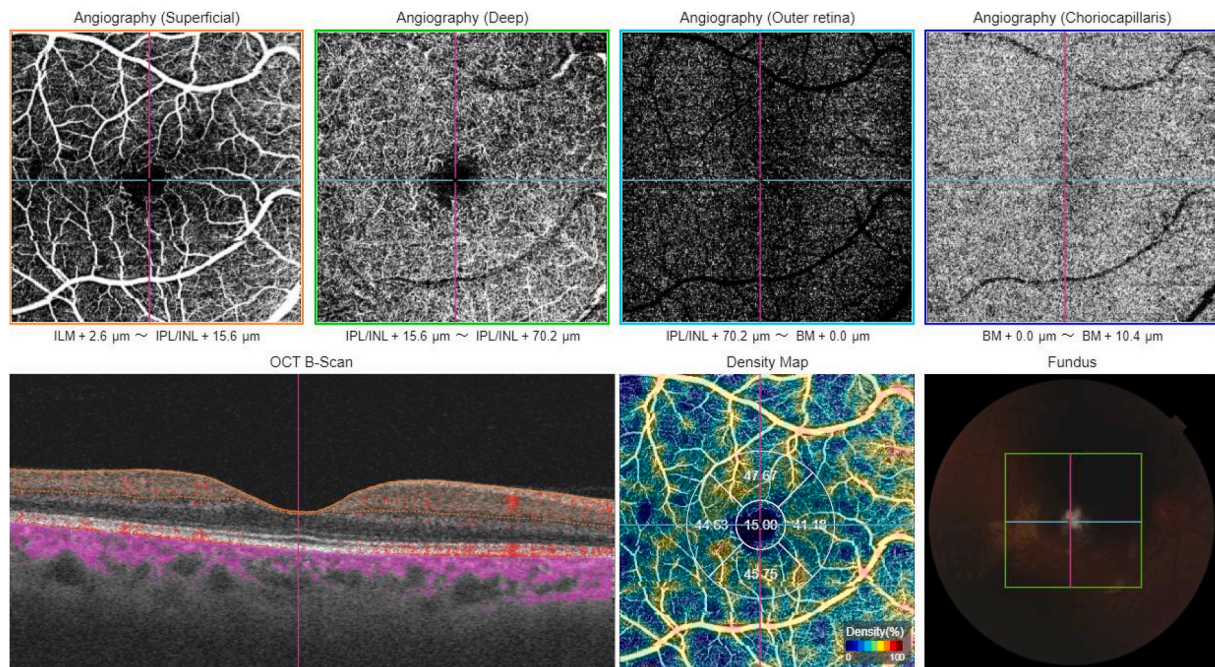


Fig. 1. OCT angiography report of the right eye for the patient with retinal abnormalities. Abbreviations: OCT, optical coherence tomography.

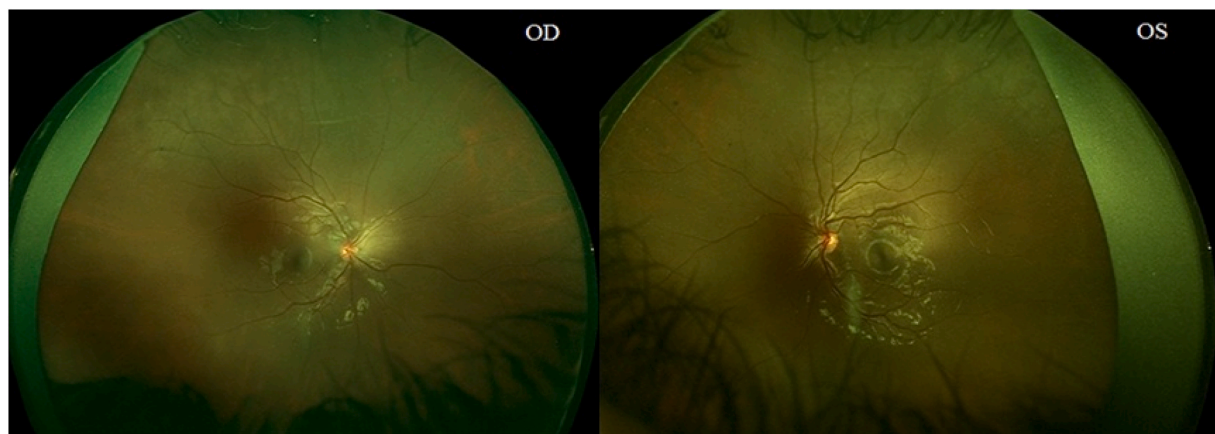


Fig. 2. Wide-angle retinal photography of the patient with retinal abnormalities. Abbreviations: OD, right eye; OS, left eye.

skin [10]. However, ocular complications attributed to vaso-occlusions may also occur during disease progression [10]. In a 2019 study conducted on the general population in the Eastern region of Saudi Arabia, the majority (57.3%) of participants were not aware of ocular complications arising from SCD [11]. This is important as the Eastern region exhibited a significantly higher prevalence of SCD (0.87%) and SCD traits (10.74%) than the other regions [7]. Meanwhile, a trial in Jeddah reported a 0.04% prevalence of SCD and a 3.46% prevalence of SCD traits among the participants [7]. This study sought to estimate the incidence of eye complications among patients with SCD in Jeddah, Saudi Arabia.

A study carried out on approximately 1000 patients with SS observed a higher incidence of PSR among patients from the older age group (30 years old and above), although the difference was not statistically significant [12]. Another study observed the same phenomenon; most SS cases were seen in the group of individuals aged 25–39 years of either sex, and the majority of SC incidences were seen in men aged 15–24 years and women aged 20–39 years, although this did not reach statistical significance [13]. The probable reason for this is that age may be reflective of the duration of vaso-occlusion and the consequential

accumulation of organ damage [12].

The sex ratio observed in our study was 1.25:1 (female-to-male). This is consistent with a study conducted in Jordan in which the sample population had a female-to-male ratio of 1.5:1 [14] and another study that had a female-to-male ratio of 2.38:1 [15]. However, it is known that no sex bias exists for SCD or SCD traits and that these observations of sex ratio biases may be attributed to probable sampling biases and small sample sizes.

The majority (88.9%) of the sample population was diagnosed with sickle cell disease. In terms of comorbidities, all patients were non-hypertensive; one had type 1 diabetes, another had type 2 diabetes, and the rest were non-diabetic. A study carried out in 2007 identified an association between pulmonary hypertension and retinopathy [16]. Lim et al. (2021) also found that hypertension and diabetes are risk factors associated with retinal thinning [17].

Five had normal visual acuity (6/6), two had slight impairments of up to 6/12 in at least one eye, and the remaining two patients had moderate visual acuity impairment in at least one eye (6/30) (Supplementary Table 1). Loss of vision has been shown to have a strong association with PSR in a study conducted in Jamaica, with a higher

incidence of loss of vision among individuals with PSR than those with NPSR [18]. In Saudi Arabia, it was found that peripheral vascular changes were frequently detected by fluorescent angiography among 61 subjects with SS disease and 10 subjects with heterozygous S beta-thalassemia [19]. Changes occurred regardless of the halotype, and were similar to what had been reported in Jamaica [19].

Among the sample population, only one patient exhibited abnormal findings on OCT angiography. Retinal ischemia occurs in patients with SCD as a result of the sickling of red blood cells and eventual vaso-occlusion of retinal blood vessels [20]. Retinal ischemia can progress to vitreous hemorrhage and retinal detachment [20]. A review by Do and Rodger (2017) stated that retinal ischemia can occur in patients without any visual symptoms [21]. This was also reported by Murthy in 2011 [20], thus suggesting that ischemia is easily overseen during a routine clinical examination, thereby implying the need for more detailed imaging techniques, such as wide-field angiography, to assess such changes among asymptomatic patients [20]. Overall, this study's results suggest that routine ophthalmological screening may not be able to detect and/or monitor the progression of ocular complications associated with SCD, and that supplementary investigation through detailed imaging techniques such as OCT angiography may be necessary.

This study has several limitations. First, the sample size for this study was small. Initially, patient data were collected from 29 patients, but since only nine underwent imaging tests due to inability of other patients to do follow ups (e.g., busy schedule, living in a different city), only those nine were considered as the sample population. Second, fluorescent angiography, an imaging technique known to be more sensitive in detecting vascular changes in the eye, was not carried out. This could have resulted in a probable underestimation of the incidence of eye complications in this study. Finally, although this study used wide-angle retinal photography, it was limited to patients with retinal abnormalities. A previously published study demonstrated that wide-field images can detect vascular changes that can be overseen using standard-field photography [22]. Despite these limitations, the authors believe that the strength of this study lies in the fact that the data on the association between ocular complications and SCD remains relatively scarce, particularly in the Kingdom of Saudi Arabia. The findings of this study suggest that routine ophthalmological screening may not be able to distinguish macular or retinal abnormalities unless supplemented by detailed imaging techniques such as OCT angiography. Additionally, this study may inspire further discussions on the practice of regular ophthalmology screening to monitor visual symptoms in patients with progressive SCD.

5. Conclusion

SCD-associated ocular complications can easily be overseen during routine clinical examination and in asymptomatic patients, highlighting the utility of more intensive ophthalmology checkups and more advanced imaging techniques to monitor the progression of such complications. Further work needs to be done to ascertain the cost-effectiveness of routine ophthalmological screening in the detection and monitoring of SCD-associated ocular complications. Recommendations for future research include focusing work on a larger sample size, taking a deeper look into the risk factors of eye complications in relation to SCD, and using advanced imaging techniques, such as OCT angiography, to detect meaningful vascular changes in the eye.

Ethical approval

Approval from the Institutional Review Board of King Abdullah International Medical Research Center, Riyadh, Saudi Arabia was accomplished prior to the conduct of the study, with Memorandum Reference No. IRB/0453/22.

Sources of funding

There are no sources of funding to declare.

Author contribution

Eid Ayed Almasoudi and Sultan Fahad Maghlah contributed in all stages of the study. Abubakr Salem Alzawaihri participated in proposal and manuscript writing in addition to data collection. Abdullah Omar Aljuwaybiri contributed in proposal and manuscript writing. Abdullah Saleh Alqahtani contributed in interpretation of the data, revising the manuscript for important intellectual content. All authors read and approved the final version of the manuscript.

Consent

Informed consent was obtained from the patients who presented to the clinic for imaging tests in accordance with the basic principles of the Declaration of Helsinki.

Registration of research studies

1. Name of the registry: Research Registry <http://www.researchregistry.com>
2. Unique Identifying number or registration ID: researchregistry7845
3. Hyperlink to your specific registration (must be publicly accessible and will be checked): <https://researchregistry.knack.com/research-registry#home/registrationdetails/626809b1cadd9e001ec91e62/>

Guarantor

Abdullah Saleh Alqahtani.

Department of Surgery, Division of Ophthalmology, Ministry of the National Guard Health Affairs, King Abdulaziz Medical City, King Saud bin Abdulaziz University for Health Sciences, King Abdullah International Medical Research Center, Jeddah, Saudi Arabia 22384 Email: dr-a-saleh@hotmail.com.

Provenance and peer review

Not commissioned, externally peer reviewed.

Declaration of competing interest

There are no conflicts of interest to declare.

Acknowledgments

This research has received no external funding.

Appendix A. Supplementary data

Supplementary data to this article can be found online at <https://doi.org/10.1016/j.amsu.2022.103999>.

References

- [1] D.C. Rees, T.N. Williams, M.T. Gladwin, Sick cell disease, *Lancet* 376 (9757) (2010) 2018–2031. [https://doi.org/10.1016/S0140-6736\(10\)61029-X](https://doi.org/10.1016/S0140-6736(10)61029-X).
- [2] A.A. Galadanci, M.R. DeBaum, N.A. Galadanci, Neurologic complications in children under five years with sickle cell disease, *Neurosci. Lett.* 706 (2019) 201–206, <https://doi.org/10.1016/j.neulet.2019.04.030>.
- [3] F.B. Piel, S.I. Hay, S. Gupta, D.J. Weatherall, T.N. Williams, Global burden of sickle cell anaemia in children under five, 2010–2050: modelling based on demographics, excess mortality, and interventions, *PLoS Med.* 10 (7) (2013), e1001484, <https://doi.org/10.1371/journal.pmed.1001484>.

- [4] D.A. Pahl, N.S. Green, M. Bhatia, M.T. Lee, J.S. Chang, M. Licursi, C. Briamonte, E. Smilow, R.W.S. Chen, Optical coherence tomography angiography and ultra-widefield fluorescein angiography for early detection of adolescent sickle retinopathy, *Am. J. Ophthalmol.* 183 (2017) 91–98, <https://doi.org/10.1016/j.ajo.2017.08.010>.
- [5] T. Hassan, M. Badr, D. Hanna, M. Arafa, A. Elhewala, S. Dabour, S. Shehata, D. A. Rahman, Retinopathy in Egyptian patients with sickle cell disease: a cross-sectional study, *Medicine (Baltim.)* 100 (51) (2021), e28355, <https://doi.org/10.1097/md.00000000000028355>.
- [6] S.M. Downes, I.R. Hambleton, E.L. Chuang, N. Lois, G.R. Serjeant, A.C. Bird, Incidence and natural history of proliferative sickle cell retinopathy: observations from a cohort study, *Ophthalmology* 112 (11) (2005) 1869–1875, <https://doi.org/10.1016/j.ophtha.2005.05.026>.
- [7] N.A. Alhamdan, Y.Y. Almazrou, F.M. Alswaidi, A.J. Choudhry, Premarital screening for thalassemia and sickle cell disease in Saudi Arabia, *Genet. Med.* 9 (6) (2007) 372–377, <https://doi.org/10.1097/gim.0b013e318065a9e8>.
- [8] S. Al-Hazzaa, A.C. Bird, A. Kulozik, B.E. Serjeant, G.R. Serjeant, P. Thomas, A. Padmos, Ocular findings in Saudi Arabian patients with sickle cell disease, *Br. J. Ophthalmol.* 79 (5) (1995) 457–461, <https://doi.org/10.1136/bjo.79.5.457>.
- [9] G. Mathew, R. Agha, STROCSS 2021: strengthening the reporting of cohort, cross-sectional and case-control studies in surgery, *Int. J. Surg.* 96 (2021), 106165, <https://doi.org/10.1016/j.ijsu.2021.106165>.
- [10] M.E.A. Abdalla Elsayed, M. Mura, H. Al Dhibi, S. Schellini, R. Malik, I. Kozak, P. Schatz, Sickle cell retinopathy. A focused review, *Graefes Arch. Clin. Exp. Ophthalmol.* 257 (7) (2019) 1353–1364, <https://doi.org/10.1007/s00417-019-04294-2>.
- [11] A.M. Alshehri, K.B. Feroze, M.K. Amir, Awareness of ocular manifestations, complications, and treatment of sickle cell disease in the eastern province of Saudi Arabia: a cross-sectional study, *Middle East Afr. J. Ophthalmol.* 26 (2) (2019) 89–94, https://doi.org/10.4103/meajo.MEAJO_200_18.
- [12] R.J. Hayes, P.I. Condon, G.R. Serjeant, Haematological factors associated with proliferative retinopathy in homozygous sickle cell disease, *Br. J. Ophthalmol.* 65 (1) (1981) 29–35, <https://doi.org/10.1136/bjo.65.1.29>.
- [13] P.D. Fox, D.T. Dunn, J.S. Morris, G.R. Serjeant, Risk factors for proliferative sickle retinopathy, *Br. J. Ophthalmol.* 74 (3) (1990) 172–176, <https://doi.org/10.1136/bjo.74.3.172>.
- [14] N.E. Abu-Yaghi, A.M. AlNawaiseh, I.M. Khourshid, T.J. AlRawashdeh, M.M. A. Rawashdeh, A.M. Zghoul, A.N. Shafagoj, Y.A. Alomairi, S.M. Muhsen, S. S. AlRyalat, Central macular thickness in patients with sickle cell disease and no signs of retinopathy: a cross-sectional study of Jordanian patients, *J. Int. Med. Res.* 49 (4) (2021), 300060520977387, <https://doi.org/10.1177/0300060520977387>.
- [15] E.Z. Oltra, C.C. Chow, T. Wubben, J.I. Lim, F.Y. Chau, H.E. Moss, Cross-sectional analysis of neurocognitive function, retinopathy, and retinal thinning by spectral-domain optical coherence tomography in sickle cell patients, *Middle East Afr. J. Ophthalmol.* 23 (1) (2016) 79–83, <https://doi.org/10.4103/0974-9233.150632>.
- [16] F. Akgül, F. Yalçın, E. Seyfeli, E. Uçar, S. Karazincir, A. Balci, E. Gali, Pulmonary hypertension in sickle-cell disease: comorbidities and echocardiographic findings, *Acta Haematol.* 118 (1) (2007) 53–60, <https://doi.org/10.1159/000102588>.
- [17] J.I. Lim, M. Niec, J. Sun, D. Cao, Longitudinal assessment of retinal thinning in adults with and without sickle cell retinopathy using spectral-domain optical coherence tomography, *JAMA Ophthalmol* 139 (3) (2021) 330–337, <https://doi.org/10.1001/jamaophthalmol.2020.6525>.
- [18] B.J. Moriarty, R.W. Acheson, P.I. Condon, G.R. Serjeant, Patterns of visual loss in untreated sickle cell retinopathy, *Eye* 2 (Pt 3) (1988) 330–335, <https://doi.org/10.1038/eye.1988.62>.
- [19] S. al-Hazzaa, A.C. Bird, A. Kulozik, B.E. Serjeant, G.R. Serjeant, P. Thomas, et al., Ocular findings in Saudi Arabian patients with sickle cell disease, *Br. J. Ophthalmol.* 79 (1995) 457–461, <https://doi.org/10.1136/bjo.79.5.457>.
- [20] R.K. Murthy, S. Grover, K.V. Chalam, Temporal macular thinning on spectral-domain optical coherence tomography in proliferative sickle cell retinopathy, *Arch. Ophthalmol.* 129 (2) (2011) 247–249, <https://doi.org/10.1001/archophthalmol.2010.357>.
- [21] B.K. Do, D.C. Rodger, Sickle cell disease and the eye, *Curr. Opin. Ophthalmol.* 28 (6) (2017) 623–628, <https://doi.org/10.1097/icu.0000000000000423>.
- [22] M. Cho, S. Kiss, Detection and monitoring of sickle cell retinopathy using ultra wide-field color photography and fluorescein angiography, *Retina* 31 (4) (2011) 738–747, <https://doi.org/10.1097/IAE.0b013e3181f049ec>.