

Case Report

Severe adverse effects of 5-fluorouracil in S-1 were lessened by haemodialysis due to elimination of the drug

Kazunori Inoue, Yasuyuki Nagasawa, Ryohei Yamamoto, Hiroki Omori, Tomonori Kimura, Kodo Tomida, Yoshiyuki Furumatsu, Enyu Imai, Yoshitaka Isaka and Hiromi Rakugi

Department of Geriatric Medicine and Nephrology, Osaka University Graduate School of Medicine, Osaka, Japan

Abstract

S-1 and cisplatin are used as one of the first-line chemotherapies for gastric cancer in Japan. The plasma concentration of 5-fluorouracil (5-FU) is increased in patients with renal dysfunction because gimeracil in S-1 inhibits the degradation of 5-FU and about 50% of gimeracil is excreted in the urine. We describe a 35-year-old man with acute kidney injury while taking S-1 and cisplatin for advanced gastric cancer and who presented severe adverse effects of 5-FU. This case report describes the evolution of the plasma concentrations of 5-FU with haemodialysis along with a decrease in the adverse drug effects.

Keywords: 5-fluorouracil; gimeracil; haemodialysis; S-1

Background

Gastric cancer is the commonest malignancy in Japan. Phase II studies of S-1 have noted responses of 44–54% in patients with gastric cancer [1–3] and S-1 and cisplatin are used as one of the first-line treatments for this type of cancer in the country [4].

S-1 is a novel 5-fluorouracil (5-FU) derivative, composed of tegafur, gimeracil and oteracil potassium. Tegafur is slowly converted to 5-FU *in vivo*, mainly by the liver microsomal P-450 drug-metabolizing enzyme system. 5-FU is degraded by hepatic dihydropyrimidine dehydrogenase (DPD), converted to F- β -alanine, and excreted in the urine [5]. 5-Chloro-2,4-dihydropyridine (CDHP) is a reversible competitive inhibitor of DPD whereby 5-FU can be retained for longer at high blood concentrations [6]. The plasma concentration of 5-FU is increased in the patient with renal dysfunction because ~50% of CDHP is excreted in the urine. This case report describes a decrease of the adverse effects of 5-FU by haemodialysis (HD) along with providing plasma concentrations of 5-FU and gimeracil.

Correspondence and offprint requests to: Kazunori Inoue, Department of Nephrology, Osaka University Graduate School of Medicine, 2-2 Yamadaoka (B6), Suita-city, Osaka 565-0871, Japan. Tel: +81-6-6879-3632; Fax: +81-6-6879-3639; E-mail: kznri@kid.med.osaka-u.ac.jp

Case report

A 35-year-old man suffered from immunoglobulin-A nephropathy 2 years before admission and was treated with steroid therapy. He complained of epigastric pain about 9 months before. A mass on the greater curvature of his stomach was found by gastroscopy and gastric cancer (signet cells) was diagnosed by biopsy. The abdominal CT scan showed that there were tumours in the abdominal cavity with enlarged para-aortic lymph nodes. His body surface area was approximately 1.57 m² as determined from the DuBois formula. He started taking S-1 50 mg, twice daily for 3 consecutive weeks, followed by a 2-week rest period 8 months ago. He also started intravenous cisplatin every 5 weeks and took dipyridamole, lansoprazole, granisetron hydrochloride and naproxen orally every day. He received six cycles of chemotherapy and showed a partial clinical remission.

He received 60 mg cisplatin for the last time about 1 month before his admission, and his serum creatinine increased slightly (from 95.47 to 114.92 μ mol/l) 1 week after receiving cisplatin. He continued to report appetite loss and went to hospital 1 week before his admission. He also took a blood examination after the consultation and his serum creatinine had increased to 683.33 μ mol/l. However, his doctor did not know the result until after his admission. He continued to take S-1 and the other drugs for about 1 week from the start of the renal insufficiency. His appetite loss and general fatigue were aggravated and he consulted the emergency room in our hospital.

He was drowsy and on the Glasgow Coma Scale his score was 13 of 15. His blood pressure was 133/82 mmHg and his heart rate 87 beats/min. He complained of a slight stomachache, and slight tenderness was found on physical examination. There was no free air or niveau on the abdominal X-ray. The serum creatinine and blood urea nitrogen were elevated to 1919.16 μ mol/l and 32.49 mmol/l, respectively. The patient was anuric. A nephrological consultation was requested; the patient appeared to be dehydrated and there were no signs of hydronephrosis on abdominal ultrasonography. His acute kidney injury was ascribed to a combination of drug-induced kidney injury and dehydration.

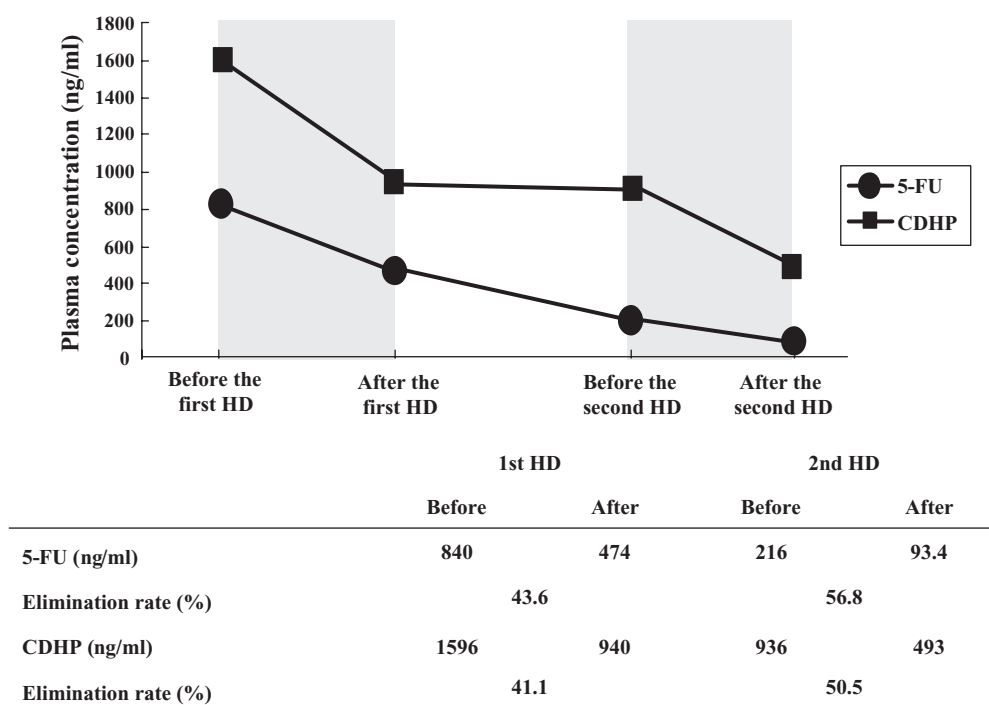


Fig. 1. The concentration of 5-FU and CDHP before and after the haemodialysis (HD). Haemodialysis was performed on the second and the third day after his admission in the shaded region. Elimination rate: [(plasma concentration before HD) – (plasma concentration after HD)]/(plasma concentration before HD) × 100 (%).

All drugs were withdrawn and HD was performed for 3–4 h with an APS-11MD dialyzer (Asahi Kasei Medical Co. Ltd) and with a blood flow between 120 and 150 ml/min on the second, third, fifth and sixth day of hospitalization; the plasma concentrations of 5-FU and CDHP were measured.

On the fifth day his urine output gradually increased and the serum creatinine decreased to the previous value (serum creatinine decreased to 85.75 $\mu\text{mol/l}$ on the eighth day). The plasma concentration of 5-FU decreased from 840 ng/ml before the first HD to 93.4 ng/ml after the second HD (Figure 1). His HD had continued till the sixth day.

However, on the fourth day, diarrhoea and stomatitis appeared till the sixth day. He was diagnosed with pancytopenia (Figure 2). Granulocyte colony stimulating factor (G-CSF) and antibiotics were administered, and on Day 7 the neutrophil count decreased to approximately $50/\text{mm}^3$. Finally, the neutrophils increased on Day 18 and the fever decreased, together with improvement of the fever, the stomatitis and diarrhoea. The patient could be discharged on Day 26 after admission.

Discussion

This patient showed severe adverse effects (pancytopenia, diarrhoea and stomatitis) because of taking S-1 in the presence of acute kidney injury. Usually S-1 should not be prescribed when the patient's creatinine clearance is <30 ml/min, because of adverse reactions due to accumulation of 5-FU in the body. In Japan, at least two patients with chronic

kidney disease taking S-1 died from sepsis due to granulocytopenia because of this adverse effect.

Acute kidney injury is known to occur with S-1, but its mechanism is unknown and the incidence is $<0.1\%$ according to the drug surveillance reports. It was less likely that kidney injury by cisplatin lasted for 1 month. We thought that this patient's acute kidney injury could be ascribed to dehydration and the prescribed drugs, probably due to naproxen (NSAIDs) among others.

The patient's blood concentrations measured by liquid chromatography/mass spectrometry of 5-FU and CDHP, 24 h after taking 50 mg of S-1 were 840.0 ng/ml and 1596.0 ng/ml, respectively (Figure 1). C_{max} levels of 5-FU and CDHP were reported to be 128.5 ng/ml and 284.6 ng/ml, respectively, in individuals without renal insufficiency [7]. When higher doses of 5-FU were taken, the number of neutrophils reaching the minimum nadir was decreased [8]. Moreover, the elimination rates of 5-FU and CDHP by a 4-h HD session were 71.0–87.6% and 53.1–63.4%, respectively [9,10]. Our patient's first and second HD were performed for only 3 h because we wanted to avoid dialysis disequilibrium syndrome. We speculate that the elimination rate of 5-FU and CDHP by HD were only ~ 50 and 45%, because of this short duration of HD. However, the plasma concentration of 5-FU decreased from 840 to 93.4 ng/ml after his second HD, which is under the C_{max} after taking a normal dose of S-1.

The concentration of 5-FU was decreased from the end of the first HD to the start of the second HD while the concentration of CDHP did not decrease. The reason is that CDHP is a competitive inhibitor and that 5-FU was degraded

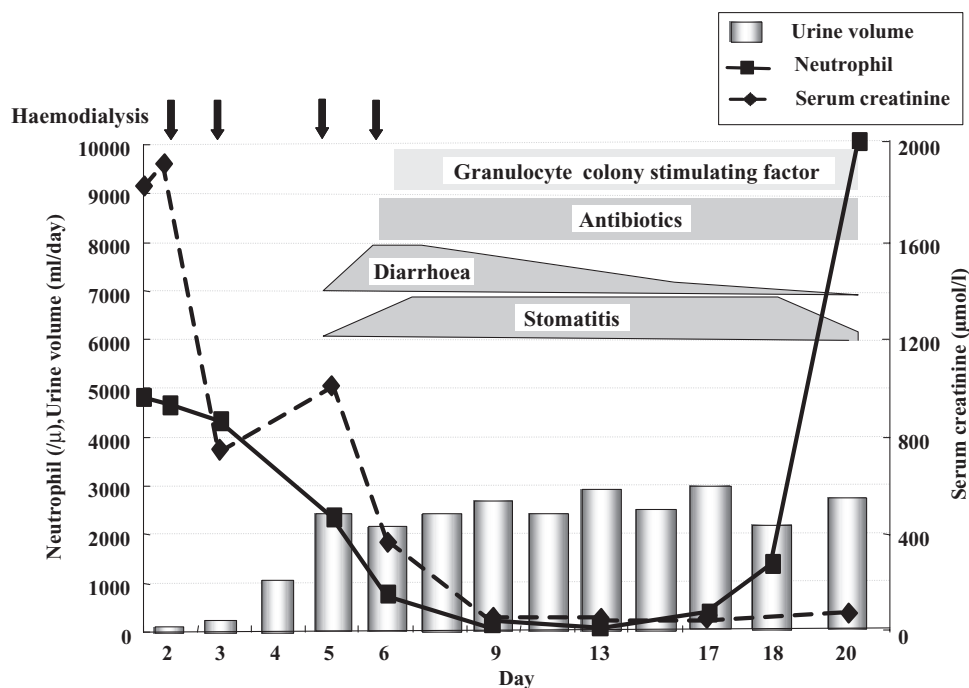


Fig. 2. Changes in serum creatinine, neutrophil and urine volume in the patient's clinical course.

by other pathways than the hepatic dihydropyrimidine dehydrogenase.

Probably the concentration of 5-FU would have decreased gradually only by stopping S-1. But it was thought that we could decrease the risk of the adverse effects (especially shorten the period of bone marrow suppression) and enhance the recovery without sepsis by eliminating 5-FU by HD.

In conclusion, when high plasma concentrations of 5-FU are suspected, the plasma levels of 5-FU and CDHP should be measured and the indication of HD for the removal of 5-FU and CDHP to avoid severe myelosuppression should be strongly considered.

Acknowledgement. We would like to thank TAIHO Pharmaceutical Co., Ltd for measuring the plasma concentrations of 5-FU and CDHP.

Conflict of interest statement. None declared.

References

1. Sugimachi K, Maehara Y, Horikoshi N *et al.* An early phase II study of oral S-1, a newly developed 5-fluorouracil derivative for advanced and recurrent gastrointestinal cancers. *Oncology* 1999; 57: 202–210
2. Sakata Y, Ohtsu A, Horikoshi N *et al.* Late phase II study of novel oral fluoropyrimidine anticancer drug S-1 (1M tegafur-0.4M gimestat-1M otastat potassium) in advanced gastric cancer patients. *Eur J Cancer* 1998; 34: 1715–20
3. Koizumi W, Kurihara M, Nakano S *et al.* Phase II study of S-1, a novel oral derivative of 5-fluorouracil, in advanced gastric cancer. *Oncology* 2000; 58: 191–197
4. Koizumi Y, Narahara H, Hara T *et al.* S1 plus cisplatin versus S-1 alone for first-line treatment of advanced gastric cancer (SPIRITS trial): a phase trial. *Lancet Oncol* 2008; 9: 215–221
5. Fujii S, Shimamoto Y, Ohshimo H *et al.* Effect of the plasma concentration of 5-furuorouracil and the duration of continuous venous infusion of 5-furuorouracil with an inhibitor of 5-furuorouracil degradation on Yoshida sarcoma in rats. *Jpn J Cancer Res* 1989; 80: 167–172
6. Shirasaka T, Nakano K, Takechi T *et al.* Enhancement of the antitumor activity of 1M tegafur-0.4M 5-chloro-2,4-dihydropyrimidine-1M potassium oxonate (S-1) against human colon carcinoma orthotopically implanted into nude rats. *Cancer Res* 1996; 56: 2062–2606
7. Hirata K, Horikoshi N, Aiba K *et al.* Pharmacokinetic study of S-1, a novel oral fluorouracil antitumor drug. *Clin Cancer Res* 1999; 5: 2000–2005
8. Jean L, Mary Q, Abdel S *et al.* Pharmacokinetics and pharmacodynamic effects of 5-fluorouracil given as a one-hour intravenous infusion. *Cancer Chemother Pharmacol* 2001; 47: 117–125
9. Tanaka T, Fujita S, Tanaka T *et al.* TS-1 treatment for progressive gastric cancer in patient on chronic dialysis—assessment of dosage regimen by monitoring blood concentrations of therapeutic drugs (TDM). *Jpn J Cancer Chemother* 2005; 32: 841–845
10. Tominaga K, Higuchi K, Okazaki H *et al.* Safety and efficacy of S-1, a novel oral fluorouracil antitumor drug, for a chronic renal failure patient maintained on hemodialysis *Oncology* 2004; 66: 358–364

Received for publication: 8.11.08

Accepted in revised form: 24.11.08