

Laparoscopic approach to an incidentally found pelvic retroperitoneal liposarcoma

Case report and review

Vincenzo Dario Mandato, MD, PhD^{a,*}, Valentina Mastrofilippo, BSc^b, Loredana De Marco, MD^c, Lorenzo Aguzzoli, MD^b

Abstract

Rationale: Well-differentiated liposarcomas (WDLPS) are rare retroperitoneal tumors that can reach significant size as they can grow without constraints before becoming symptomatic. Laparotomic open radical tumor resection represents the most common surgical approach.

Patient concerns: A mass with “fat fluid level” was found in the right pelvis of an asymptomatic woman undergoing routine transvaginal ultrasound: the preoperative diagnosis was right mature ovarian teratoma.

Diagnosis: Postoperative histopathology confirmed the diagnosis of WDLPS.

Interventions: A radical laparoscopic excision of the retroperitoneal mass with bilateral salpingectomy was performed.

Outcomes: Patient is free of disease at 18 months after surgery.

Lesson: Despite computed tomography scan is the gold standard technique to identify WDLPS, such neoplasms can be misdiagnosed for mature ovarian teratomas. When a retroperitoneal mass is incidentally discovered during a surgery, an open core-needle biopsy is usually performed, and appropriate treatment planned only after complete staging and final pathology are available. Instead, when tumor margins are identified, resection of an incidentally diagnosed WDLPS would benefit from laparoscopic magnification that could improve distinguishing the disease from the surrounding tissues. Therefore, laparoscopy could represent a safe and effective technique to diagnose and treat retroperitoneal diseases.

Abbreviations: CT = computed tomography scan, DDLPS = high-grade dedifferentiated liposarcoma, DFS = disease-free survival, DWD = died with disease, FOD = free of disease, MRI = magnetic resonance image, OS = overall survival, WDLPS = well-differentiated liposarcoma.

Keywords: disease-free survival, laparoscopy, ovarian teratoma, radical resection, retroperitoneal liposarcoma

1. Introduction

Liposarcoma (also known as atypical lipomatous tumor^[1]) is the most common soft-tissue tumor. It is a rare malignant tumor of embryogenic mesodermal origin presenting in the following histologic variants: well-differentiated, myxoid, round cell, pleomorphic, and dedifferentiated^[2].

Rarely located in the gastrointestinal tract, liposarcomas can develop in the extremities or trunk, but it is the retroperitoneum the most common location,^[3] as they account for approximately 15% of all retroperitoneal sarcomas.^[4] The incidence of

retroperitoneal liposarcomas is 0.3 to 0.4 per 100,000 individuals.^[4] The 2 most common retroperitoneal types are well-differentiated (WDLPS) and high-grade dedifferentiated (DDLPS). These 2 variants share the molecular hallmark of MDM2 gene amplification which differentiates these from other retroperitoneal tumors.^[5]

Retroperitoneal liposarcomas have a higher incidence in the 6th and 7th decade, they present with symptoms that vary and may be nonspecific such as bleeding, weight loss, and abdominal pain.^[6] Usually, retroperitoneal liposarcomas reach large sizes as the retroperitoneal region offers large for them to grow asymptotically.^[5,7] We report a case of a retroperitoneal laparoscopically resected WDLPS along with a literature review of all the published retroperitoneal WDLPS cases in women.

2. Case report

A 60-year-old woman was referred for surgery with the diagnosis of right ovarian mature teratoma. The diagnosis of ovarian teratoma was made due to a “fat fluid level” noted on transvaginal ultrasound, and confirmed on computed tomography (CT) scan (Fig. 1). The patient was asymptomatic, tumor markers were in the normal range. The adnexa and the uterus appeared to be normal at laparoscopy, a 5-cm retroperitoneal capsulated solid mass was noted in the posterior sheet of the right

Editor: N/A.

The authors have no funding and conflicts of interest to disclose.

^a Unit of Obstetrics and Gynecology, ^b Unit of Surgical Gynecol Oncology, ^c Unit of Pathology, Azienda USL-IRCCS of Reggio Emilia, Risorgimento, Italy.

* Correspondence: Vincenzo Dario Mandato, Unit of Obstetrics and Gynecology, Azienda USL-IRCCS of Reggio Emilia, Viale Risorgimento n 80, Italy (e-mail: dariomandato@gmail.com).

Copyright © 2019 the Author(s). Published by Wolters Kluwer Health, Inc. This is an open access article distributed under the Creative Commons Attribution License 4.0 (CCBY), which permits unrestricted use, distribution, and reproduction in any medium, provided the original work is properly cited.

Medicine (2019) 98:15(e15184)

Received: 11 October 2018 / Received in final form: 3 March 2019 / Accepted: 15 March 2019

<http://dx.doi.org/10.1097/MD.00000000000015184>

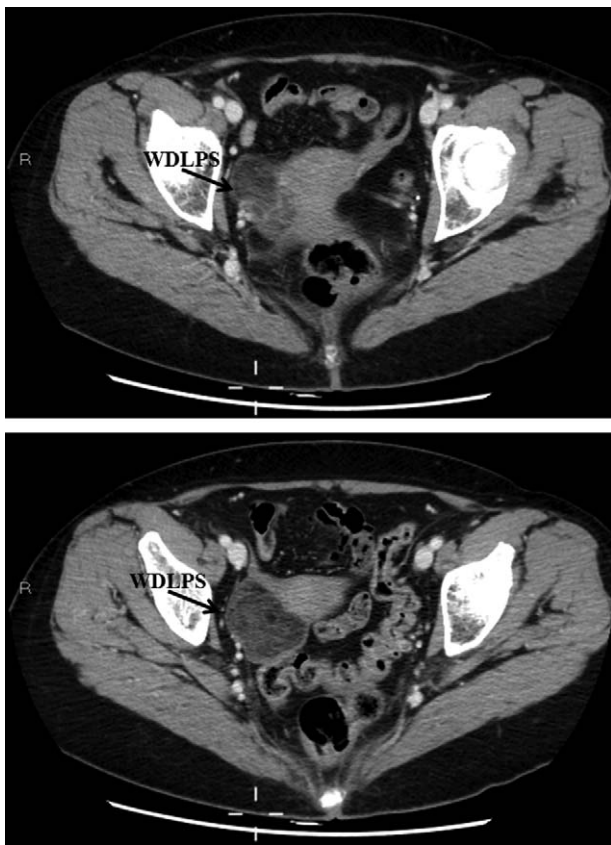


Figure 1. Computed tomography scan misdiagnosed a well-differentiated liposarcoma (WDLPS) as an ovarian mature teratoma because the well-capsulated homogeneous fatty components. WDLPS was located in the right pelvis close to the uterus corpus and cervix.

broad ligament (Fig. 2). The mass was radically resected and retrieved in a bag. Prophylactic bilateral salpingoophorectomy and endometrial biopsy were also performed. On histology, adipocyte proliferation with different maturation stages was noted, as well as spindle cells with hyperchromatic nuclei, inflammatory cells, and mast cells. The diagnosis of WDLPS (Fig. 3) was made. The patient's postoperative course was uneventful. Upon discharge, abdominal and pelvis CT scan as well as magnetic resonance image (MRI) were offered alternately every 6 months. Eighteen months after WDLPS resection the patient was disease free.

2.1. Ethical review

Ethical approval was not necessary for case report publication; and patient written informed consent was obtained to collect data and images for publication.

3. Review of literature

3.1. Systematic review of the literature

We reviewed the literature concerning on retroperitoneal WDLPS in women using PubMed until August 2018, using the following key words “well-differentiated liposarcoma,” “retroperitoneal well-differentiated liposarcoma,” “well-differentiated liposarcoma of retroperitoneum,” “atypical lipomatous tumor,” “retroperitoneal atypical lipomatous tumor,” “atypical lipoma-

tous tumor of retroperitoneum.” A total of 36 retroperitoneal WDLPS were found; in 4 cases, few data were reported, so 32 cases were included in the review.^[2,7–35]

3.2. Clinical features

Table 1 shows the main clinical features of all 32 retroperitoneal WDLPS.

Mean age at presentation was 54.2 years, SD \pm 13.8. Three out of 31 (9.7%) patients were pregnant at the time of diagnosis.

Most of retroperitoneal WDLPS occurred in both abdomen and pelvis, only in 1 case (3.2%) WDLPS was confined in the pelvis.^[27] The tumor size was available in 25/32 (78.1%) patients, ranging from 8 to 60 cm, with a mean size of 29.7 cm (SD \pm 13.3). In 2 cases, the weight of the tumor was reported, 2 kg^[8] and 18 kg,^[23] respectively. Symptoms were reported in 29/32 (90.6%) patients, consisting in abdominal distension 10/29 (34.5%), pain 8/29 (27.6%), mass 7/29 (24.1%), dyspnea 2/29 (6.9%), weight gain 2/29 (6.9%), weight loss 1/29 (3.4%), constipation 1/29 (3.4%), syncope 1/29 (3.4%), while 2/29 (6.9%) patients were asymptomatic. The most common surgical approach was laparotomy, as minimally invasive surgery was chosen in only 3 cases (9.4%).^[14,27,35] WDLPS was completely excised without multiorgan resection in 23/32 (71.9%) patients,^[2,8,9,11,12,14,16,20–23,25–32,34,35] in 9/32 (28.1%) patients required a more aggressive surgery.^[8,10,13,15–19,24,33] Postsurgical treatment was reported in 28/32 (87.5%) patients: 23/28 (82.1%) patients received no adjuvant therapy, 2/28 (7.1%) patients received chemotherapy,^[8,10] 2/28 (7.1%) patients received radiation therapy,^[12,13] and 1/28 (3.6%) patient received both chemo and radiotherapy.^[29]

3.3. Follow-up data

Information on recurrence was not available for 3/32 (9.4%) patients. In 22/32 (68.7%) patients, the disease did not recur, while 7/29 (24.1%) patients had 1 or more recurrences. Of note, 1/7 (14.3%) patient had 3 recurrences,^[33] 1/7 (14.3%) patient had 2 recurrences,^[8] the 1st recurrence was after 24 months and was treated by surgery and chemotherapy instead the 2nd recurrence was treated by surgery and radiotherapy, patient died of disease 84 months from the diagnosis. Notably, this patient had received adjuvant chemotherapy after 1st surgery.^[8] One patient of 7 (14.3%) had 1 recurrence that was treated with surgery and chemotherapy, she was FOD at 8 months from relapse.^[31] Four patients of 7 (57.1%) had 1 recurrence that was surgically treated, 1 patient recurred after 16 months,^[29] 1 after 20 months,^[2] 1 after 35 months,^[16] and 1 after 84 months.^[23] After surgery 3 patients remained FOD^[2,16,29] while we did not find follow-up information about 1 patient.^[23] Survival information were available for 27/32 (84.4%) patients, 26/27 (96.3%) patients were FOD and 1/27 (3.7%) patient died with disease (DWD) 84 months after diagnosis.^[8] Median survival (OS) was 24 months (ranging from 3 to 288 months) and the disease-free survival (DFS) was 22 months (ranging from 3 to 204 months). Among FOD patients, 16/26 (61.5%) had been treated with only tumor excision, 9/26 (34.6%) with tumor excision plus multiorgan resection and 1/26 (3.8%) patient with surgery plus adjuvant chemo and radiotherapy.^[29] Five of 26 (19.2%) FOD patients had 1 or more recurrences.^[2,16] In these patients, median DFS was 20 months, median OS was 28 months (ranging from 11 to 288 months). One of 27 (3.7%) patients died after 2 recurrences.^[8]

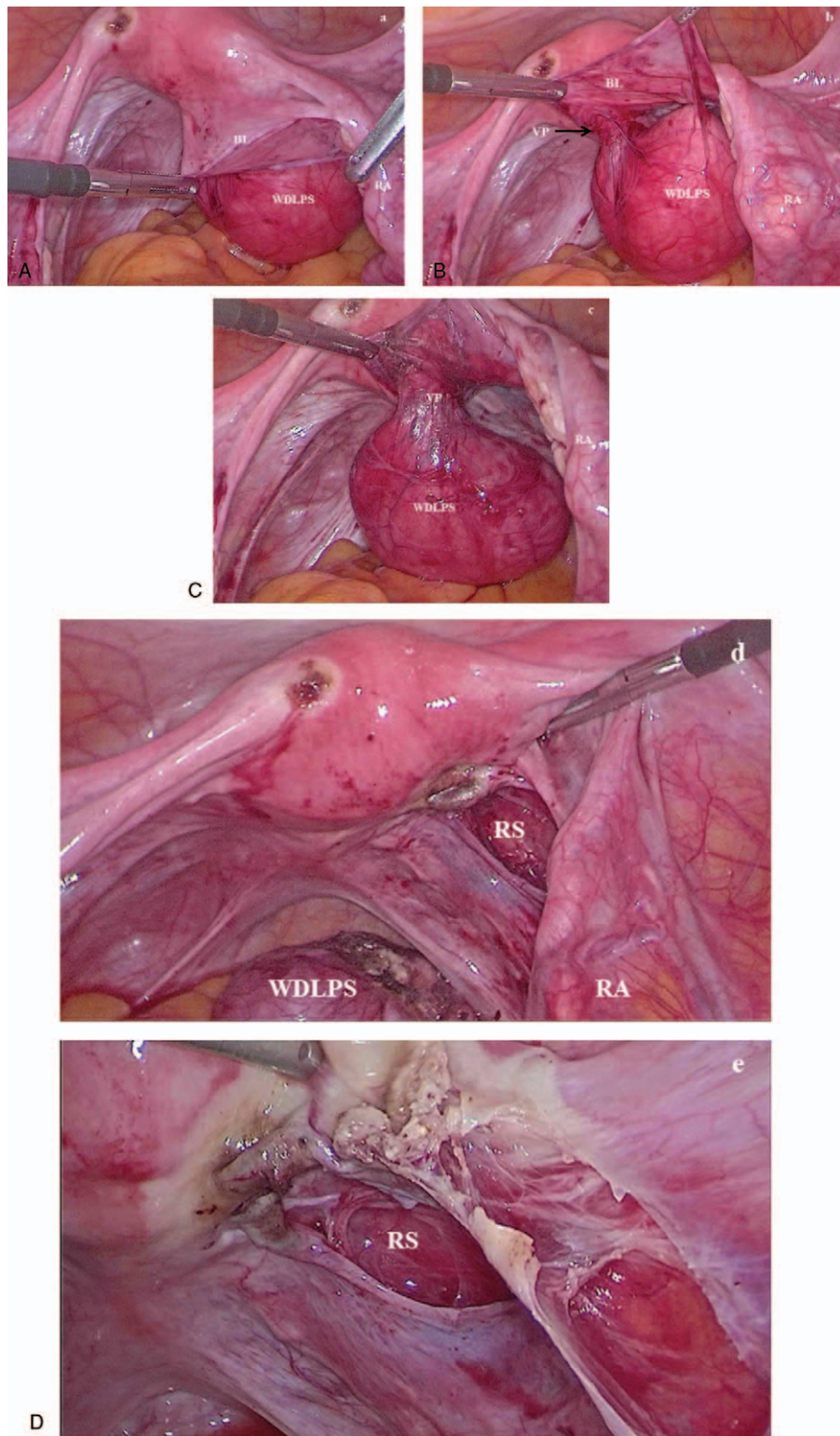


Figure 2. Laparoscopic radical resection: (A) a well-differentiated liposarcoma (WDLPS) was found in the posterior sheet of the right broad ligament (BL), while the right adnexa (RA) was normal; (B) during enucleation of WDLPS a vascular peduncle (VP) was found and (C) isolated; (D) WDLPS was radically resected, retroperitoneal space (RS) was free of disease; (E) a bilateral salpingoophorectomy was also performed.

4. Discussion

Today 32 cases of WDLPS have been reported in literature, women (mean age 54.2 years) were younger than commonly reported.^[6] Only 3 cases were treated laparoscopically.^[14,27,35]

as tumors were smaller than commonly reported. Radical tumor resection represents the gold standard for treatment.^[5] The 5-year survival rate for retroperitoneal WDLPS is 83%.^[2] WDLPS have no risk of metastasis but a high risk (60%) of local

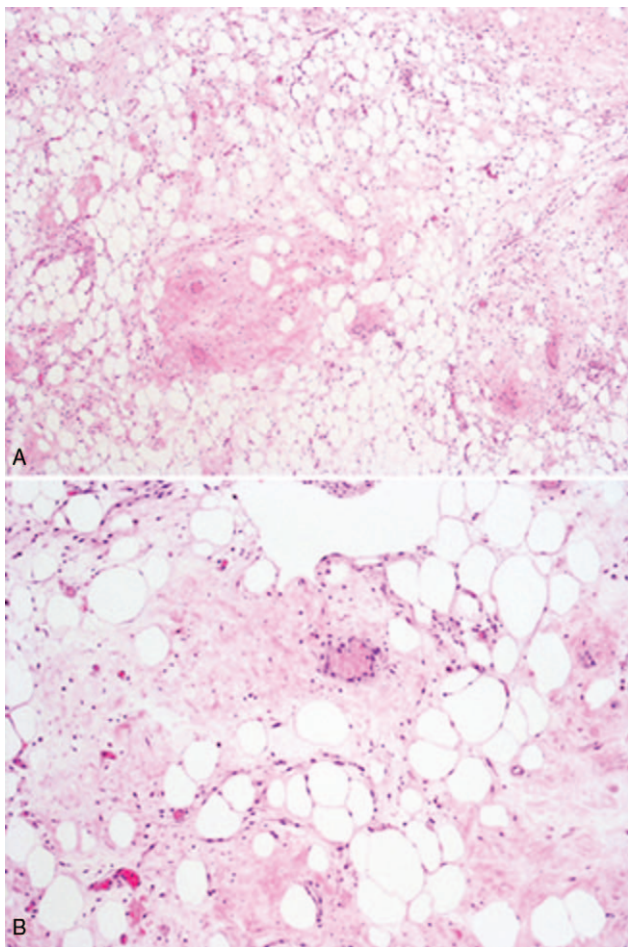


Figure 3. (A) Low-power view of well-differentiated liposarcoma composed entirely of a mature adipocytic proliferation, showing significant variation in cell size. (B) High-power view shows focal nuclear atypia in both adipocytes and stromal cells. The fibrous component may occasionally represent the majority of the neoplasm.

recurrence because defects of the retroperitoneal fat might create a niche for recurrence.^[5] In our review, the risk of recurrence was 24.1%: 7 patients had been previously treated with surgery only,^[2,8,16,23,29,31,33] whereas 2 patients received also chemotherapy^[8,31] and 1 patient also received radiotherapy at the time of 2nd recurrence.^[8] Because these tumors are classically chemo and radio resistant, surgical resection is essential to avoid recurrence. Usually radical surgery requires extensive multiorgan resection because the majority (80%) of retroperitoneal sarcomas are asymptomatic abdominal masses.^[5,7,28] In our review, the mean tumor size was of 29.7 cm (SD ±13.3 cm), ranging from 8 to 60 cm and extensive multiorgan resection was required in 28.1% of cases. Most of cases were diagnosed because presenting as huge abdominal/pelvic masses associated with aspecific symptoms such as abdominal discomfort/pain,^[2,11,17,18,21,31,35] constipation,^[8] dyspnea,^[23,31] weight gain,^[17,26] or loss.^[18] As in our patient, 3/28 (10.7%) cases of retroperitoneal WDLPS were accidentally diagnosed.^[13–15] Although in our case WDLPS was misdiagnosed with an ovarian benign teratoma, CT scan with intravenous contrast is considered the diagnostic technique of choice for WDLPS.^[5] In a retrospective blinded review of imaging in patients with retroperitoneal liposarcoma, an area of focal nodular/water density was found to be a specific (97.8%) marker for DDLPS and had showed a

Table 1

Summary of the clinical and pathologic characteristics of 31 cases of retroperitoneal well-differentiated liposarcomas reported in literature.

| First author | Year | Age, yr | Ethnicity | Pregnancy | Symptoms | Site | Size, cm | Surgical Approach | Treatment | Postsurgery treatment | Recurrence | Follow-up | ER | PR | CD 63 | CD 163 | S-100 | ki-67 | MDM2 | Cdk4 | CD68 | VIM | | |
|------------------------------|------|---------|-----------|-----------|---|---|----------|-------------------|--|-----------------------|--|-----------------|-----|-----|-------|--------|-------|-------|------|------|------|-----|-----|-----|
| Takegji ^[8] | 1984 | 29 | Asiatic | No | Abdomen distension | Right retroperitoneum | 35 | | Tumor excision | Chemotherapy | Yes (2 recurrences treated with surgery and chemotherapy and surgery and radiotherapy) | DWD 84 mo | UNK | UNK | UNK | UNK | UNK | UNK | UNK | UNK | UNK | UNK | UNK | UNK |
| | | 39 | Asiatic | No | Right hypochohncial distension | Right retroperitoneal tumor that displaced the right kidney, the duodenum, the hepatic flexure of colon | 35 | | Tumor excision | No | No | FOD 180 mo | UNK | UNK | UNK | UNK | UNK | UNK | UNK | UNK | UNK | UNK | UNK | UNK |
| | | 38 | Asiatic | No | Constipation | Left retroperitoneum | 2 kg | | En bloc tumor excision with left ureter kidney and splenic flexure | No | No | FOD 108 mo | UNK | UNK | UNK | UNK | UNK | UNK | UNK | UNK | UNK | UNK | UNK | UNK |
| Uchida ^[9] | 1984 | 77 | Asiatic | No | Abdominal mass | The mass involved into the right kidney and ascending colon | | | Tumor excision | No | No | FOD 14 mo | UNK | UNK | UNK | UNK | UNK | UNK | UNK | UNK | UNK | UNK | UNK | UNK |
| Ohyabu ^[10] | 1989 | 62 | Asiatic | No | Abdominal mass | Entire right abdominal cavity | 28 | | Tumor excision with right nephrectomy | Yes (chemotherapy) | No | FOD 3 mo | UNK | UNK | UNK | UNK | UNK | UNK | UNK | UNK | UNK | UNK | UNK | UNK |
| Susin ^[11] | 2000 | 27 | Caucasian | No | Abdominal enlargement and lower abdominal discomfort | From left adnexa to the epigastric region | 40 | Laparotomy | Tumor excision by blunt dissection | No | No | FOD after 24 mo | UNK | UNK | UNK | UNK | UNK | UNK | UNK | UNK | UNK | UNK | UNK | UNK |
| Osmanagaoglu ^[12] | 2003 | 61 | Caucasian | No | Abdominal mass, vague digestive disturbances and abdominal distension | Retroperitoneal mass that marginally involved the right kidney and ovary. | 30 | Laparotomy | Tumor excision by blunt excision | Yes (radiotherapy) | No | FOD 12 mo | UNK | UNK | UNK | UNK | UNK | UNK | UNK | UNK | UNK | UNK | UNK | UNK |

(continued)

Table 1
(continued).

| First author | Year | Age, yr | Ethnicity | Pregnancy | Symptoms | Site | Size, cm | Surgical Approach | Treatment | Postsurgery treatment | Recurrence | Follow-up | ER | PR | CD 63 | CD 163 | S-100 | ki-67 | MDM2 | Cdk4 | CD68 | VIM | | | |
|--------------------------------|------|---------|----------------|-----------|--|---|----------|-------------------------------------|---|-----------------------|--|-----------------|-----|-----|-------|--------|-------|-------|------|------|------|-----|-----|-----|-----|
| Terakawa ^[3] | 2005 | 61 | Asiatic | No | CT for right renal tumor | Renal capsule | | | Right radical nephrectomy | Radiotherapy | UNK | UNK | UNK | UNK | UNK | UNK | UNK | UNK | UNK | UNK | UNK | UNK | UNK | | |
| Bali ^[9] | 2005 | 77 | Caucasian | No | Abdominal discomfort | Adjacent kidney | 8 | Hand-assisted laparoscopic approach | Dissection with mobilization of the lateral attachments of the colon. | UNK | No | UNK | UNK | UNK | UNK | UNK | UNK | UNK | UNK | UNK | UNK | UNK | UNK | UNK | |
| Delpiaz ^[14] | 2007 | 61 | Caucasian | No | Asymptomatic | Retroperitoneal space displacing the left kidney | 10 | Laparoscopy | Tumor excision | No | No | FOD after 12 mo | UNK | UNK | UNK | UNK | UNK | UNK | UNK | UNK | UNK | UNK | UNK | UNK | |
| Lopes ^[15] | 2009 | 33 | Latin American | Yes | Routine examination | Mass compressing uterus down and to the right and the rectosigmoid and extending cranially into the retroperitoneum | 22 | Laparotomy | En bloc tumor excision resection, resectomized-omy, left oophorectomy and distal ureterectomy of the left ureter | No | No | FOD 12 mo | UNK | UNK | UNK | UNK | UNK | UNK | UNK | UNK | UNK | UNK | UNK | UNK | |
| Fernandez-Ruiz ^[16] | 2010 | 61 | Caucasian | No | Left inguinal mass | Left iliopectas fascia | 20 | | Wide excision with peritoneal lymphadenectomy | No | No | FOD 59 mo | UNK | UNK | UNK | UNK | UNK | UNK | UNK | UNK | UNK | UNK | UNK | UNK | |
| | | 47 | Caucasian | No | Abdominal mass in left lower quadrant | Left lower quadrant | 27 | | Tumor excision with left saplingophorectomy | No | Yes (local recurrence after 35 mo. Resected) | FOD 46 mo | UNK | UNK | UNK | UNK | UNK | UNK | UNK | UNK | UNK | UNK | UNK | UNK | |
| Arakaki ^[17] | 2010 | 43 | Asiatic | No | Abdominal fullness and weight gain | Right retroperitoneal space which adhered to the right kidney | 30 | | Tumor excision with resection of right kidney | No | No | FOD 22 mo | UNK | UNK | UNK | UNK | UNK | UNK | UNK | UNK | UNK | UNK | UNK | UNK | |
| Smrkolj ^[18] | 2010 | 62 | Caucasian | No | Abdominal discomfort, sense of fullness, weight loss | Tumor arose from the left retroperitoneal space and displaced the abdominal viscera to the right side of the abdominal cavity | 60 | Laparotomy | Tumor excision with removal of the posterior abdominal wall including portion of the quadrants lumbor muscle and psoas minor muscle and the left parietal peritoneum of the diaphragm | No | No | FOD 60 mo | UNK | UNK | UNK | UNK | UNK | UNK | UNK | UNK | UNK | UNK | UNK | UNK | UNK |
| Duenas-Garcia ^[19] | 2011 | 35 | Latin American | Yes | Palpable mass | Right subcostal angle and part of the left to the symphysis pubis | 52 | | Debulking surgery | No | No | FOD 12 mo | UNK | UNK | UNK | UNK | UNK | UNK | UNK | UNK | UNK | UNK | UNK | UNK | |
| Ajif ^[20] | 2011 | 65 | African | No | Abdominal pain and abdominal swelling | Encapsulated mass occupying the entire pelvis extending to epigastrium | 17 | | Tumor excision | No | No | FOD 12 mo | UNK | UNK | UNK | UNK | UNK | UNK | UNK | UNK | UNK | UNK | UNK | UNK | |
| Selmanj ^[21] | 2011 | 58 | Caucasian | No | Abdominal pain and distension | Abdominal cavity arising from the right retroperitoneum and compressing the surrounding structures | 50 | Laparotomy | Tumor excision | No | No | FOD 12 mo | UNK | UNK | UNK | UNK | UNK | UNK | UNK | UNK | UNK | UNK | UNK | UNK | |
| Shahaj ^[22] | 2012 | 65 | Asiatic | No | Painless distension of abdomen | Left hypochondrium, left lumbar and left iliac fossa involving umbilical region | 26 | | Tumor excision | No | No | FOD 24 mo | UNK | UNK | UNK | UNK | UNK | UNK | UNK | UNK | UNK | UNK | UNK | UNK | |
| Kawabata ^[23] | 2012 | 53 | Asiatic | No | Abdominal distention and dyspnea | The mass, originated from the left lower pelvis, occupied entire abdominal cavity | 18 kg | | Tumor excision | UNK | Yes after 84 mo (surgically treated) | UNK | UNK | UNK | UNK | UNK | UNK | UNK | UNK | UNK | UNK | UNK | UNK | UNK | |
| Makin ^[24] | 2012 | 47 | African | No | Abdominal pain | Mass adhered to left kidney, the splenic flexure of the colon, the spleen and the tail of the pancreas. | 25 | | Tumor excision with pancreatectomy, splenectomy, nephrectomy, and left colectomy | No | No | UNK | UNK | UNK | UNK | UNK | UNK | UNK | UNK | UNK | UNK | UNK | UNK | UNK | |
| Nakajima ^[25] | 2014 | 71 | Asiatic | No | Abdominal protuberance | Entire abdomen | 30 | | En bloc resection | UNK | UNK | UNK | UNK | UNK | UNK | UNK | UNK | UNK | UNK | UNK | UNK | UNK | UNK | UNK | |

(continued)

Table 1
(continued).

| First author | Year | Age, yr | Ethnicity | Pregnancy | Symptoms | Site | Size, cm | Surgical Approach | Treatment | Postsurgery treatment | Recurrence | Follow-up | ER | PR | CD 63 | CD 163 | S-100 | Ki-67 | MDM2 | Cdk4 | CD68 | VIM | |
|----------------------------|------|---------|----------------|-----------|-------------------------------|--|----------|-------------------|--|-------------------------------|--|-----------------------------|-----|-----|-------|--------|-------|-------|------|------|------|-----|-----|
| Sharma ^[26] | 2015 | 60 | Asiatic | No | Weight gain | Retropitoneal mass which had displaced the gut loops to left and posteriorly, ascending colon medially and urinary bladder and uterus to right | 47 | Transperitoneal | Tumor excision | No | No | FOD 6 mo | UNK | UNK | UNK | UNK | UNK | UNK | UNK | UNK | UNK | UNK | UNK |
| Honda ^[27] | 2015 | 64 | Asiatic | No | UNK | Left side of pelvis | 15 | Laparoscopy | Tumor excision | No | No | UNK | UNK | UNK | UNK | UNK | UNK | UNK | UNK | UNK | UNK | UNK | UNK |
| Kasashima ^[28] | 2015 | 34 | Asiatic | Yes | Abdominal distension | Abdominal mass displacing the ascending colon and the right kidney to the left | 43 | Laparotomy | Tumor excision | No | No | FOD 36 mo | POS | NEG | UNK | UNK | UNK | UNK | UNK | UNK | UNK | UNK | UNK |
| Yang ^[29] | 2016 | 60 | Asiatic | No | Abdominal distension | From right fatty renal capsule and the kidney was covered by the carcinoma | 20 | | Tumor excision | Chemotherapy and Radiotherapy | No | FOD 6 mo | UNK | UNK | POS | UNK | UNK | UNK | UNK | UNK | UNK | UNK | UNK |
| Oh ^[30] | 2016 | 71 | Asiatic | No | Abdominal distension | The tumor was encasing the entire left kidney and adherent to the aorta | 45 | Laparotomy | Tumor excision | No | Yes after 16 mo | FOD 28 mo | UNK | UNK | UNK | UNK | UNK | UNK | UNK | POS | UNK | UNK | UNK |
| Iannidis ^[31] | 2018 | 55 | Caucasian | No | Dyspnea and abdominal pain | Right portion of the abdomen. The tumor was in contact with the right kidney, the inferior vena cava and the right renal vein | 23 | | | No | No | FOD 48 mo | UNK | UNK | UNK | UNK | UNK | UNK | UNK | UNK | UNK | UNK | UNK |
| Da Silva ^[32] | 2018 | 42 | Latin American | No | UNK | Left pararenal space | 14 | | Tumor excision | No | Yes after 3 mo (treated with surgery and chemotherapy) Yes after 20 mo (surgically treated) | FOD 8 mo after chemotherapy | UNK | UNK | UNK | UNK | POS | POS | POS | POS | POS | UNK | UNK |
| Miao ^[2] | 2018 | 61 | Asiatic | No | Abdominal pain | Mass adhered to and constricted the main trunk and branch of the superior mesenteric vein, especially ileocolic vein | 30 | | Tumor excision | No | No | FOD 27 mo | UNK | UNK | UNK | UNK | UNK | UNK | UNK | UNK | UNK | UNK | UNK |
| Al Sheikhi ^[33] | 2018 | 61 | Caucasian | No | Collapsing and abdominal pain | From the mid-pole of the left kidney (with adjacent hematoma) | 21 | Retropitoneal | Left radical nephrectomy via a left flank incision | No | No | FOD 6 mo | UNK | UNK | UNK | UNK | UNK | UNK | UNK | UNK | UNK | UNK | UNK |
| Nukada ^[34] | 2018 | 56 | Asiatic | No | UNK | UNK | UNK | | Tumor excision | No | Yes (1st after 204 mo, 2nd after 48 mo, third after 24 mo: surgically treated) | FOD 288 mo | UNK | UNK | UNK | UNK | UNK | UNK | UNK | UNK | UNK | UNK | UNK |
| Mandato YD | 2018 | 60 | Caucasian | No | Right ovarian teratoma | Posterior sheet of the right broad ligament | 5 | Laparoscopy | Tumor excision and prophylactic salpingo-oophorectomy and endometrial biopsy | No | No | FOD 16 mo | UNK | UNK | UNK | UNK | UNK | UNK | UNK | UNK | UNK | UNK | UNK |

CD = cluster of differentiation, CM = centimeter, DWD = died of disease, ER = estrogen receptor, FOD = free of disease, MDM2 = murine double minute 2, MO = months, PR = progesterone receptor, UNK = unknown, VIM = vimentin, YR = years.

negative predictive value of 100%, suggesting that most WDLPS diagnosis can be strongly suggested on imaging alone.^[36] MRI is an option for patients with contrast allergies or when more precise definition of anatomy is needed.^[5] When preoperative imaging is not pathognomonic for WDLPS, image-guided core-needle biopsies should be obtained particularly when neoadjuvant treatment is taken into consideration. The risk of tumor seeding along the biopsy track is minimal and it is not a reason to avoid such procedure.^[37] However, areas of potential dedifferentiation could be missed because of the large size, with a false negative rate of over 50%.^[38] On the contrary, open biopsy via laparotomy or laparoscopy is not recommended because of the risk of peritoneal contamination and seeding, and it may also distort tissue planes needed for subsequent resection.^[39] If a retroperitoneal mass is discovered incidentally during surgery performed for other reasons, an open core-needle biopsy should be considered if it can be performed without peritoneal contamination, otherwise no further action should be taken until adequate imaging is obtained. Intraoperative frozen sections have been shown to be not very useful. An operative decisions should only be made after reviewing the final pathology and imaging studies.^[40] In our case, we discovered incidentally WDLPS that was radically resected and sent for frozen section suggesting a tumor with adipocytes and inflammatory cells. Radical excision was obtained thank to the well-defined margins of the tumor and the scant presence of fatty tissue in the broad ligament. High degree of adipocyte differentiation makes it difficult to distinguish between WDLPS and normal retroperitoneal tissue. Laparoscopic magnification could help distinguish disease from the surrounding tissues. When the final pathology report showed WDLPS, an MRI was repeated to exclude residual disease and other localizations. Retroperitoneal WDLPS are rare and locally advanced at the time of diagnosis. Radical resection represents the only effective treatment. When feasible for tumor characteristics (lesion location, size, shape) and surgical skills, laparoscopic approach should be preferred, as it allows radical dissection of the tumor with the benefit of mini-invasive approach.^[14,27,35] Laparoscopy could cause less adhesions making a 2nd surgery easier in case of recurrence. However, tumor spillage should be avoided because the risk of abdominal and trocar site implant is not negligible.^[41] Four cases of retroperitoneal WDLPS were successfully treated by laparoscopy so far. Despite CT scan is considered the gold standard to diagnose WDLPS it is important to stress that it is possible to misdiagnose WDLPS with mature ovarian teratoma that has a different prognosis and does not require follow-up. Actually laparoscopy could represent a safe and effective technique to diagnose and treat retroperitoneal WDLPS.^[14,27,35,42]

Author contributions

Conceptualization: Vincenzo Dario Mandato, Lorenzo Aguzzoli.

Data curation: Valentina Mastrofilippo.

Writing – original draft: Vincenzo Dario Mandato, Loredana De Marco.

References

- [1] Fletcher CDM, Bridge JA, Hogendoorn PCW, et al. WHO Classification of Tumours of Soft Tissue and Bone, 4th ed. Lyon: IARC Press; 2013.
- [2] Miao RC, Wan Y, Zhang XG, et al. Devascularization of the superior mesenteric vein without reconstruction during surgery for retroperitoneal liposarcoma: a case report and review of literature. *World J Gastroenterol* 2018;24:2406–12.
- [3] Mettlin C, Priore R, Rao U, et al. Results of the national soft-tissue sarcoma registry. *J Surg Oncol* 1982;19:224–7.
- [4] Herrera-Gómez A, Ortega-Gutiérrez C, Betancourt AM, et al. Giant retroperitoneal liposarcoma. *World J Surg Oncol* 2008;6:115.
- [5] Mansfield SA, Pollock RE, Grignol VP. Surgery for abdominal well-differentiated liposarcoma. *Curr Treat Options Oncol* 2018;19:1.
- [6] Vijay A, Ram L. Retroperitoneal liposarcoma: a comprehensive review. *Am J Clin Oncol* 2015;38:213–9.
- [7] Chouairy CJ, Abdul-Karim FW, MacLennan GT. Retroperitoneal liposarcoma. *J Urol* 2007;177:1145.
- [8] Takagi H, Kato K, Yamada E, et al. Six recent liposarcomas including largest to date. *J Surg Oncol* 1984;26:260–7.
- [9] Uchida K, Shimazui T, Kikuchi K, et al. A case of retroperitoneal liposarcoma [in Japanese]. *Hinyokika Kyo* 1984;30:781–5.
- [10] Ohyabu Y, Sameshima H, Nakayama M, et al. The retroperitoneal liposarcoma: a case report [in Japanese]. *Hinyokika Kyo* 1989;35:307–13.
- [11] Susini T, Taddei G, Massi D, et al. Giant pelvic retroperitoneal liposarcoma. *Obstet Gynecol* 2000;95:1002–4.
- [12] Osmanoglu MA, Bozkaya H, Ozeren M, et al. Primary retroperitoneal liposarcoma. *Eur J Obstet Gynecol Reprod Biol* 2003;109:228–30.
- [13] Terakawa T, Taguchi I, Imanishi O, et al. A case of retroperitoneal liposarcoma arising from the renal capsule [in Japanese]. *Hinyokika Kyo* 2005;51:171–3.
- [14] Dalpiaz O, Gidaro S, Lipsky K, et al. Case report: Laparoscopic removal of 10-cm retroperitoneal liposarcoma. *J Endourol* 2007;21:83–4.
- [15] Lopes RI, Machado M, Paz C, et al. Successful outcome of a surgically treated giant retroperitoneal liposarcoma during pregnancy. *Arch Gynecol Obstet* 2009;280:1067–9.
- [16] Fernandez-Ruiz M, Rodriguez-Gil Y, Guerra-Vales JM, et al. Primary retroperitoneal liposarcoma: clinical and histological analysis of ten cases. *Gastroenterol Hepatol* 2010;33:370–6.
- [17] Arakaki R, Yoshikawa T, Yamada H, et al. A case of retroperitoneal well-differentiated liposarcoma with metaplastic bone formation [in Japanese]. *Hinyokika Kyo* 2010;56:697–700.
- [18] Smrkolj S, Rakar S, Stofa A, et al. Giant pelvic retroperitoneal liposarcoma: case report. *Eur J Gynaecol Oncol* 2010;31:705–8.
- [19] Duenas-Garcia OF, Diaz-Sotomayor M, Rico-Olvera H. Well-differentiated giant retroperitoneal liposarcoma during pregnancy. *Rev Esp Enferm Dig* 2011;103:657–8.
- [20] Aji S, Alhassan S, Ibrahim S. Giant retroperitoneal liposarcoma mimicking ovarian tumour - a case report. *J West Afr Coll Surg* 2011;1:105–11.
- [21] Selmani R, Begovic G, Janevski V, et al. Giant retroperitoneal liposarcoma: a case report. *Prilozi* 2011;32:323–32.
- [22] Shahaji C, Amit P, Prashant P, et al. Giant retroperitoneal liposarcoma: a case report. *Case Rep Oncol Med* 2012;2012:869409.
- [23] Kawaota T, Fukada T, Kuwahara T, et al. A case of retroperitoneal liposarcoma. *Gan To Kagaku Ryoho* 2012;39:2423–5.
- [24] Makni A, Triki A, Fetirich F, et al. Giant retroperitoneal liposarcoma. Report of 5 cases. *Ann Ital Chir* 2012;83:161–6.
- [25] Nakajima Y, Fukunari H, Kato T, et al. Two cases of giant retroperitoneal liposarcoma [in Japanese]. *Gan To Kagaku Ryoho* 2014;41:2468–71.
- [26] Sharma M, Mannan R, Bhasin TS, et al. Giant Inflammatory variant of well-differentiated liposarcoma: a case report of a rare entity. *J Clin Diagn Res* 2013;7:1720–1.
- [27] Honda S, Yoshioka S, Yanagisawa K, et al. A case of liposarcoma occurring in the retroperitoneum treated by laparoscopic excision [in Japanese]. *Gan To Kagaku Ryoho* 2015;42:1941–3.
- [28] Kasashima H, Yamasaki Y, Morimoto Y, et al. A case of retroperitoneal liposarcoma after delivery with expression of estrogen receptor: report of a case. *Int J Surg Case Rep* 2015;7:99–103.
- [29] Yang J, Zhao Y, Zheng CH, et al. Huge retroperitoneal liposarcoma with renal involvement requires nephrectomy: a case report and literature review. *Mol Clin Oncol* 2016;5:607–9.
- [30] Oh SD, Oh SJ, Suh BJ, et al. A giant retroperitoneal liposarcoma encasing the entire left kidney and adherent to adjacent structures: a case report. *Case Rep Oncol* 2016;9:368–72.
- [31] Ioannidis A, Koutserimpas C, Konstantinidis M, et al. Dyspnea caused by a giant retroperitoneal liposarcoma: a case report. *Oncol Lett* 2018;16:1539–42.
- [32] Da Silva FR, Lima AVJ, Albuquerque EWRP, et al. Complete remission of recurrent retroperitoneal liposarcoma after the administration of Gemcitabine and Docetaxel as first-line adjuvant chemotherapy: a case report. *Case Rep Oncol* 2018;11:341–6.
- [33] Al Sheikh M, Simson N, Obi-Njoku O, et al. Acute haemorrhage from a retroperitoneal liposarcoma: a rare presentation. *BMJ Case Rep* 2018;8:2018.

- [34] Nukada S, Aoyama T, Kamiya M, et al. A case of retroperitoneal liposarcoma resected 6 times in 24 years [in Japanese]. *Gan To Kagaku Ryoho* 2018;45:106–8.
- [35] Ball AJ, Siddiq FM, Garcia M, et al. Hand-assisted laparoscopic removal of retroperitoneal liposarcoma. *Urology* 2005;65:1226.
- [36] Lahat G, Madewell JE, Anaya DA, et al. Computed tomography scan-driven selection of treatment for retroperitoneal liposarcoma histologic subtypes. *Cancer* 2009;115:1081–90.
- [37] Strauss DC, Hayes AJ, Thway K, et al. Surgical management of primary retroperitoneal sarcoma. *Br J Surg* 2010;101:520–3.
- [38] Ikoma N, Torres KE, Somaiah , et al. Accuracy of preoperative percutaneous biopsy for the diagnosis of retroperitoneal liposarcoma subtypes. *Ann Surg Oncol* 2015;22:1068–72.
- [39] Bonvalot S, Raut CP, Pollock RE, et al. Technical considerations in surgery for retroperitoneal sarcomas: position paper from ESurge, a master class in sarcoma surgery, and EORTCSTBSG. *Ann Surg Oncol* 2012;19:2981–91.
- [40] Trans-Atlantic RPS Working Group Management of primary retroperitoneal sarcoma (RPS) in the adult: a consensus approach from the Trans-Atlantic RPS Working Group. *Ann Surg Oncol* 2015;22:256–63.
- [41] Nomura R, Tokumura H, Matsumura N. Laparoscopic resection of a retroperitoneal liposarcoma: a case report and review of the literature. *Int Surg* 2013;98:219–22.
- [42] Horiguchi A, Saito S, Baba S, et al. Port site recurrence after laparoscopic resection of retroperitoneal liposarcoma. *J Urol* 1998;159:1296–7.