


# Classification Systems for Knee Osteochondritis Dissecans: A Systematic Review

CARTILAGE  
 July-September 2022: 1–15  
 © The Author(s) 2022  
 DOI: 10.1177/19476035221121789  
[journals.sagepub.com/home/CAR](https://journals.sagepub.com/home/CAR)  


Luca Andriolo<sup>1\*</sup>, Luca Solaro<sup>1\*</sup>, Sante Alessandro Altamura<sup>1</sup>, James L. Carey<sup>2,3</sup>, Stefano Zaffagnini<sup>1</sup>, and Giuseppe Filardo<sup>4</sup>

## Abstract

**Objective.** Aim of this systematic review was to describe all classification systems for knee osteochondritis dissecans (OCD) lesions, evaluating their accuracy and reliability, as well as their use in the literature on knee OCD. **Design.** A systematic review of the literature was performed in July 2021 on PubMed, WebOfScience, and Cochrane Collaboration (library) to describe all published classification systems for knee OCD lesions and quantify the use of these classifications in the literature. **Results.** Out of 1,664 records, 30 studies on 33 OCD classifications systems were identified, describing 11 radiographic, 13 MRI, and 9 arthroscopic classifications. The search included 193 clinical studies applying at least one OCD classification, for a total of 7,299 knee OCD cases. Radiographic classifications were applied to 35.8%, MRI to 35.2%, and arthroscopic classifications to 64.2% of the included studies. Among these, in the last two decades, the International Cartilage Repair Society's (ICRS) arthroscopic classification was the most described approach in studies on knee OCD. Overall, there is a lack of data on accuracy and reliability of the available systems. **Conclusions.** Several classifications are available, with ICRS being the most used system over the time period studied. Arthroscopy allows to confirm lesion stability, but noninvasive imaging approaches are the first line to guide patient management. Among these, radiographic classifications are still widely used, despite being partially superseded by MRI, because of its capability to detect the earliest disease stages and to distinguish stable from unstable lesions, and thus to define the most suitable conservative or surgical approach to manage patients affected by knee OCD.

**Level of evidence:** Systematic review, level IV.

## Keywords

osteochondritis dissecans, classification, knee, osteochondral, cartilage

## Introduction

Osteochondritis dissecans (OCD) is a focal, idiopathic pathologic process of the osteochondral unit,<sup>1</sup> with the knee being the most affected joint.<sup>2,3</sup> This condition involves primarily the subchondral bone and has the potential for secondary instability with disruption of the overlying articular cartilage, which could result in the separation of the osteochondral fragment. These alterations can severely impair joint function and lead to the development of early osteoarthritis (OA).<sup>4</sup> Accordingly, the choice of the most appropriate treatment is crucial to improve patient symptoms and prevent OA, especially considering the young age of the affected patients.<sup>3,5</sup> Several options are currently available, ranging from conservative management<sup>6</sup> to surgical approaches with fragment fixation, drilling, or osteochondral replacement procedures.<sup>7,8</sup>

The algorithm for OCD management needs to consider several factors, like the skeletal maturity, the presence of cartilage degeneration, the stability of the lesion and its

<sup>1</sup>Clinica Ortopedica e Traumatologica 2, IRCCS Istituto Ortopedico Rizzoli, Bologna, Italy

<sup>2</sup>Penn Center for Advanced Cartilage Repair and Osteochondritis Dissecans Treatment, Hospital of the University of Pennsylvania, Philadelphia, PA, USA

<sup>3</sup>Perelman School of Medicine, University of Pennsylvania, Philadelphia, PA, USA

<sup>4</sup>Applied and Translational Research (ATR) Center, IRCCS Istituto Ortopedico Rizzoli, Bologna, Italy

\*These authors equally contributed to the preparation of the manuscript

### Corresponding Author:

Luca Solaro, Clinica Ortopedica e Traumatologica 2, IRCCS Istituto Ortopedico Rizzoli, Via Pupilli, 1/10, 40136 Bologna, Italy.  
 Email: [luca.solaro@alice.it](mailto:luca.solaro@alice.it)



probability to heal.<sup>8-10</sup> A proper OCD classification is therefore crucial to choose the best treatment approach for OCD lesions. From 1888, when König first named the disease,<sup>11</sup> the need to better understand the different types of OCD lesions led to the development of several classifications systems. Different methods have been proposed either based on radiologic or arthroscopic evaluations, all presenting specific advantages and drawbacks in terms of costs, invasiveness, and ability to detect key diagnostic aspects.<sup>12</sup> To date, a consensus about the most suitable classification system is still lacking. The absence of a universally recognized classification method makes it difficult to compare the results of the current literature and to provide the clinicians with clear indications to properly identify and treat each specific OCD lesion.

Aim of this systematic review was to describe all classification systems for knee OCD lesions, evaluating their accuracy and reliability, as well as their use in the literature on knee OCD.

## Materials and Methods

A systematic review of the literature was performed on the existing OCD classifications systems. The search was conducted on July 27, 2021, on the three medical electronic databases PubMed, WebOfScience, and Cochrane Collaboration (library) using the following parameters: ([OCD] OR [osteochondritis dissecans]) AND (knee). The guidelines for Preferred Reporting Items for Systematic Reviews and Meta-Analysis (PRISMA) were used.<sup>13</sup> All the results were screened and analyzed separately by two independent observers (L.S. and S.A.A.). A selection to exclude duplicates was performed. In the first step, the following inclusion criteria for relevant articles were used during the initial screening of titles and abstracts: articles of any level of evidence, written in English language, with no time limitation, reporting about knee OCD. Exclusion criteria were articles written in other languages, preclinical studies, and articles focusing on other joints or other pathologies than knee OCD. In a second step, full texts of the selected articles were examined, and papers were further selected to the purpose of the present review for the analysis of two main aspects:

1. *To describe* all published classification systems for knee OCD lesions. Reference lists from the selected papers were screened to detect other articles describing new OCD classification systems. In this step also articles in other languages and systematic reviews were selected, if reporting a previously not described OCD classification.
2. *To quantify* the use of these classifications in the literature; the full texts of the clinical studies about knee OCD lesions were examined according to the

inclusion and exclusion criteria defined in the first step of the systematic review. Moreover, systematic reviews and articles that did not use OCD classifications to describe patient series affected by OCD were excluded.

Relevant data (year, study design, classification system, classification criteria description, and number of OCD cases analyzed) of all the included studies were extracted and collected in a database by two observers (L.S. and S.A.A.), with involvement of a third author (L.A.) to reach consensus in case of disagreement, to be analyzed for the purpose of the present manuscript.

## Results

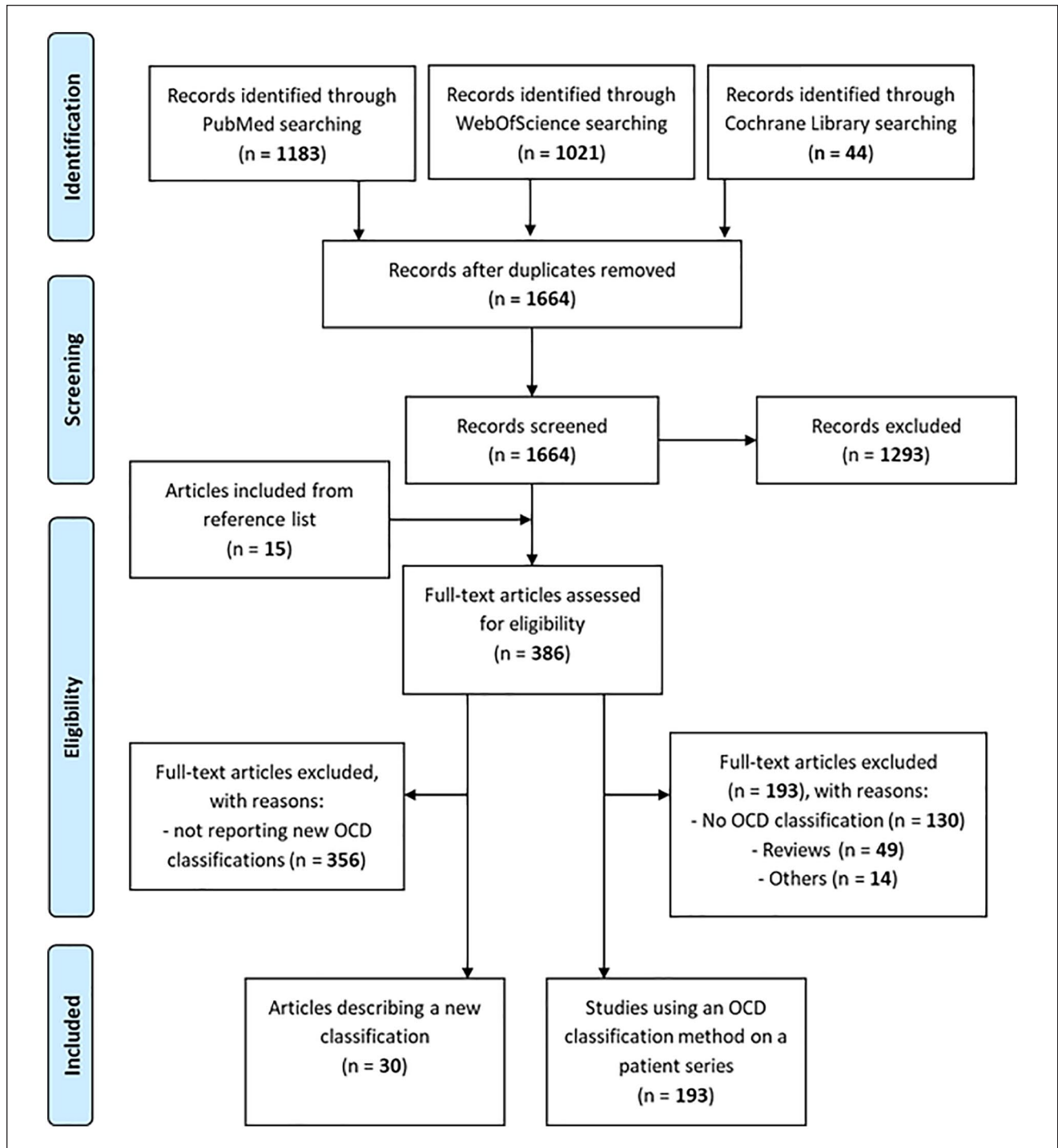
The search identified a total of 1,664 records after duplicates removal (**Fig. 1**). The articles were screened according to the inclusion and exclusion criteria, leaving a total of 385 full-text articles assessed for eligibility. Finally, 30 studies describing 33 OCD classifications systems and 193 clinical studies applying at least one OCD classification were included.

### OCD Classifications

The 30 articles proposed 11 radiographic classifications (1 using a combination of x-rays and bone scan), 13 MRI classifications, and 9 arthroscopic classifications.

**X-ray classifications.** X-rays have been used to classify OCD severity in 7 studies, OCD location in 3 studies, and one study focused on both severity and location<sup>14</sup> (**Table 1**).

The first x-ray-based OCD classification was described by Berndt and Harty<sup>15</sup> in 1959 and focused on OCD severity, being originally used for OCD of the talus and then widely adopted also for knee lesions. This system recognizes 4 grades of OCD severity, emphasizing the process of progressive detachment of the osteochondral fragment, grading it from a stable lesion to a complete displacement with the presence of an intra-articular body. Similar criteria for defining lesion severity depending on fragment stability or detachment were also applied in the subsequent classifications of Clanton and Delee,<sup>19</sup> Rodegerdts and Gleißner,<sup>18</sup> and Brückl *et al.*,<sup>20</sup> with the last two also describing sclerosis and translucency to better identify the earlier stages. In 1988, Bedouelle *et al.*<sup>22</sup> proposed the assessment of other lesion features including the presence of calcification and the appearance as a nodule with more or less shrinkage or with a sleigh bell aspect. Later, Bruns in 1997<sup>23</sup> implemented in the concept of growing instability the distinction of malicious or dissected forms in the more advanced stages, which corresponded also to MRI and arthroscopic findings. Finally, Lefort *et al.*<sup>24</sup> in 2006 introduced a



**Figure 1.** PRISMA flow-chart of the systematic literature review.

classification based both on the extension of the lesion and the physical status.

The first radiographic classification focused on lesion location was introduced by Aichroth in 1971,<sup>16</sup> describing seven categories of specific locations according to their relative frequency, with the lateral posterior portion of the

medial femoral condyle defined as the “classical” OCD location. In 1977, Harding<sup>17</sup> focused on lesions of the medial femoral condyle dividing them in 3 zones and identifying an “area at risk” between the Blumensaat line (tangent to the roof of the intercondylar notch in lateral-lateral projection) and the tangential line to the posterior cortex of

**Table 1. X-ray Classifications.**

Article	Study design summary	Classification	Sensitivity, specificity, inter/intra-rater agreement
Berndt and Harry <sup>15</sup>	Systematic review and anatomical investigation Reproducing typical lesions of OCD of the dome of the talus in laboratory by applying various forces to the ankle of amputation specimens	OCD severity: I: Small depression area with no detachment of the osteochondral fragment II: Partial detachment of the osteochondral fragment III: Full detachment but osteochondral fragment <i>in situ</i> IV: Complete detachment with osteochondral fragment dislocated, free intra-articular body	—
Aichroth <sup>16</sup>	Retrospective case series 105 patients with knee OCD reviewed; lesions were classified based on their location	OCD location: <ul style="list-style-type: none"> <li>• Posterolateral portion of the MFC described as “classical” OCD location.</li> <li>• Trochlea and central areas of the MFC “extended classical” locations.</li> <li>• Inferocentral portion of the MFC</li> <li>• Inferocentral portion of the LFC</li> <li>• Anterior portion of the LFC</li> <li>• Intercondylar notch lesions are rare</li> <li>• Isolated involvement of femoral trochlea and patella is less than 5% of cases</li> </ul>	—
Harding <sup>17</sup>	Prospective case series 12 patients with diagnosis of OCD of MFC evaluated with lateral x-ray	OCD location: Zone A: in front of the Blumensaat line. Zone B: between zone A and C, “area at risk.” Zone C: behind the tangential line to the posterior cortex of the femoral diaphysis.	—
Rodegterds and Gleißner <sup>18</sup>	Original article not available	OCD severity: I: Potentially depressed osteochondral fracture (“Sleeping phase”) II: Demarcation without sclerotic rim III: Demarcation with sclerotic rim IV: Partly detached fragment, non-displaced V: Displaced fragment (“loose body”)	—
Clanton and DeLee <sup>19</sup>	Review	OCD severity: Type I: depressed osteochondral fracture Type II: fragment attached by osseous bridge Type III: detached non-displaced fragment Type IV: displaced fragment	—
Brückl <i>et al.</i> <sup>20</sup>	Retrospective case series 33 juvenile and 28 adults knee OCD cases were reviewed	OCD severity: Stage I: dawn stage (OCD cannot be detected by radiography) Stage II: obvious translucency Stage III: demarcation by sclerosis Stage IV: pronounced demarcation, lesion is sclerotic and loosened Stage V: loose body	—
Cahill and Berg <sup>14</sup>	Prospective case series 99mTc-diphosphonate joint scintigraphy used on 18 cases of knee OCD and repeated at 6-wk intervals until healing had occurred. Scans were categorized according to their level of scintigraphic activity and appearance on standard x-rays	OCD location: Based on AP projection, anatomic zones 1, 2, 4, and 5 are delineated by bisecting the individual condyles. Zone 3 is outlined by the walls of the intercondylar tunnel. In the LL projection, Zone A is limited by a line projected along the roof of the intercondylar tunnel (Blumensaat line). Zones B and C are separated by a line projecting distally from and parallel to the posterior femoral cortex. OCD severity <sup>21</sup> : 0: Normal appearance both in x-ray and scintigraphy 1: Visible x-ray lesion without any increase in scintigraphy activity 2: Accumulation of the isotope at the level of the lesion but not in the adjacent bone of the femoral condyle 3: Accumulation of the isotope both at the level of the lesion and adjacent femoral condyle 4: In addition, accumulation of the isotope in the tibial plateau opposite to the lesion	—

(continued)

**Table 1. (continued)**

Article	Study design summary	Classification	Sensitivity, specificity, inter/intra-rater agreement
Hughston et al. <sup>21</sup>	Review and retrospective case series of 94 patients with knee OCD were reviewed to identify factors that may influence treatment and long-term prognosis. Authors developed a classification to assess the effect of lesion localization on the long-term prognosis.	<p>OCD location: Based on AP projection, they identified the following:</p> <ul style="list-style-type: none"> <li>• Intercondylar lesions (between condyles, at intercondylar notch level)</li> <li>• Non-meniscal lesions (between intercondylar and meniscal lesions, not in contact with meniscus in full extension)</li> <li>• Meniscal lesions (the most medial areas of the MFC and the most lateral of the LFC, that are in contact with the meniscus in full extension)</li> </ul> <p>Based on the LL projection considering a line tangent to the posterior cortical bone of the femoral diaphysis:</p> <ul style="list-style-type: none"> <li>• Anterior lesions (weightbearing zones, in contact with the tibial plateau between 0° and 30° of flexion)</li> <li>• Posterior lesions (considered to be in no weightbearing zones and in contact with the tibial plateau over 30° of flexion)</li> </ul> <p>OCD severity: Stage 1: clearly incomplete well-defined image (Ia) with more or fewer calcifications within (Ib); Stage 2: presence of a nodule (IIa) with more or less shrinkage of the nodule in relation to the condyle (IIb); Stage 3: sleigh-bell aspect; Stage 4: free fragment in the joint with an empty bed.</p> <p>OCD severity: Stage I: No changes Stage II: Sclerosis Stage III<sup>a</sup>: Partial loosening Stage IV<sup>b</sup>: Complete Dissection, Loose body</p> <p>OCD severity: Grade I: Surface area smaller than 350 mm<sup>2</sup> with open physes Grade II: Surface area larger than 350 mm<sup>2</sup> with open physes Grade III: Closed physes</p>	—
Bedouelle <sup>22</sup>	Original article not available		—
Bruns <sup>23</sup>	Review of literature and proposal of a radiographic, arthroscopic, and MRI staging system.		—
Lefort et al. <sup>24</sup>	Review of literature and proposal of a radiographic, arthroscopic, and MRI staging system		—

OCD = Osteochondritis dissecans; MFC = medial femoral condyle; LFC = lateral femoral condyle; LL = latero-lateral.

<sup>a</sup>Both radiographic and scintigraphic.

<sup>b</sup>Stages III and IV can be subdivided into the malicious (M) or dissected (D) form.

the femoral diaphysis. In 1984, Hughston *et al.*<sup>21</sup> proposed a new “anatomical” radiographic classification using the meniscus as reference. Based on the AP projection, they identified “Intercondylar lesions,” “Non-meniscal lesions,” and “Meniscal lesions,” while on the LL projection anterior and posterior lesions were differentiated based on the tangential line to the femoral posterior cortex already used by Harding. Cahill and Berg<sup>14</sup> proposed in 1983 a location system dividing the knee into 5 zones in medial-lateral direction, similarly to Hughston *et al.*, and 3 zones in anteroposterior direction, in a similar fashion to the older Harding classification. Moreover, they combined x-ray findings and 99mTc scintigraphy to describe 5 grades of OCD severity. Bone scan findings were indicative of the extent of progression or healing of OCD, although its use has been subsequently replaced by MRI.

**Bone scan and nuclear medicine imaging.** Cahill and Berg<sup>14</sup> classification included not only radiographs, but also 99mTc-diphosphonate joint scintigraphy, performed on 18 cases of knee OCD and repeated at 6-week intervals until healing had occurred. Based on scintigraphic activity and x-ray appearance, the authors developed a 0 to 4 grading system. Bone scan findings were indicative of the extent of progression or healing of OCD.

**MRI classifications.** In the last decades, MRI has progressively gained importance for evaluating the knee, especially concerning cartilage pathologies. Currently, it is the most important radiological exam to diagnose and to follow-up knee OCD lesions, and to this aim, 13 classification systems have been described (Table 2). The most important focus of these classifications is the lesion stability/instability, which is key to decide the conservative/surgical management. All the existing classification systems describe intact articular cartilage for stable or low-grade lesions while authors agree that high-signal intensity in T2-weighted sequences between parent bone and fragment is an indicator of instability, even though in some cases, the high-signal intensity was described to also indicate healing or fibrous tissue at the interface.<sup>25-27</sup>

The first MRI criteria to predict the instability of the OCD lesion were formulated by De Smet *et al.*<sup>28</sup> in 1990 (high T2-signal intensity line surrounding the lesion, fluid-filled cartilage defect, presence of subchondral cysts, high T2-signal fracture line in articular cartilage) and were subsequently used and revised by Kijowski *et al.*<sup>26</sup> These criteria did not provide a detailed classification of the lesions with specific stages but rather an evaluation of the risk of instability. However, Nelson *et al.*<sup>29</sup> and the following paper of Dipaola *et al.*<sup>30</sup> can be considered the first to describe in 1991 an MRI-based classification system. They described a 4-stage MRI classification based on T2-weighted sequences, with Stages I and II considered to be stable and Stages III

and IV instable lesions. Later, in 1992, Kramer *et al.*<sup>33</sup> proposed the use of a contrast agent (MR arthrography) to improve the sensitivity of MRI in staging OCD, using T1- and T2-weighted sequences and GE sequences. They proposed a 5 stages classification introducing a stage with only subchondral bone alterations without cartilage involvement. The same concept of bone-originating lesion based on the detection of fluid (either synovial fluid or gadolinium in case of absent effusion) between fragment and underlying bone was also used by Hefti *et al.*<sup>36</sup> in 1999 to develop a new 5 stages classification. Contrarily, in 1998, Bohndorf<sup>34</sup> differentiated OCD lesions only into 2 types in relation to the stability and the need for surgery: Type 1 (stable lesions not requiring surgery) and type 2 (unstable lesions where surgical intervention is recommended). Similarly, Jurgensen *et al.*<sup>37</sup> in 2002, published a new classification differentiating two types of OCD lesions considering their stability based on T1 and T2 sequences. Later, Chen *et al.*,<sup>39</sup> in 2013, proposed a new 5 stages classification system adding a three-dimensional (3D) T1-weighted gradient-echo (GRE) MR sequence to the routine protocol to better differentiate fluid from granulation tissue and consequently to better detect unstable lesions. Finally, Hussain *et al.*,<sup>32</sup> in 2021, proposed a simpler 3-group classification with a reported excellent intra-rater agreement and moderate inter-rater agreement.

Other classifications have been specifically developed for Juvenile OCD (JOCD), to improve accuracy by considering the different characteristics with respect to adult forms. Yoshida *et al.*,<sup>35</sup> in 1998, developed a staging system differentiating JOCD in 4 stages in relation to the natural history of the lesions and introducing a last stage called “healing stage.” In 2003, Hughes *et al.*<sup>38</sup> revisited previous classifications<sup>30,33,34,40</sup> and developed a 4-stage system, with Stages 1, 2, and 3 considered stable and with high chance to heal with conservative treatment, whereas Stage 4 required surgery. Finally, Ellermann *et al.*, in 2016,<sup>31</sup> based on the preclinical histological evidence that JOCD might occur after a focal failure of endochondral ossification, developed a 5-stage classification system, with T2\* mapping added to the MRI protocol, which described also the healed osseous lesion (Stage IV) and the not-healed osseous lesion (Stage V).

**Arthroscopic classifications.** Nine different arthroscopic classifications (Table 3) of knee OCD lesions were found in the literature. They all present a similar scale of increasing instability, from an initial softening of the articular cartilage with a progressive detachment of the fragment from the parent bone up to the final creation of a crater with loose bodies.

The first arthroscopic classification for OCD has been published by Guhl<sup>41</sup> in 1979. This simple 4-grade classification distinguished stable lesions (Grades 1 and 2) and

**Table 2. MRI Classifications.**

Article	Study design summary	Classification	Sensitivity, specificity, inter/intra-rater agreement
De Smet et al. <sup>28</sup>	Prospective case series Authors correlated MR examinations with arthroscopic findings in 21 patients with OCD to see if MR imaging could be used to predict lesion stability and articular cartilage defects.	Criteria to predict the instability of the lesion: <ul style="list-style-type: none"> <li>High T2-signal intensity line surrounding lesion</li> <li>Fluid-filled cartilage defect</li> <li>Presence of subchondral cysts</li> <li>High T2-signal fracture line in articular cartilage</li> </ul> I: Articular cartilage intact but thickened with small changes in intensity II: Breach in the articular cartilage, with a rim of low-signal intensity on T2-weighted sequences behind the fragment, indicating fibrous attachment or granuloocyte tissue III: Breach in the articular cartilage with high intensity changes behind the fragment on T2-weighted sequences, suggesting fluid behind the lesion. IV: Loose bodies with a defect of the articular cartilage surface.	—
Nelson et al. <sup>29</sup> Dipaola et al. <sup>30</sup>	Prospective case series 12 patients with osteochondral lesions of either the knee or talus were studied using MRI prior to arthroscopic treatment. They developed a new staging system for osteochondral lesions	Stage 1: Low-signal intensity rim on T1- and T2-weighted sequences without interruption, less clearly visible on GE sequences Stage 2: Low-signal intensity rim on T1- and T2-weighted sequences between osteochondral fragment and the remaining bone, no sign of cartilage disruption Stage 3: Low-signal intensity rim on T1-weighted sequences and a partially high intensity signal rim on GE sequences at the interface between the lesion and the remaining bone, circumscribed disruption of the cartilaginous layer Stage 4: Low-signal intensity rim on T1-weighted sequences and a high intensity signal rim on T2-weighted sequences at the interface between the lesion and the remaining bone, total separation of a non-displaced fragment Stage 5: Loose bodies with a defect of the articular cartilage surface Stage 1: Bone bruise, edema Stage 2: Osteolysis, sclerosis Stage 3: Partial loosening, fluid subchondral Stage 4: empty defect, loose body	Sensitivity 70% Specificity 81% Accuracy 76% (Ellermann et al. <sup>31</sup> ) Krippendorff's alpha for inter-rater agreement was 0.50 (95% CI = [0.34, 0.64]). Intra-rater agreement was 0.94 (95% CI = [0.86, 0.99]; Hussain et al. <sup>32</sup> ) 92.9% on T1W SE 100% on GE (Kramer et al. <sup>33</sup> )
Kramer et al. <sup>33</sup>	Prospective case series MR evaluation of 25 knees with clinical suspect of OCD before and after intra-articular administration of 40 ml of a saline/Gd-DTPA mixture (MR arthrography). All images were interpreted by two experienced radiologists and classified by consensus without knowledge of clinical or arthroscopic data.	Type 1 (stable): intact cartilage, convex low-intensity subchondral bone lesion on T1-weighted sequences with demarcation of bone edema. Increase in intensity of the signal to the interface between the lesion and the remaining bone after injection of the contrast agent iv. On T2-weighted sequences, no visible rhyme, no cystic alterations (>5 mm) adjacent to the fragment, no visible cartilage defects in the T2 sequences. Type 2 (unstable): Cartilage defect with or without incomplete fragment separation, fluid around the undetached fragment, and dislodged fragment. No contrast enhancement of the osteochondral fragment. Initial stage: Low-intensity signal on T1 and T2 sequences in lesion floor and interface, slightly low intensity on T1 of the fragment, variable in T2, increased signal and thickened width on T1 and T2 of the articular cartilage Progressive stage: Lesion floor expanded the low-signal zone, ± cysts (T2 W), high intensity at interface, inhomogeneous high intensity of the fragment, high intensity and thickening of articular cartilage with or without disruption Terminal stage: Low intensity on T1 and high intensity on T2 at the surface of lesion floor, low intensity of the fragment on T1 and T2 sequences, disruption and thickening of the articular cartilage Healing stage: Homogeneous intensity of the lesion floor similar to the intact region of epiphysis with some irregularity in the peripheral zone, low-intensity interfaces, slight high intensity thickening, and disruption of articular cartilage remain long time Stage I: Small change of signal without clear margins of fragment Stage II: Osteochondral fragment with clear margins but without fluid between fragment end underlying bone Stage III: Fluid is visible partially between fragment and underlying bone Stage IV: Fluid is completely surrounding the fragment, but the fragment is still in situ Stage V: Fragment is completely detached and displaced (loose body).	—
Brunns <sup>3</sup>	Review of literature and proposal of a radiographic, arthroscopic, and MRI staging system.	Stable: <ul style="list-style-type: none"> <li>Representation of the OCD only in the T1-SE or representation of a signal poor Border seam between osteochondral fragment and lesion bed in the T2-SE</li> </ul> Instable: <ul style="list-style-type: none"> <li>Representation of a partial or completely signal-rich border seam between osteochondral fragment and lesion bed in the T2-SE</li> </ul>	—
Bohndorf <sup>4</sup>	Review of literature Authors developed a new MRI classification based on review of literature especially on OCD imaging that correlates with the appropriate therapy.	—	—
Yoshida et al. <sup>35</sup>	Prospective case series The site of lesion, spontaneous healing, onset mechanism, and MRI findings of 51 knees in 38 patients with osteochondritis dissecans involving the femoral condyle in the growth stage were investigated.	—	—
Hefi et al. <sup>36</sup>	Prospective case series 452 patients with 509 affected knees were classified and treated conservatively or surgically	—	Krippendorff's alpha for inter-rater agreement 0.51 (95% CI = [0.33, 0.66]). The intra-rater agreement was 0.88 (95% CI = [0.75, 0.97]; Hussain et al. <sup>32</sup> ) 92% of accuracy in detecting instability compared with arthroscopy (Jurgensen et al. <sup>37</sup> )
Jurgensen et al. <sup>37</sup>	Prospective case series In 90 patients with OCD of the knee or ankle, MRI was carried out before arthroscopy. According to the interface between the osteochondral fragment and the parent bone, MRI was classified in 2 stages (stable or unstable) and compared with the arthroscopic findings	—	—

(continued)

Table 2. (continued)

Article	Study design summary	Classification	Sensitivity, specificity, inter/intra-rater agreement
Hughes et al. <sup>28</sup>	Prospective case series Twenty-one knees in 19 patients with JOCD underwent MRI and clinical follow-up over 5 years. Lesions were classified as stable or unstable on MRI and compared with clinical and arthroscopic data. Authors developed a new MRI staging system for JOCD modifying previous classifications.	Stage 1: Bone signal intensity change, articular cartilage swelling Stage 2: Bone fragmentation <i>in situ</i> , linear high signal (T2 W) fragment/bone interface. ± cysts (T2 W), intact articular cartilage Stage 3: Bone fragmentation <i>in situ</i> , linear high signal (T2 W) fragment/bone interface. ± cysts (T2 W), articular cartilage is intact but swelling or thinning. ± focal signal intensity changes Stage 4a: Bone fragmentation <i>in situ</i> , linear high signal (T2 W) fragment–bone interface, linear high signal (T2 W) extending through articular cartilage (tear) Stage 4b: Osteochondral fragment, displaced from subchondral parent bone (loose body), subchondral surface defects, articular cartilage loss Stages 1 and 2 are stable and do not require surgery, stages 3 and 4 are unstable and require surgery Revised De Smet criteria for lesion instability: <ul style="list-style-type: none"> <li>High T2-signal intensity rim with one of the following: same signal intensity as synovial fluid, surrounded by additional high T2-signal intensity rim</li> <li>Fluid-filled osteochondral defect</li> <li>Presence of multiple or large (&gt;5 mm) subchondral cysts</li> <li>High T2 signal fracture line in articular cartilage</li> <li>A high T2 signal intensity rim or cysts surrounding an adult OCD lesion are unequivocal signs of instability.</li> </ul> A high T2 signal intensity rim surrounding a JOCD lesion indicates instability only if it has the same signal intensity as adjacent joint fluid, is surrounded by a second outer rim of low T2-signal intensity, or is accompanied by multiple breaks in the subchondral bone plate on T2-weighted MR images. Cysts surrounding a JOCD lesion indicate instability only if they are multiple or large in size.	Sensitivity: -each criteria JOCD: 0%-88% Adult OCD: 27%-54% -all criteria together JOCD: 100% Adult OCD: 100% Specificity: each criteria JOCD: 21%-100% Adult OCD: 100% all criteria together JOCD: 11% Adult OCD: 100% (Kijowski et al. <sup>26</sup> ) Sensitivity 96% (Adult: 93%; Juvenile: 100%) Specificity 100% (Adult: 100%; Juvenile 100%; Chen et al. <sup>29</sup> )
Kijowski et al. <sup>26</sup>	Retrospective comparative 32 skeletally immature patients (36 juvenile OCD lesions) and 33 skeletally mature patients (34 adult OCD lesions) evaluated with MRI and arthroscopy. MR retrospectively reviewed by two radiologists to compare the sensitivity and specificity of De Smet criteria for the detection of instability. Sensitivity and specificity of the criteria were calculated separately for juvenile and adult OCD lesions.	Stage I: No interface, smooth cartilage surface Stage II: Low-signal interface between fragment and underlying bone on T2-weighted and 3D GRE images, partial cartilage tear Stage III: High-signal interface on T2-weighted and 3D GRE images, partial/complete cartilage tear Stage IV: High-signal interface on T2-weighted and low- or intermediate-signal interface on 3D GRE images (fluid at interface), complete cartilage tear Stage V: An osteochondral defect Type I: Epiphyseal Cartilage Lesion with necrotic center (no cleft at the interface), assessed on the Shortest-TE Image and T2* Map image Type II: Epiphyseal Cartilage Lesion with complete or incomplete rim calcification (cleft at the interface). Assessed on the shortest-TE image Type III: Partially or completely ossified lesion (varying degrees of osseous bridging and/or clefting at the interface). Assessed on the shortest-TE image Type IV: Healed osseous lesion with a linear bony scar (no cleft at the interface), no add-on sequence needed Type V: not-healed detached osseous lesion (Sequestrum), no add-on sequence needed Grade 1: Cartilage is intact without a breach in the cartilage <sup>a</sup> Grade 2: Cartilage is breached/fissured with a stable lesion. No displacement of the lesion <sup>a</sup> Grade 3: Cartilage is breached/fissured with an unstable lesion, defined by: <ol style="list-style-type: none"> <li>True fluid between lesion and base (signal equivalent to joint fluid on T2 image).</li> <li>Hinged lesion with partial displacement.</li> <li>Fully displaced (including loose body) lesion.</li> </ol>	Sensitivity 100% Specificity 100% (Kijowski et al. <sup>26</sup> )
Chen et al. <sup>29</sup>	Prospective case series Two independent radiologists reviewed MR images of 40 patients with knee OCD performed with 3D GRE MR sequence. All patients had arthroscopic surgery within 3 months of their MRI. Authors developed a new MRI and arthroscopic grading system for OCD.	Stage I: No interface, smooth cartilage surface Stage II: Low-signal interface between fragment and underlying bone on T2-weighted and 3D GRE images, partial cartilage tear Stage III: High-signal interface on T2-weighted and 3D GRE images, partial/complete cartilage tear Stage IV: High-signal interface on T2-weighted and low- or intermediate-signal interface on 3D GRE images (fluid at interface), complete cartilage tear Stage V: An osteochondral defect Type I: Epiphyseal Cartilage Lesion with necrotic center (no cleft at the interface), assessed on the Shortest-TE Image and T2* Map image Type II: Epiphyseal Cartilage Lesion with complete or incomplete rim calcification (cleft at the interface). Assessed on the shortest-TE image Type III: Partially or completely ossified lesion (varying degrees of osseous bridging and/or clefting at the interface). Assessed on the shortest-TE image Type IV: Healed osseous lesion with a linear bony scar (no cleft at the interface), no add-on sequence needed Type V: not-healed detached osseous lesion (Sequestrum), no add-on sequence needed Grade 1: Cartilage is intact without a breach in the cartilage <sup>a</sup> Grade 2: Cartilage is breached/fissured with a stable lesion. No displacement of the lesion <sup>a</sup> Grade 3: Cartilage is breached/fissured with an unstable lesion, defined by: <ol style="list-style-type: none"> <li>True fluid between lesion and base (signal equivalent to joint fluid on T2 image).</li> <li>Hinged lesion with partial displacement.</li> <li>Fully displaced (including loose body) lesion.</li> </ol>	Sensitivity 100% Specificity 100% (Adult: 100%; Juvenile 100%; Chen et al. <sup>29</sup> )
Ellermann et al. <sup>31</sup>	Retrospective case series. 13 patients (20 JOCD) evaluated 3T MRI (multi-echo gradient-recalled-echo sequence with the shortest echo time of 4 ms, T2* mapping). Authors developed a new MRI staging system for JOCD.	Stage I: No interface, smooth cartilage surface Stage II: Low-signal interface between fragment and underlying bone on T2-weighted and 3D GRE images, partial cartilage tear Stage III: High-signal interface on T2-weighted and 3D GRE images, partial/complete cartilage tear Stage IV: High-signal interface on T2-weighted and low- or intermediate-signal interface on 3D GRE images (fluid at interface), complete cartilage tear Stage V: An osteochondral defect Type I: Epiphyseal Cartilage Lesion with necrotic center (no cleft at the interface), assessed on the Shortest-TE Image and T2* Map image Type II: Epiphyseal Cartilage Lesion with complete or incomplete rim calcification (cleft at the interface). Assessed on the shortest-TE image Type III: Partially or completely ossified lesion (varying degrees of osseous bridging and/or clefting at the interface). Assessed on the shortest-TE image Type IV: Healed osseous lesion with a linear bony scar (no cleft at the interface), no add-on sequence needed Type V: not-healed detached osseous lesion (Sequestrum), no add-on sequence needed Grade 1: Cartilage is intact without a breach in the cartilage <sup>a</sup> Grade 2: Cartilage is breached/fissured with a stable lesion. No displacement of the lesion <sup>a</sup> Grade 3: Cartilage is breached/fissured with an unstable lesion, defined by: <ol style="list-style-type: none"> <li>True fluid between lesion and base (signal equivalent to joint fluid on T2 image).</li> <li>Hinged lesion with partial displacement.</li> <li>Fully displaced (including loose body) lesion.</li> </ol>	Sensitivity 100% Specificity 100% (Adult: 100%; Juvenile 100%; Chen et al. <sup>29</sup> )
Hussain et al. <sup>32</sup>	120 standardized knee MRIs of patients with knee evaluated, both for progression and location of the lesion. MRIs were independently classified by 2 readers into the novel, 4-part, and Nelson classification systems. Inter-rater and intra-rater agreements were reported.	Stage I: No interface, smooth cartilage surface Stage II: Low-signal interface between fragment and underlying bone on T2-weighted and 3D GRE images, partial cartilage tear Stage III: High-signal interface on T2-weighted and 3D GRE images, partial/complete cartilage tear Stage IV: High-signal interface on T2-weighted and low- or intermediate-signal interface on 3D GRE images (fluid at interface), complete cartilage tear Stage V: An osteochondral defect Type I: Epiphyseal Cartilage Lesion with necrotic center (no cleft at the interface), assessed on the Shortest-TE Image and T2* Map image Type II: Epiphyseal Cartilage Lesion with complete or incomplete rim calcification (cleft at the interface). Assessed on the shortest-TE image Type III: Partially or completely ossified lesion (varying degrees of osseous bridging and/or clefting at the interface). Assessed on the shortest-TE image Type IV: Healed osseous lesion with a linear bony scar (no cleft at the interface), no add-on sequence needed Type V: not-healed detached osseous lesion (Sequestrum), no add-on sequence needed Grade 1: Cartilage is intact without a breach in the cartilage <sup>a</sup> Grade 2: Cartilage is breached/fissured with a stable lesion. No displacement of the lesion <sup>a</sup> Grade 3: Cartilage is breached/fissured with an unstable lesion, defined by: <ol style="list-style-type: none"> <li>True fluid between lesion and base (signal equivalent to joint fluid on T2 image).</li> <li>Hinged lesion with partial displacement.</li> <li>Fully displaced (including loose body) lesion.</li> </ol>	Krippendorff's alpha for inter-rater agreement was 0.49 (95% CI = [0.32, 0.65]) The intra-rater agreement was 0.98 (95% CI = [0.94, 1.00]; Hussain et al. <sup>32</sup> )

OCD = Osteochondritis dissecans; JOCD = Juvenile Osteochondritis dissecans; GRE = gradient-echo.

<sup>a</sup>Fluid signal may be present in the form of bone marrow edema, defined as bright signal on T2-weighted imaging—but not the same density as joint fluid.



**Table 3. Arthroscopic Classifications.**

Article	Study design summary	Classification	Sensitivity, specificity, inter/intra-rater agreement
Guhl <sup>41</sup>	Prospective case series Authors arthroscopically treated 23 patients with OCD. They proposed an arthroscopic classification to give the right indication to the treatment.	Grade 1: Intact cartilage and subchondral bone Grade 2: Initial signs of fragment separation but fragment <i>in situ</i> , no mobile Grade 3: Partially detached mobile fragment <i>in situ</i> (flap lesion) Grade 4: Craters with loose bodies (salvageable or unsalvageable)	-
Ewing and Voco <sup>42</sup>	Prospective case series 29 patients were arthroscopically treated for OCD. Lesions were classified using a new grading system.	Grade 1: intact lesion (stable) Grade 2: lesion demonstrating early separation (stable) Grade 3: lesion partially attached (flap lesion, unstable) Grade 4: crater lesion with loose body (unstable)	-
Johnson et al. <sup>43</sup>	Prospective case series 35 knees were arthroscopically treated with compression screw fixation for OCD	Articular cartilage intact <ul style="list-style-type: none"> <li>• Fragment stable</li> <li>• Fragment mobile with compression</li> <li>• Articular cartilage separated (unstable)</li> <li>• Fragment <i>in situ</i></li> <li>• Fragment hinged (partially attached)</li> <li>• Fragment completely loose</li> </ul>	-
Nelson et al. <sup>29</sup> Dipaola et al. <sup>30</sup>	Prospective case series 12 patients with osteochondral lesions of either the knee or talus were studied using MRI prior to arthroscopic treatment. They developed a new staging system for osteochondral lesions	Grade/Stage 0: Intact cartilage (stable) Grade/Stage 1: Focal area of softening, fibrillation and fissure of articular cartilage, no definable fragment (stable) Grade/Stage 2: Articular cartilage breached with non-mobilizable fragment (stable) Grade/Stage 3: Articular cartilage breached with mobilizable fragment, partially attached, flap lesion (unstable) Grade/Stage 4: Completely detached fragment, free intra-articular body (unstable)	-
Brun <sup>23</sup>	Review of literature and proposal of a radiographic, arthroscopic and MRI staging system	Stage I: Cartilage intact, mechanically normal Stage II: Cartilage intact, mechanically possible indentation or circular cartilage demarcation Stage III D: Fragment dissected <i>in situ</i> , can be passed under with a hook, partial fixation of the OCD, possible synovitis Stage III M: like III D; Cartilage thinly in several parts and changed (malicious, softened) Stage IV D: Fragment bed empty, cartilage edge rounded, frayed, OCD fragment floating freely, synovitis Stage IV M: like IV D, possibly still cartilage parts at the defect edge Grade 1: Irregularity and softening of articular cartilage, no fissures or definable fragments (stable) Grade 2: Fissuring of the cartilage with non-mobile fragment (stable) Grade 3: Dislocable but still partially attached fragment (flap lesion, unstable) Grade 4: Intra-articular loose body and defect on the joint surface (unstable)	-
O'Connor et al. <sup>25</sup>	Retrospective case series Patients who undergone both MRI and arthroscopy were reviewed. The authors revisited the Guhl's classification to correlate MRI findings with arthroscopic findings.	Grade 1: stable with continuity; softened area covered by intact cartilage Grade 2: partial discontinuity; stable on probing Grade 3: complete discontinuity; "dead in situ"; not dislocated Grade 4: dislocated fragment; loose within bed or empty defect	-
Britberg and Winalski <sup>44</sup>	A state-of-the-art system for clinical cartilage evaluation and imaging assessment is presented. A working group of ICRS developed a new classification system of OCD.	All the grades are divided into 2 subgroups: A for lesion less deep than 10 mm, B for lesions deeper than 10 mm. Stage 1: Intact but partially soft and cartilage Stage 2: Overlying cartilage fissure Stage 3: Exposed bone or attached fragment Stage 4: Partially detached fragment Stage 5: Craters with loose bodies	-
Chen et al. <sup>39</sup>	Prospective case series Two independent radiologists reviewed MR images of 40 patients with knee OCD performed with 3D GRE MR sequence. All patients had arthroscopic surgery within 3 months of their MRI. Authors developed a new MRI and arthroscopic grading system for OCD.	Stage 1 (CUE BALL): No abnormality detectable arthroscopically (not mobile) Stage 2 (SHADOW): Cartilage is intact and subtly demarcated (not mobile) Stage 3 (WRINKLE IN THE RUG): Cartilage is demarcated with a fissure, buckle, and/or wrinkle (not mobile) Stage 4 (LOCKED DOOR): Cartilage fissuring at periphery, unable to hinge open (mobile) Stage 5 (TRAP DOOR): Cartilage fissuring at periphery, able to hinge open (mobile) Stage 6 (CRATER): Exposed subchondral bone defect (mobile)	Inter-observer reliability: 94%-95%; Intra-observer reliability: 96% (Carey et al. <sup>45</sup> )
Chen et al. <sup>45</sup>	Prospective case series Thirty representative arthroscopic videos were evaluated by 10 orthopedic surgeon raters, who classified each lesion. After 4 wk, the raters again classified the OCD lesions depicted in the 30 videos in a randomly selected order. Authors developed a classification system for arthroscopic evaluation of OCD of the knee that includes 6 arthroscopic categories: 3 immobile types and 3 mobile types.		

OCD = Osteochondritis dissecans; ICRS = International Cartilage Repair Society; GRE = gradient-echo.

unstable lesions (Grades 3 and 4). *Guhl's* classification laid the foundation for the formulation of the subsequent arthroscopic classifications which present overlapping aspects, like the similar one proposed in 1988 by Ewing and Voto.<sup>42</sup> In 1990, Johnson *et al.*<sup>43</sup> classified OCD in 3 different diagnostic groups (stable, unstable, loose body) with further division related to the integrity of articular cartilage and the separation of the fragment. In the same year, Nelson *et al.*<sup>29</sup> modulated the OCD classification system proposed by Pritsch *et al.* for talar lesions<sup>40</sup> and formulated a more detailed graduation system ranging from Grade 0 (normal cartilage) to Grade 4 (detached fragment with intra-articular loose body), which also found a correspondence with the parallel MRI classification developed in the same study.<sup>29</sup> The following year, Dipaola *et al.*<sup>30</sup> further elaborated this classification and its correlation with the MRI findings. Bruns in 1997,<sup>23</sup> O'Connor *et al.* in 2002,<sup>25</sup> and Chen *et al.* in 2013<sup>39</sup> also revised previous classification systems, correlating arthroscopic findings with new or already described MRI classification systems.

In 2003, to address the need for standardized and universally accepted classification systems in cartilage pathology, the International Cartilage Repair Society (ICRS, currently International Cartilage Regeneration & Joint Preservation Society) published a staging system specific for OCD lesions of the knee.<sup>44</sup> This system, described by Brittberg and Winalsky, included 4 stages, each one consisting in 2 subgroups, A and B, for lesions, respectively, inferior or superior to 10 mm in depth. Finally, in 2016, Carey and other members of the Research in OsteoChondritis of the Knee (ROCK) group<sup>45</sup> developed a new staging system with the aim of making classification easier and more reproducible. Their staging system includes 6 categories: 3 types of lesions are considered non-mobile and 3 mobile. To improve understanding, applicability, and reproducibility, every type of lesion was named with an easy name to remember providing a simple description of the arthroscopic appearance. Helpful instructions to distinguish "borderline" lesions were also provided. Moreover, this classification was also assessed for its reliability, demonstrating an excellent inter-observer and intra-observer reliability, respectively, 0.95 and 0.96.<sup>45</sup>

### Application of OCD Classifications

The search found 193 clinical studies applying at least one OCD classification, for a total of 7,299 OCD cases in the knee joint. The number of cases described in the articles ranged between  $n = 1$  and  $n = 892$  with a mean of 38 OCD knee lesions examined per study. Along with the overall increase in publication numbers, many proposed classifications have been increasingly used, with the ICRS classification system rising in the last two decades and currently being the main reference in OCD literature (**Fig. 2**).

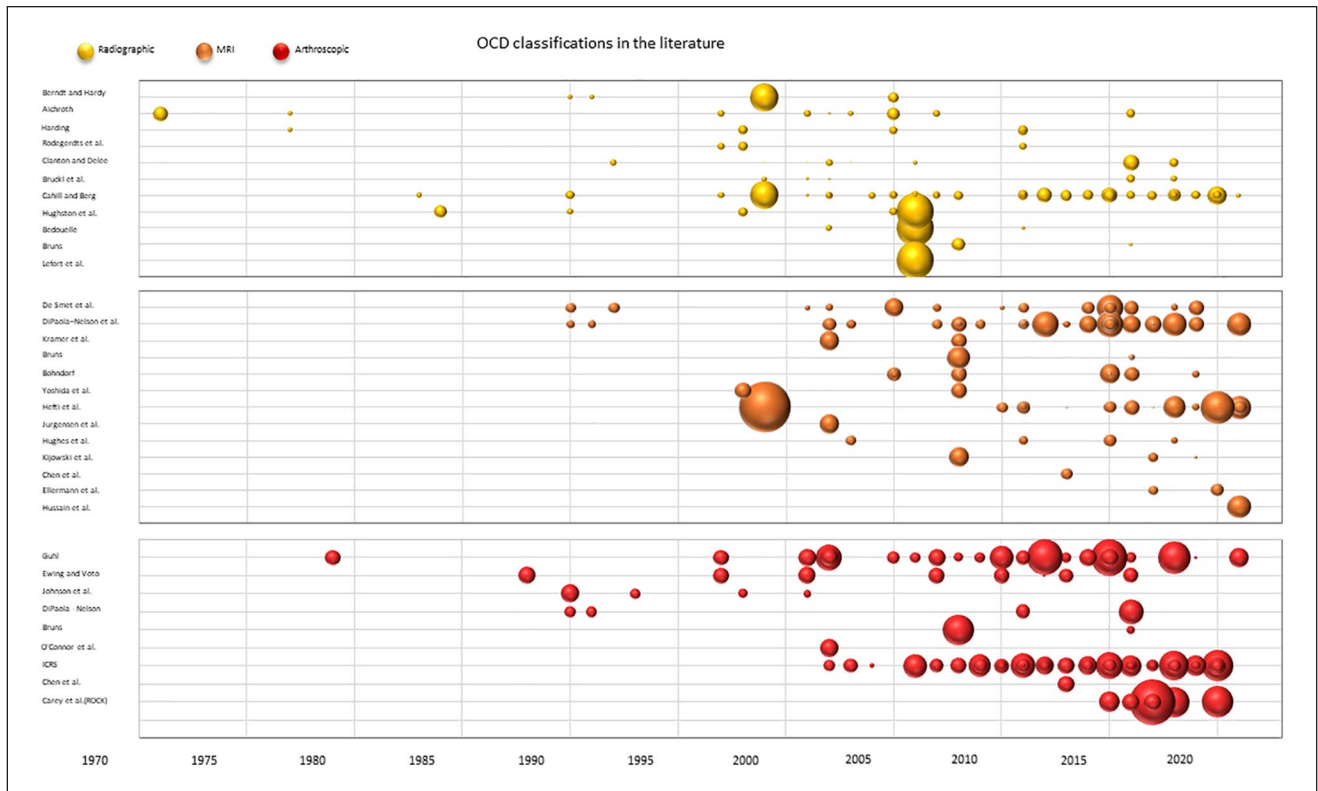
**X-ray classifications.** Radiographic classifications were widely adopted in the past decades and are still used. A total of 69 studies on 4,105 OCD cases (56.2% of the OCD examined) used at least one radiographic classification. *Cahill and Berg* classification was the most adopted, being reported in 36 studies (18.6%) on 2,053 knees (28.1% of the overall OCD literature cases examined). *Hughston* classification was applied in 5 studies and 1,097 cases (15.0%). *Bedouelle* classification was used in 3 studies and 924 cases (12.7%). The recently introduced *Lefort* classification was described in a multicentric study involving 892 OCD cases (12.2%). Other x-ray classifications were documented in less patients: *Aichroth* classification and *Clanton and DeLee* classification were both used in 9 studies, for 386 (6.0%) and 260 (4.2%) cases, respectively, and *Bruckl et al.* in 6 studies and 90 (1.4%) cases (see **Fig. 2** for more details).

**MRI classifications.** A total of 68 studies reporting on 2,959 (40.5%) of the lesions examined in this review employed at least one MRI classification. *Nelson et al.* and *Dipaola et al.* classification was the most frequently adopted being used in 26 studies on 1,082 OCD patients corresponding to 14.8% of the examined cases. The first described *De Smet* MRI criteria were adopted in 14 studies and 462 patients (6.3% of the cases). The *Hefti et al.* classification was used in 13 studies reporting on 1,113 OCDs (15.2% of the cases). Other classifications based on MRI were used less, as *Bohndorf* classification with 8 studies on 230 (3.1%) cases, and *Hughes et al.* classification with 4 studies on 77 (1.0%) cases (see **Fig. 2** for more details).

**Arthroscopic classifications.** A total of 124 studies (64.2%) corresponding to 3,511 (48.1%) of the lesions examined in this review resulted to be classified with at least one arthroscopic classification. Among the included studies, 67 (34.7%) employed the *ICRS system* for grading a total of 1,549 knees OCD lesions corresponding to 21.2% of the cases examined. Other arthroscopic classification systems also resulted to be frequent in the reviewed literature. *Guhl's* classification was used in 33 studies and 1,028 knees, which represents 14.0% of the cases examined. The *Ewing and Voto* classification was used in 9 studies for grading 197 lesions (2.7%). The classification introduced in 2016 by the *ROCK* study group was used in 7 studies for a total of 566 lesions (7.7% of the cases; see **Fig. 2** for more details).

### Discussion

The main finding of this study is that many knee OCD classification systems have been described, with the ICRS classification being the most used one, but many others are still commonly applied, based on radiographic, MRI, or arthroscopic OCD features.



**Figure 2.** OCD classifications in the literature. The figure shows the use of all OCD classifications in the literature over time. Each bubble represents a clinical study where the respective classification is used and the size of the bubble proportionally represents the number of patients included in the study. OCD = Osteochondritis dissecans.

The ideal OCD classification system should offer a precise and reliable grading of the lesion based on the clear description of lesion characteristics and allow the diagnosis in the early phases to avoid treatment delay. Moreover, it should be able to identify lesions with high risk of fragmentation and osteochondral detachment, defining the healing potential and therefore guiding either the conservative management or the surgical treatment.<sup>46</sup> The different classification systems converge to the final scenario of fragment detachment, which requires surgical treatment of refixation, excision, or reconstruction of the defect, while limits the possibility to rely on a bone marrow stimulation procedure (e.g., retro- or anterograde drilling).<sup>36,47</sup> More challenging is the definition of the different earlier phases characterizing OCD pathology, where one of the key parameters is the stability of the OCD lesion, as this could determine the evolution toward healing or progression.<sup>27,28,48,49</sup> In fact, while stable lesions, typical of JOCD, can be treated conservatively, unstable lesions often require surgical management.<sup>7</sup>

The term “stability” was used in 1987 by Mesgarzadeh *et al.*<sup>50</sup> to refer to the mechanical integrity of the subchondral OCD lesion. In their study, the authors compared plain radiographs, scintigraphy, and MRI to determine the best

way to assess the stability of OCD lesions. Bone scintigraphy and MR imaging were considered preferable diagnostic modalities for evaluating the mechanical status of OCD lesions.<sup>14,50,51</sup> Still, some characteristics on plain x-rays have been associated with an increased risk of instability: larger lesion size, minimal subchondral bone on the progeny fragment, and increased thickness of the sclerotic rim,<sup>52</sup> and some authors<sup>24,53</sup> suggested that the need for an MRI could be based on specific radiographic features. According to Lefort *et al.*,<sup>24</sup> Grade I OCD with open physes does not require first-line imaging studies other than radiographs, while criteria for MRI are Grade II or III, surface area greater than 350 mm<sup>2</sup>, or closed physes.<sup>53</sup> In 2015 and 2017, the ROCK study group<sup>54,55</sup> evaluated different radiographic features with the aim of identifying the best parameters to be used effectively in the diagnosis and treatment choice of knee OCD lesions. They concluded that many diagnostic features of femoral condyle lesions can be reliably classified on plain radiographs, such as detachment of the fragment, growth plate maturity, condylar width, lesion size, fragmentation, displacement, boundary, central radiodensity, and contour.<sup>54,55</sup> In their studies, they found excellent inter-rater reliability when judging the overall healing of OCD femoral condyle lesions on radiographs as well as on

5 specific features (boundary, sclerosis, size, shape, and ossification). Building upon these findings, Ramski *et al.*, in 2017, proposed a radiographic grading of healing types for OCD lesions that demonstrated good inter- and intra-observer reliability.<sup>56</sup> These authors retrospectively reviewed 41 consecutive knee OCD lesions treated by a single surgeon and radiographically classified healing patterns such as boundary resolution, increasing radiodensity of progeny fragment, combined or not applicable. Still, radiographic classifications present undeniable limitations, mainly related to the poor early diagnosis and a suboptimal lesion stability evaluation. Nowadays, they are mostly used to describe the location of the lesion or the healing status, while their application for assessing lesion severity and stability is indeed considered less informative.

The gold standard for assessing the stability of knee OCD is the arthroscopic evaluation. This approach allows to study the entire joint and to treat OCD defect and associated lesions in the same surgical step. Nonetheless, in young patients, cracks or mobility may be absent due to the thick cartilage layer overlying the fragment, thus arthroscopic signs of instability could arise later than MRI signs.<sup>53</sup> Moreover, arthroscopy has the limitation of not being able to evaluate the subchondral bone, and it is an invasive procedure with related risks, which questions its use as diagnostic tool. Rather, it should be the last step of a more complex algorithm for OCD management, being indicated when surgical procedures are required and when a precise clinical and imaging diagnose has been made, mostly by the use of MRI. This systematic review presented the large number of arthroscopic classifications described in the literature, highlighting the lack of standardization and of data regarding their reliability. In fact, only the ROCK arthroscopic classification has been evaluated for its intra- and inter-observer reliability, demonstrating excellent results.<sup>45</sup> Despite being formulated only in 2016, the ROCK classification is increasingly applied, and its use already reached 9% of the OCD cases classified in the literature. Still, nowadays the most used is the ICRS arthroscopic classification,<sup>44</sup> which has been applied in more than one third of the studies. First described in 2003, this classification was developed as an arthroscopic grading system. However, the defined criteria have been largely accepted and sometimes exploited also for the imaging evaluation,<sup>57</sup> which presents several advantages that overcome the limitations of arthroscopic systems.

MRI is a noninvasive approach to study OCD lesions, and it is arguably the best tool for detecting the early presence of OCD, identifying stable lesions that arthroscopy may miss.<sup>26,57-60</sup> The primary aim of all MRI classifications is to determine the stability or instability of the lesion. Several MRI features were associated with instability, like loose bodies, cysts in the subchondral bone, breaches through the articular cartilage overlying the OCD fragment,

and a line of high-intensity signal between progeny fragment and parent bone on T2-weighted images.<sup>25,28,34,61</sup> However, this signal may also represent a healing reaction,<sup>25,34,35</sup> with the risk of misinterpreting the lesion stability and thus misleading toward the need for surgery. In the last years, more specific MRI protocols have been introduced to better distinguish stable and unstable MRI lesions. To this regard, on 3D GRE MR imaging with spectral fat suppression,<sup>62,63</sup> the articular cartilage appears bright while fluid is dark to intermediate, helping in differentiating fluid from granulation tissue. Chen *et al.*<sup>39</sup> demonstrated excellent diagnostic capabilities in detecting unstable OCD lesions combining routine sequences with 3D GRE T1-weighted MR imaging. These good results were confirmed for both adult and JOCD, with excellent accuracy and reliability, overcoming the previous findings of Kijowski *et al.*<sup>26</sup> who stated that MRI was not reliable in predicting the stability of OCD prior to skeletal maturity.

The evaluation and classification of JOCD has been the focus of other authors. To quantify the healing potential in juvenile subjects, Wall *et al.*<sup>27</sup> evaluated the influence of different variables (patient age, lesion size, lesion location, knee symptoms, and sex) on a non-operative treatment protocol for JOCD. They developed a system “nomogram” including normalized length and width of the lesions and the presence of mechanical symptoms to predict the probability of spontaneous healing. The latest JOCD classification, published in 2016, by Ellermann *et al.*, focused instead on the staging of the natural history of a JOCD lesion, proposing an etiopathogenetic hypothesis in which focal failure of endochondral ossification and epiphyseal cartilage ischemia would lead to a type I entirely cartilaginous lesion as the earliest disease manifestation.<sup>31</sup> While this hypothesis awaits further confirmation, it is worth noticing how the overall debate on the very causes of this disease remains open.<sup>64</sup> The lack of knowledge on key aspects of disease development and progression, as well as response to treatment, may limit the possibility for an optimal and effective management of OCD patients. Further work will be needed to define reliable characteristics to predict clinical lesion instability and prognosis.<sup>65</sup>

A useful tool to better characterize OCD and investigate the healing prognosis can be represented by nuclear medicine imaging (CT-SPECT and PET-scan), as demonstrated in some studies on the follow-up of OCD.<sup>66,67</sup> However, there is a drawback represented by the relatively high dose of radiation to the patients, which currently makes the presence of clinical studies on this topic limited. Thus, based on the available literature, an initial x-ray can be considered useful to assess both severity and location, focusing on the radiographic features described and validated by the ROCK group,<sup>14,54,55</sup> followed by an MRI evaluation performed with specific sequences to analyze the stability and

hypothesize the prognosis.<sup>33,39,65</sup> While the aforementioned approaches provide important information, the arthroscopic procedure remains the gold standard to evaluate OCD stability. In this setting, the lesions can be classified with ICRS and ROCK classifications,<sup>44,45</sup> to better characterize OCDs and plan the treatment accordingly.

This study has some limitations, especially in the terms of representing the overall use of classification systems in the literature. In fact, the search focused on papers specifically referring to OCD classifications, thus not including those using other criteria not pertaining to OCD classifications. This hindered the possibility to quantify completely the application of criteria to classify and manage OCD in the current practice. Another limitation may be the absence of comparative evaluations of the quality of the classification systems to define the most suitable ones. Moreover, only a few studies assessed the effectiveness of the proposed methods by evaluating accuracy or reliability, and the prognostic value also remains unclear. Thus, further studies are needed to better understand the value of each available classification system. Nevertheless, this review defined some trends in the literature, and the results allowed to draw meaningful considerations.

Several classification systems based on radiographs, MRI, and arthroscopy have been proposed over the years to classify OCD location or severity, focusing on key features to assess lesion stability and healing potential. Arthroscopy, using the ICRS or the more recent ROCK classifications, remains the gold standard to confirm lesion stability while offering the possibility to directly perform the surgical treatment. However, noninvasive imaging approaches are the first line evaluation to guide patient management. Among these, nowadays radiographic classifications are superseded by MRI because of its capability to detect the earliest stages of the disease and to distinguish stable from unstable lesions, and thus to define the most suitable conservative or surgical approach to manage patients affected by knee OCD.

### Acknowledgments and Funding

The author(s) received no financial support for the research, authorship, and/or publication of this article.

### Declaration of Conflicting Interests

The author(s) declared the following potential conflicts of interest with respect to the research, authorship, and/or publication of this article: James L Carey is in the board or committee member of International Cartilage Repair Society; is a paid consultant for JRF Ortho (USA) and Vericel Corporation (USA); received research support from Ossur (Iceland) and Vericel Corporation (USA); is in the editorial or governing board of The American Journal of Sports Medicine. All the other authors declare that they have no potential conflicts of interest regarding the publication of this paper.

### Ethical Approval

Ethical approval was not sought for the present study because it is a systematic review and does not directly involve patients.

### ORCID iDs

Luca Andriolo  <https://orcid.org/0000-0001-6352-9671>

Luca Solaro  <https://orcid.org/0000-0001-5786-9602>

### References

- Edmonds EW. Editorial Commentary: osteochondritis dissecans of the knee: the great confounder. *Arthroscopy*. 2020;36(3):795-6. doi:10.1016/j.arthro.2019.10.041.
- Marsden C, Wiernik G. The incidence of osteochondritis dissecans. *J R Army Med Corps*. 1956;102(2):124-30. <http://www.ncbi.nlm.nih.gov/pubmed/13346738>.
- Kessler JI, Nikizad H, Shea KG, Jacobs JC Jr, Bechuk JD, Weiss JM. The demographics and epidemiology of osteochondritis dissecans of the knee in children and adolescents. *Am J Sports Med*. 2014;42(2):320-6. doi:10.1177/0363546513510390.
- Sanders TL, Pareek A, Johnson NR, Carey JL, Maak TG, Stuart MJ, et al. Nonoperative management of osteochondritis dissecans of the knee: progression to osteoarthritis and arthroplasty at mean 13-year follow-up. *Orthop J Sports Med*. 2017;5(7):2325967117704644. doi:10.1177/2325967117704644.
- Weiss JM, Shea KG, Jacobs JC Jr, Cannamela PC, Becker I, Portman M, et al. Incidence of osteochondritis dissecans in adults. *Am J Sports Med*. 2018;46(7):1592-5. doi:10.1177/0363546518764676.
- Andriolo L, Candrian C, Papio T, Cavicchioli A, Perdisa F, Filardo G. Osteochondritis dissecans of the knee—conservative treatment strategies: a systematic review. *Cartilage*. 2019;10(3):267-77. doi:10.1177/1947603518758435.
- Filardo G, Andriolo L, Soler F, Berruto M, Ferrua P, Verdonk P, et al. Treatment of unstable knee osteochondritis dissecans in the young adult: results and limitations of surgical strategies—the advantages of allografts to address an osteochondral challenge. *Knee Surg Sports Traumatol Arthrosc*. 2019;27(6):1726-38. doi:10.1007/s00167-018-5316-5.
- Carey JL, Grimm NL. Treatment algorithm for osteochondritis dissecans of the knee. *Orthop Clin North Am*. 2015;46(1):141-6. doi:10.1016/j.ocl.2014.09.010.
- Crawford DC, Safran MR. Osteochondritis dissecans of the knee. *J Am Acad Orthop Surg*. 2006;14(2):90-100. doi:10.5435/00124635-200602000-00004.
- Detterline AJ, Goldstein JL, Rue JP, Bach BR Jr. Evaluation and treatment of osteochondritis dissecans lesions of the knee. *J Knee Surg*. 2008;21(2):106-15.
- Tarabella V, Filardo G, Di Matteo B, Andriolo L, Tomba P, Viganò A, et al. From loose body to osteochondritis dissecans: a historical account of disease definition. *Joints*. 2016;4(3):165-70.
- Jacobs JC Jr, Archibald-Seiffer N, Grimm NL, Carey JL, Shea KG. A review of arthroscopic classification systems for osteochondritis dissecans of the knee. *Clin Sports Med*. 2014;33(2):189-97. doi:10.1016/j.csm.2013.11.005.

13. Moher D, Shamseer L, Clarke M, Ghersi D, Liberati A, Petticrew M, *et al.* Preferred reporting items for systematic review and meta-analysis protocols (Prisma-P) 2015 statement. *Syst Rev.* 2015;4:1. doi:10.1186/2046-4053-4-1.
14. Cahill BR, Berg BC. 99m-technetium phosphate compound joint scintigraphy in the management of juvenile osteochondritis dissecans of the femoral condyles. *Am J Sports Med.* 1983;11(5):329-35.
15. Berndt AL, Harty M. Transchondral fractures (osteochondritis dissecans) of the talus. *J Bone Joint Surg Am.* 1959;41-A:988-1020. <http://www.ncbi.nlm.nih.gov/pubmed/13849029>.
16. Aichroth P. Osteochondritis dissecans of the knee. A clinical survey. *J Bone Joint Surg Br.* 1971;53(3):440-7.
17. Harding WG, 3rd. Diagnosis of osteochondritis dissecans of the femoral condyles: the value of the lateral x-ray view. *Clin Orthop Relat Res.* 1977(123):25-6. <http://www.ncbi.nlm.nih.gov/pubmed/852179>.
18. Rodegerdts U, Gleißner S. Langzeiterfahrungen mit der operativen Therapie der Osteochondrosis dissecans des Kniegelenkes. *Orthop Praxis.* 1979;8:612-22.
19. Clanton TO, DeLee JC. Osteochondritis dissecans. History, pathophysiology and current treatment concepts. *Clin Orthop Relat Res.* 1982(167):50-64. <http://www.ncbi.nlm.nih.gov/pubmed/6807595>.
20. Brückl R, Rosemeyer B, Thiermann G. [Results of operative treatment of osteochondrosis dissecans of the knee joint in juveniles]. *Z Orthop Ihre Grenzgeb.* 1982;120(5):717-24.
21. Hughston JC, Hergenroeder PT, Courtenay BG. Osteochondritis dissecans of the femoral condyles. *J Bone Joint Surg Am.* 1984;66(9):1340-8.
22. Bedouelle J. L'osteochondrite disséquante des condyles fémoraux chez l'enfant et l'adolescent. *Cahiers d'enseignement de la S.O.F.C.O.T, Conférences d'enseignement. Exp Scient Fr Paris.* 1988;17:61-73.
23. Bruns J. [Osteochondrosis Dissecans]. *Orthopade.* 1997;26(6):573-84. doi:10.1007/PL00003414.
24. Lefort G, Moyen B, Beaufils P, de Billy B, Breda R, Cadilhac C, *et al.* Osteochondritis dissecans of the femoral condyles: report of 892 cases. *Rev Chir Orthop Reparatrice Appar Mot.* 2006;92(5 Suppl):2S97-141.
25. O'Connor MA, Palaniappan M, Khan N, Bruce CE. Osteochondritis dissecans of the knee in children. A comparison of MRI and arthroscopic findings. *J Bone Joint Surg Br.* 2002;84(2):258-62.
26. Kijowski R, Blankenbaker DG, Shinki K, Fine JP, Graf BK, De Smet AA. Juvenile versus adult osteochondritis dissecans of the knee: appropriate MR imaging criteria for instability. *Radiology.* 2008;248(2):571-8. doi:10.1148/radiol.2482071234.
27. Wall EJ, Vourazeris J, Myer GD, Emery KH, Divine JG, Nick TG, *et al.* The healing potential of stable juvenile osteochondritis dissecans knee lesions. *J Bone Joint Surg Am.* 2008;90(12):2655-64. doi:10.2106/JBJS.G.01103.
28. De Smet AA, Fisher DR, Graf BK, Lange RH. Osteochondritis dissecans of the knee: value of mr imaging in determining lesion stability and the presence of articular cartilage defects. *AJR Am J Roentgenol.* 1990;155(3):549-53.
29. Nelson DW, Dipaola J, Colville M, Schmidgall J. Osteochondritis dissecans of the talus and knee: prospective comparison of MR and arthroscopic classifications. *J Comput Assist Tomogr.* 1990;14(5):804-8.
30. Dipaola JD, Nelson DW, Colville MR. Characterizing osteochondral lesions by magnetic resonance imaging. *Arthroscopy.* 1991;7(1):101-4.
31. Ellermann J, Johnson CP, Wang L, Macalena JA, Nelson BJ, LaPrade RF. Insights into the epiphyseal cartilage origin and subsequent osseous manifestation of juvenile osteochondritis dissecans with a modified clinical MR imaging protocol: a pilot study. *Radiology.* 2017;282(3):798-806. doi:10.1148/radiol.2016160071.
32. Hussain ZB, Mathew ST, Feroe AG, Lins LAB, Miller P, Kocher MS. Novel magnetic resonance imaging classification of osteochondritis dissecans of the knee: a reliability study. *J Pediatr Orthop.* 2021;41(6): e422-6. doi:10.1097/BPO.0000000000001814.
33. Kramer J, Stiglbauer R, Engel A, Prayer L, Imhof H. MR Contrast Arthrography (MRA) in osteochondrosis dissecans. *J Comput Assist Tomogr.* 1992;16(2):254-60.
34. Bohndorf K. Osteochondritis (osteochondrosis) dissecans: a review and new MRI classification. *Eur Radiol.* 1998;8(1):103-12.
35. Yoshida S, Ikata T, Takai H, Kashiwaguchi S, Katoh S, Takeda Y. Osteochondritis dissecans of the femoral condyle in the growth stage. *Clin Orthop Relat Res.* 1998(346):162-70.
36. Hefti F, Beguiristain J, Krauspe R, Moller-Madsen B, Riccio V, Tschauner C, *et al.* Osteochondritis dissecans: a multi-center study of the European Pediatric Orthopedic Society. *J Pediatr Orthop B.* 1999;8(4):231-45.
37. Jurgensen I, Bachmam G, Schleicher I, Haas H. [Osteochondritis dissecans—an easy classification in MRI]. *Z Orthop Ihre Grenzgeb.* 2002;140(1):58-64.
38. Hughes JA, Cook JV, Churchill MA, Warren ME. Juvenile osteochondritis dissecans: a 5-year review of the natural history using clinical and MRI evaluation. *Pediatr Radiol.* 2003;33(6):410-7.
39. Chen CH, Liu YS, Chou PH, Hsieh CC, Wang CK. MR grading system of osteochondritis dissecans lesions: comparison with arthroscopy. *Eur J Radiol.* 2013;82(3):518-25. doi:10.1016/j.ejrad.2012.09.026.
40. Pritsch M, Horoshovski H, Farine I. Arthroscopic treatment of osteochondral lesions of the talus. *J Bone Joint Surg Am.* 1986;68(6):862-5.
41. Guhl JF. Arthroscopic treatment of osteochondritis dissecans: preliminary report. *Orthop Clin North Am.* 1979;10(3):671-83. <http://www.ncbi.nlm.nih.gov/pubmed/460840>.
42. Ewing JW, Voto SJ. Arthroscopic surgical management of osteochondritis dissecans of the knee. *Arthroscopy.* 1988;4(1):37-40.
43. Johnson LL, Uitvlugt G, Austin MD, Detrisac DA, Johnson C. Osteochondritis dissecans of the knee: arthroscopic compression screw fixation. *Arthroscopy.* 1990;6(3):179-89.
44. Brittberg M, Winanski CS. Evaluation of Cartilage Injuries and Repair. *J Bone Joint Surg Am.* 2003;85-A(Suppl 2):58-69.

45. Carey JL, Wall EJ, Grimm NL, Ganley TJ, Edmonds EW, Anderson AF, *et al.* Novel arthroscopic classification of osteochondritis dissecans of the knee: a multicenter reliability study. *Am J Sports Med.* 2016;44(7):1694-8. doi:10.1177/0363546516637175.
46. Jones MH, Williams AM. Osteochondritis dissecans of the knee: a practical guide for surgeons. *Bone Joint J.* 2016;98-B(6):723-9. doi:10.1302/0301-620X.98B6.36816.
47. Cahill BR, Phillips MR, Navarro R. The results of conservative management of juvenile osteochondritis dissecans using joint scintigraphy. A prospective study. *Am J Sports Med.* 1989;17(5):601-5605.
48. De Smet AA, Ilahi OA, Graf BK. Untreated osteochondritis dissecans of the femoral condyles: prediction of patient outcome using radiographic and MR findings. *Skeletal Radiol.* 1997;26(8):463-7.
49. Kocher MS, Micheli LJ, Yaniv M, Zurakowski D, Ames A, Adrignolo AA. Functional and radiographic outcome of juvenile osteochondritis dissecans of the knee treated with transarticular arthroscopic drilling. *Am J Sports Med.* 2001;29(5):562-6.
50. Mesgarzadeh M, Sapega AA, Bonakdarpour A, Revesz G, Moyer RA, Maurer AH, *et al.* Osteochondritis dissecans: analysis of mechanical stability with radiography, scintigraphy, and MR. *Radiology.* 1987;165(3):775-80.
51. Cahill B. Treatment of juvenile osteochondritis dissecans and osteochondritis dissecans of the knee. *Clin Sports Med.* 1985;4(2):367-84.
52. Carey JL, Ganley TJ, Grimm NL. Osteochondritis dissecans in the knee: treatment algorithms. In: Carey JL, editor. *Osteochondritis dissecans—monograph series.* American Academy of Orthopaedic Surgeons; 2015. p. 15-22.
53. Accadbled F, Vial J, Sales de Gauzy J. Osteochondritis dissecans of the knee. *Orthop Traumatol Surg Res.* 2018;104(1S):S97-105. doi:10.1016/j.otsr.2017.02.016.
54. Wall EJ, Polousky JD, Shea KG, Carey JL, Ganley TJ, Grimm NL, *et al.* Novel radiographic feature classification of knee osteochondritis dissecans: a multicenter reliability study. *Am J Sports Med.* 2015;43(2):303-9. doi:10.1177/0363546514566600.
55. Wall EJ, Milewski MD, Carey JL, Shea KG, Ganley TJ, Polousky JD, *et al.* The reliability of assessing radiographic healing of osteochondritis dissecans of the knee. *Am J Sports Med.* 2017;45(6):1370-5. doi:10.1177/0363546517698933.
56. Ramski DE, Ganley TJ, Carey JL. A radiographic healing classification for osteochondritis dissecans of the knee provides good interobserver reliability. *Orthop J Sports Med.* 2017;5(12):2325967117740846. doi:10.1177/2325967117740846.
57. Ellermann JM, Donald B, Rohr S, Takahashi T, Tompkins M, Nelson B, *et al.* Magnetic resonance imaging of osteochondritis dissecans: validation study for the ICRS classification system. *Acad Radiol.* 2016;23(6):724-9. doi:10.1016/j.acra.2016.01.015.
58. Quatman CE, Quatman-Yates CC, Schmitt LC, Paterno MV. The clinical utility and diagnostic performance of MRI for identification and classification of knee osteochondritis dissecans. *J Bone Joint Surg Am.* 2012;94(11):1036-44. doi:10.2106/JBJS.K.00275.
59. Luhmann SJ, Schootman M, Gordon JE, Wright RW. Magnetic resonance imaging of the knee in children and adolescents. Its role in clinical decision-making. *J Bone Joint Surg Am.* 2005;87(3):497-502.
60. Kocher MS, DiCanzio J, Zurakowski D, Micheli LJ. Diagnostic performance of clinical examination and selective magnetic resonance imaging in the evaluation of intraarticular knee disorders in children and adolescents. *Am J Sports Med.* 2001;29(3):292-6.
61. De Smet AA, Ilahi OA, Graf BK. Reassessment of the MR criteria for stability of osteochondritis dissecans in the knee and ankle. *Skeletal Radiol.* 1996;25(2):159-63.
62. Cicutini F, Forbes A, Asbeutah A, Morris K, Stuckey S. Comparison and reproducibility of fast and conventional spoiled gradient-echo magnetic resonance sequences in the determination of knee cartilage volume. *J Orthop Res.* 2000;18(4):580-4.
63. Eckstein F, Westhoff J, Sittek H, Maag KP, Haubner M, Faber S, *et al.* In vivo reproducibility of three-dimensional cartilage volume and thickness measurements with MR imaging. *AJR Am J Roentgenol.* 1998;170(3):593-7.
64. Andriolo L, Crawford DC, Reale D, Zaffagnini S, Candrian C, Cavicchioli A, *et al.* Osteochondritis dissecans of the knee: etiology and pathogenetic mechanisms. A systematic review. *Cartilage.* 2020;11(3):273-90. doi:10.1177/1947603518786557.
65. Fabricant PD, Milewski MD, Kostyun RO, Wall EJ, Zbojniec AM, Research in Osteochondritis of the Knee (ROCK) Study Group, *et al.* Osteochondritis dissecans of the knee: an interrater reliability study of magnetic resonance imaging characteristics. *Am J Sports Med.* 2020;48(9):2221-9. doi:10.1177/0363546520930427.
66. Konala P, Iranpour F, Kerner A, Rasch H, Friederich NF, Hirschmann MT. Clinical benefit of SPECT/CT for follow-up of surgical treatment of osteochondritis dissecans. *Ann Nucl Med.* 2010;24(8):621-4. doi:10.1007/s12149-010-0391-9.
67. Hirschmann MT, Davda K, Rasch H, Arnold MP, Friederich NF. Clinical value of combined single photon emission computerized tomography and conventional computer tomography (SPECT/CT) in sports medicine. *Sports Med Arthrosc Rev.* 2011;19(2):174-81. doi:10.1097/JSA.0b013e3181ec8707.