

Scrotal Labia – An Uncommon Presentation of Vulvar Lichen Simplex Chronicus

Abstract

Lichen simplex chronicus (LSC) of the vulva is an acquired, persistent, severely itchy dermatosis usually located in easily reachable areas of the body like the extremities, nape of the neck, and genitalia. It also has a strong association with atopy and is said to be initiated and perpetuated by the itch–scratch–itch cycle. Two cases of rugose labia as the sole presentation of LSC of vulva are being presented.

Keywords: *Itching, lichenification, lichen simplex chronicus, rugosity, vulva*

Two Indian female patients aged 52 years and 28 years (P1 and P2), with severe itching over labia majora (LMA) and labia minora (LMi) leading to an unusually rugose scrotal appearance over the past 8 and 6 years, respectively, are being described. Both had unrelenting itch with nocturnal exacerbation and had developed a preoccupation with the altered appearance of their genitalia. While P1 had developed cancerphobia, P2 admitted to taking frequent photographs of her vulva and not allowing her boyfriend any intimacy in the daytime for the fear of exposing her genitalia. She was also keen on exploring surgical options to alter the appearance of her labia. Both were atopic individuals with a strong family history. There was no vaginal discharge, evidence of dermatophytosis, history of any external application of a drug, or cosmetic or toiletry product. Clinical examination of P1 revealed hyperpigmented thickened LMA with markedly increased rugosity resembling scrotal skin. Some areas showed barely perceptible erythema [Figure 1a]. Rest of the vulva appeared normal. Biopsy showed changes consistent with LSC [Figure 1b]. P2 had markedly rugose, hyperpigmented, thickened, and protruding LMi with a hard, leathery feel. Mild rugosity of the skin over LMA and localized eczematization over her left inguinal fold were noted [Figure 2]. A skin biopsy performed by a gynecologist had been reported by a general pathologist

as “nonspecific inflammation.” History and morphology favored the diagnosis of LSC of LMi. Both patients underwent treatment with halobetasol propionate for the first 3 weeks, followed by mometasone furoate cream 4 to 5 days a week with emollients, levocetirizine in the morning, and hydroxyzine at night for P1 and amitriptyline for P2. The lesion on the inguinal fold of P2 responded to treatment with mometasone and emollients in a few weeks. Both were counseled about the nature of the disease and the importance of breaking the “itch–scratch–itch” cycle by strictly avoiding rubbing and scratching. P2 was discouraged from undergoing cosmetic labiaplasty.

LSC is a well-defined dermatosis often found in association with atopy. It is characterized by excruciatingly pruritic single or multiple lichenified lesions, usually as plaques.^[1] LSC of vulva commonly presents with a single or multiple whitish or hyperpigmented keratotic plaque or often multiple, coalesced papules.^[2] Although it is seen most commonly on hair-bearing areas such as LMA and mons pubis, involvement of the LMi, perianal region, and upper medial thighs is not uncommon.^[2] Two interesting cases of vulvar LSC are presented for the striking rugosity of LMA and LMi and marked hyperpigmentation in the latter. Although variable pigmentation and rugosity are considered normal variations of vulva, the

**Shyam
Bhanushankar
Verma**

*Nirvan Skin Clinic, Makarpura
Road, Vadodara, Gujarat, India*

Address for correspondence:

*Dr. Shyam Bhanushankar
Verma,
Nirvan Skin Clinic, Makarpura
Road, Vadodara - 390 009,
Gujarat, India.
E-mail: skindiaverma@gmail.
com*

Access this article online

Website: www.idoj.in

DOI: 10.4103/idoj.IDOJ_896_20

Quick Response Code:



How to cite this article: Verma SB. Scrotal labia – An uncommon presentation of vulvar lichen simplex chronicus. *Indian Dermatol Online J* 2021;12:590-2.

Received: 02-Dec-2020. **Accepted:** 15-May-2021.

Published: 14-Jul-2021.

This is an open access journal, and articles are distributed under the terms of the Creative Commons Attribution-NonCommercial-ShareAlike 4.0 License, which allows others to remix, tweak, and build upon the work non-commercially, as long as appropriate credit is given and the new creations are licensed under the identical terms.

For reprints contact: WKHLRPMedknow_reprints@wolterskluwer.com

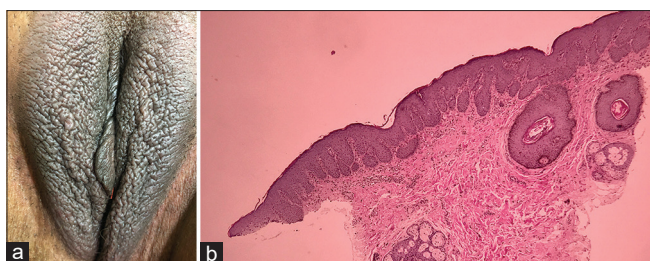


Figure 1: (a) Marked rugosity with thickening of the labia majora. (b) Hyperkeratosis, irregular acanthosis with bulbous rete, upper dermal perivascular infiltrate, and follicular hyperplasia

long-standing severe itching associated with gradually increasing rugosity with accompanying leathery texture of labia and histopathological changes go against these being normal in both patients.^[2,3] Vulvar LSC has some notable features. The early erythema of inflammation or the bright red color of early LSC described in predominantly Western textbooks are not easily appreciated in darkly pigmented individuals.^[4] The usually well-defined margins, scaling, and crusting of LSC are often not easily appreciable over the vulva due to the inherent moistness of the area.^[4] The two patients described here gave a history of habitual rubbing and did not exhibit any signs of scratching like the multiple, frequently linear, excoriations. The striking feature in these patients was the marked rugosity of labial skin as the sole presenting feature of LSC. This can be attributed to lichenification, the end stage of the itch–scratch–itch cycle that results in thick, leathery texture of the extremely pruritic labial skin with accentuated markings in the form of rugosity of labia of both atopic patients.^[1,2,4]

Following are some observations regarding the normality of the vulva in the context of rugosity, leathery feel, and pigmentation of LMa and LMi in our cases. A paucity of description of normal female genitalia and its variations in the medical literature has been noted.^[5] Vulva and its individual structures show immense variation in color, dimensions, shape, and surface.^[3,6] Therefore, defining a “normal vulva” is not only nebulous but also very subjective and also dependent on the perception of the affected individual.^[3,6,7] It is not surprising that labiaplasty is the most sought-after procedure in cosmetic genital surgery given the fact that LMi has the highest variations in its dimensions and shape.^[6,7] Although not much studied, some rugosity of labia is considered normal.^[3,7,8]

Conclusion

In conclusion, two dark-skinned atopic women with striking rugosity of labial skin as the sole presenting feature of LSC are presented. It is important for dermatologists to be aware of the wide range of variability in the appearance of a normal vulva, to clarify misconceptions, and to prevent unnecessary treatment. The author voices a special concern regarding the growing demand for genital reconstruction surgery by women often spurred by a mistaken notion

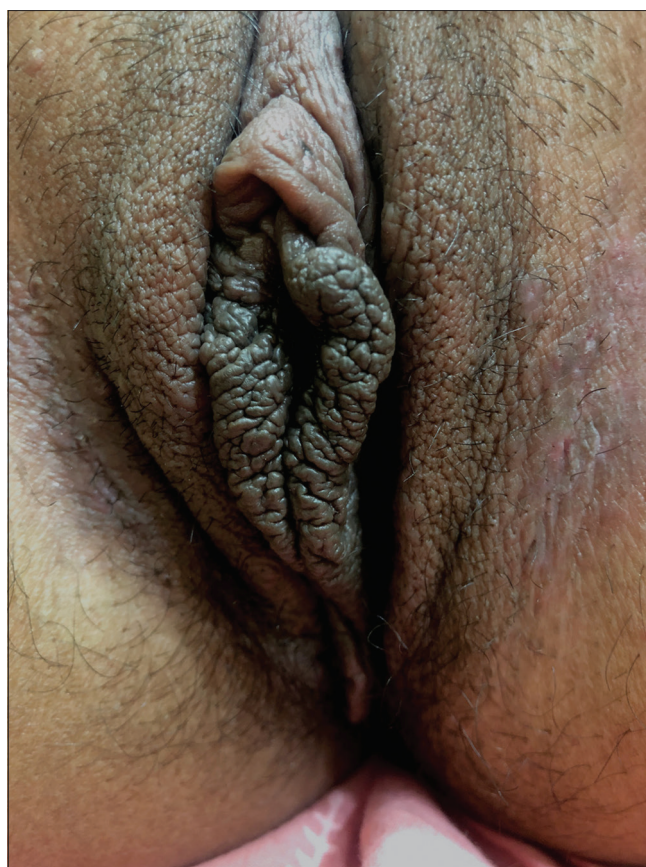

Figure 2: Hyperpigmented, markedly rugose, leathery, protruding labia minora

of “an ideal vulva,” a highly subjective and elusive term mainly fuelled by media and the internet.^[9]

Financial support and sponsorship

Nil.

Conflicts of interest

There are no conflicts of interest.

References

1. Stander S, Greaves M. Pruritus, prurigo and lichen simplex. In: Griffiths CEM, Barker J, Bleiker T, *et al.*, editors. *Rook's Textbook of Dermatology*. 9th ed. John Wiley & Sons; 2016. p. 83-18.
2. Mortaki D, Mortaki A. Lichen simplex chronicus. In: Bornstein J, editor. *Vulvar Disease - Breaking the Myths*. 1st ed. Switzerland: Springer; 2019. p. 121-9.
3. Sacher Bina C. The normal vulva and vagina. In: Bornstein J, editor. *Vulvar Disease - Breaking the Myths*. 1st ed. Switzerland: Springer; 2019. p. 7-18.
4. Lynch PJ. Lichen simplex chronicus (atopic/neurodermatitis) of the anogenital region. *Dermatol Ther* 2004;17:8–19.
5. Andrikopoulou M, Michala L, Creighton SM, Liao LM. The normal vulva in medical textbooks. *J Obstet Gynecol* 2013;33:648–50.
6. Hunter JG. Labia Minora, labia majora, and clitoral hood alteration: Experience-based recommendations. *Aesthet Surg J* 2016;36:71-9.

7. Hennekam RC, Allanson JE, Biesecker LG, Carey JC, Opitz JM, Vilain E. Elements of morphology: Standard terminology for the external genitalia. *Am J Med Genet A* 2013;161:1238-68.
8. Lloyd J, Crouch NS, Minto CL, Liao LM, Creighton SM. Female genital appearance: "Normality" unfolds. *BJOG* 2005;112:643-6.
9. Clerico C, Lari A, Mojallal A, Boucher F. Anatomy and aesthetics of the labia minora: The ideal vulva? *Aesthetic Plast Surg* 2017;41:714-9.