



ORIGINAL RESEARCH

Factors affecting the incidence of chorda tympani nerve transection in middle ear surgery

Saki Takihata MD | Takaomi Kurioka MD, PhD  | Kunio Mizutari MD, PhD  |
Akihiro Shiotani MD, PhD

Department of Otolaryngology-Head and Neck Surgery, National Defense Medical College, Saitama, Japan

Correspondence

Kunio Mizutari, MD, PhD, Department of Otolaryngology, Head and Neck Surgery, National Defense Medical College, 3-2 Namiki, Tokorozawa, Saitama 359-8513, Japan.
Email: tari@mbf.ocn.ne.jp

Abstract

Objective: To reveal the factors affecting the incidence of chorda tympani nerve (CTN) transection during middle ear surgery.

Study Design: Retrospective case review.

Setting: Tertiary referral center.

Patients: We analyzed 232 ears (117 ears with cholesteatoma, 101 ears with chronic otitis media, and 14 ears with otosclerosis) that underwent tympanoplasty or stapes surgery during 2017–2020.

Intervention: Eighty-four ears underwent transcanal endoscopic ear surgery (TEES), 103 ears underwent microscopic ear surgery (MES), and 45 ears underwent surgery using both endoscopy and microscopy (Dual).

Main Outcome Measure: To confirm CTN transection, intraoperative endoscopic/microscopic video images were evaluated. We used the same video images to determine the anatomical variation of the CTN course in the middle ear.

Results: In 18 ears (7.8%: 6/84 TEES ears [7.1%], 6/103 MES ears [5.8%], and 6/45 Dual ears [13.3%]), the CTN was cut during middle ear surgery. There was no significant difference in CTN transection among groups. In cholesteatoma patients, stapes involvement resulted in a significantly higher CTN transection incidence. CTN anatomical variants such as the “Attached Short type” and “Ultrashort type” showed a significantly higher CTN transection incidence.

Conclusion: Although endoscopic surgery did not reduce the incidence of CTN transection during middle ear surgery, pathological involvement of the stapes and CTN anatomical variants, such as the “Attached Short type” and “Ultrashort type,” may increase this incidence. Preoperative evaluation of stapes involvement and anatomical location of the CTN course could help identify patients at greater risk for iatrogenic CTN transection.

Level of Evidence: 4.

Saki Takihata and Takaomi Kurioka have contributed equally to this work.

This is an open access article under the terms of the [Creative Commons Attribution-NonCommercial-NoDerivs](https://creativecommons.org/licenses/by-nc-nd/4.0/) License, which permits use and distribution in any medium, provided the original work is properly cited, the use is non-commercial and no modifications or adaptations are made.

© 2022 The Authors. *Laryngoscope Investigative Otolaryngology* published by Wiley Periodicals LLC on behalf of The Triological Society.

KEYWORDS

chorda tympani, middle ear surgery, survey, taste

1 | INTRODUCTION

Tympanoplasty/stapes surgery is an established procedure for removing middle ear pathology and improving conductive hearing loss.¹⁻³ During tympanoplasty or stapes surgery, serious complications, such as facial nerve palsy, cerebrospinal fluid leakage, or damage to the semicircular canal, can occur. However, the incidence of these complications is low, approximately 1%, if a trained surgeon performs the surgery.^{4,5} On the other hand, trauma to the chorda tympani nerve (CTN) is reported as the most frequent complication, occurring in 15%–55% of patients who undergo middle ear surgery.⁶⁻⁸

The CTN, which innervates the anterior part of the tongue and the salivary glands, runs through the middle ear cavity. Trauma to the CTN would result in dysgeusia or ageusia, seriously compromising patients' quality of life. Therefore, reducing the risk of iatrogenic injury to the CTN is critical for otologic surgeons.⁹

In particular, CTN injury can be accidental or intentional. Accidental injury of the CTN includes transection, stretching, ischemia, thermal injury, excessive handling, and desiccation when removing inflammatory middle ear pathologies, such as cholesteatoma or granulation tissue.^{10,11} Additionally, the CTN is also sacrificed if deemed necessary to gain surgical access to the pathology and reduce complications. Therefore, various factors may affect the incidence of CTN injury.

In recent years, transcanal endoscopic ear surgery (TEES) has been popularly applied to different types of middle ear disease.¹² TEES has many advantages, including a wide field of view, higher magnification of delicate anatomical structures, and clear visualization of anatomical areas located in blind spots when viewed through a microscope.¹³⁻¹⁵ Consequently, TEES is thought to be less invasive than microscopic ear surgery (MES).^{16,17} Moreover, several studies have demonstrated the superiority of TEES over MES with TEES showing a lower incidence of complications.^{18,19} Additionally, some reports have shown that TEES could reduce the incidence of damage to the CTN.¹⁰ Occasionally, the tympanic segment of the CTN is difficult to identify in microscopic view. In contrast, the CTN is readily visible during the TEES procedure upon elevation of the tympanomeatal flap, even in narrow external auditory canals (EACs).^{20,21} We consider that it is easier to find the CTN in the middle ear cavity under the endoscope, due to its wider view angle, than under the microscope. However, we also consider that TEES would have a similar risk of damaging the CTN because transcanal manipulation within the middle ear is frequently performed close to the CTN. Moreover, besides the surgical approach, various factors could affect the incidence of CTN transection, such as pathological involvement and anatomical variation of the CTN course. In particular, progressive middle ear diseases may force the surgeon to sacrifice the CTN due to difficulty in complete removal of the pathology when preserving the CTN.

In this study, we retrospectively analyzed the incidence of CTN transection during middle ear surgery at our institution and investigated the relationship between the CTN transection incidence and surgical procedures, such as endoscopic, microscopic, or combined (dual) approaches. We also evaluated the influence of pathological involvement and anatomical variation of the CTN on the CTN transection incidence.

2 | PATIENTS AND METHODS

2.1 | Patients

We evaluated 316 ears that underwent middle ear surgery at the National Defense Medical College Hospital between January 2017 and December 2020 in this retrospective case review. Cases ($n = 84$) with cochlear implant, tumor, revision surgery, and otitis media with ANCA-associated vasculitis were excluded.

The study protocol was approved by the Institutional Review Board of the National Defense Medical College, Saitama, Japan (approval #3103). Written informed consent was obtained from all participants.

2.2 | Surgical intervention

TEES was performed using 0- or 45-degree angled rigid endoscopes with an outer diameter of 2.7 mm (Karl Storz) coupled with a full high-definition video system (Karl Storz, Tuttlingen, Germany). MES was performed under a microscope (Leica). According to the Massachusetts Eye and Ear Infirmary EES Classification System,²² class 3 (endoscope only) was defined as "TEES," classes 0 (microscope only) and 1 (endoscope used to assess the disease only) were defined as "MES," whereas class 2 (mixed dissection, microscope and endoscope used for dissection) was defined as "Dual." According to the EAONO/JOS criteria, the extent of cholesteatoma was subclassified into the following regions: protympanum (P), tympanic cavity (T), attic or epitympanum (A), and mastoid cavity (M). The existence of stapes involvement in cholesteatoma patients was also reviewed using intraoperative video images.

Although the term "CTN injury" should include not only anatomical damages but also decreased neural function measured by threshold elevation in the gustatory test, we defined only CTN transection cases during surgery as "CTN injury" in this study. This was done as postoperative gustatory examination was not performed in our institution. In middle ear surgery, we equally used all the universal surgical tools, such as suction, WULLSTEIN needle, round knife, duckbill elevator, bone chisel, scissor, and ear curette, in all surgical approaches (TEES, MES, or Dual).

TABLE 1 Classification of the CTN anatomical variations

| Type | Definition |
|----------------|--|
| EAC | Orifice of the posterior canaliculus is lateral to the tympanic annulus |
| Detached | CTN runs through the middle ear separately from the bony tympanic annulus |
| Attached long | CTN runs adjacent to the bony tympanic annulus, and the proximal portion is visible inferior to the IS joint |
| Attached short | CTN runs adjacent to the bony tympanic annulus, and the proximal portion is visible superior to the IS joint |
| Ultrashort | CTN appears at the notch of Rivinus, and atticotomy is required to visualize the CTN |

Abbreviations: CTN, chorda tympani nerve; EAC, external auditory canal; IS, incudostapedial.

2.3 | Classification of anatomical CTN variation

The CTN was anatomically classified based on surgical observation (Table 1) by the three authors (TS, TK, and KM) following a previous report by Uranaka et al.²⁰ The CTN in the tympanic segment was classified into five patterns: “EAC type,” “Detached type,” “Attached Long type,” “Attached Short type,” and “Ultrashort type.” In several cases, it was impossible to classify the type due to the disturbance caused by the pathological structure, such as inflammation or thickened tympanic mucosa. These cases were classified as “Unclassified type.”

2.4 | Statistical analysis

Descriptive analysis was performed using GraphPad Prism (GraphPad Software Inc.) or JMP 14.2 (SAS Institute). The chi-square test was used to evaluate the clinical characteristics and possible prognostic factors. The *t*-test and non-parametric Mann-Whitney *U* test were applied to investigate continuous variables as prognostic factors. The Cochran-Armitage trend test was used to assess the trends of CTN transection across anatomical variation of the CTN. After univariate analyses, we included various parameters into a binary logistic regression model for multivariate analysis. Study data are presented as means ± standard deviation. Values of *p* < .05 were considered statistically significant.

3 | RESULTS

3.1 | Patient demographics and operative volume

A total of 232 ears from 216 patients were considered eligible for this study. Table 2 presents the clinical characteristics of all ears. The mean age of the patients was 50.8 ± 24.0 years. In 84 ears (36.2%), surgery was conducted under TEES, in 103 ears (44.4%), surgery was conducted under MES, and in 45 ears (19.4%), surgery involved a dual approach. In terms of pathological classification, 117 ears (50.4%) had cholesteatoma, 101 ears (43.5%) had chronic otitis media (COM), and 14 ears (6.0%) had osteosclerosis.

TABLE 2 Clinical characteristics of all ears

| Variable | Value |
|---------------------------------|-------------|
| Ears (n) | 232 |
| Age (mean ± SD; years) | 50.8 ± 24.0 |
| Sex (male/female; n) | 116/116 |
| Laterality (right/left; n) | 104/128 |
| Surgical approach (n, [%]) | |
| TEES | 84 (36.2%) |
| MES | 103 (44.4%) |
| Dual | 45 (19.4%) |
| Pathology (n, [%]) | |
| Cholesteatoma | 117 (50.4%) |
| COM | 101 (43.5%) |
| Otosclerosis | 14 (6.0%) |
| Operation time (mean ± SD; min) | 139 ± 51 |

Abbreviations: COM, chronic otitis media; MES, microscopic ear surgery; SD, standard deviation; TEES, transcanal endoscopic ear surgery.

3.2 | Incidence of CTN transection and influence of the surgical approach

To investigate the potential factors related to the incidence of CTN transection, we retrospectively analyzed the clinical features, including the surgical approach and pathology, between cases with CTN preservation and those with CTN transection (Table 3). In 18 ears, the CTN was cut during middle ear surgery (7.8%). There was no significant difference between the two groups with respect to age, sex, and laterality. Of the ears with a cut CTN, there were six of 84 ears (7.1%) in the TEES group, six of 103 ears in the MES group (5.8%), and 6 of 45 ears in the Dual group (13.3%). Statistical analysis showed no significant difference in the incidence of CTN transection among groups (*p* = .28). Although there was no significant difference in the surgical approaches, the dual approach showed a tendency for a higher incidence of CTN transection than the TEES and MES approaches. Moreover, the instrument finally responsible for CTN injury was almost always the suction or elevator. In two cases in the Dual group, the CTN had been intentionally cut because it was impossible to remove the cholesteatoma completely from the CTN. In addition, there was no statistically significant difference among the two groups in terms of pathology or operation time. The incidence of CTN transection was comparable between cholesteatoma (7.7%) and COM (8.9%) cases. We performed all stapes surgeries using the TEES approach, and no incidence of CTN transection occurred.

3.3 | Influence of pathological involvement on the incidence of CTN transection

We further investigated whether the pathological status of cholesteatoma in the middle ear could affect the incidence of CTN transection (Table 4). There were nine cases with CTN transection during cholesteatoma surgery (6.8%). There was no significant difference between the two groups

TABLE 3 Clinical differences between ears with CTN preservation and CTN transection

| Variable | CTN preservation | CTN transection | <i>p</i> |
|---------------------------------|------------------|-----------------|----------|
| Ears (n, [%]) | 214 (92.2%) | 18 (7.8%) | |
| Age (mean ± SD; years) | 50.3 ± 23.8 | 56.3 ± 26.3 | .31 |
| Sex (male/female; n) | 105/109 | 11/7 | .33 |
| Laterality (right/left; n) | 95/119 | 9/9 | .65 |
| Surgical approach (n, [%]) | | | .28 |
| TEES | 78 (92.9%) | 6 (7.1%) | |
| MES | 97 (94.2%) | 6 (5.8%) | |
| Dual | 39 (86.7%) | 6 (13.3%) | |
| Pathology (n, [%]) | | | .51 |
| Cholesteatoma | 108 (92.3%) | 9 (7.7%) | |
| COM | 92 (91.1%) | 9 (8.9%) | |
| Otosclerosis | 14 (100%) | 0 (0%) | |
| Operation time (mean ± SD; min) | 138 ± 52 | 150 ± 44 | .35 |

Abbreviations: COM, chronic otitis media; CTN, chorda tympani nerve; MES, microscopic ear surgery; SD, standard deviation; TEES, transcanal endoscopic ear surgery.

TABLE 4 Influence of surgical and pathological involvement on CTN transection in cholesteatoma patients

| Variable | CTN preservation | CTN transection | <i>p</i> value | |
|-----------------------------------|------------------|-----------------|----------------|--------------|
| | | | Univariate | Multivariate |
| Ears (n, [%]) | 108 (92.3%) | 9 (7.7%) | | |
| Age (mean ± SD; years) | 47.9 ± 23.8 | 45.2 ± 29.4 | .75 | |
| Sex (male/female; n) | 56/52 | 6/3 | .39 | |
| Laterality (right/left; n) | 52/56 | 4/5 | .83 | |
| Operation time (mean ± SD; min) | 158 ± 51 | 172 ± 39 | .43 | |
| Surgical approach (n, [%]) | | | .02* | .08 |
| TEES | 44 (95.7%) | 2 (4.3%) | | |
| MES | 38 (97.4%) | 1 (2.6%) | | |
| Dual | 26 (81.2%) | 6 (18.8%) | | |
| Involving site (n) | | | | |
| P (with/without) | 0/0 | 0/0 | | |
| T (with/without) | 60/48 | 6/3 | .52 | |
| A (with/without) | 103/5 | 9/0 | .51 | |
| M (with/without) | 76/32 | 7/2 | .64 | |
| Stapes involvement (with/without) | 54/54 | 8/1 | .02* | .04* |

Abbreviations: A, attic; CTN, chorda tympani nerve; M, mastoid; MES, microscopic ear surgery; P, protympanum; SD, standard deviation; T, tympanic cavity; TEES, transcanal endoscopic ear surgery.

**p* < .05.

with respect to age, sex, and laterality. In 133 cholesteatoma ears, the surgical approach showed a significant difference between the two groups ($p = .02$). In particular, a significantly higher incidence of CTN transection was observed in the dual approach (18.8%). However, the TEES and MES approaches showed a comparable incidence of CTN transection, indicating that endoscopy had neither a beneficial nor a detrimental effect on CTN transection during middle ear surgery.

In addition, the cholesteatoma group was further analyzed in terms of the extent of the pathology. All cholesteatoma cases were determined positive or negative at the four sites (P, T, A, and M). There were no significant differences in the incidence of CTN injury

among the sites. According to the univariate and multivariate analyses, there was a statistically significant increase in the incidence of CTN injury when the cholesteatoma involved the stapes.

3.4 | Influence of anatomical variation of CTN on the incidence of the CTN transection

To investigate whether the anatomical variation of the CTN course could affect the incidence of CTN transection, operated ears were classified into five anatomical variants based on the CTN course:

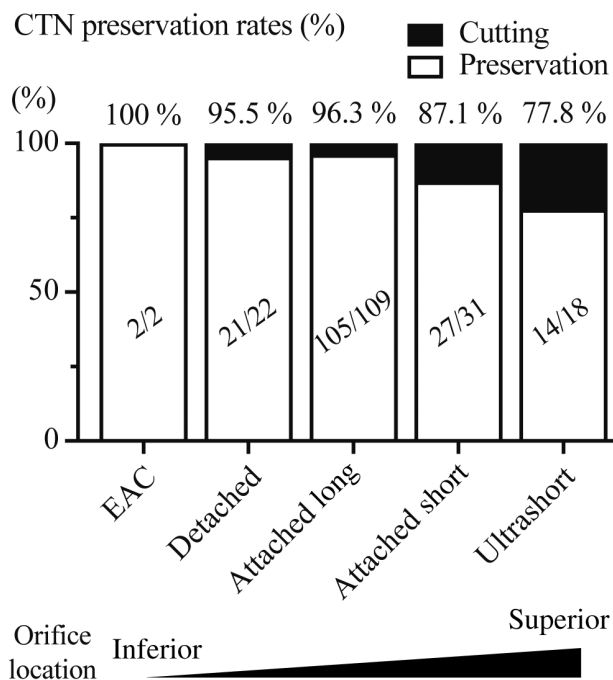


FIGURE 1 CTN preservation rates in anatomical variants of CTN. CTN preservation rates was gradually decreased from the “EAC” to “Ultrashort” type. CTN, chorda tympani nerve; EAC, external auditory canal

“EAC type,” “Detached type,” “Attached Long type,” “Attached Short type,” and “Ultrashort type,” as based on a previous study.²⁰ In all 232 ears, 182 ears were eligible for this analysis because 50 ears were excluded as they were of the “Unclassified type.” The CTN preservation rates in the “EAC type,” “Detached type,” “Attached Long type,” “Attached Short type,” and “Ultrashort type” was 100% (2/2 ears), 95.5% (21/22 ears), 96.3% (105/109 ears), 87.1% (27/31 ears), and 77.8% (14/18 ears), respectively (Figure 1). Consistent with previous reports,²⁰ the “Attached Long type” was the most common pattern among the groups. Statistical analysis revealed that there was a trend for a significant difference in the incidence of CTN transection among the five groups ($p = .01$; Cochran–Armitage trend test), which indicated that anatomic variants such as the “Attached Short type” and “Ultrashort type” were at higher risk of transection injury.

4 | DISCUSSION

In this study, we investigated whether surgical approach, otologic pathology, and anatomical variation of the CTN could affect the incidence of CTN injury during middle ear surgery. Although endoscopic surgery did not reduce the incidence of CTN transection, pathological involvement of the stapes and CTN anatomical variations, such as the “Attached Short type” and “Ultrashort type,” were significant risk factor of CTN transection. Our results suggested that preoperative evaluation of stapes involvement and classification of the CTN course could be important in identifying cases at greater risk for CTN transection.

4.1 | Surgical approach and middle ear pathology

Some previous reports related to stapes surgery have demonstrated that CTN injury was lower in TEES compared with MES approaches.^{10,23} However, TEES is limited in that it allows use of only one hand and presents a two-dimensional view, which results in difficulties in depth perception.²⁴ Furthermore, TEES involves surgical procedures close to the exposed CTN and requires careful CTN manipulation to avoid CTN injury when removing pathology from the middle ear. Accordingly, the indication for the surgical approach should be considered with an understanding of the risk of CTN transection. Nevertheless, few previous reports have specifically focused on CTN injury. In our institution, all stapes surgery was performed using TEES, and no CTN transection occurred, indicating that TEES might be suitable for stapes surgery, due to its wider view-angle around the stapes and posterior tympanic cavity.

Furthermore, we demonstrated that there was no significant difference in CTN transection rate between TEES and MES in all ears, as shown in Table 3 and 4, indicating MES is not necessarily inferior to TEES in terms of the incidence of CTN transection. However, the dual approach resulted in a higher CTN transection rate, although not statistically significant, because the dual approach is sometimes used in cases of progressive disease, to remove pathology around the sinus tympani and facial recess, where blind spots are present in the microscope view. In such cases, the surgeon has to manipulate the CTN frequently to remove middle ear pathology, because the sinus tympani is located immediately deep to the CTN. Thus, middle ear pathology rather than the surgical approach is a prognostic factor in the incidence of CTN transection, consistent with our results (Table 3). In particular, in cases of stapes involvement, a certain degree of manipulation of the CTN is often necessary to create a favorable working area around the stapes and to remove the pathology. This manipulation would naturally increase the risk of CTN injury, in terms of stretching, compression, or transection. To our knowledge, no previous study has revealed that middle ear pathology involving the stapes is associated with a high risk of CTN injury.

4.2 | Anatomical variation of CTN course

The CTN originates from the mastoid segment of the facial nerve, immediately before the latter exits the facial canal at the stylomastoid foramen.²⁵ A previous study has reported anatomical variations of the CTN course, which were classified into five types: the “EAC type,” “Detached type,” “Attached Long type,” “Attached Short type,” and “Ultrashort type”.²⁰ A better understanding of variation in CTN anatomical location may help to avoid some instances of iatrogenic CTN injury. Consistent with previous reports,²⁰ the “Attached Long type” was the most common pattern among our patients. We noted a significant trend for an increase in CTN transection in anatomical types where the CTN emerged above the posterior canaliculus, such as in the “Attached Short type” and “Ultrashort type” (Figure 1). One possible reason for the higher incidence of CTN transection in the

“Attached Short type” and the “Ultrashort type” could be that shorter sections of attachment of the CTN to the bony tympanic annulus result in reduced CTN freedom, which makes the CTN more vulnerable to manipulation. Other reasons are that the CTN in these types is easily involved inflammatory middle ear pathology, such as cholesteatoma, because in these types, the CTN emerges above the bony tympanic annulus and runs nearby the attic region, where it is prone to involvement in attic cholesteatoma. Therefore, anatomical variants in which the CTN courses in a superior position and in the vicinity of the stapes might increase the risk of CTN transection.

4.3 | Clinical implications and limitations

Our findings have clinical implications for the management of otologic surgery. Although careful preparation for preservation of CTN is mandatory regardless of the surgical approach used, stapes involvement in middle ear pathology and variation in the course of the CTN, such as the “Attached Short type” and “Ultrashort type”, might be vulnerable to CTN manipulation because the CTN courses close to the attic in these types, where it is most susceptible to attic cholesteatoma. Therefore, preoperative detection of stapes involvement and “Attached Short type” or “Ultrashort type” CTN variants in preoperative CT examination indicates the need for increased attention to preserve the CTN, regardless of the surgical approach used. It would be ideal to obtain informed patient acknowledgement of the risk of CTN injury and to formulate a treatment protocol for reconstruction of the CTN if needed.

This study had several limitations. First, this was a single-hospital, retrospective study, and the sample size was relatively small. Further studies in larger populations are warranted. Additionally, electrogustometry examination would be suitable to investigate CTN injury, because preservation of the CTN does not necessarily imply no CTN injury. Other types of CTN injury, such as stretching, ischemic injury, thermal injury, excessive handling injury, and desiccation, should be investigated by measuring electrogustometry.

5 | CONCLUSION

Our findings revealed that usage of an endoscope in middle ear surgery did not affect the incidence of CTN transection. Although the surgical approach did not markedly affect the incidence of CTN transection during middle ear surgery, pathological involvement of the stapes and CTN anatomical variants, such as the “Attached Short type” and “Ultrashort type,” may increase the risk of CTN transection. Our results indicated that careful preparation is mandatory for preservation of the CTN, regardless of the surgical approach, and that preoperative evaluation for stapes involvement and classification of the CTN course are useful for preventing iatrogenic CTN injuries.

CONFLICT OF INTEREST

The authors have no conflict of interest to disclose.

ORCID

Takaomi Kurioka  <https://orcid.org/0000-0001-6273-8527>

Kunio Mizutari  <https://orcid.org/0000-0002-0340-8293>

REFERENCES

- Schuknecht HF, Applebaum EL. Surgery for hearing loss. *N Engl J Med*. 1969;280:1154-1160.
- Mudry A. History of tympanoplasty. *Otol Neurotol*. 2005;26:554-555.
- Nazarian R, McElveen JT Jr, Eshraghi AA. History of otosclerosis and stapes surgery. *Otolaryngol Clin N Am*. 2018;51:275-290.
- Shew MA, Muelleman T, Villwock M, et al. Therapeutic Mastoidectomy does not increase postoperative complications in the Management of the Chronic ear. *Otol Neurotol*. 2018;39:54-58.
- Li KH, Chan LP, Chen CK, et al. Comparative study of endoscopic and microscopic type I Tympanoplasty in terms of delayed facial palsy. *Otolaryngol Head Neck Surg*. 2021;164:645-651.
- Michael P, Raut V. Chorda tympani injury: operative findings and postoperative symptoms. *Otolaryngol Head Neck Surg*. 2007;136:978-981.
- Berling Holm K, Bornefalk-Hermansson A, Knutsson J, von Unge M. Surgery for chronic otitis media causes greater taste disturbance than surgery for otosclerosis. *Otol Neurotol*. 2019;40:e32-e39.
- Choi N, Ahn J, Cho YS. Taste changes in patients with middle ear surgery by intraoperative manipulation of chorda tympani nerve. *Otol Neurotol*. 2018;39:591-596.
- Dana RM, McCaughey SA. Gustatory responses of the mouse chorda tympani nerve vary based on region of tongue stimulation. *Chem Senses*. 2015;40:335-344.
- Manna S, Kaul VF, Gray ML, Wanna GB. Endoscopic versus microscopic middle ear surgery: a meta-analysis of outcomes following tympanoplasty and stapes surgery. *Otol Neurotol*. 2019;40:983-993.
- Molinari G, Reale M, Bonali M, et al. Taste impairment after endoscopic stapes surgery: do anatomic variability of chorda tympani and surgical technique matter?: Post-operative dysgeusia after ESTs. *Eur Arch Otorhinolaryngol*. 2021;279:2269-2277.
- Dixon PR, James AL. Evaluation of residual disease following transcanal totally endoscopic vs postauricular surgery among children with middle ear and attic cholesteatoma. *JAMA Otolaryngol Head Neck Surg*. 2020;146:408-413.
- Tarabichi M. Endoscopic management of acquired cholesteatoma. *Am J Otol*. 1997;18:544-549.
- Ito T, Kubota T, Watanabe T, Futai K, Furukawa T, Kakehata S. Transcanal endoscopic ear surgery for pediatric population with a narrow external auditory canal. *Int J Pediatr Otorhinolaryngol*. 2015;79:2265-2269.
- Mizutari K, Takihata S, Kimura E, Inuzuka E, Shiotani A. Patency of anterior epitympanic space and surgical outcomes after endoscopic ear surgery for the attic cholesteatoma. *Otol Neurotol*. 2021;42:266-273.
- Lade H, Choudhary SR, Vashishth A. Endoscopic vs microscopic myringoplasty: a different perspective. *Eur Arch Otorhinolaryngol*. 2014;271:1897-1902.
- Ilynen I, Dundar R. Chorda tympani nerve injury during tympanoplasty. Comparison of endoscopic and microscopic methods. *Ann Ital Chir*. 2021;10. <https://doi.org/S0003469X2102813X>
- Marchioni D, Rubini A, Gazzini L, et al. Complications in endoscopic ear surgery. *Otol Neurotol*. 2018;39:1012-1017.
- Tsetsos N, Vlachtsis K, Stavrakas M, Frympas G. Endoscopic versus microscopic ossiculoplasty in chronic otitis media: a systematic review of the literature. *Eur Arch Otorhinolaryngol*. 2021;278:917-923.
- Uranaka T, Matsumoto Y, Hoshi Y, Iwasaki S, Kakigi A, Yamasoba T. Classification of the chorda tympani: an endoscopic study. *Otol Neurotol*. 2021;42:e355-e362.

21. Kojima H, Komori M, Chikazawa S, et al. Comparison between endoscopic and microscopic stapes surgery. *Laryngoscope*. 2014;124:266-271.
22. Cohen MS, Landegger LD, Kozin ED, Lee DJ. Pediatric endoscopic ear surgery in clinical practice: lessons learned and early outcomes. *Laryngoscope*. 2016;126:732-738.
23. Koukoulis A, Toth I, Gede N, et al. Endoscopic versus microscopic stapes surgery outcomes: a meta-analysis and systematic review. *Laryngoscope*. 2020;130:2019-2027.
24. Hashim ND, Jang SH, Moon IS. Endoscopic intervention of aberrant carotid artery in the middle ear. *Otol Neurotol*. 2021;42:e82-e85.
25. McManus LJ, Dawes PJ, Stringer MD. Clinical anatomy of the chorda tympani: a systematic review. *J Laryngol Otol*. 2011;125:1101-1108.

How to cite this article: Takihata S, Kurioka T, Mizutari K, Shiotani A. Factors affecting the incidence of chorda tympani nerve transection in middle ear surgery. *Laryngoscope Investigative Otolaryngology*. 2022;7(6):2088-2094. doi:[10.1002/liv.2976](https://doi.org/10.1002/liv.2976)