

# Lateral Extra-Articular Tenodesis Staple Risks Penetration of Anterior Cruciate Ligament Reconstruction Tunnel



Thomas E. Moran, M.D., Ian S. MacLean, M.D., Gregory R. Anderson, M.D.,  
Laurel A. Barras, M.D., Ryan M. Graf, M.D., David R. Diduch, M.D., and  
Mark D. Miller, M.D.

**Purpose:** To identify the risk of anterior cruciate ligament (ACL) femoral tunnel penetration with the use of a staple for lateral extra-articular tenodesis (LET) graft fixation and to determine whether this varied between 2 different techniques for ACL femoral tunnel drilling. **Methods:** Twenty paired, fresh-frozen, cadaver knees underwent ACL reconstruction with a LET. Left and right knees were randomized to ACL reconstruction with femoral tunnel creation by use of either a rigid guide pin and reamer through the accessory anteromedial portal or by the use of a flexible guide pin and reamer through the anteromedial portal. Immediately after tunnel creation, the LET was performed and fixated with a small Richard's staple. Fluoroscopy was used to obtain a lateral view of the knee to determine staple position, and visualization of the ACL femoral tunnel was performed with the arthroscope to investigate penetration of the staple into the femoral tunnel. The Fisher exact test was conducted to determine whether there was any difference in tunnel penetration between tunnel creation techniques. **Results:** The staple was noted to penetrate the ACL femoral tunnel in 8 of 20 (40%) extremities. When stratified by tunnel creation technique, the Richards staple violated 5 of 10 (50%) of the tunnels made via the rigid reaming technique compared with 3 of 10 (30%) of those created with a flexible guide pin and reamer ( $P = .65$ ). **Conclusions:** A high incidence of femoral tunnel violation is seen with lateral extra-articular tenodesis staple fixation. **Level of Evidence:** Level IV, controlled laboratory study. **Clinical Relevance:** The risk of penetrating the ACL femoral tunnel with a staple for LET graft fixation is not well understood. Yet, the integrity of the femoral tunnel is important for the success of ACL reconstruction. Surgeons can use the information in this study to consider adjustments to operative technique, sequence, or fixation devices used when performing ACL reconstruction with concomitant LET to avoid the potential for disruption of ACL graft fixation.

The anterior cruciate ligament (ACL) is one of the most commonly injured ligaments of the knee, with an estimated 200,000-350,000 ACL tears occurring annually in the United States.<sup>1-3</sup> Because of its prevalence, especially within the athletic community, considerable effort has been dedicated to optimizing the

surgical technique and perioperative management, with the goal of improving outcomes following anterior cruciate ligament reconstruction (ACL-R).<sup>1</sup> Despite an emphasis on creating an anatomic ACL-R to better restore native knee kinematics, relatively high rates of clinical failure and graft rupture in the young, athletic

From the Department of Orthopaedic Surgery, University of Virginia Medical Center, Charlottesville, Virginia, U.S.A.

The authors report the following potential conflicts of interest or sources of funding: D.R.D. reports Aesculap/B. Braun: Research support, American Orthopaedic Society for Sports Medicine: board or committee member, DJ Orthopaedics: research support, Mitek: paid consultant, Moximed: research support, Osteocentric: paid consultant, Smith & Nephew: IP royalties, and Springer: publishing royalties, financial or material support. M.D.M. reports American Orthopaedic Society for Sports Medicine: board or committee member; Arthrex: IP royalties, paid consultant; Clozex: stock or stock options; Johnson & Johnson, stock or stock options; Saunders/Mosby-Elsevier: publishing royalties, financial or material support; Stryker: stock or stock options; and Wolters Kluwer Health – Lippincott Williams & Wilkins: publishing

royalties, financial or material support. Full ICMJE author disclosure forms are available for this article online, as [supplementary material](#).

Received August 21, 2022; revised manuscript received November 4, 2022; accepted November 8, 2022.

Address correspondence to Thomas E. Moran, M.D., Department of Orthopaedic Surgery, University of Virginia, 2280 Ivy Rd., Charlottesville, VA 22903. E-mail: [tem9rs@virginia.edu](mailto:tem9rs@virginia.edu)

© 2022 THE AUTHORS. Published by Elsevier Inc. on behalf of the Arthroscopy Association of North America. This is an open access article under the CC BY-NC-ND license (<http://creativecommons.org/licenses/by-nc-nd/4.0/>).  
2666-061X/221059

<https://doi.org/10.1016/j.asmr.2022.11.013>

population remain.<sup>4-6</sup> As residual laxity has been a frequently cited etiology of graft rupture and inferior functional outcomes after ACL-R, an increasing clinical focus has been dedicated to addressing its occurrence in this cohort of patients.<sup>7-10</sup>

The modified Lemaire lateral extra-articular tenodesis (LET) recently has been advocated as an adjunct to ACL-R in certain patients at high risk of graft failure.<sup>11-14</sup> Cited indications for its use as an adjunct to ACL-R include the presence of a high-grade pivot shift, generalized ligamentous laxity, or in a young patient returning to pivoting sports.<sup>13</sup> Although some biomechanical and clinical studies have shown this technique decreases anterolateral rotational instability and reduces graft failure rates, others have not shown a clinically significant difference in outcomes with the performance of a concomitant LET and report an increased incidence in lateral compartment osteoarthritis at mid-term follow-up.<sup>12,13,15-17</sup> One recognized limitation when performing an LET concomitantly with ACL-R is the risk of ACL and LET tunnel convergence.<sup>18-22</sup> Multiple clinical and cadaveric studies have examined the effects of adjusting technical variables to circumvent this risk, including changing the knee flexion angle when drilling the ACL femoral tunnel and adjusting the starting point, direction, and angle of the LET tunnel.<sup>18-22</sup> These modifications, however, are relatively limited by the isometric footprint for the LET.

Techniques that use a staple for LET fixation attempt to avoid this risk of tunnel convergence by avoiding the need to drill an additional tunnel in the femur.<sup>23</sup> However, the risk of ACL femoral tunnel violation with the tine of the staple may still exist with this technique. The purpose of this study was to identify the risk of ACL femoral tunnel penetration with the use of a staple for LET graft fixation and to determine whether this varied between 2 different techniques for ACL femoral tunnel drilling. It was hypothesized that although the risk of ACL femoral tunnel penetration would occur with the use of a staple for LET graft fixation, the incidence would not significantly differ based upon the technique used for ACL femoral tunnel drilling.

## Methods

Ten matched pairs of fresh-frozen cadaveric knees were used (5 male, 5 female; mean age 56.4 years, range 37-68 years) for a total of 20 specimens. Left and right knees were randomized in opaque envelopes to undergo ACL-R with femoral tunnel creation via either an accessory anteromedial portal (AMP) technique using a rigid guide pin and reamer (RR) or a standard AMP with a flexible guide pin and reamer (FR) in the manner described to follow. All tunnels

were drilled by 3 orthopaedic sports medicine fellows under the direct supervision of a senior sports medicine attending.

### Femoral Tunnel Drilling

Standard anterolateral and anteromedial (AM) portals were created, and an adequate debridement of the native ACL and medial wall of the lateral femoral condyle (LFC) was performed to identify the location for femoral tunnel placement at the anatomic ACL footprint.

### AM Portal With Flexible Guide Pin and Reamer


A 7-mm femoral offset guide (Arthrex, Naples, FL) was placed through the AM portal behind the posterior wall of the LFC with the knee maintained in 120° of flexion. Guide placement was confirmed to be in the center of the ACL femoral footprint under direct arthroscopic visualization. A 2.4-mm flexible guidewire was then driven into the LFC and subsequently overreamed to 10 mm with a flexible reamer with a tunnel length of 25 mm. A 10-mm tunnel diameter was selected in accordance with the senior author's standard practice for ACL-R using a bone-patella tendon-bone autograft.

### Accessory AMP With Rigid Guide Pin and Reamer

A separate, accessory AMP was created under direct arthroscopic visualization with use of an 18-gauge spinal needle (Becton-Dickinson, Franklin Lakes, NJ) to confirm appropriate portal placement. In similar fashion to the FR technique, a 7-mm offset guide (Arthrex, Naples, FL) was placed through the accessory AMP and a rigid guide pin placed with the knee at 120° of flexion. Subsequently, a 10-mm tunnel with a depth of 25 mm was reamed.

### Lateral Extra-Articular Tenodesis

After femoral tunnel creation and before passing the ACL graft, a modified Lemaire LET was performed via the surgical technique described by Jesani and Getgood.<sup>14</sup> With the knee in 90° of flexion, a skin incision was made starting 2 cm proximal to Gerdy's tubercle and extending 6 cm further proximally. The dissection was carried down to expose the iliotibial band (ITB) and its posterior margin. An incision was made 1 cm anterior to the posterior margin, with care taken to leave the posterior fibers of the ITB undisturbed. An 8-cm × 1-cm central strip of ITB was harvested and released proximally. Deep attachments were then sharply dissected away from the graft. After a #1 VICRYL suture (Ethicon, Somerville, NJ) was secured through the proximal 2 cm of the graft, the superficial and deep borders of the lateral collateral ligament (LCL) were defined. A soft-tissue tunnel was created bluntly, deep to the LCL, and the graft was passed between this



**Fig 1.** An image of a 10-mm wide small Richard's staple (Smith & Nephew, London, UK) with 25-mm long tines.

interval, from distally to proximally. The supracondylar flare of the femur was then exposed to identify the location for staple fixation just proximal and posterior to the LCL origin. With the knee in 60 to 70° of flexion and the tibia in neutral rotation, the graft was held in slight tension and a 10-mm wide small Richard's staple (Smith & Nephew, London, UK) with 25-mm long tines (Fig 1) was inserted at an approximately 30° angle anterior and distal relative to the axis of the femur. A mallet was then used to impact the staple until it was fully seated. Fluoroscopy was used to obtain a perfect lateral view of the knee to determine staple position.

### Confirmatory Arthroscopy

Following the performance of the LET, the arthroscope was reinserted into the knee and used to visualize the femoral tunnel to confirm or exclude the presence of the staple tine. Any length of the staple tine within the tunnel was considered a positive finding (Fig 2).

### Statistical Analysis

The overall incidence of tunnel violation was reported with regard to the use of a FR and RR. A Fischer exact test was conducted to determine whether there was any statistically significant difference in tunnel violation between the 2 techniques for ACL femoral tunnel creation. Significance was set at  $P \leq .05$ .

### Results

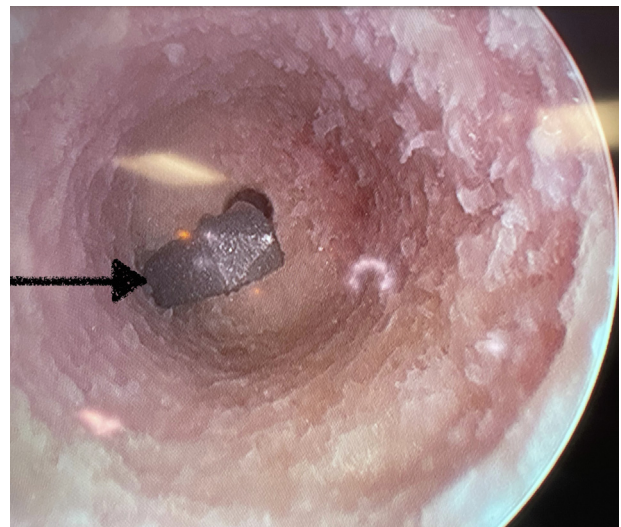
The staple was noted to violate the ACL femoral tunnel in 8 of 20 (40%) of the extremities (Table 1). When stratified by tunnel creation technique, the Richard's staple penetrated 5 of 10 (50%) of the tunnels created via a RR compared with 3 of 10 (30%) of those

created with a FR ( $P = .65$ ). The difference in incidence of tunnel penetration with respect to the technique used for femoral tunnel creation was not statistically significantly different. In addition, it was noted that the position of the small Richard's staple on lateral fluoroscopy was highly variable despite close attention to the previously mentioned landmarks.

### Discussion

The most important finding of this study is that there is a high incidence of femoral tunnel violation in ACL-R with concomitant LET using staple fixation. Femoral tunnel violation was observed with both FR and RR techniques for femoral tunnel creation, and the incidence of these events did not significantly differ between the respective technique used. The results of this study are clinically relevant, as femoral tunnel violation by the staple yields potential for disruption of ACL graft fixation and subsequent failure of the reconstruction. Therefore, surgeons may consider adjustments to operative technique, sequence, or fixation devices used when performing ACL-R with concomitant LET to avoid the potential for disruption of ACL graft fixation.

Several previous studies have documented the high risk of tunnel convergence that exists between the ACL femoral tunnel and LET tunnel with the use of interference screws or suture anchors for LET graft fixation.<sup>18-23</sup> In a study of 30 cadaver knees, Smeets et al.<sup>20</sup> reported tunnel convergence occurred in two-thirds of cases. Jaecker et al.<sup>19</sup> also reported a similar incidence, finding that tunnel convergence occurred in 7 of 10



**Fig 2.** An arthroscopic view of the femoral ACL tunnel of a right knee from the anteromedial portal demonstrating violation of the ACL femoral tunnel by a tine of the small Richard's staple (arrow) when it is being used for LET graft fixation concomitantly during ACL reconstruction. (ACL, anterior cruciate ligament.)

**Table 1.** Results of Femoral Tunnel Violation by Specimen, Laterality, and Reaming Technique

Specimen No.	Laterality	Technique	LET Staple in Tunnel
1	R	RR	N
	L	FR	Y
2	R	FR	Y
	L	RR	Y
3	R	RR	N
	L	FR	Y
4	R	FR	N
	L	RR	Y
5	R	RR	N
	L	FR	N
6	R	RR	N
	L	FR	Y
7	R	RR	Y
	L	FR	N
8	R	FR	Y
	L	RR	N
9	R	RR	N
	L	FR	N
10	R	FR	N
	L	RR	N

ACL, anterior cruciate ligament; FR, flexible reaming technique; L, left; N, staple absent in ACL femoral tunnel; R, right; RR, rigid reaming technique; Y, staple present in ACL femoral tunnel.

cadaver knees in their series. Perelli et al.<sup>22</sup> reported evidence of tunnel convergence on postoperative computed tomography scans in 8 of 52 (15.38%) patients who had undergone combined ACL-R and LET.

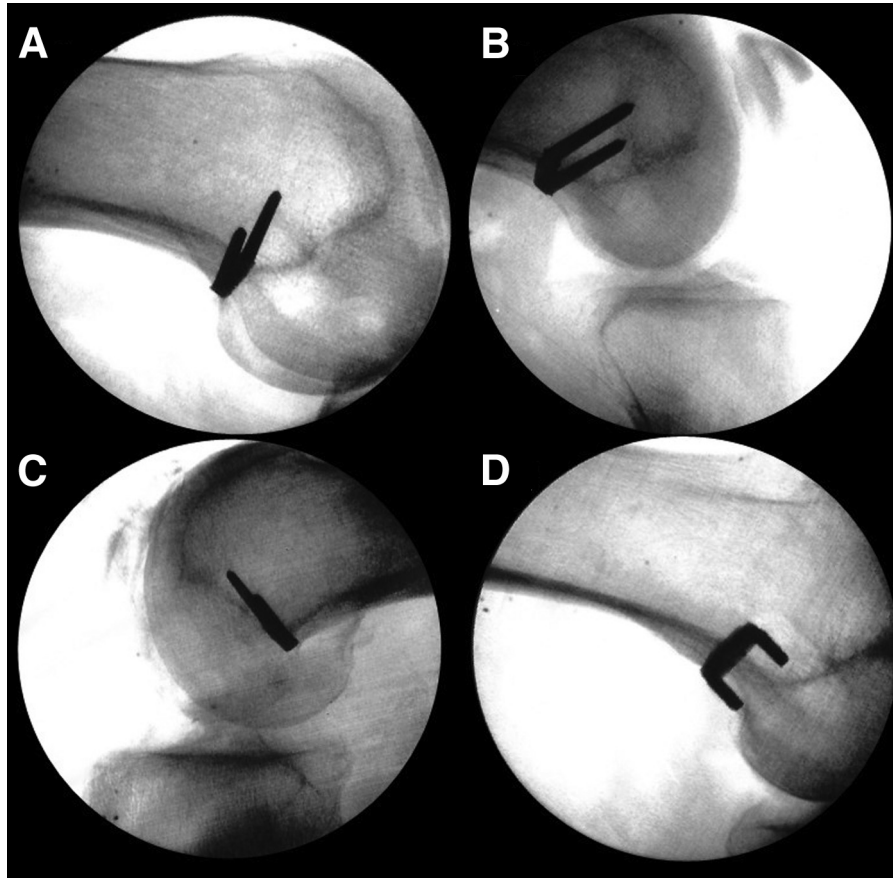
Although a purported advantage of Richard's staple fixation for the LET includes avoiding tunnel convergence, staple violation of the ACL femoral tunnel may theoretically carry a similar risk profile to tunnel convergence.<sup>18-23</sup> This study demonstrates that there is still a high rate of tunnel penetration with a small Richard's staple. Several concerns stem from this observation. Although numerous methods of ACL graft femoral fixation exist, most commonly this is performed with the use of interference screws or suspensory fixation devices.<sup>24,25</sup> The metallic staple theoretically risks damaging these devices and causing a disruption to graft fixation. There also exists the potential for damage to be incurred by the ACL graft itself. Quadriceps tendon grafts are becoming increasingly popular, and hamstring grafts remain commonly used.<sup>26</sup> The effect on a soft-tissue graft's strength and integrity if it is pierced by a staple has not been examined. While a graft containing a bone block may theoretically be less affected, this impact is also unknown.

Given the potential for damage to the ACL graft and disruption of fixation, adjustments to ACL-R operative technique, sequence, or fixation devices used may be considered by surgeons performing concomitant ACL-R and LET. A complex interplay of variables in ACL-R and LET techniques determine whether graft fixation interference will occur when these procedures are

performed concomitantly. With regard to ACL femoral tunnel creation, different methods may alter tunnel geometry into a more or less advantageous position for avoiding interference with LET graft fixation. The use of the FR for femoral tunnel creation results in a more anteverted femoral tunnel position compared with the use of a RR, whereas the intra-articular femoral tunnel aperture location is not different.<sup>27</sup> Although this difference in resultant tunnel geometry has been described, there was no significant difference in tunnel violation seen in this study depending on technique used. Outside-in ACL femoral tunnel creation also has been suggested by several authors to potentially allow more precise femoral tunnel positioning and reduce convergence with LET graft fixation, but has not presently been compared with other modern anatomic techniques.<sup>19,20</sup> Degree of knee flexion during ACL femoral tunnel creation also yields a differing tunnel orientation within the femur.<sup>27,28</sup> Kittl et al.<sup>18</sup> found that ACL femoral tunnel creation in lesser degrees of knee flexion (110-120° vs 130-140°) reduced the incidence of femoral tunnel conflict in combined ACL-R using an AMP technique and LET. Our study used uniform knee flexion during femoral tunnel creation, and we did not examine this as an independent variable affecting tunnel violation.

Insertion point, orientation, and depth of LET fixation devices also impact the occurrence of interference with the ACL femoral tunnel. Although the isometric footprint for the LET procedure limits wide variations in insertion point for fixation devices, adjustments to insertion point for LET graft fixation have been reported to lead to differences in convergence. Jaeger et al. found fewer occurrences of convergence using the more proximal MacIntosh insertion point versus the more distal insertion point described by Lemaire.<sup>19,29,30</sup> In their study, convergence did not occur with the MacIntosh insertion point, whereas tunnel convergence occurred in 7 of 10 cases (70%) using the Lemaire insertion point.<sup>19</sup> In a cadaveric study, Kittl et al.<sup>18</sup> also reported that an insertion point 5 mm proximal and 5 mm anterior to the lateral epicondyle resulted in a 15% incidence of convergence versus 40% when an insertion point 8 mm proximal and 4 mm posterior was used. Therefore, a more anterior tunnel orientation in the axial plane has been advocated by multiple authors as being advantageous in avoiding convergence. Despite the purported advantage to a more anterior insertion point, this risks a nonisometric graft, as Jaeger et al.<sup>31</sup> described the radiographic landmarks for isometric femoral attachment of an LET graft being posterior to the femoral cortical line and proximal to the posterior femoral condyle.

Orientation of the tunnel may have a significant effect, as several authors describe a significant decreased incidence in convergence with the LET



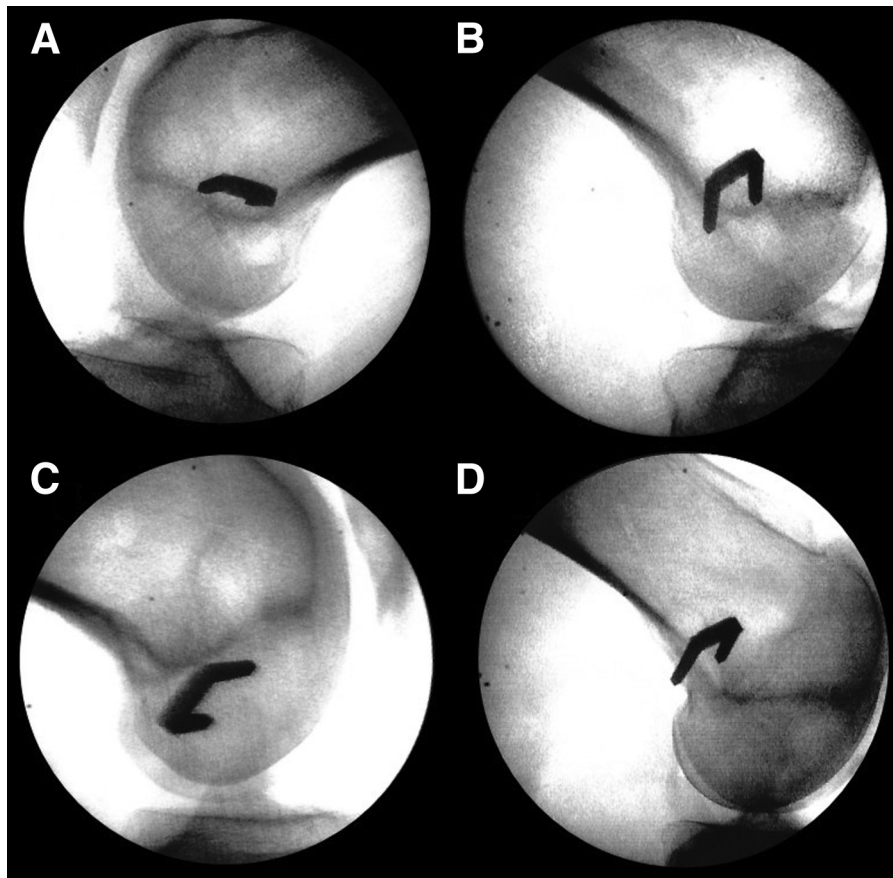
**Fig 3.** Four different example fluoroscopy images that depict staples that violated the ACL femoral tunnel when used concomitantly for LET graft fixation. The multiple images show the variability in placement location and angle of these staples when used for this purpose. (A) A lateral fluoroscopic view of a right knee demonstrating good positioning of the small Richard's staple. (B) A lateral fluoroscopic view of a right knee demonstrating excessive anterior angulation of the small Richard's staple. (C) A lateral fluoroscopic view of a left knee demonstrating a small Richard's staple located distal and anterior with excessive anterior angulation. (D) A lateral fluoroscopic view of a right knee demonstrating posterior placement of the small Richard's staple with the posterior tine abutting the posterior cortex of the femur. (ACL, anterior cruciate ligament; LET, lateral extra-articular tenodesis.)

tunnel directed 30° anteriorly.<sup>18,20-22,32</sup> Length of tunnel also impacts risk of interference. Zhu et al.<sup>32</sup> found that although tunnel convergence occurred at a mean LET tunnel depth of 23.6 mm, it may even happen at a depth of as little as 15 mm.

Notably, these aforementioned studies only examined the impact of technical modifications to ACL-R and LET with regard to the use of interference screw fixation of the LET graft. Similar adjustments to these variables have not been examined using staple fixation of the LET graft, although similar principles affecting interference of ACL and LET graft fixation may apply to a varying magnitude. The ideal combination of technical components to avoid interference with graft fixation remains to be determined, but surgeons performing combined ACL-R and LET should be aware of the interplay between variables that may result in this occurrence. Surgeons also may perform the LET

procedure after femoral tunnel drilling, but before graft passage, similar to what was done in our study. Any observation of the staple within the femoral tunnel would allow for adjustment to the staple position before ACL graft fixation.

In addition, although not a primary outcome measure of the current study, fluoroscopy enabled us to demonstrate a highly variable position of the Richard's staple even when using well-documented landmarks (Figs 3 and 4). In light of this, the use of anatomic landmarks alone may not be sufficient to ensure consistent and replicable positioning of the staple. Therefore, consideration should be given to placing the staple under fluoroscopy. The senior author uses a fluoroscopic shot after placing femoral and tibial guidewires to verify appropriate ACL-R tunnel position before drilling. Using fluoroscopy for this additional step would yield a more consistent location for the



**Fig 4.** Four different example fluoroscopy images that depict staples that did not violate the ACL femoral tunnel when used concomitantly for LET graft fixation. The multiple images show the variability in placement location and angle of these staples when used for this purpose. (A) A lateral fluoroscopic view of a left knee demonstrating good positioning of the small Richard's staple. (B) A lateral fluoroscopic view of a right knee demonstrating excessive posterior angulation of the small Richard's staple. (C) A lateral fluoroscopic view of a right knee demonstrating distal placement of the small Richard's staple. (D) A lateral fluoroscopic view of a right knee demonstrating posterior placement of the small Richard's staple with the posterior tine abutting the posterior cortex of the femur. (ACL, anterior cruciate ligament; LET, lateral extra-articular tenodesis.)

staple as well as potentially help avoid the femoral tunnel.

### Limitations

There are several limitations of note. First, although the sample size was relatively small, the number included is similar to, or exceeds, other cadaveric studies in the literature that have assessed risk of tunnel convergence with combined ACL-R and LET.<sup>18-20,22,32</sup> Our study also used the LET surgical technique described by Jesani and Getgood,<sup>14</sup> and therefore the specific incidences of femoral tunnel violation will relate to this respective method. The insertion point and orientation of the staple placed via this technique critically influence its relationship to the ACL femoral tunnel. However, there exists a relative lack of specificity of these variables in this description, as well as others throughout the literature. It cannot be ruled out that a differing insertion point and orientation for staple

placement would result in greater or fewer instances of tunnel violation. Additional research should better characterize a safe and reproducible position of staples placed for LET graft fixation. In addition, our study was not powered to detect a statistically significant difference in tunnel penetration rates based on reaming method. However, this was not the primary purpose of the study.

### Conclusions

A high incidence of femoral tunnel violation is seen with lateral extra-articular tenodesis staple fixation.

### References

1. Ellman MB, Sherman SL, Forsythe B, LaPrade RF, Cole BJ, Bach BR. Return to play following anterior cruciate ligament reconstruction. *J Am Acad Orthop Surg* 2015;23:283-296.

2. Kaeding CC, Léger-St-Jean B, Magnussen RA. Epidemiology and diagnosis of anterior cruciate ligament injuries. *Clin Sports Med* 2017;36:1-8.
3. Gornitzky AL, Lott A, Yellin JL, Fabricant PD, Lawrence JT, Ganley TJ. Sport-specific yearly risk and incidence of anterior cruciate ligament tears in high school athletes: A systematic review and meta-analysis. *Am J Sports Med* 2016;44:2716-2723.
4. Webster KE, Feller JA. Exploring the high reinjury rate in younger patients undergoing anterior cruciate ligament reconstruction. *Am J Sports Med* 2016;44:2827-2832.
5. Grassi A, Kim C, Marcheggiani Muccioli GM, Zaffagnini S, Amendola A. What is the mid-term failure rate of revision ACL reconstruction? A systematic review. *Clin Orthop Relat Res* 2017;475:2484-2499.
6. Magnussen RA, Reinke EK, Huston LJ, et al. Effect of high-grade preoperative knee laxity on 6-year anterior cruciate ligament reconstruction outcomes. *Am J Sports Med* 2018;46:2865-2872.
7. Ayeni OR, Chahal M, Tran MN, Sprague S. Pivot shift as an outcome measure for ACL reconstruction: a systematic review. *Knee Surg Sports Traumatol Arthrosc* 2012;20:767-777.
8. Kocher MS, Steadman JR, Briggs KK, Sterett WL, Hawkins RJ. Relationships between objective assessment of ligament stability and subjective assessment of symptoms and function after anterior cruciate ligament reconstruction. *Am J Sports Med* 2004;32:629-634.
9. Song GY, Hong L, Zhang H, Zhang J, Li Y, Feng H. Clinical outcomes of combined lateral extra-articular tenodesis and intra-articular anterior cruciate ligament reconstruction in addressing high-grade pivot-shift phenomenon. *Arthroscopy* 2016;32:898-905.
10. Rezende FC, de Moraes VY, Martimbianco ALC, Luzo MV, da Silveira Franciozi CE, Belloti JC. Does combined intra- and extraarticular ACL reconstruction improve function and stability? A meta-analysis. *Clin Orthop Relat Res* 2015;473:2609-2618.
11. Weber AE, Zuke W, Mayer EN, et al. Lateral augmentation procedures in anterior cruciate ligament reconstruction: Anatomic, biomechanical, imaging, and clinical evidence. *Am J Sports Med* 2019;47:740-752.
12. Hewison CE, Tran MN, Kaniki N, Remtulla A, Bryant D, Getgood AM. Lateral extra-articular tenodesis reduces rotational laxity when combined with anterior cruciate ligament reconstruction: A systematic review of the literature. *Arthroscopy* 2015;31:2022-2034.
13. Getgood AMJ, Bryant DM, Litchfield R, et al. Lateral Extra-articular tenodesis reduces failure of hamstring tendon autograft anterior cruciate ligament reconstruction: 2-year outcomes from the STABILITY Study Randomized Clinical Trial. *Am J Sports Med* 2020;48:285-297.
14. Jesani S, Getgood A. Modified Lemaire lateral extra-articular tenodesis augmentation of anterior cruciate ligament reconstruction. *JBJS Essent Surg Tech* 2019;9:e41.1-7.
15. Inderhaug E, Stephen JM, Williams A, Amis AA. Anterolateral tenodesis or anterolateral ligament complex reconstruction: Effect of flexion angle at graft fixation when combined with ACL reconstruction. *Am J Sports Med* 2017;45:3089-3097.
16. Inderhaug E, Stephen JM, Williams A, Amis AA. Biomechanical comparison of anterolateral procedures combined with anterior cruciate ligament reconstruction. *Am J Sports Med* 2017;45:347-354.
17. Geeslin AG, Moatshe G, Chahla J, et al. Anterolateral knee extra-articular stabilizers: A robotic study comparing anterolateral ligament reconstruction and modified Lemaire lateral extra-articular tenodesis. *Am J Sports Med* 2018;46:607-616.
18. Kittl C, Schwietering L, Raschke MJ, et al. Tunnel convergence rate in combined anteromedial portal anterior cruciate ligament and anterolateral structure reconstructions is influenced by anterior cruciate ligament knee flexion angle, tunnel position, and direction. *Arthroscopy* 2022;38:860-869.
19. Jaecker V, Ibe P, Endler CH, Pfeiffer TR, Herbolt M, Shafizadeh S. High risk of tunnel convergence in combined anterior cruciate ligament reconstruction and lateral extra-articular tenodesis. *Am J Sports Med* 2019;47:2110-2115.
20. Smeets K, Bellemans J, Lamers G, et al. High risk of tunnel convergence during combined anterior cruciate ligament and anterolateral ligament reconstruction. *Knee Surg Sports Traumatol Arthrosc* 2019;27:611-617.
21. Smeets K, Van Haver A, Van den Bempt S, et al. Risk analysis of tunnel collision in combined anterior cruciate ligament and anterolateral ligament reconstructions. *Knee* 2019;26:962-968.
22. Perelli S, Erquicia JI, Ibañez M, et al. Evaluating for tunnel convergence in anterior cruciate ligament reconstruction with modified Lemaire tenodesis: What is the best tunnel angle to decrease risk? *Arthroscopy* 2020;36:776-784.
23. Kwapisz A, Mollison S, McRae S, MacDonald P. Lateral extra-articular tenodesis with proximal staple fixation. *Arthrosc Tech* 2019;8:e821-e825.
24. Hapa O, Barber FA. ACL fixation devices. *Sports Med Arthrosc Rev* 2009;17:217-223.
25. Harvey A, Thomas NP, Amis AA. Fixation of the graft in reconstruction of the anterior cruciate ligament. *J Bone Joint Surg Br* 2005;87:593-603.
26. Xerogeanes JW. Quadriceps tendon graft for anterior cruciate ligament reconstruction: The graft of the future. *Arthroscopy* 2019;35:696-697.
27. Moran TE, Ignozzi AJ, Werner BC. Comparing the use of flexible and rigid reaming systems through an anteromedial portal for femoral tunnel creation during anterior cruciate ligament reconstruction: A systematic review. *Orthop J Sports Med* 2021;9:23259671211035740.
28. Basdekis G, Abisafi C, Christel P. Influence of knee flexion angle on femoral tunnel characteristics when drilled through the anteromedial portal during anterior cruciate ligament reconstruction. *Arthroscopy* 2008;24:459-464.
29. Ireland J, Trickey EL. Macintosh tenodesis for anterolateral instability of the knee. *J Bone Joint Surg Br* 1980;62:340-345.

30. Lemaire M, Combelles F. Plastic repair with fascia lata for old tears of the anterior cruciate ligament (author's transl). *Rev Chir Orthop Reparatrice Appar Mot* 1980;66: 523-525 [in French].
31. Jaeger V, Naendrup JH, Pfeiffer TR, Bouillon B, Shafizadeh S. Radiographic landmarks for femoral tunnel positioning in lateral extra-articular tenodesis procedures. *Am J Sports Med* 2019;47:2572-2576.
32. Zhu M, Han Lee DY, Williams A. Safe femoral fixation depth and orientation for lateral extra-articular tenodesis in anterior cruciate ligament reconstruction. *Orthop J Sports Med* 2021;9:2325967120976591.