

Contents lists available at [ScienceDirect](http://www.sciencedirect.com)

International Journal of Surgery Case Reports

journal homepage: www.casereports.com

Totally extra-peritoneal repair for acute incarcerated femoral hernia with intestinal obstruction

Guowei Kim^a, Jimmy Bok Yan So^b, Asim Shabbir^{a,*}^a University Surgical Cluster, National University Health System, Department of Surgery, Yong Loo Lin School of Medicine, National University of Singapore, Singapore^b Senior Consultant National University Hospital, Professor of Surgery National University of Singapore, Department of Surgery, Singapore

ARTICLE INFO

Article history:

Received 31 October 2016

Accepted 14 January 2017

Available online 17 January 2017

Keywords:

Totally extra-peritoneal repair

Femoral hernia

Incarcerated

Obstructed

Case report

ABSTRACT

INTRODUCTION: Femoral hernias frequently present with incarceration, resulting in obstruction and strangulation. Laparoscopic groin hernia repairs have been shown in the elective setting to be an effective alternative to open repair. Acute incarceration of groin hernia with obstruction, though previously seen as a relative contraindication, has been increasingly repaired with minimally invasive techniques, with the potential benefit of avoiding the morbidity associated with a laparotomy.

PRESENTATION OF CASE AND DISCUSSION: We describe a case of an acutely incarcerated femoral hernia with intestinal obstruction that was repaired using the totally extra-peritoneal approach. A releasing incision was performed to facilitate reduction of hernia prior to mesh repair. Diagnostic laparoscopy through a separate incision was then performed.

CONCLUSION: This modification of the TEP repair technique for the acutely incarcerated and obstructed femoral hernia serves to minimise potential contamination by keeping the pre-peritoneal plane strictly separate from the intra-peritoneal space.

© 2017 The Authors. Published by Elsevier Ltd on behalf of IJS Publishing Group Ltd. This is an open access article under the CC BY-NC-ND license (<http://creativecommons.org/licenses/by-nc-nd/4.0/>).

1. Introduction

Femoral hernias frequently present with incarceration, resulting in obstruction and strangulation [1]. This has resulted in about 35–43% of femoral hernias presenting commonly as a surgical emergency with high rates of laparotomy and bowel resection [2–4]. Laparoscopic hernia repairs in the elective setting has been shown to have comparable recurrence rate with less persisting pain and numbness and quicker return to usual activities when compared with open mesh repair [5]. However, incarceration has traditionally been seen as a relative contraindication for minimally invasive approaches. This has been attributed to technical difficulties with regards to reduction of the incarcerated hernia contents as well as increased risk for iatrogenic injuries.

The first reported laparoscopic approach to incarcerated femoral hernia was in 1993, which described an exploratory laparoscopy, trans abdominal pre-peritoneal repair (TAPP), followed by exteriorisation of non-viable small bowel through umbilical incision and small bowel resection [6]. To our knowledge, this is the first report of utilising a totally extra-peritoneal (TEP) approach followed by a separate diagnostic laparoscopy to an incarcerated femoral hernia in an emergent setting. The patient was managed in a tertiary

university hospital with the surgery performed by a senior surgical trainee with a senior consultant surgeon. This case report has been reported in line with Surgical Case Report (SCARE) guidelines [7].

2. Presentation of case

We report a sixty-three-year-old Chinese female who presented who presented with intestinal obstruction secondary to an incarcerated left femoral hernia (Fig. 1). She underwent emergent laparoscopic TEP repair (Fig. 2). Under general anaesthesia, the patient was positioned supine in a 15° Trendelenburg position. An infra-umbilical incision slightly to the right of the midline was made and the anterior rectus sheath entered. The pre-peritoneal space was created with blunt dissection with the aid of CO2 gas insufflation to a pressure of 12 mmHg. The femoral hernia was dissected and the constricting femoral ring was released with a relaxing incision of the lacunar ligament medially. Following reduction of the hernia contents and inversion of the sac, a 10 × 15 cm titanised polypropylene mesh was placed and the pre-peritoneal space was deflated under direct vision. Following this, the anterior sheath and skin were closed. A new supra-umbilical incision was then made and the peritoneal cavity was entered with open technique. Laparoscopy was performed with the aid of a 5 mm working port in the right iliac fossa. A bruised but viable segment of dilated small bowel was identified. Pneumoperitoneum was then released and this incision was then closed. She recovered well from surgery with no evidence of recurrence six months after surgery.

* Corresponding author at: University Surgical Cluster, National University Health System, Level 8 NUHS Tower Block, 1E Kent Ridge Road, 119228, Singapore.
E-mail address: cfsasim@nus.edu.sg (A. Shabbir).

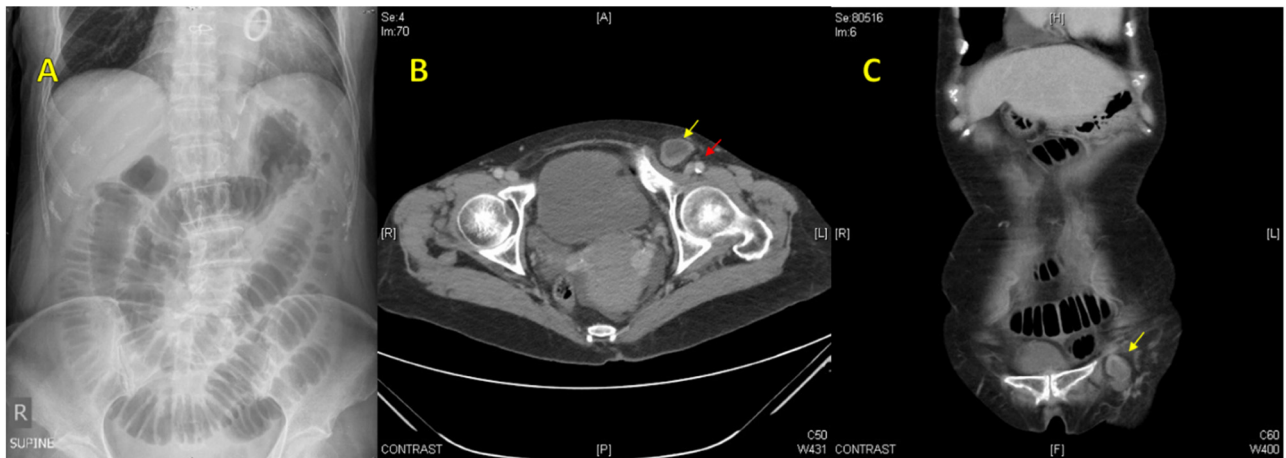


Fig. 1. A- Abdominal radiograph showing small bowel obstruction. B,C- Axial and coronal computed tomography images showing an incarcerated femoral hernia (yellow arrow) and adjacent femoral vessels (red arrow).

3. Discussion

The drive for a minimally invasive approach is probably fuelled by the relatively high rates of bowel resection (15.4–19.5%) [3,4,8] and the need for an additional laparotomy (11.1%) [2]. Though the first laparoscopic case was described in 1993, there were few reports of minimally invasive approaches to this problem until the turn of the century. This hesitance could probably be attributed to the relatively steep learning curve during the early days of laparoscopic surgery compounded by the additional technical difficulty of performing laparoscopic surgery in a patient who has obstructed or strangulated bowel. The turn of the century brought about the use of diagnostic laparoscopy to evaluate incarcerated groin hernias [9]. Soon after, reports of the use of TAPP [10–15] and TEP [16–21] in the repair of emergent groin hernias followed, with a systemic reviews showing encouraging operative times, hospital stay and morbidity [22]. Further reports demonstrated a reduction in laparotomy rates with less wound infection and shorter hospitalisation when comparing laparoscopic to open approaches [23].

The reduction of hernia contents laparoscopically with TAPP or TEP can be challenging. The use of releasing incision to the constricting hernia neck has been well described [14,17]. For femoral hernias, a releasing incision medially in the lacunar ligament can help facilitate reduction. However, care must be taken when there is an aberrant obturator artery. This incision should be performed with scissors without diathermy, to avoid collateral heat injury to the contents of the hernia at the neck.

Advocates of TAPP have suggested that the benefits of this method of repair allows for diagnostic laparoscopy to be performed first followed by intraperitoneal reduction of the incarcerated bowel. TAPP is then performed and upon completion, the affected bowel is re-inspected to assess for viability. Resection can then be carried out via a small laparotomy if necessary. An additional advantage with this method is that additional time is given while performing the TAPP to reassess for bowel viability [11]. However, TAPP can be technically challenging due to dilated bowel limiting exposure. There is added risk of intra-abdominal complications as well, especially during the insertion of ports.

TEP repair, in our opinion, is technically easier than TAPP in the obstructed patient. The gaseous distension of the pre-peritoneal plane utilises the peritoneum as a natural “retractor”, pushing the distended intra-peritoneal bowel loops away. Furthermore, entry into the pre-peritoneal plane can be performed safely. However, for TEP repair in the emergent setting, assessment of the bowel is mandatory. This can be achieved by opening the sac [17,19], or by performing a diagnostic laparoscopy either before [18,21,23] or after [16,19] performing TEP repair. Opening the sac can be hazardous with one incidence of cecal injury reported for a sliding hernia [17]. Furthermore, this often results in loss of space in the pre-peritoneal plane due to peritoneal distension, which negates the advantage of TEP over TAPP stated earlier. The same difficulty can occur when performing diagnostic laparoscopy first, as prior gaseous distension of the peritoneal cavity can subsequently limit TEP repair if insufficiently or inadequately decompressed. One suggested method to circumvent this problem would be to perform

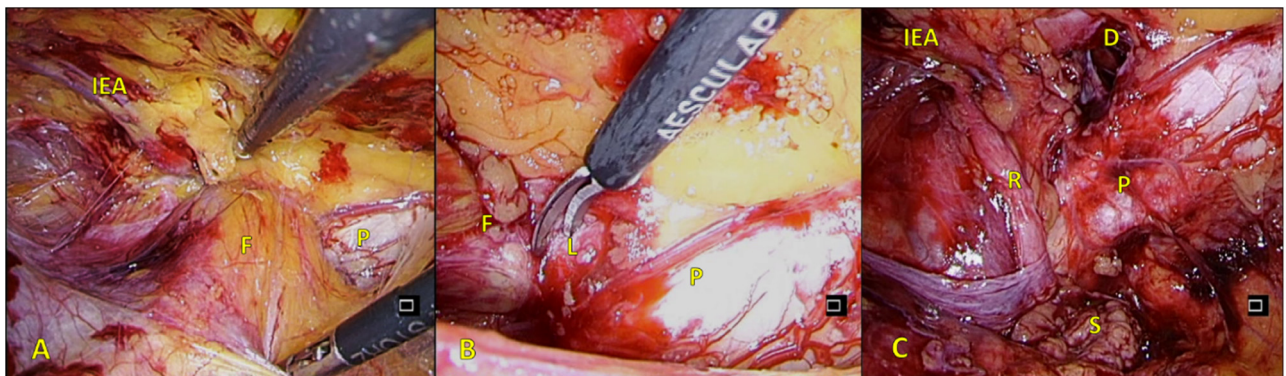


Fig. 2. A- Incarcerated femoral hernia. B- Medial incision of the lacunar ligament. C- After reduction of hernia. Femoral hernia (F), Inferior epigastric artery (IEA), Pubic tubercle (P), Lacunar ligament (L), Round ligament (R), Hernia sac (S), Femoral hernia defect (D).

laparoscopy and reduction with or without bowel resection first, followed by a staged TEP repair 8–24 days later [20]. This would also help to reduce the risk of contamination from gangrenous bowel and during bowel resection. However, the obvious drawback would be that a second general anaesthesia would be required. There is also a potential risk of recurrent acute obstruction or strangulation while waiting for the second surgery. We favour the approach of performing a diagnostic laparoscopy after TEP repair. This is because it gives a similar advantage as stated for TAPP earlier, which allows for a sufficient time from reduction to bowel inspection. Furthermore, the releasing incision can be made during TEP without breach of the peritoneum, which would occur when performing diagnostic laparoscopy with reduction prior to TEP. We prefer to completely close the anterior sheath and skin incisions used for TEP repair and to perform a separate entry into the abdomen for laparoscopy. These steps minimise potential contamination should bowel resection be required by keeping the pre-peritoneal plane strictly separate from the intra-peritoneal space.

4. Conclusion

Our case report highlights a modification of the TEP with laparoscopy technique for emergent groin hernia repair, advocating separate incisions for each procedure to minimise potential contamination should bowel resection be necessary. However, it has to be stressed that patient selection is still paramount, as it should not be used for the septic, unstable patient with high suspicion of bowel perforation. Furthermore, laparoscopic repair of hernias in the emergent setting with obstruction or strangulation is technically demanding and should only be attempted by an experienced laparoscopic surgeon.

Conflicts of interest

Guowei Kim and Asim Shabbir have no conflicts of interest to declare for this case report.

Funding

This research did not receive any specific grant from funding agencies in the public, commercial, or not-for-profit sectors.

Ethical approval

Not applicable.

Consent

The patient has consented to the use of the case details (unidentified) for research purposes.

Authors contribution

The authors, Guowei Kim, Jimmy BY So and Asim Shabbir contributed to the study concept or design, data collection, data analysis or interpretation and writing the paper.

Registration of research studies

Not applicable

Guarantors

Guowei Kim, Jimmy BY So, Asim Shabbir.

References

- [1] N.C. Gallegos, J. Dawson, M. Jarvis, M. Hobsley, Risk of strangulation in groin hernias, *Br. J. Surg.* 78 (10) (1991) 1171–1173.
- [2] O. Alimoglu, B. Kaya, I. Okan, F. Dasiran, D. Guzey, G. Bas, et al., Femoral hernia: a review of 83 cases, *Hernia* 10 (1) (2006) 70–73.
- [3] B.J. Ge, Q. Huang, L.M. Liu, H.P. Bian, Y.Z. Fan, Risk factors for bowel resection and outcome in patients with incarcerated groin hernias, *Hernia* 14 (3) (2010) 259–264.
- [4] G. Sandblom, S. Haapaniemi, E. Nilsson, Femoral hernias: a register analysis of 588 repairs, *Hernia* 3 (3) (1999) 131–134.
- [5] K. McCormack, N.W. Scott, P.M. Go, S. Ross, A.M. Grant, Laparoscopic techniques versus open techniques for inguinal hernia repair, *Cochrane Database Syst. Rev.* [Internet] (January (1)) (2003) [cited 2016 Mar 28], CD001785, Available from: <http://www.ncbi.nlm.nih.gov/pubmed/12535413>.
- [6] S.D. Watson, W. Saye, P.A. Hollier, Combined laparoscopic incarcerated herniorrhaphy and small bowel resection, *Surg. Laparosc. Endosc.* (1993) 106–108.
- [7] R.A. Agha, A.J. Fowler, A. Saeta, I. Barai, S. Rajmohan, D.P. Orgill, The SCARE statement: consensus-based surgical case report guidelines, *Int. J. Surg.* [Internet] 34 (2016) 180–186 (Available from: <http://linkinghub.elsevier.com/retrieve/pii/S174391911630303X>).
- [8] J.A. Álvarez, R.F. Baldonedo, I.G. Bear, J.A.S. Solís, P. Álvarez, J.I. Jorge, Incarcerated groin hernias in adults: presentation and outcome, *Hernia* 8 (2) (2004) 121–126.
- [9] M.I. Lavonius, J. Ovaska, Laparoscopy in the evaluation of the incarcerated mass in groin hernia, *Surg. Endosc.* 14 (5) (2000) 488–489.
- [10] B.J. Leibl, C.G. Schmedt, K. Kraft, B. Kraft, R. Bittner, Laparoscopic transperitoneal hernia repair of incarcerated hernias: is it feasible? Results of a prospective study, *Surg. Endosc.* 15 (10) (2001) 1179–1183.
- [11] R.B. Jagad, J. Shah, G.R. Patel, The laparoscopic transperitoneal approach for irreducible inguinal hernias: perioperative outcome in four patients, *J. Minim. Access Surg.* [Internet] 5 (April (2)) (2009) 31–34 [cited 2016 Mar 27], Available from: <http://www.pubmedcentral.nih.gov/articlerender.fcgi?artid=2734896&tool=pmcentrez&rendertype=abstract>.
- [12] C. Rebuffat, A. Galli, M.S. Scalambra, F. Balsamo, Laparoscopic repair of strangulated hernias, *Surg. Endosc. Other Interv. Tech.* 20 (1) (2006) 131–134.
- [13] G.L. Legnani, M. Rasini, S. Pastori, D. Sarli, Laparoscopic trans-peritoneal hernioplasty (TAPP) for the acute management of strangulated inguino-crural hernias: a report of nine cases, *Hernia* 12 (2) (2008) 185–188.
- [14] K.-K. Yau, W.-T. Siu, Cheung Y-SH, Wong C-HJ, Chung C-CC, Li K-WM, Laparoscopic management of acutely incarcerated femoral hernia, *J. Laparoendosc. Adv. Surg. Tech.* 17 (6) (2007) 759–762, <http://dx.doi.org/10.1089/lap.2006.0231>, Available from: <http://www.liebertonline.com>.
- [15] T. Ishihara, K. Kubota, N. Eda, S. Ishibashi, Y. Haraguchi, Surgical endoscopy laparoscopic approach to incarcerated inguinal hernia, *Crit. Care* 111 (1996) 1–3.
- [16] F. Mainik, R. Flade-Kuthe, A. Kuthe, [Total extraperitoneal endoscopic hernioplasty (TEP) in the treatment of incarcerated and irreparable inguinal and femoral hernias], *Zentralblatt für Chir* [Internet] 130 (December (6)) (2005) 550–553 [cited 2016 Mar 27], Available from: <http://www.ncbi.nlm.nih.gov/pubmed/16382403>.
- [17] G. Ferzli, K. Shapiro, G. Chaudry, S. Patel, Laparoscopic extraperitoneal approach to acutely incarcerated inguinal hernia, *Surg. Endosc. Other Interv. Tech.* 18 (2) (2004) 228–231.
- [18] M. Maricevich, D. Farley, A pseudo-TEP repair of an incarcerated obturator hernia, *Int. J. Surg. Case Rep.* [Internet] 2 (8) (2011) 290–292, <http://dx.doi.org/10.1016/j.ijscr.2011.09.004>, Elsevier Ltd, Available from: .
- [19] Y.Y. Choi, Z. Kim, K.Y. Hur, Laparoscopic total extraperitoneal repair for incarcerated inguinal hernia, *J. Korean Surg. Soc.* 80 (6) (2011) 426–430.
- [20] A. Sasaki, Y. Takeuchi, K. Izumi, A. Morimoto, M. Inomata, S. Kitano, Two-stage laparoscopic treatment for strangulated inguinal, femoral and obturator hernias: totally extraperitoneal repair followed by intestinal resection assisted by intraperitoneal laparoscopic exploration, *Hernia* 20 (3) (2014) 483–488.
- [21] A. Hoffman, E. Leshem, O. Zmora, O. Nachtom, M. Shabtai, A. Ayalon, et al., The combined laparoscopic approach for the treatment of incarcerated inguinal hernia, *Surg. Endosc. Other Interv. Tech.* 24 (8) (2010) 1815–1818.
- [22] S. Deeba, S. Purkayastha, P. Paraskevas, T. Athanasios, E. Darzi, A. Zacharakis, Laparoscopic approach to incarcerated and strangulated inguinal hernias, *JSL* 13 (3) (2009) 327–331.
- [23] G.P.C. Yang, C.T.Y. Chan, E.C.H. Lai, O.C.Y. Chan, C.N. Tang, M.K.W. Li, Laparoscopic versus open repair for strangulated groin hernias: 188 cases over 4 years, *Asian J. Endosc. Surg.* [Internet] 5 (3) (2012) 131–137 (Available from: <http://www.ncbi.nlm.nih.gov/pubmed/22776668>).

Open Access

This article is published Open Access at [sciencedirect.com](https://www.sciencedirect.com). It is distributed under the [IJSR Supplemental terms and conditions](https://creativecommons.org/licenses/by/4.0/), which permits unrestricted non commercial use, distribution, and reproduction in any medium, provided the original authors and source are credited.