

## Research Article

## Open Access

Hong Ren, Wei Lin, Xianjun Ding\*

# Surface coil intensity correction in magnetic resonance imaging in spinal metastases

DOI 10.1515/med-2017-0021

received February 21, 2017; accepted March 24, 2017

**Abstract:** Objective. To evaluate the clinical application of phased-array surface coil intensity correction in magnetic resonance imaging (MRI) in spinal metastases. Methods. 3 phantoms and 50 patients with a corresponding total number of 80 spinal metastases were included in this study. Fast spin echo T1- and T2- weighted MRI with and without surface coil intensity correction was routinely performed for all phantoms and patients. Phantoms were evaluated by means of variance to mean ratio of signal intensity on both T1- and T2- weighted MRI obtained with and without surface coil intensity correction. Spinal metastases were evaluated by image quality scores; reading time per case on both T1- and T2- weighted MRI obtained with and without surface coil intensity correction. Results. Spinal metastases were diagnosed more successfully on MRI with surface coil intensity correction than on MRI with conventional surface coil technique. The variance to mean ratio of signal intensity was 53.36% for original T1-weighted MRI and 53.58% for original T2-weighted MRI. The variance to mean ratio of signal intensity was reduced to 18.99% for T1-weighted MRI with surface coil intensity correction and 22.77% for T2-weighted MRI with surface coil intensity correction. The overall image quality scores (interface conspicuity of lesion and details of lesion) were significantly higher than those of the original MRI. The reading time per case was shorter for MRI with surface coil intensity correction than for MRI without surface coil intensity correction. Conclusions. Phased-array surface coil intensity correction in MRIs of spinal metastases provides improvements

in image quality that leads to more successfully detection and assessment of spinal metastases than original MRI.

**Keywords:** Magnetic resonance imaging; Spine; Surface coil; RF non-uniformity; Image intensity correction

## 1 Introduction

Magnetic resonance images offer accurate spatial information about human anatomy. A quantitative measurement of sizes and volumes requires a careful segmentation of the different tissues to visualize the lesions or organs of interest. A surface coil provides a very high signal-to-noise ratio (SNR) close to the region where it is used, but it suffers from decreased signal far from the coil. The phased-array surface coil is utilized to overcome the limited coverage of the surface coil by combining the images from two or more coils to produce a signal image. However, the non-uniformity of profile reception of phased-array surface coils still hampers their application. We have evaluated the coil sensitivity modulation from surface coil intensity correction (SCIC), which is used to improve the image homogeneity of magnetic resonance imaging when a phased-array surface coil is used for reception. In this study, SCIC was evaluated for both fast spin echo (FSE) T1-weighted and T2-weighted on a phantom study and on a spinal metastases MRI. Its efficiency was illustrated with the aid of both phantom and spinal metastases MRI.

## 2 Material and methods

### 2.1 Phantom studies

The SCIC method [1,2] was tested with a 1.5 Tesla SIGNA CV/i scanner (GE Medical Systems). To statistically evaluate the effect of the correction method, a homogeneous MRI phantom filled with aqueous copper sulfate solu-

\*Corresponding author: Xianjun Ding, Department of Orthopaedic Surgery, Sir Run Run Shaw Hospital, Zhejiang University School of Medicine, Hangzhou 310016, China, E-mail: xjdinghz@126.com  
Hong Ren, Wei Lin, Department of Radiology, Sir Run Run Shaw Hospital, School of Medicine, Zhejiang University, Hangzhou 310000, China

tion (diameter: 10 cm, 16 cm and 26 cm) was imaged. The MR examination position and protocol of FSE T1- and T2-weighted MRI were constant. The T1-weighted MRIs of the spine were obtained with a 450–500 ms TR range, a 15–20 ms TE, a 192×256 matrix one acquisition, a 3 ms excitation, a 30 cm field of view, a 3 mm slice thickness, a 1 mm interslice gap, and an echo train length (ETL) of two. T2-weighted MRIs of the spine were obtained with a 2000–3000 ms TR range, a 80–120 ms TE range, a 192×256 matrix, one acquisition, a 3 ms excitation, a 30 cm field of view, a 3 mm slice thickness, a 1 mm intersection gap, and an echo train length (ETL) of two.

We analyzed the mean and variance of image signal intensities of the uniform phantom taken with and without SCIC. To calculate these values, the signal intensities of the phantom were measured by placing regions of interest (ROIs). The ROIs for each image was placed at an identical position and size for MRIs with and without SCIC. The variance to mean ratio of signal intensity was used to determine the significance of differences between T1- and T2-weighted MRIs with and without SCIC. For methods, see references [1,2].

## 2.2 Clinical experiments

We retrospectively evaluated the image records of 50 patients with 80 spinal metastases among them who were referred to our department of radiology between July 2011 and June 2014, and who signed an informed consent after full explanation of MR imaging technique. The study had been approved by the ethics committee of Sir Run Run Shaw Hospital, School of Medicine, Zhejiang University. T1- and T2-weighted MRIs with and without SCIC were performed. The study group, including variable spinal metastases, consists of 26 men and 24 women, mean age 61 years (range: 37–80 years). The origins of spinal metastases were identified as being lung cancer in 27 patients, breast cancer in 10 patients, prostate cancer in 6 patients, renal cancer in 4 patients, lymphoma in 1 patient, and ovarian cancer in 2 patients. 50 patients were diagnosed by pathology and biopsy. Two different methods of MRI were obtained at the same time in each patient.

FSE T1- and T2-weighted MRIs of human spine were performed with the same machine and same acquisition parameters as the phantom. Patients were placed in a supine position on the table platform with a standard phased-array surface coil. The pre-saturation technique was used with FSE images to reduce motion artifacts. We selected the No Phase Wrap (NPW) from the imaging option window to prevent aliasing of anatomy inside a

prescribed field of view (FOV); Flow Compensation (FC) was used for gradient moment nulling to decrease flow artifacts.

MRI findings of both groups were evaluated in a random order. The two observers were blind to the patient's clinical information. If there was any disagreement of interpretation, a conference was held to reach a consensus. In the image analysis, MR imaging with and without SCIC were independently compared by two experienced radiologists. They assigned one of five numerical scores (0, non-visualization; 1, poor; 2, average; 3, good; 4, excellent) for the following two image characteristics: interface conspicuity of lesion, and details of lesion on MRI with and without SCIC. The Student's *t*-test was used to determine the significance of differences of MRI with and without SCIC in numerical scores. A significance level of  $\alpha=0.001$  was selected.

Two experienced radiologists independently recorded the reading time per case from 50 cases. A conference was held to reach a consensus. Statistical differences were evaluated with the independent *t*-test; a *P* value of less than 0.05 was considered significant.

## 3 Results

### 3.1 Phantom studies


To more effectively assess the behavior of the SCIC method, a homogenous phantom was imaged. The original image without SCIC is inhomogeneous in signal intensity from the left to the right of the image, which is demonstrated by lower intensity values in the left region of the image than those in the right region, (Fig.1. A and C). The variance to mean ratio of signal intensity was 53.36% for original T1-weighted MRI and 53.58% for original T2-weighted MRI (Table 1, 2). The intensity variation from areas right to left is almost suppressed in the image with SCIC (Fig.1. B and D). The variance to mean ratio of signal intensity is reduced to 18.99% for T1-weighted MRI with SCIC and 22.77% for T2-weighted MRI with SCIC, (Table 1, 2). Thus, SCIC does improve the homogeneity of these images.

### 3.2 Clinical experiments

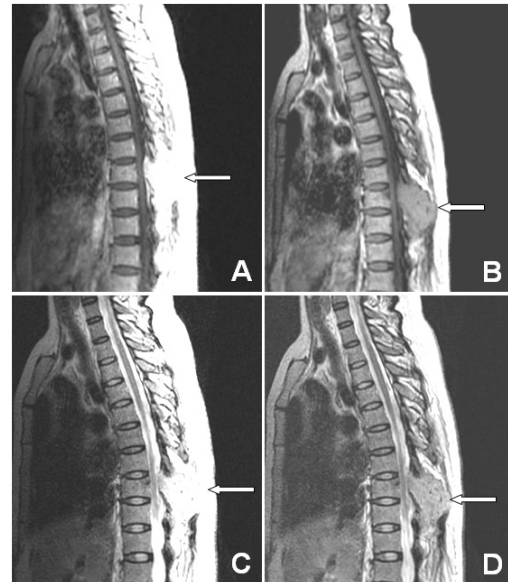
Quality scores of MRI with and without SCIC are summarized in Table 3. Both scores of interface conspicuity and details of lesion with SCIC are significantly higher than those without SCIC. MR images with SCIC decrease inten-

sity near the phased-array surface coil, reducing the areas of bright spots, (Fig.2-4).

Compared with MRI without surface coil intensity correction, the reading time per case was shorter for MRI with surface coil intensity correction (Fig.5). The difference between them is significant.



**Figure 1:** All these images were displayed at the same window and level, diameter 16cm phantom. (A) FSE T1-weighted MRI without SCIC. (B) T1-weighted MRI with SCIC. (C) FSE T2-weighted MRI without SCIC. (D) T2-weighted MRI with SCIC.



**Figure 2:** A 55-year-old man suffered from renal cell cancer with spinal metastasis. (A) In conventional FSE T1-weighted MRI, spinous process of thoracic vertebra (arrow) shows increased signal intensity, but the spinal metastasis margin and its extension is not clear. (B) In FSE T1-weighted MRI with SCIC, the margin and its extension of lesion is clearer than conventional MRI (arrow). (C) In conventional FSE T2-weighted MRI, lesion (arrow) is not clear. (D) In T2-weighted MRI with SCIC, the image clearly shows lesion in spinous process and soft tissue lesion around the vertebrae with more details (arrow).

**Table 1:** Analysis of phantom T1-weighted MRI Quality

Image number	Image with SCIC		Image without SCIC	
	Mean	Variance	Mean	Variance
1	2677.58	515.47	2665.15	1244.11
2	699.51	107.12	701.47	449.03
3	289.44	73.70	290.52	258.40
Mean	1222.18	232.10	1219.05	650.51
Var/mean%	18.99%		53.36%	

Image number 1, diameter 10 cm phantom; Image number 2, diameter 16 cm phantom; Image number 3, diameter 26 cm phantom.

**Table 2:** Analysis of phantom T2-weighted MRI Quality

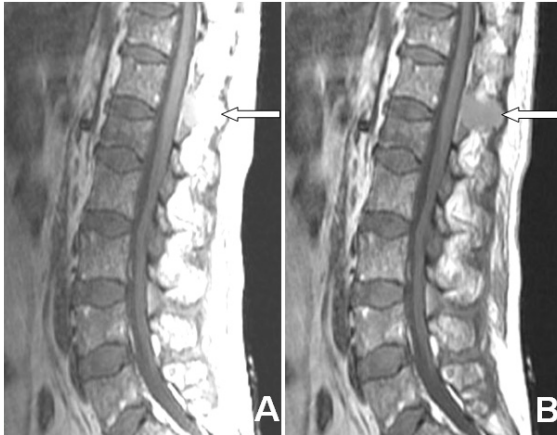
Image number	Image with SCIC		Image without SCIC	
	Mean	Variance	Mean	Variance
1	1123.79	271.78	1153.85	546.00
2	307.95	50.24	310.26	193.00
3	123.50	32.10	125.36	112.58
Mean	518.41	118.04	529.82	283.86
Var/mean%	22.77%		53.58%	

Image number 1, diameter 10 cm phantom; Image number 2, diameter 16 cm phantom; Image number 3, diameter 26 cm phantom.

**Table 3:** Comparison quality scores of MRI with and without SCIC (n=80 lesions)

Image characteristics	T1-weighted MRI		T2-weighted MRI	
	With SCIC	Without SCIC	With SCIC	Without SCIC
Interface conspicuity of lesion	2.34±0.87*	1.20±0.89	2.28±0.86*	1.23±0.84
Details of lesion	2.20±0.86*	1.08±0.81	2.18±0.87*	1.08±0.81

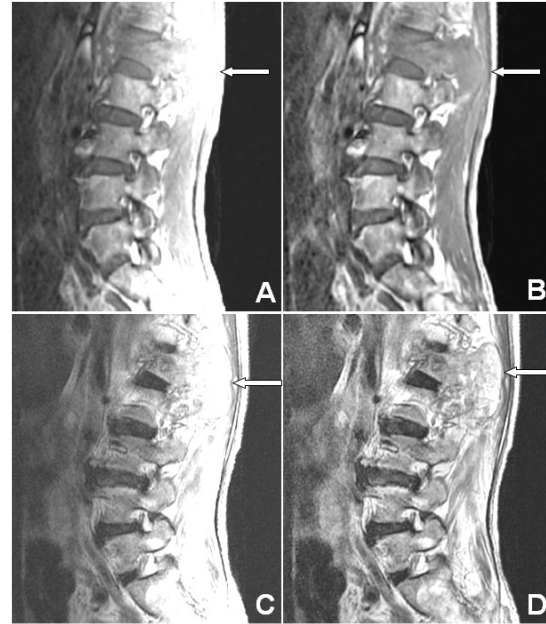Grading system: 0, non-visualization; 1, poor; 2, average; 3, good; 4, excellent. \*shows significant difference in comparison with MRI without SCIC ( $p < 0.001$ )



**Figure 3:** A 58-year-old man suffered from lung cancer with spinal metastasis. (A) In conventional FSE T1-weighted MRI, spinous process of thoracic vertebra (arrow) shows increased signal intensity, but the margin and its extension of lesion is not clear. (B) In T1-weighted MRI with SCIC, the image clearly shows spinal metastasis margin and its extension (arrow).

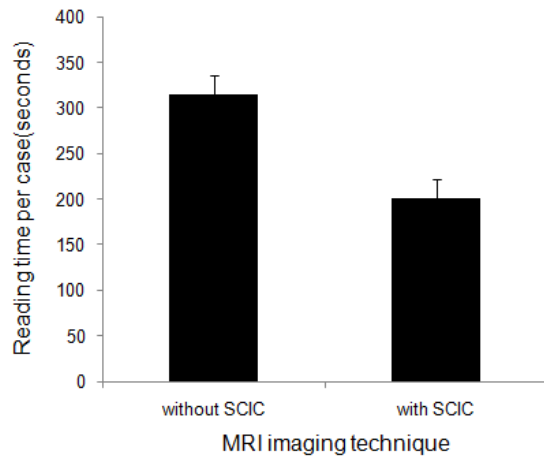
## 4 Discussion

Development of high-field MRI scanners with excellent tissue contrast, non-invasive character, high spatial resolution, and easy slice selection at any orientation is a powerful imaging technique for studying spine disorders. However, the signal intensity variation, high signal intensity near the phased-array surface coil, and low signal intensity far from the surface coil limit their use in clinical applications [2-7]. There are several facts, including coil tuning, short repetition and echo times, RF coils with poor RF uniformity and number of echoes in a multi-echo sequence, can have significant effects on image non-uniformity, but the differences between transverse, sagittal and coronal non-uniformity are small [3]. The image quality in MRI is linked to the spatial homogeneity of the electromagnetic field produced by radio frequency (RF) coils. The presence of the non-uniformity in RF magnetic fields is a significant obstacle to quantitative analysis and image processing. Such non-uniformity can be caused by the instrument itself rather than by the objects being examined. One of the major sources of



**Figure 4:** A 59-year-old man suffered from lung cancer with spinal metastasis. (A) In conventional FSE T1-weighted MRI, L1 vertebral body, spinous process and soft tissue lesion around the vertebrae (arrow) shows increased signal intensity, but the spinal metastases margin, extension and details are not clear. (B) In FSE T1-weighted MRI with SCIC, the margin and its details of lesion are clearer than conventional MRI (arrow). (C) In conventional FSE T2-weighted MRI, lesion (arrow) is not clear. (D) In T2-weighted MRI with SCIC, the image clearly shows spinal metastasis margin and its extension with more details (arrow).

image non-uniformity in the high field MR scanners is the radiofrequency (RF) coil non-uniformity. It degrades conspicuity of lesion(s) and surrounding tissues in the MRI and reduces accuracy of image [4]. The phased-array surface coil image non-uniformity results from narrowing the signal intensity distribution due to reduction of signal drop-off as the distance from the coil increase. SCIC produces broadening of the intensity distribution of homogeneous phantom. The uniformity of MRI can be improved in scans of any orientation, including oblique scans at arbitrary angles [5]. Although the general development of the hardware of the MR scanners has reduced the non-uniformity, the problem remains unsolved. In this paper, we assessed the phantom and spine as exemplars



**Figure 5:** The reading time per case. Compared with MRI without surface coil intensity correction, the reading time per case is shorter for MRI with surface coil intensity correction ( $p < 0.05$ ).

in sagittal FSE T1- and T2-weighted MRI with and without SCIC on phased-array surface coil. The SCIC feature is an automatic post-processing technique that reduces noise, and enhances contrast in the image. It will produce a series of filtered images with decreased intensity near the coil, reducing the areas of bright spots. With SCIC, each scanned series produces two reconstructed series: one original and the other corrected using SCIC. SCIC was supported by all imaging planes and pulse sequences.

To better assess the behavior of the correction method, phantom was scanned to test the performance. A uniform spherical phantom filled with aqueous copper sulfate solution was used with phased-array surface coil. The original phantom T1-weighted MRI (Fig.1. A) and T2-weighted MRI (Fig.1. C) shows that the signal intensity variation in the image is visible. There is a diminution of signal intensity from areas near phased-array surface coil to areas far from surface coil (from right to left in image). Both measurements were taken with regions of interest of same size. The coefficient of variation of signal intensity of an image is an important index of image quality. The coefficient of variation of signal intensity with SCIC is lower than original image without correction. The variance to mean ratio of signal intensity is 53.36% for original T1-weighted MRI and 53.58% for original T2-weighted MRI. The intensity variation from areas right to left was almost suppressed in the image with SCIC (Fig.1. B and D). The variance to mean ratio of signal intensity is reduced to 18.99% for T1-weighted MRI with SCIC and 22.77% for T2-weighted MRI with SCIC.

This intensity non-uniformity image is attributed to poor radio frequency (RF) coil uniformity. In phased-array surface coil images, the spread of the distribution will vary with the depth from the coil due to signal drop-off.

This intensity non-uniformity image not only makes the image interpretation difficult, but also restricts the use of phased-array surface coils in some areas of interest, such as display spinous process and soft tissue lesion around the vertebrae. In addition, this intensity fall-off causes distracting artifacts and makes it difficult to film images at a single window/level setting. Images without correction show non-uniformity and a high signal level from subcutaneous tissue near the coils [6]. The SCIC was found to significantly improve the image homogeneity near high contrast edges when a phased-array surface coil is used for reception. The intensity correction algorithm should remove the effect of the variance due to signal drop-off. Phased-array surface coil images with correction demonstrated greater anatomic detail [7].

The phased-array surface coil has an inherently non-uniformity reception profile that leads to a variation in image brightness across the spine. This significantly degrades the utility of the images for evaluation of anatomy in the spine and can also impair automated segmentation of spine structures. For example, the uncorrected T1-weighted images, the signal in the spine near the coils is much higher than spine far from the phased-array surface coils. This wide variation in image intensity makes most of the anatomy difficult to visualize with a single window and level setting (Fig.2-4). The MRI without SCIC was morphologically unacceptable before SCIC. After SCIC, the difference between the two results with and without SCIC is evident (Fig.2-4). There is significant difference between the original images and the SCIC images. The corrected phased-array surface coil images showed areas both near and far away from the surface coil with relatively constant contrast and higher SNR for area far away from the surface coil compared to the original non-corrected images. The signal intensity near surface coil was more homogeneous than and not as bright as the original one. In corrected surface coil image, a diminution of the SNR near the surface coil will not hamper the quantitative analysis of the superficial tissues of the spine, because it is too bright originally. In other words, the non-uniformity correction will make easier the automatic segmentation of different tissues near and far from the surface coil.

The comparison between MRI with and without SCIC is summarized in Table 3. The overall image quality scores (interface conspicuity of lesion and details of lesion) are significantly higher than those original MRI. The average reading time per case is shorter for MRI with SCIC than for MRI without SCIC. The advantages to the SCIC method include: a. MRI with SCIC shows the spinal lesions more clearly than the original one; b. MRI with SCIC does not have any additional time; c.

The reading time per case is shorter for MRI with SCIC than those without SCIC, while its disadvantage is that MRI is susceptible to complex patient motion [8-15].

In conclusion, the results in this study showed that spinal metastases were better demonstrated on MRI with SCIC than on MRI with conventional surface coil technique. Their overall image quality scores were significantly higher than those of original MRI. The reading time per case was shorter for MRI with SCIC than for MRI without SCIC. Therefore, we consider that the phased-array surface coil intensity correction could replace or supplement conventional technology in MRI of spinal metastases.

**Acknowledgement:** This study was partly supported by the grants from the Medical and Health Research Project of Zhejiang Province (No.2013KYA109 and No.2015KYB210), Zhejiang Province Natural Fund (No.LY16H060002).

**Conflict of interests:** No authors report any conflict of interest.

## References

- [1] Han C, Hatsukami TS, Yuan C. A multi-scale method for automatic correction of intensity non-uniformity in MR images. *J Magn Reson Imaging* 2001; 13:428-436
- [2] Yun S, Kyriakos WE, Chung JY, Han Y, Yoo SS, Park H. Projection-based estimation and nonuniformity correction of sensitivity profiles in phased-array surface coils. *J Magn Reson Imaging* 2007; 25: 588-597
- [3] Ishimori Y, Yamada K, Kimura H, Fujiwara Y, Yamaguchi I, Monma M, et al. Correction of inhomogeneous RF field using multiple SPGR signals for high-field spin-echo MRI. *Magn Reson Med Sci* 2007; 6: 67-73
- [4] Wang D, Doddrell DM. Method for a detailed measurement of image intensity nonuniformity in magnetic resonance imaging. *Med Phys* 2005; 32: 952-960
- [5] Wicks DA, Barker GJ, Tofts PS. Correction of intensity nonuniformity in MRI of any orientation. *Magn Reson Imaging* 1993; 11:183-196
- [6] Tofts PS, Barker GJ, Simmons A, MacManus DG, Thorpe J, Gass A, et al. Correction of nonuniformity in images of the spine and optic nerve from fixed receive-only surface coils at 1.5 T. *J Comput Assist Tomogr* 1994; 18:997-1003
- [7] Lin FH, Chen YJ, Belliveau JW, Wald LL. A wavelet-based approximation of surface coil sensitivity profiles for correction of image intensity inhomogeneity and parallel imaging reconstruction. *Hum Brain Mapp* 2003; 19:96-111
- [8] Martin CT, Morcuende J, Buckwalter JA, Miller BJ. Preferral MRI use in patients with musculoskeletal tumors is not excessive. *Clin Orthop Relat Res* 2012; 470: 3240-3245
- [9] Vokurka EA, Watson NA, Watson Y, Thacker NA, Jackson A. Improved high resolution MR imaging for surface coils using automated intensity non-uniformity correction: feasibility study in the orbit. *J Magn Reson Imaging* 2001; 14:540-546
- [10] Cohen MS, DuBois RM, Zeineh MM. Rapid and effective correction of RF inhomogeneity for high field magnetic resonance imaging. *Hum Brain Mapp* 2000; 10:204-211
- [11] Zhou LQ, Zhu YM, Bergot C, Laval-Jeantet AM, Bousson V, Laredo JD, et al. A method of radio-frequency inhomogeneity correction for brain tissue segmentation in MRI. *Comput Med Imaging Graph* 2001; 25:379-389
- [12] Gispert JD, Reig S, Pascau J, Vaquero JJ, García-Barreno P, Desco M. Method for bias field correction of brain T1-weighted magnetic resonance images minimizing segmentation error. *Hum Brain Mapp* 2004; 22: 133-144
- [13] Noterdaeme O, Anderson M, Gleeson F, Brady SM. Intensity correction with a pair of spoiled gradient recalled echo images. *Phys Med Biol* 2009; 54: 3473-3489
- [14] Collewet G, Davenel A, Toussaint C, Akoka S. Correction of intensity nonuniformity in spin-echo T(1)-weighted images. *Magn Reson Imaging* 2002; 20:365-373
- [15] Sosna J, Pedrosa I, Dewolf WC, Mahallati H, Lenkinski RE, Rofsky NM. MR imaging of the prostate at 3 Tesla: comparison of an external phased-array coil to imaging with an endorectal coil at 1.5 Tesla. *Acad Radiol* 2004; 11: 857-862