

Outcomes of pediatric inguinal hernia repair with or without opening the external oblique muscle fascia

Masoud Nazem, Mohamad Masoud Heydari Dastgerdi, Motaherh Sirousfard¹

Department of Surgery, Alzahra Hospital, Isfahan University of Medical Sciences, ¹Department of Pediatric Nursing, Isfahan University of Medical Sciences, Isfahan, Iran

Background: Considering that complications and outcome of each method of pediatric inguinal hernia repair are one of the determinants for pediatric surgeons for selection of the appropriate surgical technique, we compared the early and late complications of two inguinal repair techniques, with and without opening the external oblique muscle fascia. **Materials and Methods:** In this double-blind clinical trial study, boy children aged 1-month to 6 years with diagnosed inguinal hernia were included and randomly allocated into two groups for undergoing two types of hernia repair techniques, with and without opening the external oblique muscle fascia. Surgical complications such as fever, scrotal edema and hematoma, and wound infections classified as early complication and recurrence, testis atrophy and sensory impairment of inguinal area classified as late complications. The rates of mentioned early and late complications were compared in the two interventional groups. **Results:** In this study, 66 patients were selected and allocated to the two interventional groups. The prevalence of early and late complications in two studied groups were not different significantly in two interventional groups ($P > 0.05$). Operation time was significantly shorter in inguinal repair techniques without opening the external oblique muscle fascia than the other studied technique ($P = 0.001$). **Conclusion:** The findings of our study indicated that though early and late complications of the two repair methods were similar, but the time of procedure was shorter in herniotomy without opening the external oblique muscle, which considered the superiority of this method than inguinal hernia repair with opening the external oblique muscle.

Key words: Children, complication, herniotomy, inguinal hernia

How to cite this article: Nazem M, Heydari Dastgerdi MM, Sirousfard M. Outcomes of pediatric inguinal hernia repair with or without opening the external oblique muscle fascia. *J Res Med Sci* 2015;20:1172-6.

INTRODUCTION

Inguinal hernia is one of the most common conditions in infancy and childhood. The estimated prevalence rate of inguinal hernia for full-term and premature neonates have reported to be 1-5% and 9-11%, respectively.^[1,2] Inguinal hernia repair or herniotomy considered as the most common elective surgical procedure in children with inguinal hernia.^[3]

Previous studies have reported greater variability in performing inguinal herniorrhaphy by pediatrics surgeons. Levitt *et al.* have shown significant variability

in this regard.^[4] Among the wide variety reported methods of repair, two techniques are commonly performed by surgeons. One of these methods is the method described by Gross and Ferguson^[7] and the other one is the Mitchell-Bank technique.^[6]

In the method of Gross and Ferguson, the fascia of the external oblique muscle and the external ring is incised. Hence, this technique allows the surgeon to properly explore for high ligation of the sac in the inner ring. But opening the external oblique muscle could result in some complications such as perioperative nerve and vessel injury and postoperative pain, edema and hematoma.^[4,5,8]

This is an open access article distributed under the terms of the Creative Commons Attribution-NonCommercial-ShareAlike 3.0 License, which allows others to remix, tweak, and build upon the work non-commercially, as long as the author is credited and the new creations are licensed under the identical terms.

For reprints contact: reprints@medknow.com

Access this article online

Quick Response Code:



Website:

www.jmsjournal.net

DOI:

10.4103/1735-1995.172985

Address for correspondence: Dr. Mohamad Masoud Heydari Dastgerdi, Department of Surgery, Alzahra Hospital, Isfahan University of Medical Science, Isfahan, Iran. E-mail: mmh222msf@yahoo.com

Received: 10-07-2014; **Revised:** 04-01-2015; **Accepted:** 23-06-2015

In the Mitchell-Bank technique which was first described in 1882, herniotomy is performed without incision of external oblique muscle and external ring which result in minimal tissue injury.^[4,6] Though it is recommended to use this method for children younger than 1-year-old, its feasibility and safety in children aged 1-11-year-old have also been investigated. The results showed that the rate of recurrence was not different significantly comparing with Ferguson method.^[6,9]

Outcomes and technique-related complications of different pediatric inguinal hernia repair methods have been investigated in several studies. Accordingly, the rate of spermatic cord injury, total rate of complications, recurrence have been reported to be 0.1%, $\leq 2\%$, and $< 1\%$, respectively.^[10-12] The prevalence rate for hematoma, hemorrhage, and testis atrophy has been reported to be 0.9%, 0.5%, and 1%, respectively.^[11,12]

Many studies have compared different techniques of tissue repair whereas there were few studies which compare inguinal hernia repair with and without external oblique muscle and available reports mostly had a retrospective design. There is a tendency for the majority of pediatric surgeons to open the inguinal canal in children. But there are evidence which indicated that the herniotomy without opening external oblique fascia has also some advantages.^[9,13,14]

Hence, it seems that comparing mentioned methods could be helpful for surgeons, for determining the most appropriate method for herniotomy in children. Hence, considering that complications and outcome of each method is one of the determinants of selection of the appropriate surgical technique in this regard, we aimed to compare the early and late complications of two inguinal repair techniques with and opening the external oblique muscle fascia.

MATERIALS AND METHODS

In this double-blind clinical trial study, boy children who were referred to Alzahra Hospital, affiliated to Isfahan University of Medical Sciences, for inguinal hernia repair, during March 2012-March 2013 were enrolled.

The protocol of the study was approved by Regional Ethics Committee of Isfahan University of Medical Sciences (Research Project Number: 392085).

The patients were selected using convenience sampling method.

In this study, boy children aged 1-month–6 years with diagnosed inguinal hernia were included and those with

incarcerated or strangulated hernia, history of medical conditions such as cystic fibrosis, connective tissue disorders, ascites, increased abdominal pressure, and peritoneal dialysis were not included. Those patients with inappropriate cooperation during operation or follow-up period were also excluded from the study.

Informed consent form was obtained from selected patients or their parents.

Selected patients were blindly and randomly allocated in two interventional groups. Patients allocated into two groups for undergoing two types of hernia repair techniques, with and without opening the external oblique muscle fascia. In patients with bilateral inguinal hernia, two methods of repairs were performed for the each side of the hernia.

All operations were performed by one expert surgeon. After hernia repair, the patients were followed up on the day of surgery, 1-week for early complication and 6 months for testis atrophy and sensory impairment of inguinal area and 2 years for recurrent after surgical procedure blindly by a resident of surgery.

Studied surgical complications classified in two categories as early and late complications. Fever, scrotal edema and hematoma, and wound infections classified as short-term complications and recurrence, testis atrophy and sensory impairment of inguinal area classified as long-term complications.^[12] Mentioned complications examined by a resident of surgery.

Sensory impairment was assessed by stimulation of inguinal region and Scrotum with a piece of cotton, and it was established in the absence cremaster reflex or no increase no contraction in the anal verge.^[15,16]

Testicular atrophy was evaluated by an expert radiologist blindly, using ultrasonography, before and 6 months after the surgery.

Operation time was recorded by trained personnel in the operation room.

The rates of mentioned early and late complications were compared in the two interventional groups

Statistical analysis

Obtained data analyzed using SPSS version 20 (SPSS Inc., Chicago, IL, USA). The mean of age and operation time in two interventional groups was compared using Student's *t*-test. Frequency of different early and late complications was compared using Chi-square and exact

Fisher tests. The $P < 0.05$ was considered as statistically significant.

RESULTS

During this study, 80 patients were enrolled, from which 66 patients were selected and allocated to the two interventional groups [Figure 1]. From selected patients, 12 (18.2%) had bilateral inguinal hernia. Demographic characteristics of studied population and early and late complications of two methods of inguinal hernia repair methods are presented in Tables 1 and 2.

Baseline characteristics of studied population including age and the side of repaired hernia were statistically similar in two studied groups ($P > 0.05$). Time of operation was significantly shorter in inguinal hernia repair without opening the external oblique muscle fascia than those with opening the external oblique muscle fascia ($P < 0.05$).

Table 1: Demographic characteristics of boy children undergoing inguinal hernia repair with and without opening the external oblique muscle fascia

Variables	Inguinal hernia repair with opening the external oblique muscle fascia (n = 33)	Inguinal hernia repair without opening the external oblique muscle fascia (n = 33)	P
Age (years)	3.68±2.15	3.43±1.70	0.61
Side of repaired hernia (%)			
Right	20 (60.1)	16 (48.5)	0.32
Left	13 (39.9)	17 (51.5)	

Frequency of both early and late complications of the two methods was not statistically different in the two studied groups ($P > 0.05$).

DISCUSSION

In this trial, we compare the outcome of two methods of inguinal hernia repair among male children. The findings indicated that the early and late complications of the two methods of repair that is with or without opening the external oblique muscle fascia were similar, but the operation time in inguinal repair without opening the external oblique muscle fascia was shorter than the other method.

Though recently the surgical repair of inguinal hernia has been improved due to using of modern and minimally invasive surgical procedures such as laparoscopes, it seems that the ligation of the hernia sac (process vaginalis) is considered as the standard surgical treatment for inguinal hernia repair.^[14,17,18] The two most commonly used herniotomy techniques by pediatric surgeons are the Ladd and Gross procedure, and the Mitchell-Banks procedure.^[5,6] Moreover, as reported by Ravi and Hamer, after counseling with 264 surgeons, pediatrics surgeons perform different methods of herniotomy with no standard surgical technique for inguinal herniotomy in children.^[19] It is suggested that different factors could effect on the selection of the surgeons in this regard, including the rate of different complications, time of procedure, cost effectiveness, etc.^[20]

Though, still there are controversies regarding adaptation of the most appropriate method. The justification of surgeons

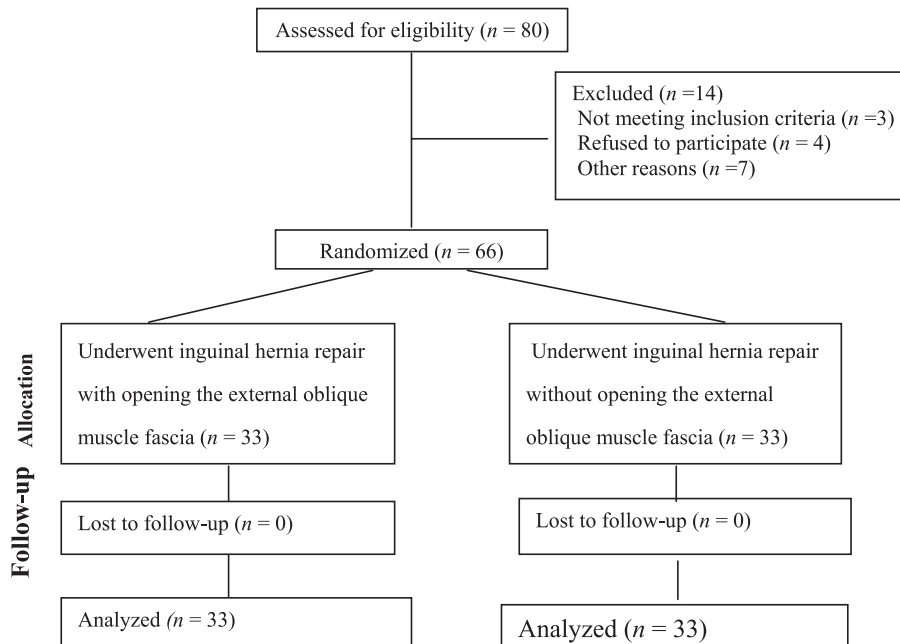


Figure 1: Consort diagram of the study

Table 2: Frequency of early and late complications of boy children undergoing inguinal hernia repair with and without opening the external oblique muscle fascia

Variables	Inguinal hernia repair with opening the external oblique muscle fascia (n = 33)	Inguinal hernia repair without opening the external oblique muscle fascia (n = 33)	P
Operation time (min)	15.15±0.57	13.83±0.52	0.001
Early complications (%)			
Fever	3 (9.1)	2 (6.1)	0.64
Scrotal edema	5 (15.2)	1 (3)	0.19
Scrotal hematoma	1 (3.0)	2 (6.1)	1.00
Wound infection	1 (3.0)	1 (3.0)	1.00
Late complications (%)			
Recurrence	0 (0)	0 (0)	1.00
Testis atrophy	0 (0)	1 (3.0)	0.31
Sensory impairment of inguinal area	3 (9.1)	2 (6.1)	0.64

which preferred the Mitchell-Banks method, is that the recurrence rate is low in this method due to opening of the inguinal canal which result in high ligation of the sac and could prevent the recurrence of hernia.^[21,22]

Review of the literature in the field of different repair methods for inguinal hernia in children indicated that still most of the pediatrics surgeons prefer inguinal herniotomy with opening the external oblique muscle fascia.^[4] There were few studies which compare the two mentioned procedures.

Some characteristics of children inguinal canal such as shorter length of the canal, less oblique plane in anteroposterior direction, involvement of more elastic tissue, and close position of the internal and external rings provide some appropriate conditions for surgeons for moving the spermatic cord and visualizing the inguinal canal of children. Some studies have shown the canal length in children up to age 12 is 4-23 mm and in adult is 40-50 mm. Shorter channel length and fascia flexibility in children enable the surgeon to could traction, bringing together the inner and outer rings and see the inner ring.^[23-27] Thus, considering these characteristics, some studies indicated the advantages of inguinal hernia repair without opening the external oblique muscle fascia for inguinal hernia repair in children.^[5,23-25]

The overall complication rate for children after inguinal hernia repair have been reported to be 2% or less.^[17] In this study, the overall complication rate was higher due to that we have reported both early and late complications.

In this study, the rate of both early and late complications was similar in two studying groups. The results of our study were similar to that reported by Turk *et al.*^[9] in Turkey. They retrospectively compare the rate of recurrence and complications of the Ferguson hernioplasty and Mitchell-Banks' technique in 4520 inguinal hernia repairs in boys aged >2 years old. They reported a total complication rate

of 2.3% and 2.9% in Ferguson hernioplasty and Mitchell-Banks' technique, respectively. The rates of early and late complications were not statistically different in their two studying groups.^[9]

In the current study, we have also reported a similar rate of early and late complication for the two studied methods. But the rate of complications in our study was higher than reported by Turk *et al.*^[9]

It may be due to the differences in the method of study as well as low sample size of our studied population comparing with the study of Turk *et al.*^[9] It seems that further multicentral studies with larger sample size would provide us more accurate results, regarding the rate of different complications.

Jabłoński *et al.*^[5] have investigated the long-term effects of different surgical techniques of inguinal hernia repair in children. They retrospectively compared the recurrence rate of Ferguson hernioplasty and Mitchell-Banks' technique among 641 children aged <6 years. They showed that the recurrence rate was higher in Ferguson hernioplasty than Mitchell-Banks' technique (1.68% vs. 0.95%). They concluded that Mitchell-Banks' technique is more appropriate procedure for inguinal hernia repair of children aged <6 years.^[5]

The rate of recurrence in different conventional open herniotomy methods have been reported to be 1-2.5%.^[28-30]

The rate of recurrence in our study was 0% in both techniques. Our results considered as confirmatory results for previously reported studies regarding the feasibility of Mitchell-Banks' technique for inguinal hernia repair in children.^[5,13]

The limitation of the current study was a small sample size of studying population and not including female children.

In general, the findings of our study indicated that though early and late complications of the two repair methods were similar. But the time of procedure was partly shorter in herniotomy without opening the external oblique muscle, which considered the safety of this method in herniotomy in children up to 6 years old. Furthermore, it is recommended to design more interventional studies for evaluation of other less invasive repair methods.

Acknowledgments

We would like to thank children and their parents for their companionship.

Financial support and sponsorship

Isfahan University of Medical Sciences.

Conflicts of interest

There are no conflicts of interest.

AUTHOR'S CONTRIBUTION

All authors contributed in the conception of the work, conducting the study, revising the draft, approval of the final version of the manuscript, and agreed for all aspects of the work.

REFERENCES

- Grosfeld JL. Current concepts in inguinal hernia in infants and children. *World J Surg* 1989;13:506-15.
- Coran AG, Fonkalsrud EW, Grosfeld JL, O'Neill JA. *Pediatric Surgery*. 6th ed. Philadelphia: Mosby Elsevier; 2006.
- Kapur P, Caty MG, Glick PL. Pediatric hernias and hydroceles. *Pediatr Clin North Am* 2008;45:773-85.
- Levitt MA, Ferraraccio D, Arbesman MC, Brisseau GF, Caty MG, Glick PL. Variability of inguinal hernia surgical technique: A survey of North American pediatric surgeons. *J Pediatr Surg* 2002;37:745-51.
- Jabłoński J, Bajon K, Gawrońska R. Long-term effects of operative treatment of inguinal hernias in children comparison of different techniques. *Przegl Pediatr* 2007;37:44-7.
- Kurlan MZ, Wels PB, Piedad OH. Inguinal herniorrhaphy by the Mitchell Banks technique. *J Pediatr Surg* 1972;7:427-9.
- Summers JE. Inguinal herniorrhaphy; methods of repair in use at the present time. *Am J Surg* 1950;80:540-4.
- Rescorla FJ, Grosfeld JL. Inguinal hernia repair in the perinatal period and early infancy: Clinical considerations. *J Pediatr Surg* 1984;19:832-7.
- Turk DE, Memetoglu ME, Edmirne DY, Karaca DF, Saday DC, Guven A. Inguinal herniotomy with the Mitchell Bank's technique is safe in older children. *J Pediatric Surg* 2013;9:12-22.
- Steigman CK, Sotelo-Avila C, Weber TR. The incidence of spermatic cord structures in inguinal hernia sacs from male children. *Am J Surg Pathol* 1999;23:880-5.
- Brandt ML. Pediatric hernias. *Surg Clin North Am* 2008;88:27-43, vii-viii.
- Glick PL, Boulanger SC. Inguinal hernias and hydroceles. In: Grosfeld JL, O'Neill Jr JA, Coran AG, Fonkalsrud E, editors. *Pediatric Surgery*. 6th ed. Philadelphia: Mosby; 2006. p. 1172-9.
- Ibrahim M, Getso KI, Mohammad MA, Akhparov NN, Aipov RR. Herniotomy in resource-scarce environment: Comparison of incisions and techniques. *Afr J Paediatr Surg* 2015;12:45-50.
- Yang C, Zhang H, Pu J, Mei H, Zheng L, Tong Q. Laparoscopic vs open herniorrhaphy in the management of pediatric inguinal hernia: A systemic review and meta-analysis. *J Pediatr Surg* 2011;46:1824-34.
- Shadgan B, Fareghi M, Stothers L, Macnab A, Kajbafzadeh AM. Definition: Cremasteric Reflex from Online Medical Dictionary. [Last retrieved on 2007 Dec 06].
- Drake RL, Vogl AW, Mitchell AW. Illustrations by Richard; Richardson, Paul. In: PBK, editor. *Gray's Anatomy for Students*. Philadelphia: Elsevier/Churchill Livingstone; 2005. Available from: <http://www.amazon.com/book>. [Last retrieved on 2013 May 25].
- Glick PL, Boulanger C. Inguinal hernias and hydroceles. In: Coran AG, Caldamone A, Adzick NS, Krummel TM, Laberge J, Shamberger R, editors. *Pediatric Surgery*. Ch. 76. Elsevier; 2012. p. 985-1001. Available from: <http://www.elsevier.com/books/pediatric-surgery-2-volumeset/coran/978-0-323-07255-7>.
- Chan KL, Hui WC, Tam PK. Prospective randomized single-center, single-blind comparison of laparoscopic vs open repair of pediatric inguinal hernia. *Surg Endosc* 2005;19:927-32.
- Ravi K, Hamer DB. Surgical treatment of inguinal herniae in children. *Hernia* 2003;7:137-40.
- Lau ST, Lee YH, Caty MG. Current management of hernias and hydroceles. *Semin Pediatr Surg* 2007;16:50-7.
- Grosfeld JL, Minnick K, Shedd F, West KW, Rescorla FJ, Vane DW. Inguinal hernia in children: Factors affecting recurrence in 62 cases. *J Pediatr Surg* 1991;26:283-7.
- Sklar C, Cameron BH. Achieving Excellent Outcomes and Avoiding Complications in Pediatric Inguinal Hernia Surgery; 2008. Available from: <http://www.google.com/P6HXW>. [Last retrieved on 2013 May 20].
- Al-Momani HM. Surgical anatomy of the inguinal canal in children. *Ann Saudi Med* 2006;26:300-2.
- Figueiredo CM, Lima SO, Xavier Júnior SD, da Silva CB. Morphometric analysis of inguinal canals and rings of human fetus and adult corpses and its relation with inguinal hernias. *Rev Col Bras Cir* 2009;36:347-9.
- Parnis SJ, Roberts JP, Hutson JM. Anatomical landmarks of the inguinal canal in prepubescent children. *Aust N Z J Surg* 1997;67:335-7.
- Tanyel FC, Ocal T, Karaagaoglu E, Büyükpamukçu N. Individual and associated effects of length of inguinal canal and caliber of the sac on clinical outcome in children. *J Pediatr Surg* 2000;35:1165-9.
- Osuoji RI, Bankole MA. Do infants and children have measurable inguinal canals? *J Nepal Paediatr Soc* 2013;33:182-5.
- Harvey MH, Johnstone MJ, Fossard DP. Inguinal herniotomy in children: A five year survey. *Br J Surg* 1985;72:485-7.
- Carneiro PM. Inguinal herniotomy in children. *East Afr Med J* 1990;67:359-64.
- Vogels HD, Bruijnen CJ, Beasley SW. Predictors of recurrence after inguinal herniotomy in boys. *Pediatr Surg Int* 2009;25:235-8.