

# Spontaneous hematoma in the setting of dual anti-platelet therapy with ticagrelor: A case report

CHUNGUANG FENG, LINGUANG WANG and LULU WANG

Department of Cardiology, Central Hospital of Xuzhou, Xuzhou Institute of Cardiovascular Disease, Xuzhou, Jiangsu 221009, P.R. China

Received October 8, 2015; Accepted May 6, 2016

DOI: 10.3892/ol.2016.4552

**Abstract.** A 69-year-old male patient was admitted to hospital because a lump was discovered, accompanied with pain lasting 5 h under his right scapula. Two months earlier, he had undergone a double-stent insertion operation due to lesions on the end of the left main coronary artery, the opening of left circumflex artery, and the opening of the anterior descending branch. After the operation, he was administered with dual anti-platelet therapy (DAPT) with aspirin and ticagrelor and was diagnosed with hematoma under his right scapula through ultrasonic inspection. It was established that no other factor, except DAPT, was responsible for his spontaneous hematoma.

## Introduction

The basis of preventive treatment for stent thrombosis is the best percutaneous intervention (PCI) performance including good expansion and apposition of the stent, otherwise, dual anti-platelet therapy (DAPT) is the cornerstone of medical therapy after PCI (1,2). Based on data from Platelet Inhibition and Patient Outcomes (3), the newer platelet inhibitors such as ticagrelor have been accepted in the current American College of Cardiology guidelines (4). However, bleeding constituted an issue as compared with clopidogrel (3).

In the present study, we describe a case of spontaneous hematoma in a patient administered ticagrelor following PCI.

## Case report

The patient was a 69-year-old man who was admitted to the Central Hospital of Xuzhou (Jiangsu, China) because a lump was discovered, accompanied with pain under his right scapula. He had a 12-year history of hypertension and 6-month history of coronary heart disease, without history of trauma,

diabetes, stroke, or alimentary tract hemorrhage. Six months earlier, the patient felt dyspnea and chest discomfort after certain activities. After resting for a few minutes, such symptoms disappeared; however, 2 months prior to admission, the symptoms became aggravated, and the patient presented to the hospital for a check-up. Coronary angiogram showed that the end of left main coronary artery had 50% local stenosis, the opening to the proximal segment of anterior descending branch had 70-90% stenosis, and the opening to the proximal segment of circumflex artery had 80% stenosis. A 3.5x24 mm resolute stent was implanted between the proximal segment of the anterior descending branch and the end of left main coronary artery. A 4.0x18 mm resolute stent was implanted between the proximal segment of circumflex artery and the end of left main coronary artery. The operation method used was culotte.

After the operation, the patient was administered 100 mg aspirin (Bayer, Beijing, China) once a day, 90 mg ticagrelor (AstraZeneca, Shanghai, China) twice a day, combined with normal medication of rosuvastatin (AstraZeneca, Shanghai, China), amlodipine besylate tablet (Pfizer, Dalian, China), and metoprolol succinate sustained-release tablet (AstraZeneca, Shanghai, China). At 5 h prior to admission, while the patient was sleeping, he experienced sudden pain under the right scapula and considered that the lump was getting larger gradually. Therefore, he was admitted for emergency treatment. Two months prior to admission, ecchymosis was found on all his limbs, waist and abdomen, but since he did not experience any discomfort, he was not treated. In the course of disease, no symptoms, such as chest pains, shortage of breath, fever, or infection were evident. A physical examination on admission indicated the following: temperature (T) 36.6°C, pulse (P) 82 times/min, respiration (R) 18 times/min, blood pressure (BP) 135/85 mmHg, clear consciousness, no cyanosis, soft neck, no distension of jugular vein, 8x10 cm enclosed mass under the right scapula, normal complexion, obvious tenderness, clear breathing sounds in both lungs, without dry or moist rale, medium heart border under percussion, heart rate of 82 times/min, regular, no murmur in auscultatory valve areas, a large bruise in the right waist and abdomen, no obvious enclosed mass, no pressing pains, soft abdomen, no pressing pains or rebound tenderness, no touch to liver, spleen or subcostal, and no edema on the limbs. Physiological reflexion existed and pathologic reflex was not drawn out.

---

*Correspondence to:* Dr Chunguang Feng, Department of Cardiology, Central Hospital of Xuzhou, Xuzhou Institute of Cardiovascular Disease, 199 Jiefang South Road, Xuzhou, Jiangsu 221009, P.R. China  
E-mail: fcg999@163.com

**Key words:** ticagrelor, hematoma, percutaneous artery intervention

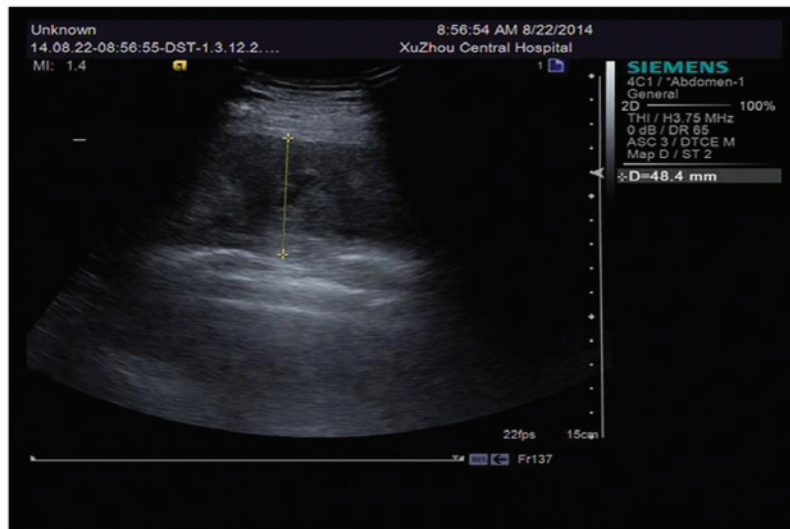


Figure 1. Liquid anechoic area under right scapula shown by ultrasonic examination.

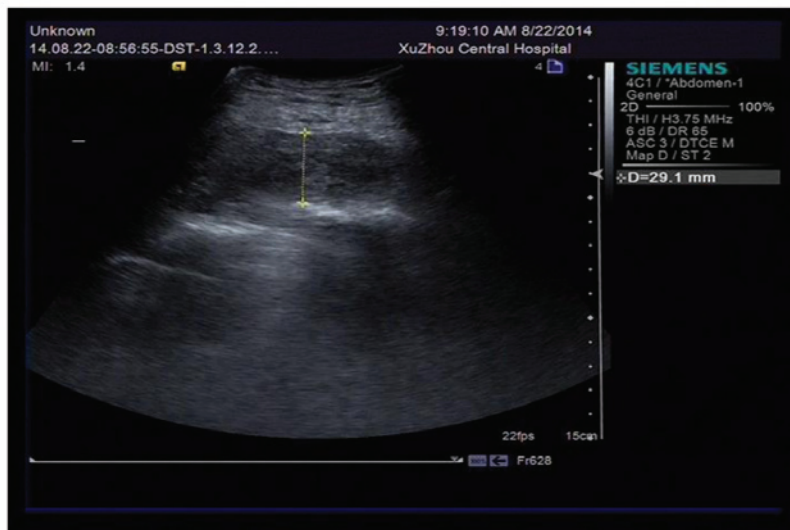


Figure 2. Liquid anechoic area reduced after puncture drainage by syringe.

The auxiliary examination included: blood routine test showing red blood cells  $3.23 \times 10^{12}/l$  [reference value:  $(4.0-5.5) \times 10^{12}/l$ ], hemoglobin 98 g/l (reference value: 120-160 g/l), hematocrit 30.2% (reference value: 40-50%), and blood platelet  $140 \times 10^9/l$  [reference value:  $(100-300) \times 10^9/l$ ]. The coagulation function was: prothrombin time (PT) 11.8 sec (reference value: 9-13 sec), active partial PT (APTT) 22.5 sec (reference value: 21-34 sec), and PT international normalized ratio (INR) 0.99 (reference value: 0.9-1.1 sec). Cardiac troponin I had a value of 0.02 (reference value: 0-0.08 ng/ml). Liver function and renal function were normal. The patient underwent a thrombelastogram examination on the first day of admission, and the following were indicated: R time 5.1 min (reference value: 5-10 min), K time 1.9 min (reference value: 1-3 min), MA 62.5 mm (reference value: 50-70 mm), CI 0.7 (reference value: -3-3), LY30 0.1% (reference value: 0-8%), AA inhibition rate 98.3%, and adenosine diphosphate (ADP)

inhibition rate 88.8%. Electrocardiogram and color Doppler ultrasound showed no abnormality. The admitting diagnosis for the patient was spontaneous edema under the right scapula.

A B ultrasonic examination was conducted on the day of admission indicating liquid anechoic area under right scapula, D 48.4 mm (Fig. 1).

Puncture drainage by syringe was conducted on the skin in an enclosed mass following disinfection, draining out 105 ml of incoagulable blood, and the liquid anechoic area turned to D 29.1 mm (Fig. 2). A pressure bandage was subsequently applied.

Coagulation disorders and an abnormal quantity of blood platelets were excluded according to the result of the patient's PT, APTT, INR and thrombelastogram examination. The thrombelastogram showed that the AA and ADP inhibition rate increased significantly, indicating that the patient had a high response towards dual antiplatelet drugs, and since the patient had undergone implantation of double stents 2 months earlier

due to left main coronary artery lesion, anterior descending branch lesion, and circumflex artery bifurcation lesion, and had used aspirin 6 months earlier, no significant abnormality was evident. Ticagrelor was used after the PCI operation and the patient denied any trauma, thus it was deemed that spontaneous edema was relevant to oral administration of ticagrelor.

Aspirin was continued, stopping ticagrelor for one day and changing to clopidogrel 75 mg QD. Pressure bandaging, combined with coronary artery-dilating medicine (isosorbide mononitrate), lipid lowering to stabilize plaque (atorvastatin) and depressurization (amlodipine besylate) treatment were applied. After 6 days, thrombelastogram examination was again conducted and the values identified were: R time 7.3 min (reference value: 5-10 min), K time 1.9 min (reference value: 1-3 min), MA 68.4 mm (reference value: 50-70 mm), CI 0.1 (reference value: -3-3), LY30 0.1% (reference value: 0-8%), AA inhibition rate 74.3%, ADP inhibition rate 81.3%, and hemoglobin 95 g/l. The enclosed mass in the affected part was gradually absorbed. At 9 days after the onset of disease, the patient had a hemoglobin of 102 g/l. The patient was discharged from hospital. After DAPT with aspirin and ticagrelor and a follow-up of 10 months, no hematoma recurred and no skin ecchymosis was evident.

## Discussion

Anti-platelet therapy is the cornerstone of treatment for PCI. DAPT combined with clopidogrel (4) and aspirin has obvious limitations in treatment, and patients have the risk of cardiovascular sudden death and stent thrombosis. Patients in Asia, due to gene polymorphism, have resistance or low reaction towards clopidogrel (5). A high dose of clopidogrel is unable to effectively avoid the risk of stent thrombosis on acute coronary syndrome (ACS) patients after PCI treatment (3). Ticagrelor is a new type of oral anti-platelet drug, which reversibly interacts with P2Y<sub>12</sub> receptor of platelet ADP, blocks signal transduction and platelet activation (6). Compared with clopidogrel, it does not need metabolic activation, and it may be quickly absorbed by the human body, and takes effect faster, inhibiting platelets significantly during the treatment period of maintenance dose. After the last medication, the drug therapeutic effect decreases significantly (7). Ticagrelor was the first oral anti-platelet drug that was confirmed to be able to reduce cardiovascular deaths and total deaths of ACS patients, and it was also able to significantly reduce the risks of cardiovascular events; thus, it has become widely used in the clinic (8). In terms of the safety of blood loss, the ticagrelor and clopidogrel groups had no significant difference in terms of massive hemorrhage, fatal massive hemorrhage, TIMI massive hemorrhage and the need of infusion of erythrocyte. However, fatal intracranial hemorrhage and non-coronary-artery bypass grafting-related hemorrhage in the ticagrelor group increased (9). Notably, the FDA, while authorizing ticagrelor stated that ticagrelor, as in the case of other anti-platelet drugs, occasionally results in fatal hemorrhage (10). Consequently, it could not be used in patients with a history of active pathological or intracranial hemorrhage (10). Particularly, clopidogrel was deemed safer than ticagrelor on various hemorrhage indexes (11). Most of the subcutaneous hematomas on scapula were relevant to trauma and diseases of the blood system. Only few spontaneous edemas were relevant

to dual anti-platelet drugs. Two months earlier, the patient in our study was diagnosed with ACS. Radiography showed that lesions appeared in the left main coronary artery, anterior descending branch, and circumflex artery. Double stents were implanted. In the Guideline for the Management of Patients with Non-ST-Elevation Acute Coronary Syndromes (4) suggested using the more effective anti-platelet drug ticagrelor on the basis of aspirin. Compared with the independent use of aspirin, skin ecchymosis on the patient increased significantly, and spontaneous edema appeared under the right scapula, which under the laboratory examination, was confirmed as the result of the patient's high response towards ticagrelor. After changing ticagrelor for clopidogrel, such symptoms disappeared and no recurrence was detected during the follow-up period.

This case suggests that with the appearance of new anti-platelet drugs, there is a stronger anti-thrombotic effect, but also an increase in rare bleeding conditions, leading to new issues that are to be resolved: i) for example, whether, as the guideline suggests, all the ACS patients after operation should use more effective anti-platelet drugs; ii) or whether certain blood platelet detection methods, such as thrombelastogram, used to verify the outcome, may be used as conventional auxiliary methods to determine the type of anti-platelet drugs to be employed.

## References

1. Lemesle G, Delhay C, Bonello L, de Labriolle A, Waksman R and Pichard A: Stent thrombosis in 2008: definition, predictors, prognosis and treatment. *Arch Cardiovasc Dis* 101: 769-777, 2008.
2. Kurz DJ and Eberli FR: Medical therapy of coronary artery disease after percutaneous intervention. *Curr Opin Pharmacol* 13: 287-293, 2013.
3. Wallentin L, Becker RC, Budaj A, *et al*: Ticagrelor versus clopidogrel in patients with acute coronary syndromes. *N Eng J Med* 361: 1045-1057, 2009.
4. Amsterdam EA, Wenger NK, Brindis RG, Casey DE Jr, Ganiats TG, Holmes DR Jr, Jaffe AS, Jneid H, Kelly RF, Kontos MC, *et al*; American Association for Clinical Chemistry: 2014 AHA/ACC Guideline for the Management of Patients with Non-ST-Elevation Acute Coronary Syndromes: a report of the American College of Cardiology/American Heart Association Task Force on Practice Guidelines. *J Am Coll Cardiol* 64: e139-e228, 2014.
5. Kubica A1, Kozinski M, Grzesek G, Fabiszak T, Navarese EP and Goch A: Genetic determinants of platelet response to clopidogrel. *J Thromb Thrombolysis* 32: 459-466, 2011.
6. Husted S and van Giezen JJ: Ticagrelor: the first reversibly binding oral P2Y<sub>12</sub> receptor antagonist. *Cardiovasc Ther* 27: 259-274, 2009.
7. Gurbel PA, Blieden KP, Butler K, Tantry US, Gesheff T, Wei C, Teng R, Antonino MJ, Patil SB, Karunakaran A, *et al*: Randomized double-blind assessment of the ONSET and OFFSET of the antiplatelet effects of ticagrelor versus clopidogrel in patients with stable coronary artery disease: The ONSET/OFFSET study. *Circulation* 120: 2577-2585, 2009.
8. Juneja S, Gupta K and Kaushal S: Ticagrelor: An emerging oral antiplatelet agent. *J Pharmacol Pharmacother* 4: 78-80, 2013.
9. Wallentin L, Becker RC, Budaj A, Cannon CP, Emanuelsson H, Held C, Horrow J, Husted S, James S, Katus H, *et al*; PLATO Investigators: Ticagrelor versus clopidogrel in patients with acute coronary syndromes. *N Engl J Med* 361: 1045-1057, 2009.
10. Gaglia MA Jr and Waksman R: Overview of the 2010 Food and Drug Administration Cardiovascular and Renal Drugs Advisory Committee meeting regarding ticagrelor. *Circulation* 123: 451-456, 2011.
11. DiNicolantonio JJ, D'Ascenzo F, Tomek A, Chatterjee S, Niazi AK and Biondi-Zoccai G: Clopidogrel is safer than ticagrelor in regard to bleeds: a closer look at the PLATO trial. *Int J Cardiol* 168: 1739-1744, 2013.