

# One case report of giant atypical leiomyoma of the ovary

Qiu-Man Wang, MM<sup>a</sup>, Ye Zhao, MM<sup>b,\*</sup>, Ying Ma, MM<sup>b</sup>, Li-Ting Yao, MM<sup>a</sup>, Xiao Han, MM<sup>a</sup>

## Abstract

**Rationale:** Ovarian leiomyoma is a rare ovarian tumor that occurs in 20–65 year-old women, and is mostly misdiagnosed as malignant tumor. In most reports on this type of tumor, ovarian myoma has a benign histology. Herein, we describe a case of ovarian atypical leiomyoma.

**Patient concerns:** The patient is a 58-year-old woman. At the age of 40 years old, the patient underwent hysterectomy due to “hysteromyoma” and secondary anemia. The patient was admitted to our hospital due to palpation of lower abdominal mass and abdominal distention.

**Diagnoses:** A mass was revealed at the left uterine appendage by pelvic ultrasound and CT. Pathology and immunohistochemistry confirmed the diagnosis of the left ovarian atypical leiomyoma.

**Interventions:** Pelvic cavity resection and right adnexectomy were performed during laparotomy for the patient.

**Outcomes:** Without radiotherapy or chemotherapy, there were no signs of tumor recurrence in a 9-month follow-up period.

**Lessons:** When a solid mass appears in ovarian tissues, ovarian leiomyoma should be considered. Patients with this type of tumor are mostly asymptomatic. Preoperative diagnosis was difficult, intraoperative frozen section would be helpful for determining the scope of the surgery, and the correct diagnosis was made by identifying the properties of smooth muscles through postoperative pathology and immunohistochemistry.

**Abbreviations:** CDFI = color Doppler flow imaging, CT = computed tomography, GS = gestational sac, HPF = high power field, MRI = magnetic resonance imaging.

**Keywords:** atypical leiomyoma, diagnose, ovary, pathogenesis, treatment

## 1. Introduction

Ovarian leiomyoma is a rare ovarian tumor, which occurs in 20 to 65-year-old women.<sup>[1]</sup> Ovarian leiomyoma usually occurs on one side. Compared with elderly patients, bilateral tumors more likely occurs in young patients.<sup>[2]</sup> The mass of this type of tumor is small,<sup>[3]</sup> and patients usually have no clinical symptoms. Furthermore, patients are often complicated with a history of hysteromyoma or hysterectomy,<sup>[4]</sup> and coexisting peritoneal disseminated leiomyoma and ovarian leiomyoma have also been reported.<sup>[5]</sup> The histology of leiomyomas ranges from benign to borderline to malignant. In most reports on this type of tumor, ovarian myoma has a benign histology. Herein, we describe a case of ovarian atypical leiomyoma.

Editor: N/A.

The authors have no conflicts of interest to disclose.

<sup>a</sup>First Clinical Medical College, Shanxi Medical University, <sup>b</sup>Department of Gynecology, First Hospital of Shanxi Medical University, Taiyuan, China.

\* Correspondence: Ye Zhao, Department of Gynecology, First Hospital of Shanxi Medical University, NO.85 South Jiefang Road, Yingze District, Taiyuan 030001, China (e-mail: zhaoye\_1818@163.com).

Copyright © 2018 the Author(s). Published by Wolters Kluwer Health, Inc. This is an open access article distributed under the terms of the Creative Commons Attribution-Non Commercial-No Derivatives License 4.0 (CCBY-NC-ND), where it is permissible to download and share the work provided it is properly cited. The work cannot be changed in any way or used commercially without permission from the journal.

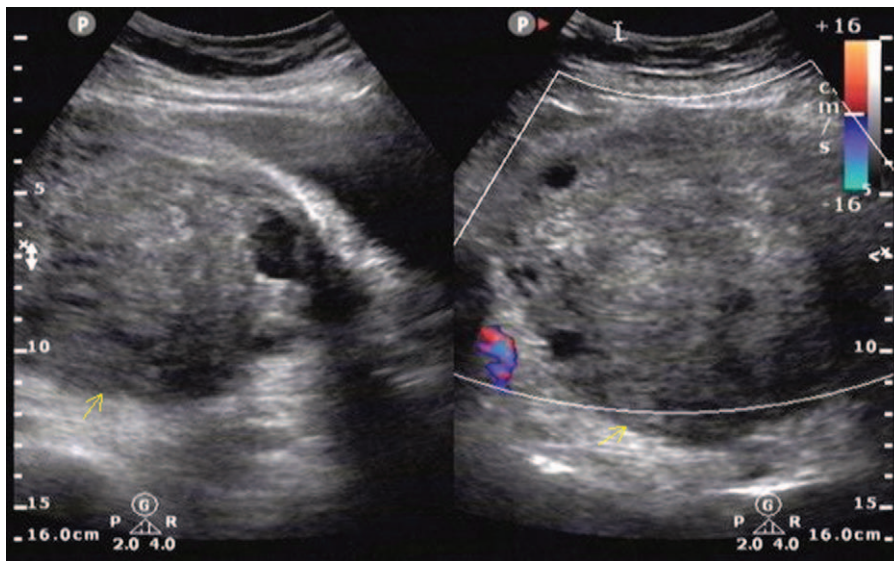
Medicine (2018) 97:40(e12526)

Received: 23 May 2018 / Accepted: 29 August 2018

<http://dx.doi.org/10.1097/MD.0000000000012526>

## 2. Case report

The patient is a 58-year-old woman, G4P1. At the age of 40 years old, the patient underwent hysterectomy due to “hysteromyoma” and secondary anemia. After the operation, the patient recovered well. The patient was admitted to our hospital due to palpation of lower abdominal mass and abdominal distention. The patient denied any family disease history or allergies history. Gynecologic examination results: The vaginal stump healed well. A mass could be touched in the pelvic cavity, the upper margin reached the level one finger width higher than the umbilicus, the texture was hard, the mass could move when pushed, no tenderness was felt, and the left margin reached the anterior axillary line, while the right margin reached the ventral median line. Vital signs were normal. Tumor markers (AFP, CEA, CA125, SCC, and CA199) and HE4 were all in the normal range. Pelvic ultrasonography revealed a mass with heterogeneous echo in the pelvis, with a size of 166.0 × 124.0 × 114.0 mm, which had an intact capsule, and was closely connected to the left appendage area. Color Doppler flow imaging (CDFI): Rich blood flow signals were observed in the mass (Fig. 1). Total abdominal computed tomography (CT) results: A quasi-round soft tissue mass with heterogeneous density was observed in the pelvic and abdominal cavities, which had relatively distinct margins (Fig. 2), and the enhanced scan revealed heterogeneous enhancement (Fig. 3). Pelvic cavity resection and right adnexectomy were performed through the abdominal approach under general anesthesia. The intraoperative findings were as follows: a large mass of approximately 20 × 18 cm was found in the pelvic cavity, which closely adhered to the bowel and bladder; no uterus was found; the mass had a smooth



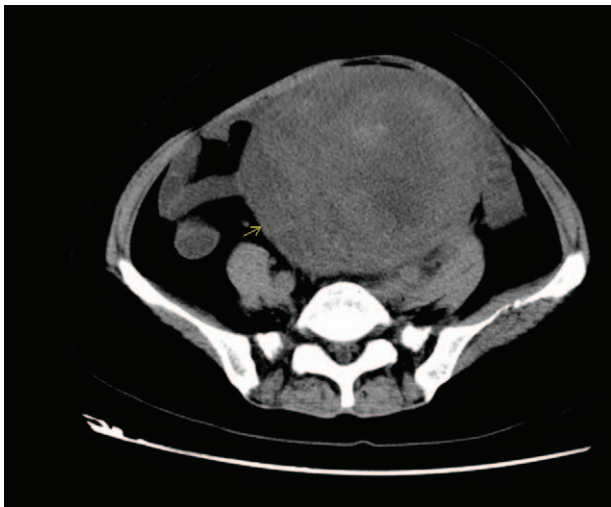**Figure 1.** B ultrasonography reveals a mass with heterogeneous echo in the pelvic cavity, which closely connects to the left appendage.

surface and solid texture, the fallopian tube structure was observed on the surface of the mass, no oviduct fimbria structure was observed, and no obvious ovarian structure was observed. Suspensory ligament was observed on the top of the mass, and a round ligament was found on the side of the mass close to the side wall of the pelvic cavity. A part of the tumor was frozen during the operation. Frozen results suggested endometrial stromal sarcoma. After the operation, the mass was dissected, and the results were as follows: the thickness of the wall of the capsule was approximately 1 to 3 cm, the color was white, the texture was tough, and a necrotic tissue of approximately  $6 \times 5$  cm was found in the center of the tumor, which was dark red, had a fragile texture, and part of the tissue was yellow. Postoperative pathology drew a diagnosis of left ovarian atypical leiomyoma, and immunohistochemistry was strongly positive for SMA. The operative procedure was smooth, and no complications occurred

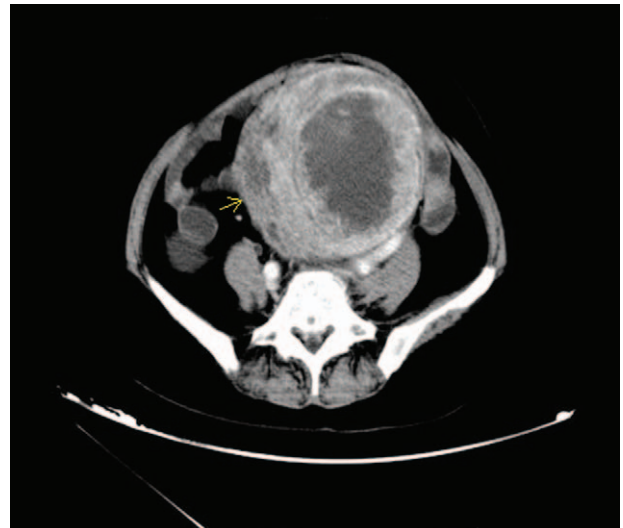
during and after the operation. The stitches were removed 8 days later. She was discharged home 12 days after the operation. Without radiotherapy or chemotherapy, there were no signs of tumor recurrence in a 9-month follow-up period. Ethics Approval: This study was conducted in accordance with the declaration of Helsinki. This study was conducted with approval from the Ethics Committee of The First Hospital of Shanxi Medical University. Written informed consent was obtained from all participants.

### 3. Discussion

Ovarian leiomyoma is rare, and accounts for 0.5% to 1.0% of all ovarian tumors. Ovarian leiomyoma can be classified into 2 types: primary and secondary. Primary ovarian leiomyoma is mainly derived from ovarian tissues, and the vast majority of



**Figure 2.** CT reveals a quasi-round mass shadow with heterogeneous density in the pelvic cavity, the boundary is relatively clear. CT=computed tomography.



**Figure 3.** Enhanced CT scan reveals the heterogeneous enhancement of the mass. CT=computed tomography.

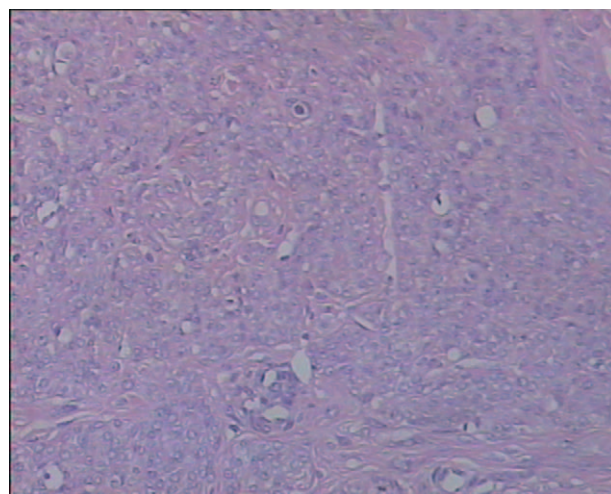
scholars have considered that it is derived from smooth muscle cells in the walls of ovarian vessels. Other theories have stated that it is derived from smooth muscle cells in the ovarian ligament, the smooth muscle cells in the ovarian stroma, the undifferentiated reproductive cells and cortical smooth muscle cells, or the smooth muscle cells in the smooth muscle metaplasia or ovarian endometriosis.<sup>[2,4,6-8]</sup> Secondary ovarian leiomyoma is derived from extra-ovarian tissues, and attaches to the ovary. In the present report, the patient underwent hysterectomy due to “hysteromyoma.” For its tumor origin, it may also be a pedicled subserous hysteromyoma. The tumor cells fell off from the uterus and connected to the ovaries, which gradually grew.

Most scholars have considered that estrogen plays an important role in the development and progression of this tumor. A scholar reported that a pregnant woman had her tumor increased by 2 cm in a year, including pregnancy.<sup>[7]</sup> Other scholars<sup>[8]</sup> have reported that in a patient with leiomyoma, in a time period of one year before menstruation, the tumor did not significantly increase, but the tumor diameter increased from 4.5 to 6.5 cm as the menstruation came. Furthermore, the increase in progesterone and estrogen may stimulate the growth of the tumor. Another scholar<sup>[9]</sup> reported 2 gestational sac (GS) patients with ovarian leiomyoma. Due to the lack of cases, merely about 70 patients have been reported worldwide. The origin and mechanism of this type of tumor needs to be further explored through large sample size studies.

The tumor usually has no clinical symptoms, and patients visit a doctor generally due to the discovery of lower abdominal masses during physical examination, or when occasionally touching masses. The patient in the present report mainly presented with massive compression symptoms, such as lower abdominal distension, frequency of urine and constipation, etc. The compression of the ureter may lead to hydronephrosis, which may also be accompanied by pleural effusion and ascites, and elevated CA125 levels.<sup>[10]</sup> The cause of ascites may be similar to the pathogenesis of Meigs syndrome. Furthermore, the tumor may cause severe acute abdomen due to torsion-induced necrosis.<sup>[3,11]</sup> Hence, this disease should be considered as one of the causes of acute abdomen.

Due to the rare nature and variability of ovarian leiomyoma, preoperative imaging diagnosis is often very difficult, and the diagnosis mainly depends on postoperative pathology and immunohistochemistry. Typical imaging methods include ultrasonography, CT, and magnetic resonance imaging (MRI). Ultrasonography suggests pelvic solid tumors, which has an echo similar with the myometrium of the uterus. Therefore, it is difficult to distinguish the pedicled subserous hysteromyoma. MRI is the main preoperative diagnostic method of ovarian leiomyoma.<sup>[12]</sup> When MRI reveals ovarian tumors similar to hysteromyoma, ovarian leiomyoma should be considered. MRI can also help distinguish between benign and malignant tumors. In addition, some scholars have suggested that<sup>[13]</sup> frozen section histology should be performed during laparoscopic surgery, in order to understand the nature of the tumor and determine the scope of the surgery.

The tumor was generally solid, and may be accompanied by secondary damage such as hyaline degeneration, bleeding, calcification, and cystic degeneration. The pathology reported by most scholars is similar to that of ordinary uterine leiomyoma. The case reported in the present study was a special uterine hysteromyoma type-atypical leiomyoma. Atypical leiomyoma is in the scope between benign leiomyoma and malignant leiomyosarcoma. The cytology was atypical, no coagulable



**Figure 4.** The tumor was a staggered arrangement of spindle cells, the nuclei presented with mild dysplasia, and the nuclear mitosis was <10 HPF (H&E  $\times 200$ ).

necrosis was found, and <10 mitosis could be found in every 10 high power field (HPF).<sup>[14]</sup> Ovarian leiomyoma must be distinguished from leiomyosarcoma, which is mainly determined by mitotic count, cell atypia, and coagulable necrosis. The pathological test results of the present case suggests that the tumor had a staggered arrangement of spindle cells, which was similar to leiomyoma, the partial area was dense in cells, the nuclei presented with mild dysplasia, the mitotic image was approximately 4 to 6/10 HPF, and no coagulable necrosis could be found (Fig. 4).

It was difficult to identify this tumor from ovarian thecoma and ovarian fibroma, which was determined by immunohistochemistry.<sup>[5,7]</sup> Immunohistochemistry can reveal positive results for vimentin, desmin, and smooth muscle actin.<sup>[15]</sup> In order to distinguish this tumor from ovarian sex cord stromal tumors, the combined staining of SMA, desmin and  $\alpha$ -inhibin should be performed. If  $\alpha$ -inhibin is positive, this suggests sex cord stromal tumors. If SMA or desmin is strongly positive, and  $\alpha$ -inhibin is negative, it can be diagnosed as leiomyoma.

The clinical treatment principle of ovarian leiomyoma is associated to age. For middle-aged and elderly patients, bilateral salpingo-oophorectomy is the gold standard.<sup>[12]</sup> After complete resection, ovarian leiomyoma rarely recurs, postoperative adjuvant therapy is not required, and the prognosis is good. For women who strongly requires to retain their reproductive functions, conservative surgery is unable to completely remove the tumor. In this case, it remains to be determined whether antiestrogen therapy, such as GnRH analogue, can be given to prevent relapse. No literature has been reported on this, and further studies are required.

#### 4. Conclusion

Ovarian leiomyoma is a rare ovarian tumor. When a solid mass appears in appendage tissues, ovarian leiomyoma should be considered. This tumor is difficult to be diagnosed by preoperative imaging examination. Hence, intraoperative frozen section would be helpful for determining the scope of the surgery, and pathology and immunohistochemistry can be used for diagnosis. The prognosis of this disease is good.

## Author contributions

**Data curation:** Qiu -Man Wang.

**Formal analysis:** Qiu -Man Wang.

**Methodology:** Ye Zhao.

**Writing – original draft:** Qiu -Man Wang, Ye Zhao, Ying Ma, Li-Ting Yao, Xiao Han.

**Writing – review & editing:** Qiu -Man Wang, Ye Zhao, Ying Ma, Li-Ting Yao, Xiao Han.

## References

- [1] Doss BJ, Wanek SM, Jacques SM, et al. Ovarian leiomyomas: clinicopathologic features in fifteen cases. *Int J Gynecol Pathol* 1999;18:63–8.
- [2] Wei C, Lilic N, Shorter N, et al. Primary ovarian leiomyoma: a rare cause of ovarian tumor in adolescence. *J Pediatr Adolesc Gynecol* 2008;21:33–6.
- [3] Kim M. Laparoscopic management of a twisted ovarian leiomyoma in a woman with 10 weeks' gestation: case report and literature review. *Medicine* 2016;95:e5319.
- [4] Sanverdi I, Vural F, Temizkan O, et al. Primary ovarian leiomyoma in a postmenopausal woman: a case report. *North Clin Istanbul* 2016;3:222–4.
- [5] Khangar B, Mallya V, Khurana N, et al. Coexisting leiomyomata peritonealis disseminata and ovarian leiomyoma. *J Midlife Health* 2017;8:45–7.
- [6] Lerwill MF, Sung R, Oliva E, et al. Smooth muscle tumors of the ovary: a clinicopathologic study of 54 cases emphasizing prognostic criteria, histologic variants, and differential diagnosis. *Am J Surg Pathol* 2004;28:1436–51.
- [7] Hsiao CH, Wang HC, Chang SL. Ovarian leiomyoma in a pregnant woman. *Taiwanese J Obstetr Gynecol* 2007;46:311–3.
- [8] Blue NR, Felix JC, Jaque J. Primary ovarian leiomyoma in a premenarchal adolescent: first reported case. *J Pediatr Adolesc Gynecol* 2014;27:87–8.
- [9] Akizawa Y, Miyashita T, Sasaki R, et al. Gorlin syndrome with an ovarian leiomyoma associated with a PTCH1 second hit. *Am J Med Genet A* 2016;170:1029–34.
- [10] Erdemoglu E, Kamaci M, Bayram I, et al. Primary giant leiomyoma of the ovary—case report. *Eur J Gynaecol Oncol* 2006;27:634–5.
- [11] Kim M, Lee C, Ko J, et al. Torsion of ovarian leiomyoma in a woman with 10 weeks' gestation. *J Minim Invasive Gynecol* 2015;22:S201–2.
- [12] Kawano Y, Takai N, Shimano M, et al. Magnetic resonance imaging findings in leiomyoma of the ovary: a case report. *Arch Gynecol Obstet* 2006;273:298–300.
- [13] van Esch EM, van Wijngaarden SE, Schaafsma HE, et al. The diagnostic and therapeutic approach of a primary bilateral leiomyoma of the ovaries: a case report and a literature review. *Arch Gynecol Obstet* 2011;283:1369–71.
- [14] Ip PP, Tse KY, Tam KF. Uterine smooth muscle tumors other than the ordinary leiomyomas and leiomyosarcomas: a review of selected variants with emphasis on recent advances and unusual morphology that may cause concern for malignancy. *Adv Anat Pathol* 2010;17:91–112.
- [15] Kim JC, Sang LN, Suh KS. Leiomyoma of the ovary mimicking mucinous cystadenoma. *Clin Imaging* 2000;24:34–7.