

# Multiple Bulky Lymph Nodal Metastasis in Microinvasive Cervical Cancer: A Case Report and Literature Review

Claudia Marchetti Natalina Mancini Milena Pernice  
Chiara Di Tucci Carlo Carraro Moira Burratti  
Margherita Giorgini Pierluigi Benedetti Panici

Department of Obstetrics and Gynecology, 'Sapienza' University of Rome, Rome, Italy

## Key Words

Cervical cancer · Microinvasive carcinoma · Lymph nodal spread · Bulky

## Abstract

Microinvasive squamous cell cervical carcinoma is characterized by an exceptional incidence of lymph nodal metastasis. We report the case of a 45-year-old woman affected by IA1 squamous cell carcinoma, found to have massive pelvic lymph nodal metastasis. After a systematic pelvic and aortic selective lymphadenectomy, at 16 months of follow-up, she is still disease-free. Patients suitable for conservative therapy should be carefully counselled about the established risks and benefits of nondestructive treatment options.

## Introduction

In 1994, the Congress of the International Federation of Gynecology and Obstetrics (FIGO) defined stage IA1 squamous cell carcinoma of the cervix as microscopic tumor with stromal invasion no greater than 3 mm in depth and 7 mm in width [1]. The standard treatment for this stage of disease consists of a complete removal of the cervix by a total abdominal or vaginal hysterectomy [2]. Conservative treatments such as cervical conization or trachelectomy are also increasingly proposed and safely performed in cases of young women who want to preserve their fertility. These modulated surgical strategies have been based on the evidence of favourable long-term outcomes; in fact, for stage IA1 nodal involvement is exceptional, ranging between 0.5 and 1.9% [3], and excellent

survival rates have been observed. We describe the case of a patient with stage IA1 squamous cell carcinoma with unexpected pelvic lymph node spread.

### Case Report

We report a 45-year-old woman, gravida 3, para 0, who was referred to our institution for menometrorrhagia in August 2006. She underwent pelvic examination, ultrasonographic evaluation and colposcopy that showed an irregular transformation zone and a squamocolumnar junction not entirely visible. A Pap smear was performed and revealed a high-grade squamous intraepithelial neoplasia (H-SIL). The patient was subjected to a cold knife conization and the cone specimen, measuring  $2.9 \times 1.8$  cm, was submitted to the pathology. Histological report confirmed the diagnosis of H-SIL and showed the presence of a focal lesion of moderately differentiated squamous cell carcinoma, with a depth of stromal invasion ranging between 0.9 and 2 mm and a lateral spread of 0.6 mm; apical resection margin and lymph-vascular space invasion (LVSI) were both negative.

Treatment options were discussed at length with the patient, including expectant management; she expressed a strong desire to avoid any future risk for recurrent disease. In October, the patient underwent total hysterectomy with bilateral adnexectomy. During surgery one suspicious right pelvic node was resected. Histological exam reported a negative uterine tissue and, unexpectedly, a metastatic squamous cervical carcinoma involving the external iliac node was detected ([fig. 1](#)).

The patient was scheduled for a total positron emission tomography-computed tomography (PET/CT) scan that showed a high uptake at the bilateral external ilium, confirming the presence of lymph nodal metastasis. In November 2006, the patient underwent relaparotomy and systematic pelvic lymphadenectomy plus radical parametrectomy. Two groups of pelvic nodes (superficial obturators, interiliac and external iliac nodes bilaterally) were sent for frozen section analysis in order to determine the tailoring of parametrectomy. Histological exam revealed a positive left nodes and Piver III–IV parametrectomy was performed. Lymphadenectomy was completed, removing deep obturator, presacral, internal and common iliac bilateral nodes, and a selective aortic lymphadenectomy. Definitive histological report revealed 4 metastatic bulky pelvic nodes of 3 cm with extracapsular involvement.

For further investigation one specimen each from cervical tissue and from lymph nodal metastases were tested for human papillomavirus (HPV) genotypes and human papillomavirus type 18 was detected in both.

An adjuvant chemotherapy with platinum 75 mg/mq p1q28 and paclitaxel 175 mg/mq p1q28 from January until May 2007 was administered. Up to now, after 35 months of follow-up, the patient is still disease-free.

### Discussion

The more recent knowledge and attention concerning screening programs and preventive medicine have achieved a very early diagnosis of cervical cancer. Nevertheless, although many efforts have been done in the last decade to unify the definitions, the management and the treatment of this medical condition, several aspects still remain controversial.

The current definition of early-stage cervical cancer has been definitely established in 1995, when the FIGO society defined stage IA1 squamous cell carcinoma of the cervix as a stromal invasion no greater than 3 mm in depth and 7 mm in width, meanwhile stage IA2 was defined as a stromal invasion with a depth of 3.0 mm to  $\leq 5.0$  mm, and an extension of  $\leq 7.0$  mm [1]. For stage IA1, nodal involvement is exceptional, ranging between 0.5 and 1.9% [3], and excellent survival rates have been observed. For all these reasons, conservative treatment such as cervical conization or trachelectomy have been used increasingly, besides the traditional extrafascial hysterectomy, in those women who wish to preserve their fertility and when surgical margins and LVSI are all negative [4].

In this paper we report the unusual case of a 45-year-old patient affected by IA1 cervical cancer with multiple and extracapsular lymph nodal metastasis. The patient was first subjected to extrafascial hysterectomy with selective pelvic lymph nodes dissection; subsequently, bulky lymph nodes were noted on imaging findings and lomboarctic lymphadenectomy with parametrectomy was performed. The final histopathologic report confirmed the presence of massive nodal involvement, meanwhile cervical tissue was disease-free.

To the best of our knowledge, only few analogous experiences have previously been reported in the literature ([table 1](#)). According to the literature data, lymph nodal involvement should be considered as the most powerful prognostic factor in the early cervical cancer; nevertheless, the question whether LVSI can also be esteemed as an independent risk variable still remains debated. In our review, when analyzing all the available data together with our report, LVSI does not seem to unequivocally correlate with the lymph nodal status, nor with the survival data ([table 2](#)); in fact, patients with LVSI seem to have a better prognosis when compared with those without LVSI; additionally, distant lymph nodal metastasis (paraaortic and supraclavicular lymph nodes) occur even without LVSI. Consequently, even if it is only a limited review, with few available data, the consideration arises that LVSI should be carefully pondered in the choice of conservative or destructive treatment.

It is also remarkable that, according to other experiences [[15](#)], the tumor and the metastatic tissue were both positive for the presence of HPV type 18, corroborating the hypothesis of the correlation between the virus and the aggressivity of the tumor, in term of prognosis and outcome.

Finally, a peculiar aspect of this report is that the preoperative evaluation of lymph nodal status was obtained by <sup>18</sup>F-fluorodeoxyglucose (FDG)-PET/CT scan, confirming and supporting the increasing evidence reported in the literature that FDG-PET/CT scan can be valuable for lymph node staging in patients with early-stage cervical cancer. In fact, comparative studies of FDG-PET with either CT or magnetic resonance (MR) imaging for depicting lymph node spread [[16](#)] have suggested a more significant role for FDG-PET, with a specificity of 99.7% and an accuracy of 99.3%.

This report adds a new case of FIGO stage IA1 cervical cancer with extensive lymph nodal spread, to emphasize the possibility of nodal metastases in the setting of microinvasive squamous carcinoma. The patients suitable for conservative therapy should be accurately selected, with the aid of new diagnostic tools, such as PET/CT for the clinical staging and molecular biomarkers for a more reliable prognostic correlation with the pathological findings. In any case, this subset of patients should also be carefully counselled about the established risks and benefits of nondestructive treatment options.

### Acknowledgements

The histological slides were prepared in the laboratory at the Department of Pathologic Anatomy, Policlinico Umberto I, 'Sapienza' University of Rome, Italy. Thanks go to Professor Ugo Di Tondo. Repeated follow-up was required for the patient. It is conducted by Professor Maria Luisa Frammarino dei Malatesta; thanks to her.

**Table 1.** Literature review of lymph node metastasis in microinvasive cervical cancer IA1 and correlation to LVSI+

Author, year	No. of cases	LND	Positive LNs (%)	LVSI+	Histotype
<i>Case series</i>					
Bohm et al., 1976 [5]	69	56	4 (7.14)	2	Squamous
Seski et al., 1977 [6]	54	37	1 (2.70)	0	Squamous
Hasumi et al., 1980 [7]	106	106	1 (0.9)	3	Squamous
Maiman et al., 1988 [8]	83	65	1 (1.5)	5	Squamous
Tsukamoto et al., 1989 [9]	103	103	1 (0.9)	4	Squamous
Elliott et al., 2000 [3]	387	121	1 (0.8)	N.A.	Squamous
Smith et al., 2002 [10]	200	70	2 (2.85)	–	Adenocarcinoma/ adenosquamous
Lee and Lee, 2006 [11]	174	116	3 (2.58)	7	Squamous
Total			14		
<i>Case report</i>					
Collins et al., 1989 [12]	1	1	1	0	Squamous
Nagarsheth et al., 2000 [13]	1	1	1	0	Adenocarcinoma
Argenta et al., 2005 [14]	1	1	1	0	Adenosquamous
Total			3		

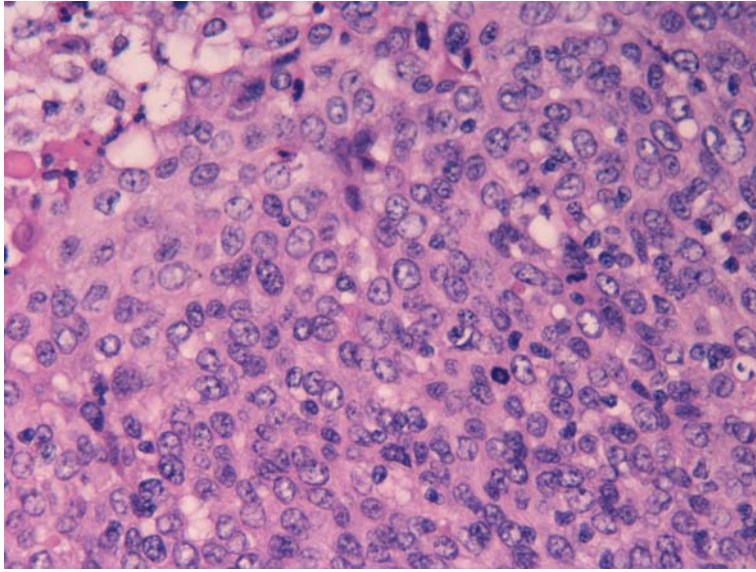
LND = lymph node dissection; LNs = lymph nodes; – = not reported; LVSI = lymph-vascular space invasion; N.A. = not available.

**Table 2.** Analysis of patients with positive nodes

Author, year	Pts. with positive LNs	Lymph nodal sites	LVSI	Status	Histotype
Bohm et al., 1976 [5]	4	3 Left obturator 1 Left external iliac, right external iliac	2 patients + 2 patients –	1 DOD at 2 years and 8 months, 1 DOD at 6 years and 4 months, 2 DID	Squamous
Seski et al., 1977 [6]	1	Pelvic	N.A.	NED	Squamous
Hasumi et al., 1980 [7]	1	Pelvic	–	N.A.	Squamous
Maiman et al., 1988 [8]	1	Pelvic	+	N.A.	Squamous
Tsukamoto et al., 1989 [9]	1	Left internal iliac	+	DID at 7 years	Squamous
Collins et al., 1989 [12]	1	Pelvic and paraaortic	–	DOD at 7 months	Squamous
Elliott et al., 2000 [3]	1	N.A.	–	DOD	N.A.
Nagarsheth et al., 2000 [13]	1	Pelvic	–	N.A.	Adenocarcinoma
Smith et al., 2002 [10]	1 (1)	Pelvic	N.A.	NED at 4 months	Endometrioid adenocarcinoma
	1 (3)	Pelvic	N.A.	DOD at 12 months	adenosquamous
Argenta et al., 2005 [14]	1	Pelvic and paraaortic	–	NED at 15 months	Adenosquamous
Lee and Lee, 2006 [11]	3	Left supraclavicular	–	DOD at 15 months	Squamous
		Pelvic	+	NED at 54 months	Squamous
		Pelvic	–	NED at 60 months	Squamous
Our case		Pelvic	–	NED at 12 months	Squamous

NED = no evidence of disease; DOD = died of disease; DID = died of intercurrent disease; LVSI = lymph-vascular space invasion; N.A. = not available.

**Fig. 1.** Lymphatic metastasis in squamous cell cervical carcinoma stage IA1.



## References

- 1 Creasman WT: New gynecologic cancer staging. *Gynecology Oncology* 1995;58:157–158.
- 2 Cairns M, Cruickshank M: Treatment and follow-up of women with microinvasive cervical cancer. *Reviews in Gynaecological and Perinatal Practice* 2006;6:126–132.
- 3 Elliott P, Coppleson M, Russell P: Early invasive (FIGO stage IA) carcinoma of the cervix: a clinico-pathologic study of 476 cases. *Int J Gynecol Cancer* 2000;10:42–52.
- 4 Itsukaichi M, Kurata H, Matsushita M: Stage IA1 cervical squamous cell carcinoma: conservative management after laser conization with positive margins. *Gynecol Oncol* 2003;90:387–389.
- 5 Bohm JW, Krupp PJ, Lee FYL: Lymph node metastasis in microinvasive epidermoid cancer of the cervix. *Obstet Gynecol* 1976;48:65–67.
- 6 Seski JC, Abell MR, Morley GW: Microinvasive squamous carcinoma of the cervix. Definition, histologic analysis, late results of treatment. *Obstet Gynecol* 1977;50:410–414.
- 7 Hasumi K, Sakamoto A, Sugano H: Microinvasive carcinoma of the uterine cervix. *Cancer* 1980;45:928–931.
- 8 Maiman MA, Fruchter RG, Di Maio TM: Superficially invasive squamous cell carcinoma of the cervix. *Obstet Gynecol* 1988;72:399–403.
- 9 Tsukamoto N, Kaku T, Matsukuma K: The problem of stage 1a (FIGO, 1985) carcinoma of the uterine cervix. *Gynecol Oncol* 1989;34:1–6.
- 10 Smith HO, Qualls CR, Romero AA: Is there a difference in survival for IA1 and IA2 adenocarcinoma of the uterine cervix? *Gynecol Oncol* 2002;85:229–241.
- 11 Lee KBM, Lee JM: Lymph node metastasis and lymph vascular space invasion in microinvasive squamous cell carcinoma of the uterine cervix. *Int J Gynecol Cancer* 2006;16:1184–1187.
- 12 Collins HS, Burke TW, Woodward JE: Widespread lymph node metastases in a patient with microinvasive cervical carcinoma. *Gynecology Oncology* 1989;34:219–221.
- 13 Nagarsheth NP, Maxwell GL, Bentley RC: Bilateral pelvic lymph node metastases in a case of FIGO stage IA1 adenocarcinoma of the cervix. *Gynecol Oncol* 2000;77:467–470.
- 14 Argenta PA, Kubicek GJ, Dusenberry KE: Widespread lymph node metastases in a young woman with FIGO stage IA1 squamous cervical cancer. *Gynecol Oncol* 2005;97:659–661.
- 15 Im SS, Wilczynski SP, Burger RA: Early stage cervical cancers containing human papillomavirus type 18 DNA have more nodal metastasis and deeper stromal invasion. *Clinical Cancer Res* 2003;9:4145–4150.
- 16 Sironi S, Buda A, Picchio M: Lymph node metastasis in patients with clinical early-stage cervical cancer: detection with integrated FDG PET/CT. *Radiology* 2006;238:272–279.