

A de Winter electrocardiographic pattern caused by left main coronary artery occlusion: A case report

Journal of International Medical Research
48(5) 1–6

© The Author(s) 2020

Article reuse guidelines:

sagepub.com/journals-permissions

DOI: 10.1177/0300060520927209

journals.sagepub.com/home/imr



Zhong-Qun Zhan , Yang Li, Li-Hao Wu and Li-Hong Han

Abstract

A de Winter electrocardiographic (ECG) pattern comprising precordial junctional ST depression followed by tall, positive symmetrical T waves in leads V1/V2 to V4/V6 is often concomitant with ST elevation in lead aVR. This finding strongly suggests proximal left anterior descending coronary artery occlusion. We described a patient who had the de Winter ECG pattern in leads V2 to V4 by acute left main coronary artery (LMCA) occlusion. The ECG also showed maximal ST depression in leads V4 to V5 and inverted T waves in leads V5 to V6. This finding indicated a global subendocardial ischemia ECG pattern, which suggested LMCA or three-vessel disease. Early recognition of this ECG manifestation is important for averting a disastrous prognosis in acute LMCA occlusion because emergent coronary intervention may be life-saving.

Keywords

Acute coronary occlusion, de Winter ECG pattern, left main coronary artery, electrocardiogram, aVR ST-segment elevation, diffuse ST-segment depression

Date received: 9 February 2020; accepted: 27 April 2020

Introduction

A de Winter electrocardiographic (ECG) pattern comprising precordial junctional ST depression (STD) followed by tall, positive symmetrical T waves in leads V1/V2 to V4/V6 is often concomitant with ST

Department of Cardiology, Shenzhen Hospital-University of Chinese Academy of Sciences, Shenzhen, P.R. China

Corresponding author:

Zhong-Qun Zhan, Department of Cardiology, Shenzhen Hospital-University of Chinese Academy of Sciences, No. 2453 Songbai Road, Guangming District, Shenzhen 518106, P.R. China.

Email: zzqun21@126.com



Creative Commons Non Commercial CC BY-NC: This article is distributed under the terms of the Creative Commons Attribution-NonCommercial 4.0 License (<https://creativecommons.org/licenses/by-nc/4.0/>) which permits non-commercial use, reproduction and distribution of the work without further permission provided the original work is attributed as specified on the SAGE and Open Access pages (<https://us.sagepub.com/en-us/nam/open-access-at-sage>).

elevation (STE) in lead aVR. This situation strongly suggests proximal left anterior descending coronary artery (LAD) occlusion and is regarded as an ST-elevation myocardial infarction (STEMI) equivalent by some investigators.¹⁻⁵ The original description of the de Winter pattern was upsloping STD. However, in the ECG samples of the original article on the de Winter pattern, not all patients had upsloping STD.³ A systematic review showed that the de Winter ECG pattern of acute LAD occlusion is typically located in leads V2 to V4.² Junctional STD followed by tall, positive symmetrical T waves may also be associated with right coronary artery (RCA) occlusion when present in the inferior leads.⁶ This condition is also associated with occlusion of a gigantic obtuse marginal artery in the lateral and inferior leads,⁷ obstruction of the left main coronary artery (LMCA) in leads V3/V4 to V6,^{8,9} or with first diagonal branch occlusion with involvement of leads V2 to V5.¹⁰ However, the de Winter ECG pattern in leads V2 to V4 is a rare manifestation of acute LMCA occlusion. We present a case of a patient with the de Winter ECG pattern in leads V2 to V4 by LMCA occlusion.

Case presentation

A 54-year old man was transferred from a local hospital to the Emergency Department with a 2-hour history of persistent chest pain radiating to the neck. He reported episodes of exertional angina pectoris for 1 year. Risk factors for coronary artery disease included hypertension and obesity that were not well controlled. His blood pressure (BP) was 160/95 mmHg. Cardiac auscultation showed soft heart sounds without murmurs. Pulmonary auscultation did not show any rales. ECG on admission (Figure 1a) showed sinus rhythm of 94 beats/minute (bpm), a qR pattern in leads I and aVL, an rS pattern in the

inferior leads, and SIII >SII, which suggested left anterior fascicular block. There was also STE in lead aVR >V1, a narrow Q wave in V2, downsloping STD in III and aVF, and horizontal STD in I and II, and in V3 to V5 (V6 had a shifting baseline). There was profound STD followed by tall, positive symmetrical T waves (de Winter ECG pattern) in leads V2 to V4, profound STD with inverted T waves in leads V5 to V6, and maximal STD in leads V4 to V5. The troponin I level was 150 ng/mL (normal value: <50 ng/mL). The preliminary diagnosis was non-ST-elevation myocardial (NSTEMI).

Emergent coronary angiography was indicated because there were ECG signs of global ischemia (STD in 9 leads and STE in aVR) and a typical ECG pattern of severe coronary artery disease, including LMCA stenosis and the STEMI equivalent de Winter ECG pattern. The patient was administered ticagrelor 180 mg, acetylsalicylic acid 300 mg, and rosuvastatin 20 mg. The patient was then directly transferred to the catheterization laboratory. Angiography showed total occlusion of the LMCA (Figure 1b) and collateral circulation to the distal LAD (Figure 1c) from the RCA. The LMCA was opened by aspiration of thrombus and stent implantation, and Thrombolysis In Myocardial Infarction 3 flow was observed (Figure 1e). After opening the LMCA, a small left circumflex coronary artery was observed and there was 80% stenosis in the LAD (Figure 1e). The patient developed ventricular fibrillation, which was reversed by defibrillation after opening of the LMCA. An ECG after reperfusion showed sinus rhythm of 68 bpm and resolution of the ST-segment deviations. There was a QS wave in leads V1 to V2, an embryonic r wave in lead V3 together with a negative T wave in leads V2 to V5, and disappearance of the de Winter ECG pattern in leads V2 to V4 and left anterior fascicular block (Figure 1d). The patient recovered

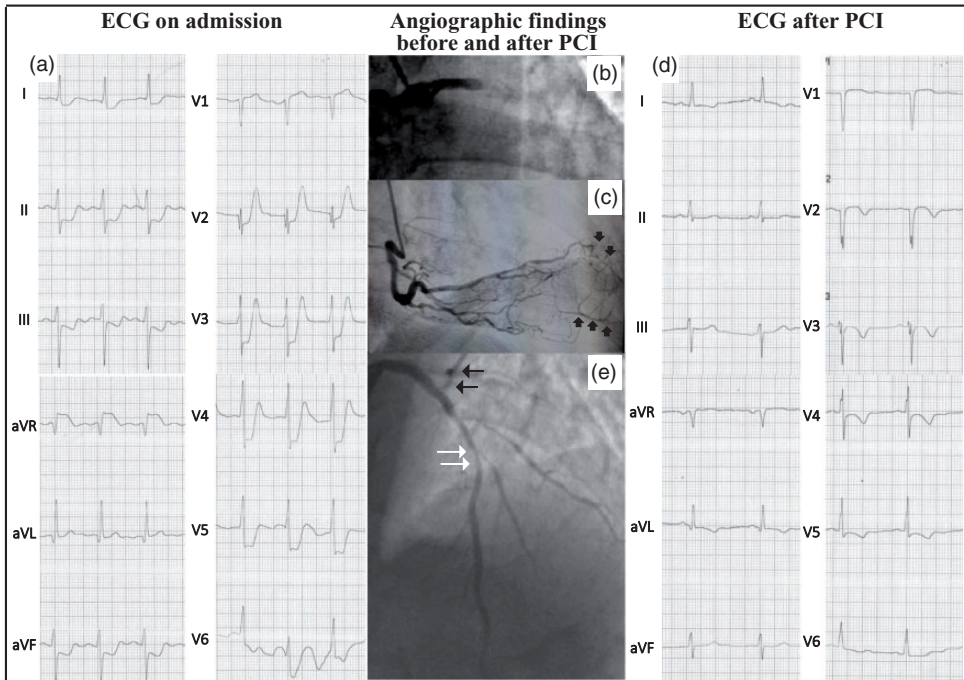


Figure 1. (a) ECG on admission showed sinus rhythm of 94 beats/minute, a qR pattern in leads I and aVL, an rS pattern in the inferior leads, and $S_{III} > S_{II}$, which suggested left anterior fascicular block. There was also a narrow Q wave in V2, and profound ST depression in leads I, II, III, and aVF ($II > III$ and aVF), and in all of the precordial leads, except for lead V1. There was junctional ST depression followed by tall, positive symmetrical T waves (de Winter ECG pattern) in leads V2 to V4 and profound ST depression with inverted T waves in leads V5 to V6. (b) Angiography shows total occlusion of the left main coronary artery. (c) Collateral circulation to the distal left anterior descending coronary artery (black arrow) from right coronary artery angiography. (e) The left main coronary artery was opened by aspiration of thrombus and stent implantation. A small left circumflex coronary artery (black arrows) can be seen. There is 80% stenosis in the left anterior descending coronary artery (white arrows). (d) An ECG after reperfusion showed sinus rhythm of 68 beats/minute and resolution of ST-segment deviation. There was a QS wave in leads V1 to V2, an embryonic r wave in lead V3 together with a negative T wave in leads V2 to V5, and disappearance of the de Winter sign in leads V2 to V4 and left anterior fascicular block. ECG: electrocardiogram; PCI: percutaneous intervention.

well and was discharged home on the eighth day of the hospital stay.

The study was approved by the ethics committee of Shenzhen Hospital-University of the Chinese Academy of Science. Verbal consent was obtained from the patient for the procedures and for publication.

Discussion

We present a unique case of the de Winter ECG pattern in leads V2 to V4 and diffuse

STD with concomitant STE in lead aVR caused by acute total occlusion of the LMCA. In patients with acute coronary syndrome, the ECG pattern with seven or more leads with STD and reciprocal STE in aVR, and often in V1, is due to subtotal occlusion with subendocardial ischemia.^{11–13} This situation has been erroneously attributed to LMCA occlusion. Although our patient had total occlusion of the LMCA, the ECG pattern was attributed to good collateral circulation from the RCA.

An ECG presentation in the precordial leads is variable in patients with obstruction of the LMCA because of varying contributions of the LAD and circumflex components and different ischemic severity.⁸ A well-developed collateral circulation from the RCA is often found in NSTEMI associated with LMCA occlusion.¹⁴ When LMCA occlusion is total and severe transmural ischemia develops in patients without a perceived collateral circulation, the patient usually presents with STEMI similar to LAD occlusion proximal to the first septal and first diagonal branches. However, there may be no STE in leads V1 and aVR because of left circumflex coronary artery involvement.¹⁴ Therefore, acute total LMCA occlusion in patients with a well-developed collateral circulation from the RCA may not cause significant STE, or even result in STD in the precordial leads. The de Winter ECG pattern in leads V2 to V4 strongly suggests proximal LAD occlusion. This is mainly because leads V2 to V4 are the core leads perfused by the LAD,¹⁻⁵ while diffuse STD with inverted T waves maximally in leads V4 to V5 (global ischemia ECG pattern) is the typical manifestation of angiographic LMCA disease or severe three-vessel disease.^{15,16} STD in the precordial leads is a common ECG finding of sub-total LMCA occlusion or total occlusion with collateral circulation. However, the de Winter ECG pattern in leads V2 to V4 caused by acute occlusion of the LMCA is probably a rare manifestation of LMCA disease. Sunbul et al.⁹ reported one patient with the de Winter ECG pattern in leads V3 to V6 caused by LMCA subtotal occlusion. Our research group⁸ previously reported another patient with the de Winter ECG pattern in leads V4 to V6 by LMCA disease. A recent study by Tuohinen et al.¹⁷ suggested that the typical ECG changes in patients with NSTEMI are associated with subtle echocardiographic changes. These authors compared ECG

changes with the “modern” echocardiography technique and found that STD was related to changes in diastolic function, while inverted T waves were associated with systolic deterioration. Subendocardial ischemia with myocardial protection through the collateral circulation or ischemic preconditioning has been proposed as the pathophysiological background of the de Winter ECG pattern.^{18,19} Therefore, we hypothesize that the de Winter ECG pattern in leads V2 to V4 with concomitant STD and inverted T waves in leads V5 to V6 can be found in patients with acute LMCA occlusion when there is a well-developed collateral circulation without severe systolic functional deterioration. We consider that a well-developed collateral circulation to the LAD and ischemic preconditioning protected our case from transmural ischemia in the anterior wall and severe systolic functional deterioration. Our patient presented with the de Winter ECG pattern in leads V2 to V4 and STD with inverted T waves in leads V5 to V6 without development of cardiogenic shock.

The de Winter ECG pattern associated with LAD disease consistently presents with STD followed by positive T waves in the precordial leads and maximal STD is usually found in lead V3.² Although our patient presented with the de Winter ECG pattern in leads V2 to V4, maximal STD in leads V4 to V5 and inverted T waves in leads V5 to V6 were distinct characteristics that were different from LAD occlusion. This finding may indicate a global subendocardial ischemia ECG pattern suggestive of LMCA or three-vessel disease.²⁰

There is one other possible explanation for the STD in leads V2 to V4 in our patient. Posterior (currently called lateral) STE myocardial infarction may show similar STD with positive T waves. However, in such cases, the T wave in V2 is not as large as it was in our case. Moreover, STD would be maximal in leads V2 to V4, whereas in

our case, it was maximal in leads V4 to V5. Finally, STE in lead aVR, which is reciprocal to ST depression in leads II and V5, would not be so pronounced.

Conclusion

The de Winter ECG pattern in leads V2 to V4 can be caused by acute occlusion of the LMCA. Maximal STD in leads V4 to V5 and inverted T waves in leads V5 to V6 may indicate a global subendocardial ischemia ECG pattern suggestive of LMCA or three-vessel disease. Early recognition of these ECG manifestations is important for averting a disastrous outcome in LMCA occlusion because emergent invasive therapy may save lives.

Declaration of conflicting interest

The authors declare that there is no conflict of interest.

Funding

This research was supported by key medical disciplines of Guangming District.

ORCID iD

Zhong-Qun Zhan  <https://orcid.org/0000-0002-0982-5194>

References

1. Littmann L. The Dressler - de Winter sign of acute proximal LAD occlusion. *J Electrocardiol* 2018; 51: 138–139.
2. Morris NP and Body R. The De Winter ECG pattern: morphology and accuracy for diagnosing acute coronary occlusion: systematic review. *Eur J Emerg Med* 2017; 24: 236–242.
3. De Winter RJ, Verouden NJ, Wellens HJ, et al. A new ECG sign of proximal LAD occlusion. *N Engl J Med* 2008; 359: 2071–2073.
4. Verouden NJ, Koch KT, Peters RJ, et al. Persistent precordial “hyperacute” T-waves signify proximal left anterior descending artery occlusion. *Heart* 2009; 95: 1701–1706.
5. De Winter RW, Adams R, Verouden NJ, et al. Precordial junctional ST-segment depression with tall symmetric T-waves signifying proximal LAD occlusion, case reports of STEMI equivalence. *J Electrocardiol* 2016; 49: 76–80.
6. Tsutsumi K and Tsukahara K. Is the diagnosis ST-segment elevation or non-ST-segment elevation myocardial infarction. *Circulation* 2018; 138: 2715–2717.
7. Xu W, Zou H and Huang S. Junctional ST-depression and tall symmetrical T-waves with an obtuse marginal artery occlusion: a case report. *J Electrocardiol* 2019; 54: 40–42.
8. Zhan ZQ, Nikus K and Birnbaum Y. Different ECG patterns of left main coronary artery occlusion signifying varying degrees of ischemic severity. *J Electrocardiol* 2020; 60: 12–14. Doi: 10.1016/j.jelectrocard.2020.02.010.
9. Sunbul M, Erdogan O, Yesildag O, et al. De Winter sign in a patient with left main coronary artery occlusion. *Postepy Kardiologii Interwencyjnej* 2015; 11: 239–240.
10. Montero Cabezas JM, Karalis I and Schalijs MJ. De Winter electrocardiographic pattern related with a non-left anterior descending coronary artery occlusion. *Ann Noninvasive Electrocardiol* 2016; 21: 526–528.
11. Smith SW. Updates on the electrocardiogram in acute coronary syndromes. *Curr Emerg Hosp Med Rep* 2013; 1: 43–52.
12. Miranda DF, Lobo AS, Walsh B, et al. New insights into the use of the 12-lead electrocardiogram for diagnosing acute myocardial infarction in the Emergency Department. *Can J Cardiol*. 2018; 34: 132–145.
13. Yip HK, Wu CJ, Chen MC, et al. Effect of primary angioplasty on total or subtotal left main occlusion: analysis of incidence, clinical features, outcomes, and prognostic determinants. *Chest* 2001; 120: 1212–1217.
14. Fiol M, Carrillo A, Rodríguez A, et al. Electrocardiographic changes of ST-elevation myocardial infarction in patients with complete occlusion of the left main trunk without collateral circulation: differential diagnosis and clinical considerations. *J Electrocardiol* 2012; 45: 487–490.

15. Nikus K, Järvinen O, Sclarovsky S, et al. Electrocardiographic presentation of left main disease in patients undergoing urgent or emergent coronary artery bypass grafting. *Postgrad Med* 2011; 123: 42–48.
16. Nikus KC, Eskola MJ, Virtanen VK, et al. ST-depression with negative T waves in leads V4-V5—a marker of severe coronary artery disease in non-ST elevation acute coronary syndrome: a prospective study of angina at rest, with troponin, clinical, electrocardiographic, and angiographic correlation. *Ann Noninvasive Electrocardiol* 2004; 9: 207–214.
17. Tuohinen SS, Rankinen J, Skyttä T, et al. Associations between ECG changes and echocardiographic findings in patients with acute non-ST elevation myocardial infarction. *J Electrocardiol* 2018; 51: 188–194.
18. Gorgels AP. Explanation for the electrocardiogram in subendocardial ischemia of the anterior wall of the left ventricle. *J Electrocardiol* 2009; 42: 248–249.
19. Zhong-qun Z, Nikus KC and Sclarovsky S. Prominent precordial T waves as a sign of acute anterior myocardial infarction: electrocardiographic and angiographic correlations. *J Electrocardiol* 2011; 44: 533–537.
20. Knotts RJ, Wilson JM, Kim E, et al. Diffuse ST depression with ST elevation in aVR: is this pattern specific for global ischemia due to left main coronary artery disease. *J Electrocardiol* 2013; 46: 240–248.