

# Blood-sparing removal technique of extracorporeal membrane oxygenation circuit in a Jehovah Witness patient

## Case report

Sang Min Park, MD, PhD<sup>a,\*</sup>, Bom Lee, MD<sup>a</sup>, Christopher Y. Kim, MD<sup>b</sup>

### Abstract

**Rationale:** Percutaneous cardiopulmonary support (PCPS) using extracorporeal membrane oxygenation (ECMO) is widely used in the critical patients with cardiopulmonary collapse. It is a representative blood-consuming procedure. In limited situations in which the option of blood transfusion is unavailable, there is no general agreement as to whether ECMO is contraindicated.

**Patient concerns:** A 61-year-old male Jehovah Witness with acute respiratory collapse and loss of consciousness was rushed to our emergency room. Throughout his hospital course, the patient's family refused any type of blood transfusion even at the risk of death.

**Diagnosis:** The clinical situations were secondary to a massive pulmonary thromboembolism

**Interventions:** The patient underwent veno-venous ECMO via both femoral veins. The patient was recovered by intensive medical care although the level of hemoglobin (Hb) and hematocrit (Hct) was gradually decreased from 15.8 g/dl and 46.8% to 11.7 g/dl and 36.5%, respectively.

**Outcomes:** On hospital day 3, ECMO was successfully removed using a blood-sparing ECMO removal technique involving the recycling of blood within the circuit by continuous saline infusion. There was no significant change in level of Hb/Hct and hemodynamic profile. At 2 days after ECMO removal, the level of Hb/Hct was elevated up to 9.2 g/dl and 30.0%, respectively without any transfusion.

**Lessons:** Our blood-sparing removal technique of ECMO appears to be feasible and led to no significant adverse impact on hemodynamic status. The technique might be helpful for critical patients who cannot receive blood transfusion due to any cause.

**Abbreviations:** ECMO = extracorporeal membrane oxygenation, Hb = hemoglobin, Hct = hematocrit, PCPS = Percutaneous cardiopulmonary support.

**Keywords:** case report, extracorporeal membrane oxygenation, Jehovah Witness, transfusion

## 1. Introduction

Percutaneous cardiopulmonary support (PCPS) using extracorporeal membrane oxygenation (ECMO) has been widely used in

patients with cardiopulmonary collapse.<sup>[1-3]</sup> Almost all patients undergoing ECMO procedure receive multiple and massive blood transfusions because of procedural blood loss, frequent laboratory monitoring, and hemolysis. Especially, an amount of blood loss is unavoidable during the ECMO removal due to the considerable discarded blood within the ECMO circuit. Complicating the utilization of ECMO is if a patient cannot receive blood transfusions due to any cause including religious grounds or a shortage of blood supply due to a rare blood type.<sup>[4-6]</sup>

We managed a Jehovah Witness patient with severe hypoxia due to massive pulmonary thromboembolism using ECMO. Based on religious grounds, the family refused any type of blood transfusions throughout the entire hospital course. We successfully removed ECMO apparatus by blood-sparing technique of recycling blood in the circuit.

## 2. Case

A 61-year-old male came to the emergency room due to loss of consciousness and severe dyspnea. Upon arrival, he developed a generalized seizure. Subsequently, cardiac arrest occurred during preparation for brain imaging. A return of spontaneous

Editor: N/A.

Informed written consent was obtained from the guardian for publication of this case report and accompanying images.

The authors have no conflicts of interests to disclose.

<sup>a</sup> Cardiology Division, Cardiovascular Center, Chuncheon Sacred Heart Hospital, Hallym University College of Medicine, Chuncheon, Republic of Korea, <sup>b</sup> Utah Cardiology, Farmington, UT.

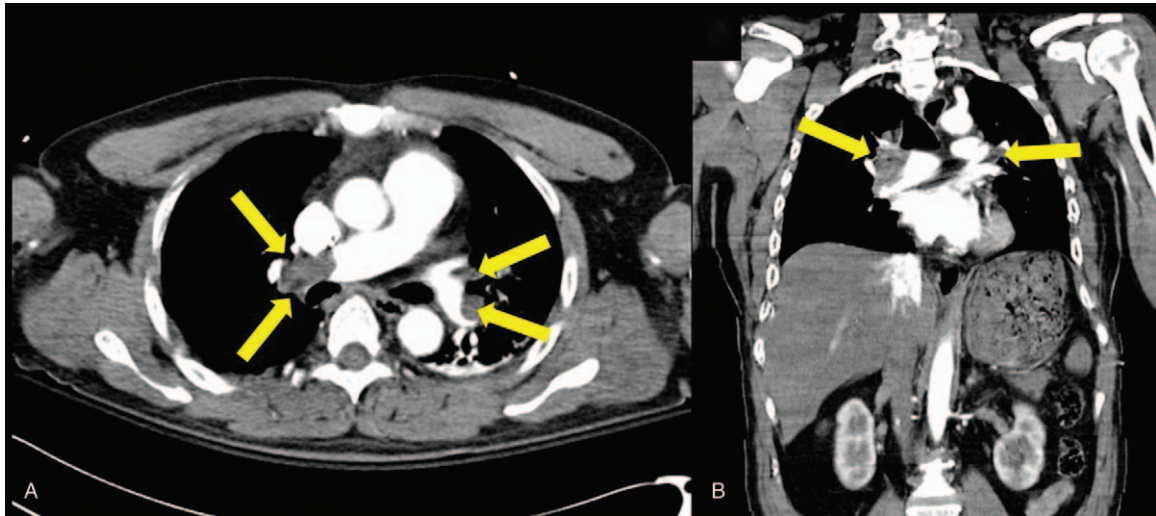
\* Correspondence: Sang Min Park, 77 Sakju-ro, Chuncheon 24253, Republic of Korea (e-mail: samipark@hanmail.net).

Copyright © 2019 the Author(s). Published by Wolters Kluwer Health, Inc. This is an open access article distributed under the terms of the Creative Commons Attribution-Non Commercial-No Derivatives License 4.0 (CCBY-NC-ND), where it is permissible to download and share the work provided it is properly cited. The work cannot be changed in any way or used commercially without permission from the journal.

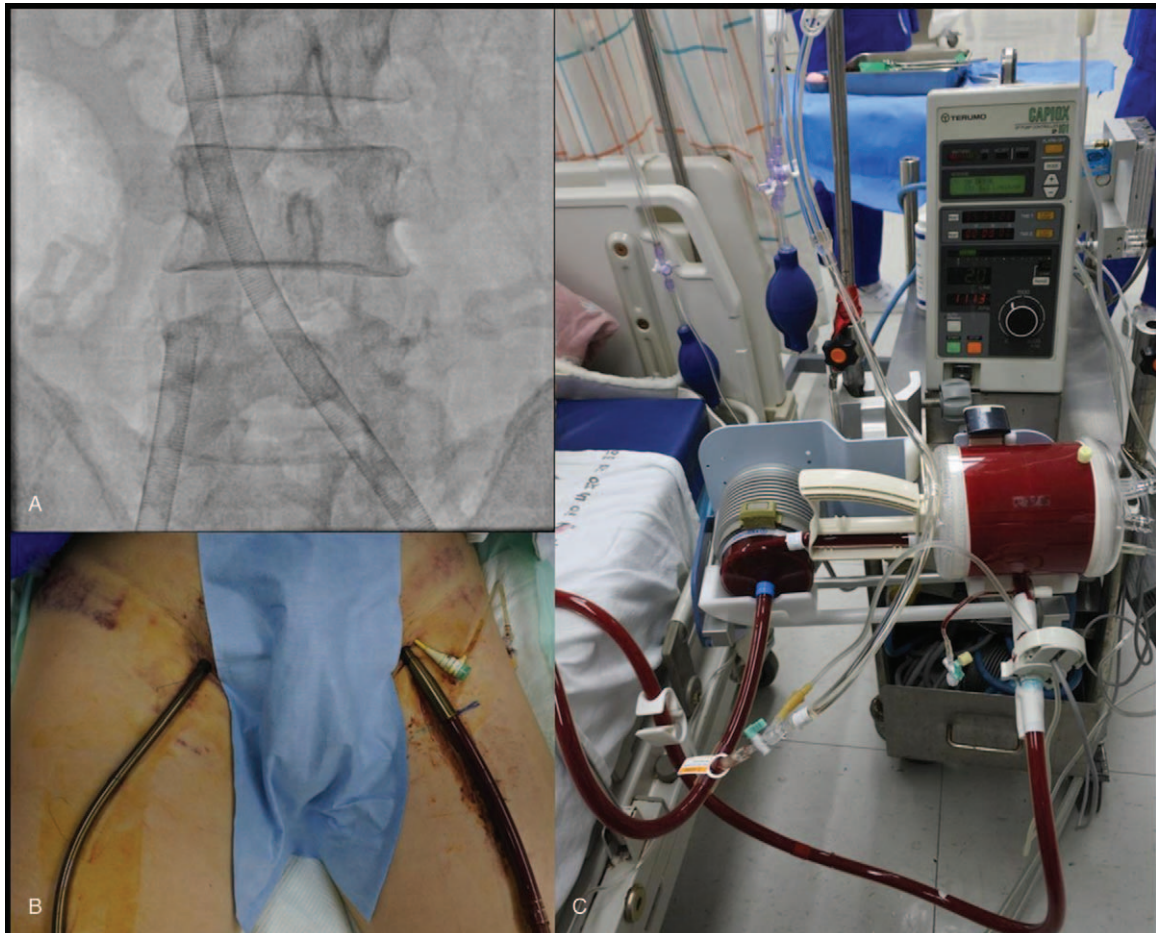
Medicine (2019) 98:31(e16740)

Received: 12 February 2019 / Received in final form: 31 May 2019 / Accepted: 15 July 2019

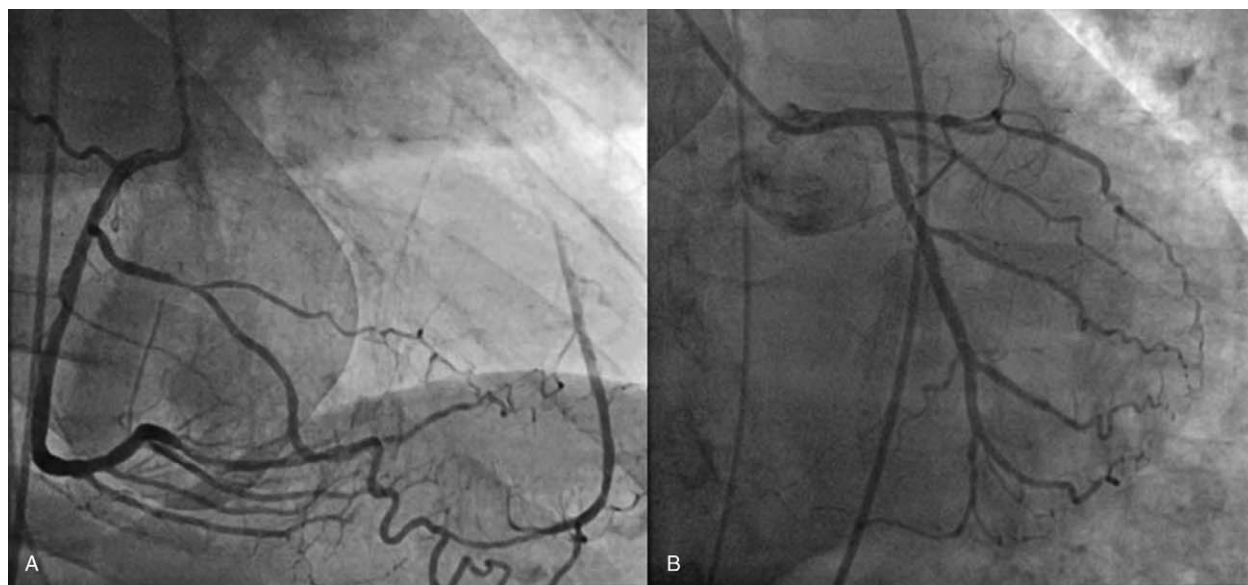
<http://dx.doi.org/10.1097/MD.00000000000016740>



**Figure 1.** Chest computed tomography (CT) scan showing large filling defects both main and lower lobe pulmonary arteries suggesting massive pulmonary thromboembolism (yellow arrows).



**Figure 2.** Veno-venous extracorporeal membrane oxygenation with the access cannula in the left femoral vein and the return cannula in the right femoral vein.



**Figure 3.** Coronary angiography showing chronic total occlusion of left anterior descending artery with good collateral flow from the distal part of the right coronary artery.

circulation was attained 3 minutes after initiation of cardiopulmonary resuscitation. There was no specific medical history such as hypertension and diabetes. Social history taking revealed that the patient was a Jehovah Witness. The patient had been suffering from a painful left thigh for several days. A chest computed tomography scan revealed large-sized filling defects in both main pulmonary arteries suggesting massive pulmonary thromboembolism (Fig. 1). The vital signs were improved with inotropic support. However, severe hypoxia was not corrected despite intensive mechanical ventilation with high oxygen flow.

For respiratory support, PCPS using ECMO during intensive care was considered. The guardian agreed to the ECMO procedure but strongly refused any type of blood transfusion including autotransfusion in deference to the patient's religious beliefs. After receiving informed consent, emergent veno-venous type ECMO (Capiiox EBS, Terumo, Tokyo, Japan) was applied in catheterization room (Fig. 2). Simultaneously performed coronary angiography showed chronic total occlusion of the proximal-to-mid segment of the left anterior descending artery with good collateral flow from the distal segment of the right coronary artery (Rentrop grading of II-III/III) (Fig. 3). Immediately after ECMO procedure, the level of Hb and Hct decreased from 15.8 g/dl and 46.8% to 11.7 g/dl and 36.5%, respectively. On hospital day 3, the level of Hb and Hct was gradually decreased to 7.7 g/dl and 23.6%, respectively. The global oxygenation was recovered with minimal support by ECMO. The decision was made to remove the ECMO apparatus.

In order to minimize additional blood loss, blood-sparing strategy during ECMO circuit removal should be attempted. Our blood-loss minimizing decannulation techniques were as follows: After the access cannula was clamped by hemostat, a total of 600 cc of saline was slowly infused via access cannula port to the ECMO circuit until the blood in entire circuit including the both cannulae, the pump, and the membrane chamber was replaced with saline. Then, the venous return cannula was clamped and both cannulae were carefully removed at 0 rpm of motor speed (Fig. 4). There was no evidence of air and/or thrombus entering


the circuit during the entirety of the ECMO removal procedure. Moreover, there was no significant change in patient hemodynamics before and after ECMO removal. Several hours later, the level of Hb and Hct was not changed. Two days after ECMO removal, the level of Hb and Hct was increase up to 9.2 g/dl and 30.0%, respectively (Fig. 5). Informed consent was given for publication of the case by the patient's guardian.

### 3. Discussions

PCPS using ECMO has been widely used in patients with intractable cardiogenic shock and/or brain hypoxia in an emergent setting. ECMO is considered as a representative blood-consuming procedure. During initial cannulation and maintenance of ECMO, frequent blood sampling is required to monitor the hematologic and metabolic status including anemia, acid-base balance, and thrombotic status.<sup>[7]</sup> Especially at weaning and decannulation, another massive blood loss is inevitable because the considerable blood in the removed circuit usually discarded.<sup>[1,7]</sup> For these reason, blood product transfusion is crucial during ECMO support period. Regretfully, there is no specific information or consensus in current guidelines for blood-saving during ECMO removal.<sup>[1]</sup>

Blood transfusion is often limited in some clinical situations such as a rare blood type or patient refusal due to various causes. From this social and medical standpoint, it is difficult to manage Jehovah Witness patients because they strongly refuse receiving any type of blood transfusion. Even in the special clinical situation, treatment strategies need to be individualized depending on the patients' clinical situation.<sup>[4,5]</sup> Moreover, the appropriate medical therapies, care, and consideration should be given in order to respect their individual autonomy.<sup>[8]</sup> To overcome this clinical handicap, several techniques have been proposed in previous literature; Iron supplementation, human recombinant erythropoietin injection, and bloodless cardiac surgery with autologous transfusion etc. in the surgical management of Jehovah Witness patient.<sup>[5,6]</sup>





**Figure 4.** Blood-sparing removal technique of ECMO circuit. The access cannula was clamped by hemostat (yellow circle) after saline was connected at the access cannula port (white rectangles) (A and B). Total 600 cc of saline was slowly infused into the EMCO circuit until the entire circuit was filled with saline (B and D). Quite different color change in the circuit with membrane chamber before (C and E) and after (D and F) the replacing the blood with saline is noted.

In the present case, we intended to recycle blood in the ECMO circuit including both access and return cannula and within the membrane chamber. ECMO circuit in our institute was designed to be filled with 500 cc of blood which is estimated as 2 or 3 units of packed red blood cell.<sup>[7]</sup> Owing to the technique, the level of Hb and Hct was increased without any transfusion at second day after ECMO circuit removal.

In conclusion, our blood-sparing removal technique of ECMO circuit appears to be feasible and led to no significant adverse impact on the patient's hemodynamic status. Our technique might be helpful for critical patients who cannot receive blood

transfusion due to any cause. Further clinical trials are warranted to validate this technique.

#### Author contributions

**Conceptualization:** Sang Min Park, Christopher Y Kim.

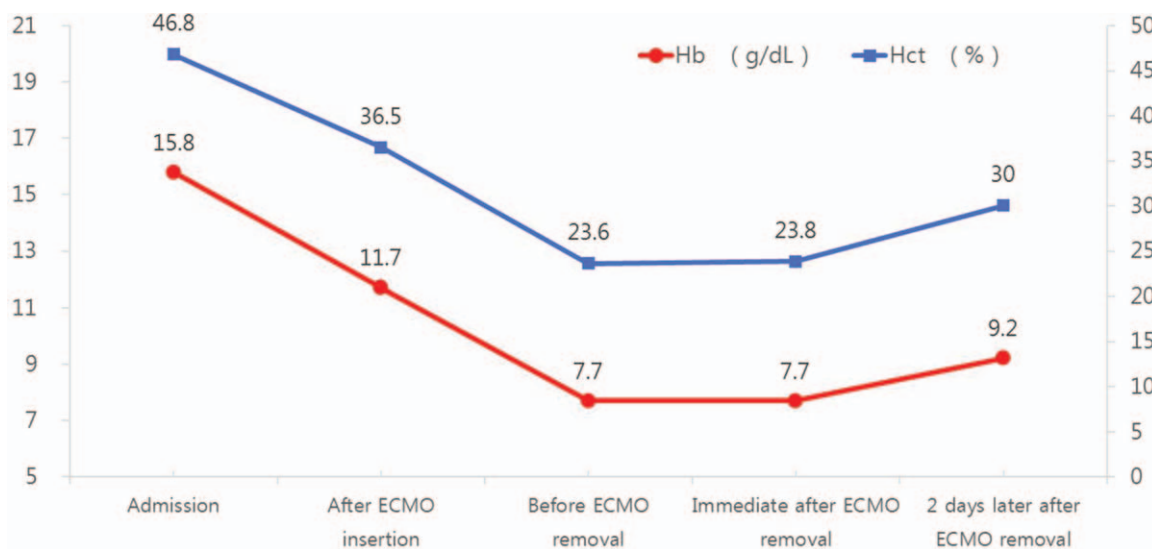
**Investigation:** Sang Min Park, Bom Lee.

**Methodology:** Sang Min Park, Bom Lee, Christopher Y Kim.

**Project administration:** Sang Min Park.

**Resources:** Sang Min Park.

**Supervision:** Sang Min Park, Christopher Y Kim.



**Figure 5.** Serial change of the level of hemoglobin (Hb) and hematocrit (Hct). The level of Hb and Hct was gradually decreased just before ECMO removal. It was increased without blood transfusion at 2 days after ECMO removal.

**Validation:** Sang Min Park.

**Visualization:** Sang Min Park.

**Writing – original draft:** Sang Min Park.

**Writing – review & editing:** Sang Min Park, Bom Lee, Christopher Y Kim.

**References**

[1] Makdisi G, Wang IW. Extra Corporeal Membrane Oxygenation (ECMO) review of a lifesaving technology. *J Thorac Dis* 2015;7: E166–76.

[2] Kjærgaard B, Rasmussen BS, de Neergaard S, et al. Extracorporeal cardiopulmonary support may be an efficient rescue of patients after massive pulmonary embolism. An experimental porcine study. *Thromb Res* 2012;129:e147–51.

[3] Leick J, Liebetrau C, Szardien S, et al. Percutaneous circulatory support in a patient with cardiac arrest due to acute pulmonary embolism. *Clin Res Cardiol* 2012;101:1017–20.

[4] Russo MJ, Merlo A, Eton D, et al. Successful use of ECMO in a Jehovah’s Witness after complicated re-heart transplant. *ASAIO J* 2013;59:528–9.

[5] Preston TJ, Olshove VFJr, Chase M. Bloodless extracorporeal membrane oxygenation in the Jehovah’s Witness patient. *J Extra Corpor Technol* 2012;44:39–42.

[6] Lindholm J, Palmér K, Frenckner B. Long-term ECMO treatment in Jehovah’s Witness patient without transfusions. *Perfusion* 2012;27:332–4.

[7] Thavendiranathan P, Bagai A, Ebidia A, et al. Do blood tests cause anemia in hospitalized patients? The effect of diagnostic phlebotomy on hemoglobin and hematocrit levels. *J Gen Intern Med* 2005;20:520–4.

[8] Kleinman I. The right to refuse treatment: ethical considerations for the competent patient. *CMAJ* 1991;144:1219–22.