



Since January 2020 Elsevier has created a COVID-19 resource centre with free information in English and Mandarin on the novel coronavirus COVID-19. The COVID-19 resource centre is hosted on Elsevier Connect, the company's public news and information website.

Elsevier hereby grants permission to make all its COVID-19-related research that is available on the COVID-19 resource centre - including this research content - immediately available in PubMed Central and other publicly funded repositories, such as the WHO COVID database with rights for unrestricted research re-use and analyses in any form or by any means with acknowledgement of the original source. These permissions are granted for free by Elsevier for as long as the COVID-19 resource centre remains active.



COVID-19 and otologic surgery

Donald Tan, MD, Kristen L. Yancey, MD, Jacob B. Hunter, MD

From the Department of Otolaryngology – Head and Neck Surgery, University of Texas Southwestern Medical Center, Dallas, TX, United States



KEYWORDS

Humans;
 COVID-19;
 Pandemics;
 Mastoidectomy;
 Ear;
 Middle;
 Cadaver;
 Virion;
 Otolaryngology;
 Mucous Membrane;
 SARS-CoV-2;
 Endoscopy

In this article, we aim to summarize the impacts of COVID-19 on the practice of otologic surgery. Cadaveric studies have indicated COVID-19 viral particles are present in the middle ear mucosa of infected hosts. Otologic procedures can generate significant amounts of droplets due to reliance on high-speed drills. Multiple guidelines have been developed to improve patient and provider safety peri-operatively. Particle dispersion can be mitigated during microscopic mastoidectomy by utilizing barrier drape techniques. The barrier drape may similarly be applied to the surgical exoscope. Endoscopic techniques have theoretical improved safety benefits by minimizing the need for drilling. The discoveries and innovations borne of the COVID-19 pandemic will lay the groundwork for the practice of otology amidst future pandemics.

© 2022 Elsevier Inc. All rights reserved.

Introduction

The Coronavirus Disease-19 (COVID-19) pandemic has forced many changes upon the practice of Otolaryngology. In the early days of the pandemic, little was known about the pathogenicity and routes of transmission of the novel virus. In many healthcare settings, the strain of increasing hospitalizations, staffing shortages, and supply chain disruptions led to temporary cessation of elective surgeries. Out of an abundance of caution, several policies and strategies were put into place by Otolaryngologists to balance protecting patients and providers alike from the rapid spread of COVID-19 with providing needed care. At the time of this submission, we lie at a unique juncture in the course of the pandemic. As we look back, we see that the widespread availability of vaccines and testing has

obviated the need for many of the restrictions and precautions of early pandemic times. However, as we look forward, emerging variant strains that evade immunity could threaten to undo the progress we have made. In this article, we aim to summarize and discuss techniques and considerations for practicing otologic surgery during uncertain pandemic times like COVID-19, so that we may be prepared to face the emerging pathogens of tomorrow.

COVID-19 and the middle ear

In March of 2020, the first study of the survivability of COVID-19 on surfaces raised the alarm that this virus was potentially highly transmissible via aerosols and fomites.¹ Around the same time, researchers identified high viral loads within swabs of the nasal passages – raising additional concern for the safe practice of otolaryngology.² Naturally, this raised several concerns pertaining to otology. Early studies explored whether the middle ear, a space that shares an epithelial lined connection with the nasopharynx, could harbor COVID-19 viral particles. In

Address reprint requests and correspondence: Jacob B. Hunter MD, Department of Otolaryngology Head and Neck Surgery, University of Texas Southwestern Medical Center, 2001 Inwood Road, Dallas, TX 75390-9035.

E-mail address: Jacob.Hunter@UTSouthwestern.edu

<http://doi.org/10.1016/j.otot.2022.04.004>

1043-1810/© 2022 Elsevier Inc. All rights reserved.

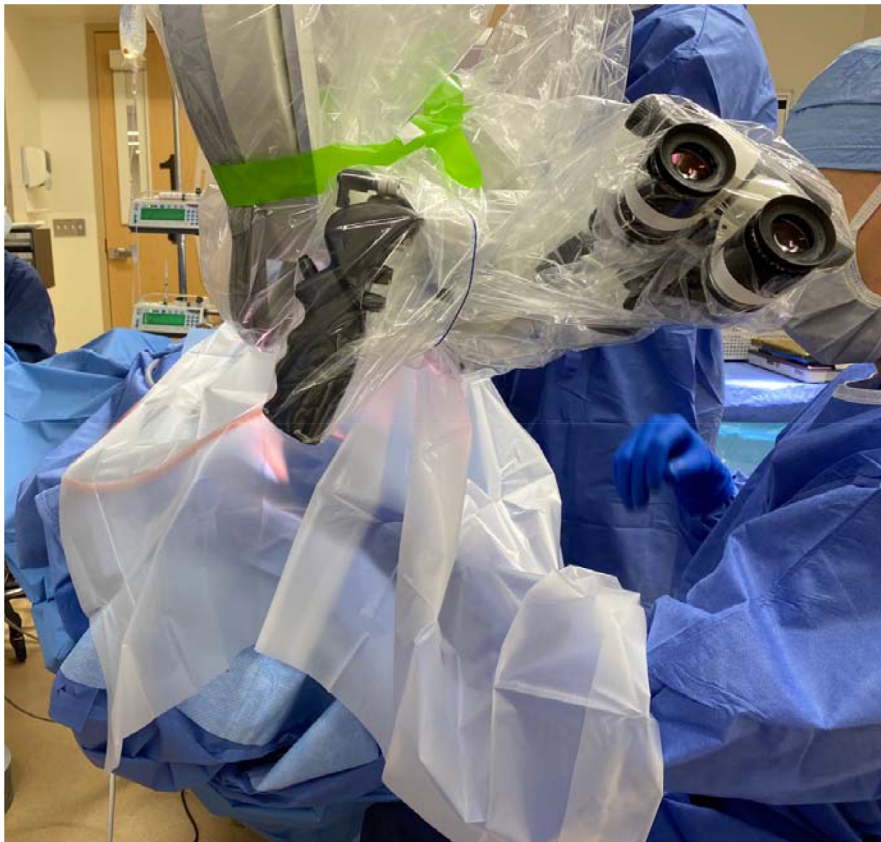

Figure 1 Demonstration of in-vivo utilization of the 'Ototent' fashioned from a 1060 Steri-Drape (3M).

the absence of definitive answers, the safety of surgically instrumenting the middle ear was called into question. Perhaps most importantly, it remains unclear what precautions should be taken.

To date no study has successfully demonstrated viable COVID-19 particles within the middle ear space of a live subject.^{2,3} However, several cadaveric studies have suggested this is likely to be the case. Frazier et al. were the first to confirm the presence of COVID-19 viral particles in the mastoid and middle ear with RT-PCR in 2 of 3 deceased subjects with a post-mortem interval ranging from 16 to 48 h.⁴ Other post-mortem studies corroborated these findings and additionally found viral particles present in the middle ear without any history of acute otitis media.⁵ In a case series by Kurabi et al. of 3 deceased subjects with detectable viral burden in the nasopharynx, 1 had middle ear viral load 1 thousand times lower than the nasopharynx, 1 had undetectable middle ear viral load, and 1 had viral load ten times higher than the nasopharynx.⁶ Thus, it is reasonable to hypothesize based on the existing evidence that the middle ear harbors COVID-19 particles in living hosts, however there remains a dearth of evidence as to whether these particles are transmissible via instrumentation during otologic procedures.

Pre-operative safety considerations

Various guidelines have been proposed during the pandemic to improve the delivery of safe otologic care.⁷⁻⁹ One suggestion has been the categorization of otologic surgeries into timeframes of urgency so that cases may be postponed in times of limited healthcare resources or in patients with active infection. George et al. provided considerations for delaying the timing of cholesteatoma surgery.⁷ They suggest decision to delay cholesteatoma surgery may be guided by disease activity, bone erosion on high-resolution CT, symptomatology, and presence of complications. Saadi et al. presented a 4 tiered schematic of "Elective, Semi-elective, Semiurgent, and Urgent and/or Emergent" otologic surgeries to guide timing of surgery during the active pandemic.⁹ Separately, the American Neurotology Society, American Otological Society, and American Academy of Otolaryngology – Head and Neck Foundation jointly proposed a 4 tiered system of "Emergent, Urgent, Time-sensitive, and Routine" surgical indications.⁸ For example, they classify coalescent mastoiditis as emergent, infected cholesteatoma failing antibiotics as urgent, cochlear implantation as time-sensitive, and stapedectomy as routine. Within this document they additionally provide suggestions about triaging clinic visits, selecting personal protective equipment (PPE) usage based on risk of procedure, and the role of trainees. While these guidelines may have limited applicability in various practice settings, they remain



Figure 2 Custom designed microscope drape (Grace Medical) featuring structure, operator arm ports, suction port, attachment device to the microscope lens, and adhesive to the patient side).

useful considerations to support the decision making of practicing otolaryngologists.

Mastoidectomy and aerosol generation

Literature from the early pandemic showed that endonasal instrumentation is sufficiently aerosol generating that it poses a transmission risk to the operating room staff.¹⁰ Operating under the assumption that the middle ear mucosa can host live viral particles, researchers have aimed to quantify the dispersion of particles during mastoidectomy to estimate the risk of intraoperative aerosol generation. In a literature review by Favre et al., 6 experiments aimed at describing particle spread during mastoidectomy were identified: 4 cadaveric, 1 live subject, and 1 plastic model. There was significant variation in experimental design, methodology, and primary outcomes that limited comparisons of the studies. In 2 of 6 studies fluorescent droplets were detected up to 2 meters away from the drilling site. Two studies reported direction of spread as an outcome measure and indicated that particles were mostly directed towards the surgeon yet present in all directions, implying risk to all intraoperative staff. They concluded that future studies are needed to determine the ef-

fects of burr type and/or size, and drill speed on particle dispersion. As it stands, mastoidectomy results in significant particle spread due to high-speed drilling. It remains undetermined whether viral particles exist within the dispersed particles, whether virus-containing aerosols are additionally generated, and how the risk of viral transmission during mastoidectomy compares to endonasal high-speed drilling given the suggested difference in viral load between the subsites.

Safety precautions for mastoidectomy – microsurgery

A unique pandemic era challenge of using the operating microscope is the limited ability to wear PPE while maintaining an adequate field of view. There is an inverse relationship between the surgeon's distance from the microscope and the resultant field of view. A recent study of various combinations of masks and eye protection showed that all goggles and face shields, as well as certain bulkier N95 masks decreased the operator's field of view.¹¹ In the most dramatic example, concurrent use of a N95 mask and visor face-shield decreased the visible target area from 100% without PPE to only 4%. Due to the concern for

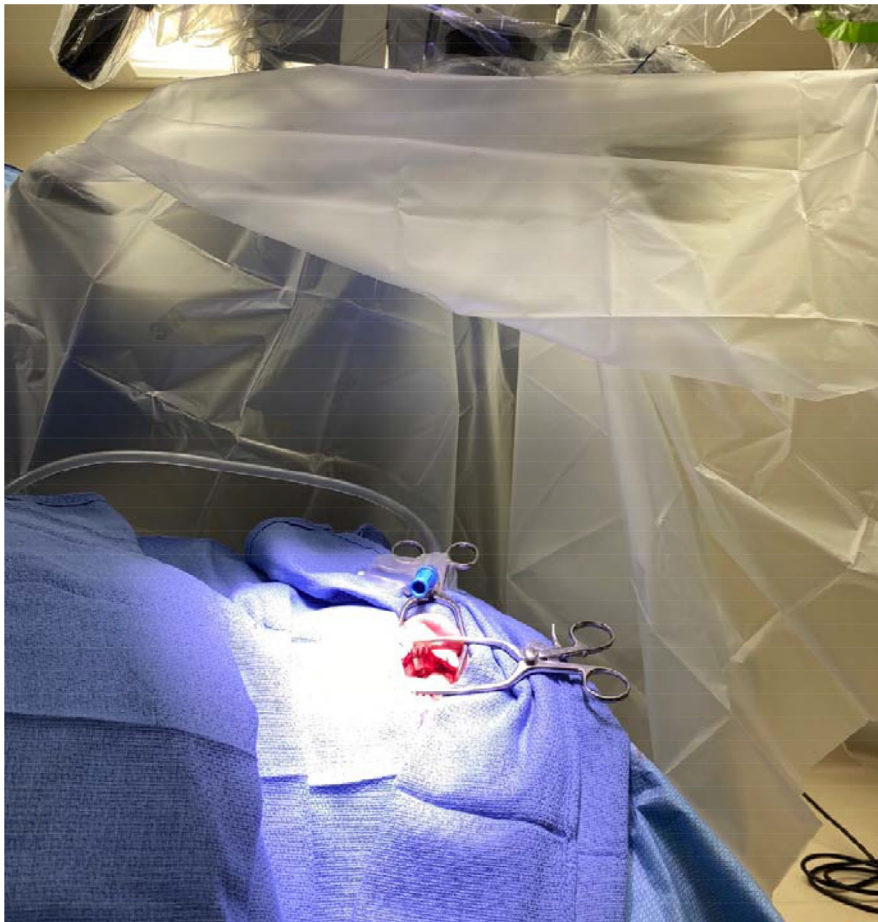

Figure 3 A view from underneath the 'OtoTent' demonstrates a second 'scavenger' suction positioned near the operative site to reduce particle dispersion during drilling.

aerosolization of viral particles with powered instruments combined with the limited ability of the surgeon to wear adequate PPE, investigators began to experiment with methods of particle mitigation during mastoidectomy.

Several studies have focused on the use of various surgical drapes to create a barrier between the operative site and the microscope.^{12–18} The basic principle involves using a sterile drape connected to the microscope to create a tent-like enclosed space over the operative site, aptly named OtoTents (Fig. 1).¹⁸

Chari et al. performed a head-to-head cadaveric study comparing a drape made from a 1060 Steri-Drape (3M) and a custom drape with arm ports they designed with Grace Medical.¹⁸ The 1060 drape is an opaque square shaped sterile drape with adhesive in the center that is most commonly utilized in Ophthalmology procedures.¹⁵ The 1060 drape OtoTent may allow for aerosol escape during arm movements because the surgeon's arms are placed under rather than through the drape (Fig. 1). In their study they had the least aerosolization with the custom drape (Fig. 2) with the addition of a second suction near the operative site (Fig. 3) and delayed removal of the drape after drilling to allow for settling of airborne particles.

In another cadaveric study, Chen et al. demonstrated that their modified 1060 drape OtoTent was inexpensive and quantitatively reduced particle dispersion beyond the boundaries of the drape.¹⁵ Their modification involved securing the drape posteriorly between the surgeon's arms with tape. They additionally suggest in the operating room, the drape may be secured circumferentially with staples and arm ports created by incising the drapes, although this was not tested in their experimental design.

Carron *et al.* reported they were able to fashion OtoTents out of clear drapes that were readily available at their institution.¹³ Utilizing a Steri-Drape 1015 (3M), the C-Armor (Tidi), or Sterile-Z Back Table Cover (Tidi) they found that larger transparent drapes make it easier for the surgical technician to safely pass instruments into the field (Figs. 4 and 5).

Cottrell *et al.* demonstrate an OtoTent fashioned from a Genesys C-Arm/Mobile X-Ray drape as well as a video tutorial for assembly: <https://doi.org/10.1186/s40463-020-00471-0>.¹⁶

Many variations of the OtoTent exist, but they are largely untested in the clinical setting. However, several points of observation can be made from the existing evidence. As the basic function is easy to approximate, for



Figure 4 Surgical technician passing instrument to surgeon through a transparent OtoTent fashioned from C-Armor drape (Tidi).

most providers the best drape material is probably the 1 that is readily available. Transparent drapes are advantageous over opaque drapes as they allow the surgeon and surgical technician better visualization of the field. Incorporating a Mayo stand within the drape with commonly used instruments limits manipulation of the drape. A second scavenger suction positioned near the operative site can mitigate particle dispersion. Adding povidone iodine to the irrigation solution is simple, inexpensive, theoretically virucidal, produces minimal discoloration, and has not been shown to be ototoxic.¹⁹ Placing the surgeon's arms through the drapes rather than under the drapes may limit escape of aerosols. Delaying removal of the drape after completion of drilling minimizes release of airborne particles. Although the risk of viral transmission during mastoidectomy remains unknown, these measures remain options for consideration when an abundance of caution is indicated.

Safety precautions for mastoidectomy - exoscope-assisted surgery

The exoscope is an extracorporeal digital telescope that provides 3-D visualization by viewing a special HD monitor with polarized lenses. This allows for a 2 handed surgical technique that is more ergonomically favorable than the traditional microscopic approach.²⁰ In the pandemic era, exoscopes are theoretically advantageous as they are compatible with OtoTent type draping but do not have significant limitations in the visual field when wearing PPE. The 3-D lenses can be modified to be applied to the outside surface of a face-shield or respirator so long as care is taken to maintain the correct polarity of the "front" and "back" of the lenses.^{17,21} Gordon et al. suggest adding a Leyla holding rod or anesthesia circuit holder tree opposite the exoscope and securing the drape tautly to it to create more space.²¹ The previously mentioned considerations for

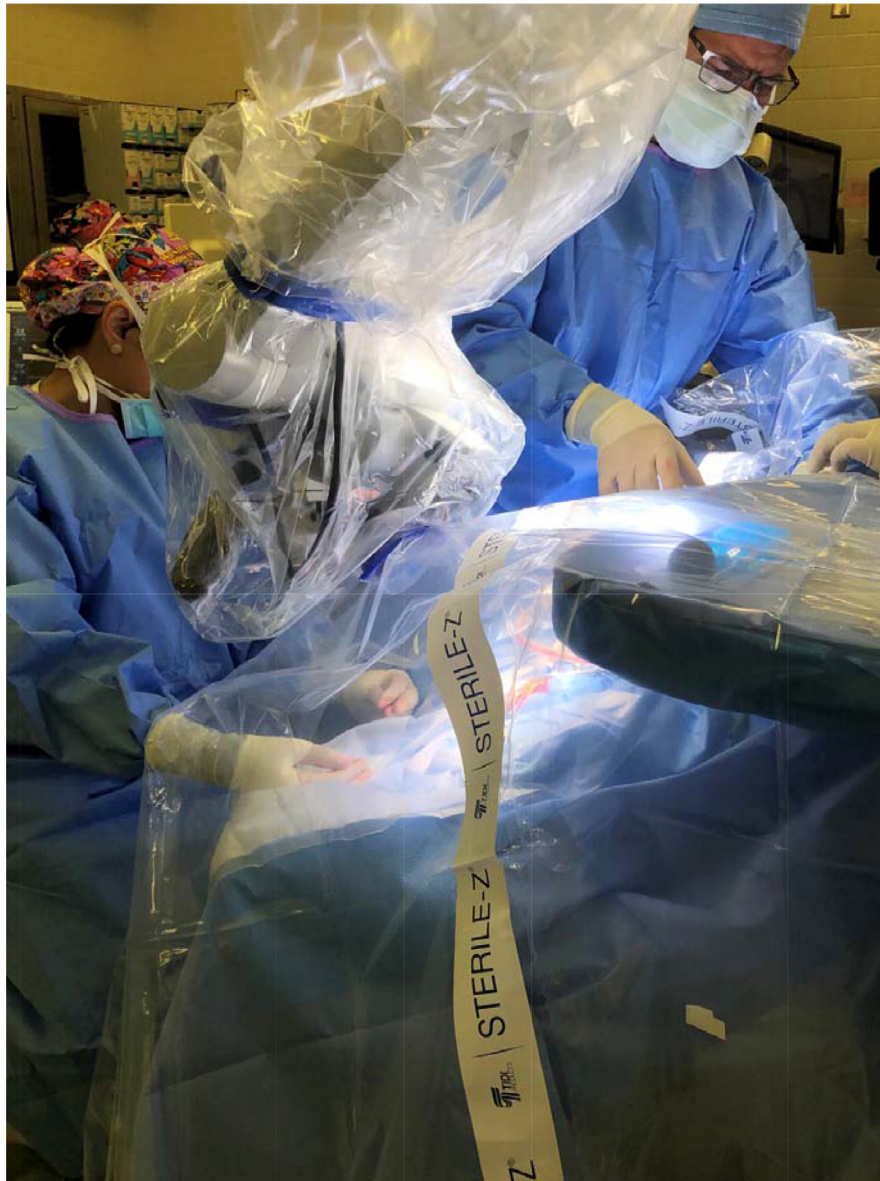


Figure 5 The Sterile-Z Back Table Cover (Tidi) is a cost effective option for fashioning a transparent OtoTent that additionally includes the Mayo stand.

microscopic mastoidectomy should also theoretically apply to exoscopic mastoidectomy.

Mitigation of particle spread – a case for endoscopic ear surgery

Another valid strategy to mitigate the risk of aerosolization during mastoidectomy is to minimize drilling via the trans-canal endoscopic approach when clinically appropriate. Like exoscopic surgery, endoscopic surgery is similarly ergonomically favorable.²⁰ A cadaveric study comparing droplet spread during endoscopic drill atticotomy, microscopic drill atticotomy, and cortical mastoidectomy demonstrated a significant 4.5-fold reduction in droplet generation between endoscopic and microscopic atticotomy and a 62-

fold reduction between endoscopic atticotomy and cortical mastoidectomy.²² No literature currently exists regarding the usage of drape barrier systems when using powered instruments in endoscopic ear surgery, however the basic ideas of adapting a containment system should theoretically apply.

Conclusion

It remains uncertain if COVID-19 is transmissible during otologic surgery in the same way it has been shown for endonasal surgery. Cadaveric studies suggest COVID-19 viral particles can be present within the middle ear mucosa. Certain otologic surgeries, mastoidectomy especially, are aerosol generating by nature. A variety of strategies have been proposed to enhance the safety of otologic

surgery during a pandemic. Guidelines exist to assist with triaging surgical cases and clinic visits. Various techniques have been proposed to minimize intraoperative dispersal of aerosolized viral particles, although they are largely untested in the clinical setting. Endoscopic and exoscopic surgery offer favorable ergonomics and do not limit the surgeon's ability to wear PPE. These innovations borne in times of extreme uncertainty will serve as the groundwork for the future of Otolaryngology as the COVID-19 pandemic continues to evolve, and we prepare for the pandemics of the future.

Disclosures

The authors report no proprietary or commercial interest in any product mentioned or concept discussed in this article.

Declaration of Competing Interest

None.

References

- van Doremalen N, Bushmaker T, Morris DH, et al: Aerosol and surface stability of SARS-CoV-2 as compared with SARS-CoV-1. *N Engl J Med* 382:1564–1567, 2020. doi:[10.1056/NEJMc2004973](https://doi.org/10.1056/NEJMc2004973).
- Kimura KS, Smetak MR, Freeman MH, et al: Undetectable viral load within the mastoid during cochlear implantation in a patient with COVID-19. *Otolaryngol Case Rep* 19:100273, 2021. doi:[10.1016/j.xocr.2021.100273](https://doi.org/10.1016/j.xocr.2021.100273).
- Wanna GB, Schwam ZG, Kaul VF, et al: COVID-19 sampling from the middle ear and mastoid: a case report. *Am J Otolaryngol* 41:102577, 2020. doi:[10.1016/j.amjoto.2020.102577](https://doi.org/10.1016/j.amjoto.2020.102577).
- Frazier KM, Hooper JE, Mostafa HH, et al: SARS-CoV-2 virus isolated from the mastoid and middle ear: Implications for COVID-19 precautions during ear surgery. *JAMA Otolaryngol Head Neck Surg* 146:964–966, 2020. doi:[10.1001/jamaoto.2020.1922](https://doi.org/10.1001/jamaoto.2020.1922).
- Jeican II, Aluș M, Lazăr M, et al: Evidence of sars-cov-2 virus in the middle ear of deceased covid-19 patients. *Diagnostics* 11:1–12, 2021. doi:[10.3390/diagnostics11091535](https://doi.org/10.3390/diagnostics11091535).
- Kurabi A, Pak K, DeConde AS, et al: Immunohistochemical and qPCR detection of SARS-CoV-2 in the human middle ear versus the nasal cavity: case series. *Head Neck Pathol* 1–5, 2021 Published online. doi:[10.1007/s12105-021-01378-6](https://doi.org/10.1007/s12105-021-01378-6).
- George M, Alexander A, Mathew J, et al: Proposal of a timing strategy for cholesteatoma surgery during the COVID-19 pandemic. *Eur Arch Otorhinolaryngol* 277:2619–2623, 2020. doi:[10.1007/s00405-020-06037-0](https://doi.org/10.1007/s00405-020-06037-0).
- Kozin ED, Remenschneider AK, Blevins NH, et al: American neurotology society, American otological society, and American academy of otolaryngology - Head and neck foundation guide to enhance otologic and neurotologic care during the COVID-19 pandemic. *Otol Neurotol Off Publ Am Otol Soc Am Neurotol Soc Eur Acad Otol Neurotol* 41:1163–1174, 2020. doi:[10.1097/MAO.0000000000002868](https://doi.org/10.1097/MAO.0000000000002868).
- Saadi RA, Bann D v, Patel VA, et al: A commentary on safety precautions for otologic surgery during the COVID-19 pandemic. *Otolaryngol Head Neck Surg (United States)* 162:797–799, 2020. doi:[10.1177/0194599820919741](https://doi.org/10.1177/0194599820919741).
- Workman AD, Welling DB, Carter BS, et al: Endonasal instrumentation and aerosolization risk in the era of COVID-19: simulation, literature review, and proposed mitigation strategies. *Int Forum Allergy Rhinol* 10:798–805, 2020. doi:[10.1002/alr.22577](https://doi.org/10.1002/alr.22577).
- Clamp PJ, Broomfield SJ: The challenge of performing mastoidectomy using the operating microscope with coronavirus disease 2019 personal protective equipment (PPE). *J Laryngol Otol* 134:739–743, 2020. doi:[10.1017/S0022215120001607](https://doi.org/10.1017/S0022215120001607).
- Das A, Mitra S, Kumar S, et al: Two-drape closed pocket technique: minimizing aerosolization in mastoid exploration during COVID-19 pandemic. *Eur Arch Otorhinolaryngol* 277:3529–3532, 2020. doi:[10.1007/s00405-020-06353-5](https://doi.org/10.1007/s00405-020-06353-5).
- Carron JD, Buck LS, Harbarger CF, et al: A simple technique for droplet control during mastoid surgery. *JAMA Otolaryngol Head Neck Surg* 146:671, 2020. doi:[10.1001/jamaoto.2020.1064](https://doi.org/10.1001/jamaoto.2020.1064).
- Favre N, McIntyre K, Kuo C, et al: Mitigation of particle spread during mastoidectomy: a systematic review. *Cureus* 13, 2021. doi:[10.7759/cureus.19040](https://doi.org/10.7759/cureus.19040).
- Chen JX, Workman AD, Chari DA, et al: Demonstration and mitigation of aerosol and particle dispersion during mastoidectomy relevant to the COVID-19 era. *Otol Neurotol Off Publ Am Otol Soc Am Neurotol Soc Eur Acad Otol Neurotol* 41:1230–1239, 2020. doi:[10.1097/MAO.0000000000002765](https://doi.org/10.1097/MAO.0000000000002765).
- Cottrell J, Lui J, Le T, et al: An operative barrier system for skull base and mastoid surgery: creating a safe operative theatre in the era of COVID-19. *J Otolaryngol Head Neck Surg* 49:1–4, 2020. doi:[10.1186/s40463-020-00471-0](https://doi.org/10.1186/s40463-020-00471-0).
- Tu N, Bojrab D, Sioshansi P, et al: Exoscope-assisted otologic surgery during the COVID-19 pandemic. *Otol Neurotol Off Publ Am Otol Soc Am Neurotol Soc Eur Acad Otol Neurotol* 42:e378–e379, 2021. doi:[10.1097/MAO.0000000000002916](https://doi.org/10.1097/MAO.0000000000002916).
- Chari DA, Workman AD, Chen JX, et al: Aerosol dispersion during mastoidectomy and custom mitigation strategies for otologic surgery in the COVID-19 Era. *Otolaryngol Head Neck Surg (United States)* 164:67–73, 2021. doi:[10.1177/0194599820941835](https://doi.org/10.1177/0194599820941835).
- Khan MM, Parab SR: 0.5% povidone iodine irrigation in otorhinolaryngology surgical practice during COVID 19 pandemic. *Am J Otolaryngol Head Neck Med Surg* 41:337–339, 2020. doi:[10.1016/j.amjoto.2020.102687](https://doi.org/10.1016/j.amjoto.2020.102687).
- Ridge SE, Shetty KR, Lee DJ: Heads-up surgery: endoscopes and exoscopes for otology and neurotology in the era of the COVID-19 pandemic. *Otolaryngol Clin N Am* 54:11–23, 2021. doi:[10.1016/j.otc.2020.09.024](https://doi.org/10.1016/j.otc.2020.09.024).
- Gordon SA, Deep NL, Jethanamest D: Exoscope and personal protective equipment use for otologic surgery in the era of COVID-19. *Otolaryngol Head Neck Surg (United States)* 163:179–181, 2020. doi:[10.1177/0194599820928975](https://doi.org/10.1177/0194599820928975).
- Anschuetz L, Yacoub A, Buetzer T, et al: Quantification and comparison of droplet formation during endoscopic and microscopic ear surgery: a cadaveric model. *Otolaryngol Head Neck Surg (United States)* 164:1208–1213, 2021. doi:[10.1177/0194599820970506](https://doi.org/10.1177/0194599820970506).