

Safety and efficacy of spinal loop rectangle and sublaminar wires for osteoporotic vertebral compression fracture fixation

Sanganagouda Shivanagouda Patil, Shekhar Yashwant Bhojaraj, Abhay Madhusudan Nene

Department of Spine Surgery, Wockhardt Hospital and Medical Research Centre, Mumbai, Maharashtra, India

ABSTRACT

Background: Natural history of osteoporotic vertebral compression fractures (OVCFs), that is, collapse, loads the rigid pedicle screw rod construct in the absence of anterior column reconstruction, often leading to implant back outs. Semi rigid spinal loop rectangle and sublaminar wire construct allows controlled axial collapse and does not require anterior column reconstruction.

Materials and Methods: This is a retrospective study of 50 consecutive patients of OVCFs. The immediate and final follow-up safety (neurologic deficit, implant failure/back out, revision surgeries, and infection) and efficacy (visual analog scale [VAS] score, axial collapse of the fracture, fracture union and retaining, and the attempted segmental deformity correction) parameters were compared to describe the utility of spinal loop rectangle and sublaminar wiring as a novel, low cost modality of spinal instrumentation for treating OVCFs.

Results: All the twelve patients with Frankel grade D neurologic deficit improved to Frankel grade E and six patients (out of 8) with Frankel grade C improved to Frankel grade E (and remaining two patients improved to Frankel grade D), following surgery. The average preoperative VAS score of 8.98 (ranging from 5 to 10) improved to 2.76 (ranging from 1 to 10) at final follow-up. Controlled collapse of anterior column, union of OVCF nonunion, and retaining of attempted deformity correction by sublaminar wire anchors cephalad and caudal to the transpedicular decompression was seen in each patient at the final follow-up.

Conclusion: Spinal loop rectangle and sublaminar wiring construct are viable alternative options for stabilizing OVCFs.

Key words: Osteoporotic vertebral compression fractures, spinal loop rectangle and sublaminar wiring, stabilization

Introduction

The use of pedicle screws is the most popular spinal instrumentation method today.^[1,2] In an osteoporotic spine, pedicle screws are at a greater risk of pull out due to poor hold at the bone-screw interface. A weak and rarified trabeculae in the cancellous bone within the vertebral body,

as well as pedicles, offer little resistance against screw pull out.^[3-5] The pedicle screw rod being most rigid among existing constructs are at a risk of failure leading to implant back out due to anterior column collapse which appears to be the natural history with osteoporotic vertebral compression fractures(OVCFs). This is, especially true in the absence of anterior column reconstruction.^[6,7] In contrast, a semi rigid, extra-cortical fracture stabilization by spinal loop rectangle and sublaminar wiring (SLW) is not only strong enough to hold the spine in normal alignment but also allows controlled axial, anterior column collapse to happen.^[8] The newer techniques of augmented pedicle screw fixation require longer learning

This is an open access article distributed under the terms of the Creative Commons Attribution-NonCommercial-ShareAlike 3.0 License, which allows others to remix, tweak, and build upon the work non-commercially, as long as the author is credited and the new creations are licensed under the identical terms.

For reprints contact: reprints@medknow.com

Access this article online	
<p>Quick Response Code:</p> 	<p>Website: www.asianjns.org</p>
	<p>DOI: 10.4103/1793-5482.175648</p>

Address for correspondence:

Dr. Sanganagouda Shivanagouda Patil, Department of Spine Surgery, Wockhardt Hospital and Medical Research Centre, Dr. Anand Rao Nair Road, Agripada, Mumbai Central, Mumbai - 400 008, Maharashtra, India.
E-mail: sanganpatil9@gmail.com

How to cite this article: Patil SS, Bhojaraj SY, Nene AM. Safety and efficacy of spinal loop rectangle and sublaminar wires for osteoporotic vertebral compression fracture fixation. Asian J Neurosurg 2017;12:436-40.

curves, involve additional costs to the patients, and are not without complications. In this novel study, authors have described the safety and efficacy of low cost spinal loop rectangle and SLW as a modality of spinal instrumentation for treating OVCFs.

Materials and Methods

This is a retrospective study of 50 consecutive patients of OVCF (from January 2009 to December 2013). All these patients had fractures due to trivial trauma as etiology. As a protocol, each patient with OVCF was investigated routinely on standing roentgen graph, computed tomography (CT) scan, and magnetic resonance imaging (MRI) scan. The patients with severe spinal pain due to failed conservative treatment (consisting of rest or limited activity till pain got better, mild analgesics, calcitonin nasal sprays, and calcium with Vitamin D3 supplements for a duration from 1 to 3 months) for OVCFs were included in the study. Those patients presenting with impending and/or proven neurological deficits (Frankel grade D and more) were also included in the study as they underwent emergent surgery. The patients with fractures due to secondary causes of osteoporosis such as multiple myeloma and metastatic tumors were excluded from the study.

The patients with persistent pain and dysfunction (i.e., at 4–6 weeks, equal to or more than that in the immediate postinjury condition) were further investigated and standing dynamic X-rays were done to know the fracture morphology and extent of deformity. Repeat CT and MRI scans were done to know the fracture morphology, as well as the extent of the spinal cord compression, in patients with neurologic deficits. There was no “control” group, as all patients with above inclusion criteria underwent the same surgery. In this study, the following parameters were considered, at final follow-up to assess the safety and efficacy of the use of spinal loop rectangle and SLW as a modality of spinal instrumentation in OVCFs.

Safety parameters

- Neurologic deficit
- Implant failure/back out
- Revision surgeries
- Infection.

Efficacy parameters

The pain score of each patient before surgery and at final follow-up was measured using a visual analog scale (VAS) score. During each follow-up, controlled axial collapse of the fracture, fracture union, and retaining the attempted segmental deformity correction that is, maintaining the segmental sagittal and coronal spinal alignment by loop rectangle and SLW were assessed.

There were 21 males and 29 females and the average age was 73.22 years (48–83 years). The average follow-up period was 55.46 months (26–106 months). In this study,

46 patients had fracture at thoracolumbar (TL) junction and two patients had fracture at lumbar (L) and thoracic (T) spine each. Of these, 20 patients were presented with epidural cord compression (Frankel grade C-08 and Frankel grade D-12) with neurologic deficit and 30 patients had severe spinal pain due to instability. All the patients in this series underwent transpedicular decompression (TPD) and spinal stabilization using locally available spinal loop rectangle and SLW.

All the patients were treated by the same team and regular 3 months follow-up was done in the 1st year and then yearly. Patients’ demographic and radiologic data were obtained from hospital records retrospectively and subsequently during follow-ups.

Surgical procedure

Midline skin incision extending three to four levels cephalad and three levels caudal to the fractured vertebra was considered as optimum for stabilization of TL OVCFs, using spinal loop rectangle and SLW. After midline exposure, paraspinous muscles were elevated and retracted bilaterally from spinous processes, laminae; pars interarticularis up to the tip of transverse processes. This not only helped in the wide exposure of interlaminar area for wiring but also assisted in preparing a good fusion bed for bone grafting.

Sublaminar wiring technique

Supra/inter spinous ligament and ligamentum flavum were excised, and a sublaminar space was created at each level for passing wires. After exposing the sublaminar spaces, a double loop of 20 gauge “cold cured stainless steel wires” were inserted around the laminae of to be instrumented cephalad and caudal vertebral levels by insertion, advancement, roll through, and pull through technique. The measured size loop rectangle is then adequately contoured for sagittal balance. The wires are passed through the loop rectangle with cephalad wire always ending inside it, and caudal wire outside the loop rectangle at all levels, except for the terminal ones where the caudal wires end inside the loop rectangle, thus preventing the cephalad or caudal slippage of the loop rectangle. These wires were sequentially tightened clockwise starting at the ends of loop rectangle followed by inner wires. Tightening the wires in phases until final torque is reached, helps to correct the kyphotic deformity onto the contoured spinal loop rectangle. After final tightening, the extra length of wire is cut and buried on itself over the lamina. Finally, good graft bed preparation is done for posterior fusion.

Transpedicular decompression

This is defined as anterior decompression of the spinal cord via pedicles of a posterior approach. For single level, bilateral TPD, wide laminectomies of the adjacent superior and inferior laminae were done [Figure 1]. The superior facet was excised until the pedicle was exposed circumferentially. Shoulder of

the nerve root just inferior to the pedicle was identified and secured inferiorly by placing cotton pledgets between it and the pedicle. The bone marrow within the exposed pedicle was scraped out using bone curette. This was continued till one reached middle column/front of the cord [Figure 2a and b]. Finally, the medial pedicle wall was excised using Kerrison rongeur so as to get an access to the retropulsed fractured middle column bone fragments compressing on the cord, which were then decompressed too [Figure 3a-e].

Results

Following were the results of safety and efficacy parameters of TPD and spinal loop rectangle and SLW for OVCFs at the final follow-up.

Safety parameter results

- Neurologic deficit: Twenty patients had a significant neurologic deficit (Frankel grade C-08 and Frankel grade D-12) due to epidural cord compression by retropulsed middle column bone fragments. All patients with Frankel grade D improved completely following an emergency surgery. Six patients with Frankel grade C improved completely and two patients improved partially (to Frankel grade D). Two patients had persistent paraesthesias (in the perineal area and lower limbs) until the last follow-up
- Implant failure/back outs: Wire breakage and implant backout were seen in seven patients at the final follow-up. In all the patients, wire breakage occurred at a single level at the cephalad end, with the prominence of the superior end of spinal loop rectangle with $< 10^\circ$ kyphosis at the proximal junction. All these patients were clinically asymptomatic. These were the patients who continued smoking and did not continue regular antiosteoporotic treatment
- Revision surgeries: None of these patients required a revision surgery

- Infection: Four patients had deep wound infection which required wound debridement and finally they were healed by secondary intention.

Efficacy parameter results

The average preoperative VAS score of 8.98 (ranging from 5 to 10) improved to 2.76 (ranging from 1 to 10) at the final follow-up. Spinal loop rectangle and SLW by virtue of its semi rigid nature and stronger extra cortical hold over laminae allowed the controlled collapse of anterior column (in the absence of anterior column reconstruction) in each patient. In all these patients, OVCF nonunions healed in collapsed position with SLW anchors cephalad and caudal to the TPD retaining the attempted deformity correction at the final follow-up. Although single level wire breakage was seen in seven patients at the cephalad terminal, none was clinically symptomatic.

The average duration of surgery was 203.22 min (ranging from 120 to 230 min). Average blood loss was 741ml (ranging from 150 to 2000 ml).

Complications

There were two deaths in the postoperative period due to medical complications. Four patients with superficial surgical site infection were healed with broad spectrum antibiotic treatment. Wire breakage at the cephalad end of fixation in seven patients was clinically asymptomatic.

Discussion

With the resurgence of third generation spinal implants, the utility of spinal loop rectangle and SLW was considered obsolete.^[9] The pedicle screws offer the strongest stabilization and better three-dimensional correction while treating degenerative spine and spinal deformity disorders.^[10] The use of pedicle screw rod construct becomes a mandatory, especially when interbody fusion is planned in these disorders.

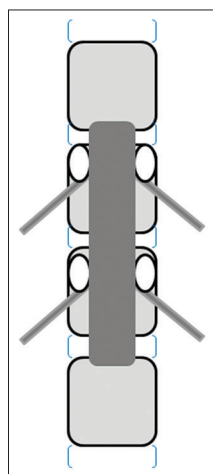


Figure 1: Adjacent two level laminectomy for single level transpedicular decompression

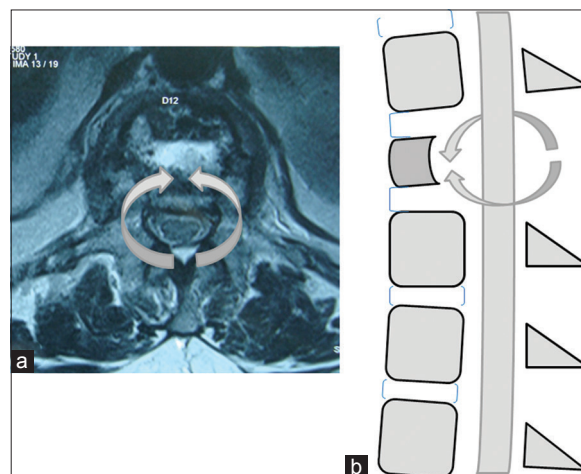


Figure 2: Axial view (a) and sagittal view (b) of transpedicular route to the compressive bone fragments in the fractured middle column

Considering the age in whom the OVCFs predominantly occur, anterior approach surgeries are not the preferred one, due to the morbidity and mortality associated with it.^[11-16] As shown in this study and many others, TPD is a posterior approach surgery to decompress all the three columns of thoracic and lumbar spine. This is, especially true when the fractured middle/anterior column fragments are compressing the cord.^[17] Compared to the anterior transcravitory approach surgeries, TPD has following advantages:

- Posterior spinal approach more familiar and less morbid in elderly patients
- TPD addresses the spinal cord compression globally i.e., by freeing the compression anterior as well as posterior to the spinal cord
- This procedure allows the use of stronger cortical bony anchor points for SLW at multiple levels
- TPD allows up to 20–25° of kyphosis correction segmentally^[18]
- TPD permits bony reconstitution and fusion to occur anteriorly as the anterior column is left relatively intact.

The spinal loop rectangle and SLW is a semirigid construct with “cold-cured” dual wires anchored to cortices of both laminae and tightened on to the contoured stainless steel dual rods. In an osteoporotic spine, the cortices of the laminae are much stronger compared to marrow within pedicles as well as vertebral body.^[19] Biomechanically, spinal loop rectangle and SLW construct only offers sagittal plane stability (by contoured dual rods) and rotational and/or translational stability (by cold cured dual SLWs, anchored on to the cortices of both laminae, and tightened on to dual rods). Being semirigid and poor

in axial stability, this construct allows vertebral collapse to happen (in the absence of anterior column reconstruction).^[20,21] This weakness in the construct is utilized to the surgeons advantage by converting antero-inferior dislodgement forces acting at the site of fracture into the forces of fracture union by controlled collapse, as shown in this study [Figure 4a-c].

Locally made spinal loop rectangle and cold cured SLW is approximately, one tenth of the price compared to imported third generation titanium implants (i.e., pedicle screws and rods). The instrumentation procedure is easy to learn, user friendly, and safer technique. This requires lesser inventory, making it suitable for wider social applicability more so in developing countries as shown in this study.

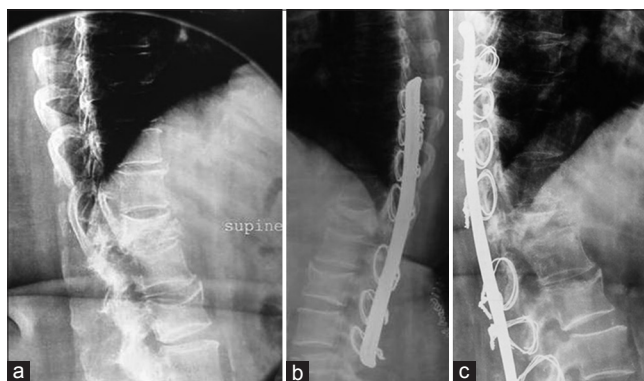

Figure 4: A 72-year-old female patient with osteoporotic vertebral compression fracture nonunion of the T12 vertebral body (a), immediate postoperative lateral view X-ray shows fracture stabilization with spinal loop rectangle and sublaminar wirings (b), postoperative follow-up X-ray at 2 years shows fracture healing by collapse with implants *in situ* (c)

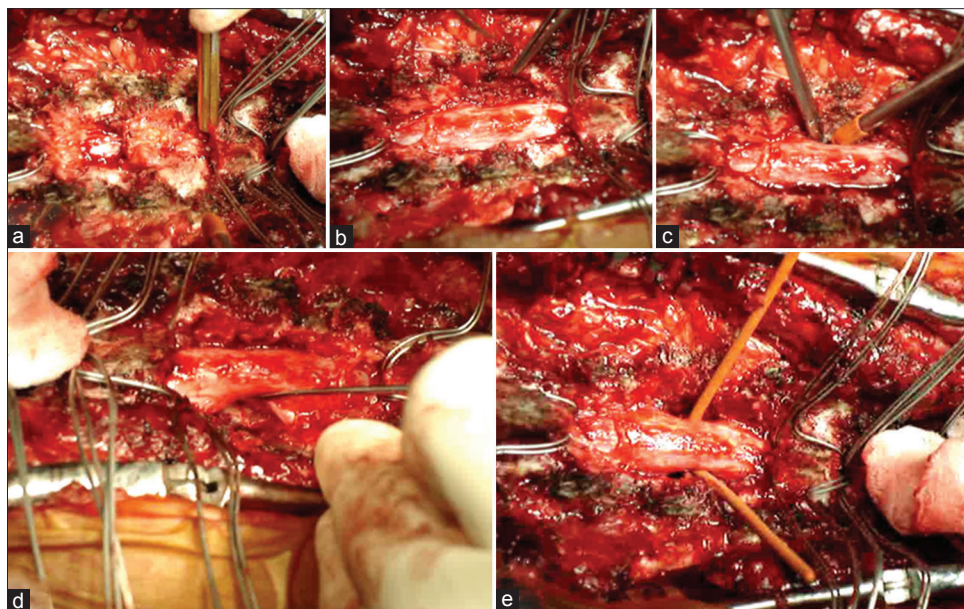


Figure 3: Sublaminar wires *in situ* and start of the laminectomy (a), two level wide laminectomy (b), ipsilateral transpedicular decompression (c), contra lateral transpedicular decompression (d), decompressed spinal cord after middle column bone fragments compressing on to the spinal cord were removed (e)

The wound complications related to the longer surgical exposure for extra bony anchor points in the spinal loop rectangle and SLW instrumentations is debatable and less relevant in the patients of OVCFs, as shown in this study.

Conclusion

Spinal loop rectangle and SLW construct relies on the lamina for its hold, which is the strongest part of the osteoporotic vertebra. The natural history of an OVCF healing (i.e., collapse) and semi rigid nature of this construct which allows controlled axial collapse to happen, both work in the favor of patient and surgeon's benefit. The easy learning curve, user friendly and safe implantation technique, makes this a viable alternative option while stabilizing OVCFs.

Financial support and sponsorship

Nil.

Conflicts of interest

There are no conflicts of interest.

References

- Hirabayashi S, Kumano K, Kuroki T. Cotrel-Dubousset pedicle screw system for various spinal disorders. Merits and problems. *Spine (Phila Pa 1976)* 1991;16:1298-304.
- Yuan HA, Garfin SR, Dickman CA, Mardjetko SM. A historical cohort study of pedicle screw fixation in thoracic, lumbar, and sacral spinal fusions. *Spine (Phila Pa 1976)* 1994;19 20 Suppl: 2279S-96S.
- Halvorson TL, Kelley LA, Thomas KA, Whitecloud TS 3rd, Cook SD. Effects of bone mineral density on pedicle screw fixation. *Spine (Phila Pa 1976)* 1994;19:2415-20.
- Kumano K, Hirabayashi S, Ogawa Y, Aota Y. Pedicle screws and bone mineral density. *Spine (Phila Pa 1976)* 1994;19:1157-61.
- Soshi S, Shiba R, Kondo H, Murota K. An experimental study on transpedicular screw fixation in relation to osteoporosis of the lumbar spine. *Spine (Phila Pa 1976)* 1991;16:1335-41.
- Glassman SD, Alegre GM. Adult spinal deformity in the osteoporotic spine: Options and pitfalls. *Instr Course Lect* 2003;52:579-88.
- Patil S, Nene AM. Predictors of kyphotic deformity in osteoporotic vertebral compression fractures: A radiological study. *Eur Spine J* 2014;23:2737-42.
- Cresswell TR, Marshall PD, Smith RB. Mechanical stability of the AO internal spinal fixation system compared with that of the Hartshill rectangle and sublaminar wiring in the management of unstable burst fractures of the thoracic and lumbar spine. *Spine (Phila Pa 1976)* 1998;23:111-5.
- Wilber RG, Thompson GH, Shaffer JW, Brown RH, Nash CL Jr. Postoperative neurological deficits in segmental spinal instrumentation. A study using spinal cord monitoring. *J Bone Joint Surg Am* 1984;66:1178-87.
- Moore DC, Maitra RS, Farjo LA, Graziano GP, Goldstein SA. Restoration of pedicle screw fixation with an *in situ* setting calcium phosphate cement. *Spine (Phila Pa 1976)* 1997;22:1696-705.
- Chang KW, Chen YY, Lin CC, Hsu HL, Pai KC. Apical lordosating osteotomy and minimal segment fixation for the treatment of thoracic or thoracolumbar osteoporotic kyphosis. *Spine (Phila Pa 1976)* 2005;30:1674-81.
- Faciszewski T, Winter RB, Lonstein JE, Denis F, Johnson L. The surgical and medical perioperative complications of anterior spinal fusion surgery in the thoracic and lumbar spine in adults. A review of 1223 procedures. *Spine (Phila Pa 1976)* 1995;20:1592-9.
- Hodge WA, DeWald RL. Splenic injury complicating the anterior thoracoabdominal surgical approach for scoliosis. A report of two cases. *J Bone Joint Surg Am* 1983;65:396-7.
- McAfee PC. Complications of anterior approaches to the thoracolumbar spine. Emphasis on Kaneda instrumentation. *Clin Orthop Relat Res* 1994;306:110-9.
- Nakai S, Zielke K. Chylothorax – A rare complication after anterior and posterior spinal correction. Report on six cases. *Spine (Phila Pa 1976)* 1986;11:830-3.
- Weis JC, Betz RR, Clements DH 3rd, Balsara RK. Prevalence of perioperative complications after anterior spinal fusion for patients with idiopathic scoliosis. *J Spinal Disord* 1997;10:371-5.
- Suk SI, Kim JH, Lee SM, Chung ER, Lee JH. Anterior-posterior surgery versus posterior closing wedge osteotomy in posttraumatic kyphosis with neurologic compromised osteoporotic fracture. *Spine (Phila Pa 1976)* 2003;28:2170-5.
- Patil S, Rawall S, Singh D, Mohan K, Nagad P, Shial B, *et al.* Surgical patterns in osteoporotic vertebral compression fractures. *Eur Spine J* 2013;22:883-91.
- Coe JD, Warden KE, Herzig MA, McAfee PC. Influence of bone mineral density on the fixation of thoracolumbar implants. A comparative study of transpedicular screws, laminar hooks, and spinous process wires. *Spine (Phila Pa 1976)* 1990;15:902-7.
- Mohan AL, Das K. History of surgery for the correction of spinal deformity. *Neurosurg Focus* 2003;14:e1.
- Luque ER. Interpeduncular segmental fixation. *Clin Orthop Relat Res* 1986;203:54-7.