

# Optimizing Inflammatory Bowel Disease for Successful In Vitro Fertilization

Jason J. Pan, MD<sup>1</sup>, Mora Cannon, RN<sup>2</sup>, Edward Kane Jr, MD<sup>3</sup>, and Gauree Konijeti, MD, MPH<sup>2,4</sup>

<sup>1</sup>Department of Internal Medicine, Scripps Green Hospital, La Jolla, CA

<sup>2</sup>Division of Gastroenterology, Scripps Clinic, La Jolla, CA

<sup>3</sup>Division of Pathology, Scripps Clinic, La Jolla, CA

<sup>4</sup>Scripps Translational Science Institute, La Jolla, CA

## ABSTRACT

We present a nulliparous woman with mild to moderate ulcerative colitis (UC) and multiple failed cycles of in vitro fertilization (IVF) in whom we achieved a successful, viable pregnancy following clinical and endoscopic UC remission. Infertile patients with inflammatory bowel disease who have failed multiple cycles of IVF should try to achieve clinical remission and mucosal healing (absence of erosions or ulcers) prior to reattempting conception. Furthermore, deficiencies in vitamin B12, vitamin D, and iron should be addressed.

## INTRODUCTION

The inflammatory bowel disease (IBD) patient population has fertility rates similar to the general population, although patients who have undergone surgery or have active disease may have decreased fertility.<sup>1-6</sup> Surgery, especially proctocolectomy followed by ileal pouch anal anastomosis, can cause scarring and adhesions that cause blockage of the fallopian tubes.<sup>7</sup> More recent studies have shown that a laparoscopic approach may improve infertility rates.<sup>8-9</sup> Limited data also suggest that active disease, particularly Crohn's disease, can contribute to infertility.<sup>1,3,10</sup> Active disease may cause inflammation in the fallopian tubes or ovaries, dyspareunia, decreased libido, depression, or decreased ovarian reserve.<sup>10-12</sup>

For IBD patients with infertility, in vitro fertilization (IVF) is a common, safe, albeit expensive solution. IVF is as successful for women with IBD as the general IVF population in terms of cumulative live birth rate, pregnancy rate after one IVF cycle, and incidence of live birth after first cycle.<sup>13</sup> IVF has been found to be successful in women with ulcerative colitis (UC) regardless of whether they had prior surgery.<sup>14</sup> Factors predicting successful IVF in IBD appear to be younger age (<35 years old) and lower body mass index, but no data are available to guide optimizing success of IVF for women with IBD who are unable to achieve pregnancy through IVF.<sup>15</sup>

## CASE REPORT

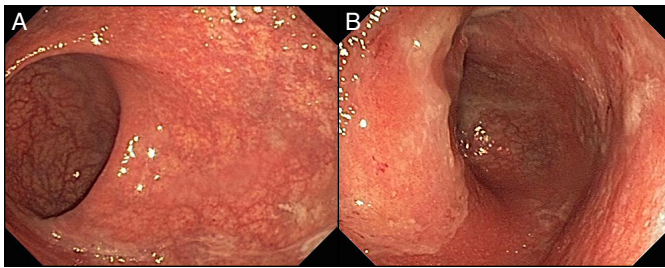
A 34-year-old nulliparous woman with a 12-year history of UC proctosigmoiditis who had undergone four IVF cycles unsuccessfully was referred to gastroenterology. She and her husband had an unremarkable infertility work-up. Of the four IVF cycles, two led to chemical pregnancies based on early rise in serum human chorionic gonadotropin (hCG) with spontaneous abortions around week 5. Her regimen initially consisted of intermittent mesalamine suppositories as needed for symptoms. She reported 6 formed bowel movements with mucus daily, most with small amounts of bright red blood, but otherwise no symptoms. She reported no tobacco or alcohol use. Vital signs were normal (body mass index 21 kg/m<sup>2</sup>), and physical examination was unremarkable. Labs revealed C-reactive protein <3 mg/L and erythrocyte sedimentation rate 10 mm/hr, as well as normal comprehensive metabolic panel, thyroid-

ACG Case Rep J 2016;3(4):e199. doi:10.14309/crj.2016.172. Published online: December 21, 2016.

Correspondence: Jason J. Pan, 10666 North Torrey Pines Rd, #403C, La Jolla, CA 92037 (Pan.Jason@scrippshealth.org).



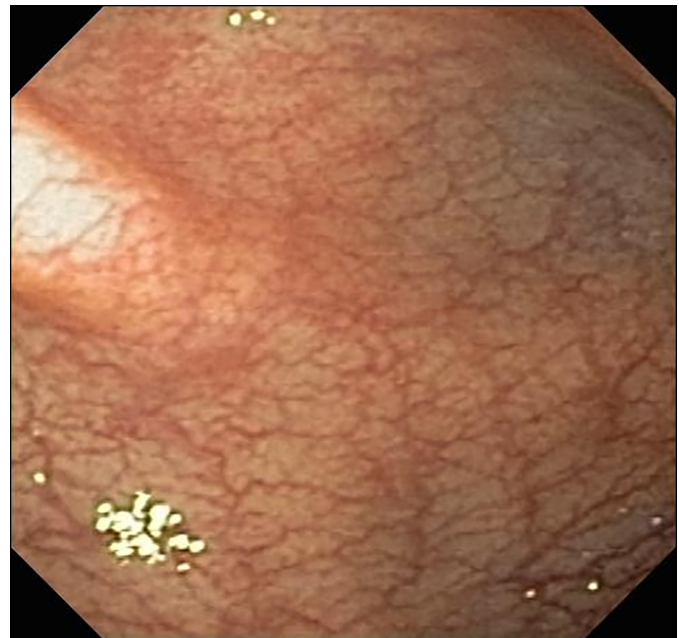
Copyright: © 2016 Pan et al. This work is licensed under a Creative Commons Attribution-NonCommercial-NoDerivatives 4.0 International License. To view a copy of this license, visit <http://creativecommons.org/licenses/by-nc-nd/4.0>.



**Figure 1.** Initial colonoscopy of (A) rectum and (B) sigmoid revealed moderate colitis with circumferential continuous erythema, friability, and punctate erosions.

stimulating hormone, 25-hydroxy vitamin D, vitamin B12, and folate. Although complete blood count was normal, she had significant iron deficiency (iron 50 mg/dL, transferrin 384 mg/dL, saturation 10%, ferritin 7.1 ng/mL). Celiac testing, stool culture, ova/parasites, *Clostridium difficile* polymerase chain reaction, and *Giardia* antigen were negative. Colonoscopy revealed continuous colitis with erythema, friability, and punctate erosions (Mayo endoscopy subscore 2) from rectum to 25 cm (Figure 1). She began oral mesalamine 4.8 g daily and mesalamine enemas nightly with clinical remission (1-3 bowel movements without blood) within 8 weeks. Intravenous iron resulted in normalization of her iron indices.

Repeat flexible sigmoidoscopy 2 months later revealed only mild erythema in the rectosigmoid region, and biopsies demonstrated inactive colitis (Figure 2). Within 2-3 weeks of the sigmoidoscopy, the patient underwent another cycle of IVF. She did not achieve a viable pregnancy, but the beta hCG (bHCG) response was “significantly higher” than prior attempts. Before additional IVF attempts, we waited 6 months to ensure sustained clinical and endoscopic remission. She remained in clinical remission on the same doses of oral and topical mesalamine, and flexible sigmoidoscopy 6 months after the last confirmed minimal rectosigmoid erythema with inactive colitis on histology (Figure 3). A subsequent IVF trial

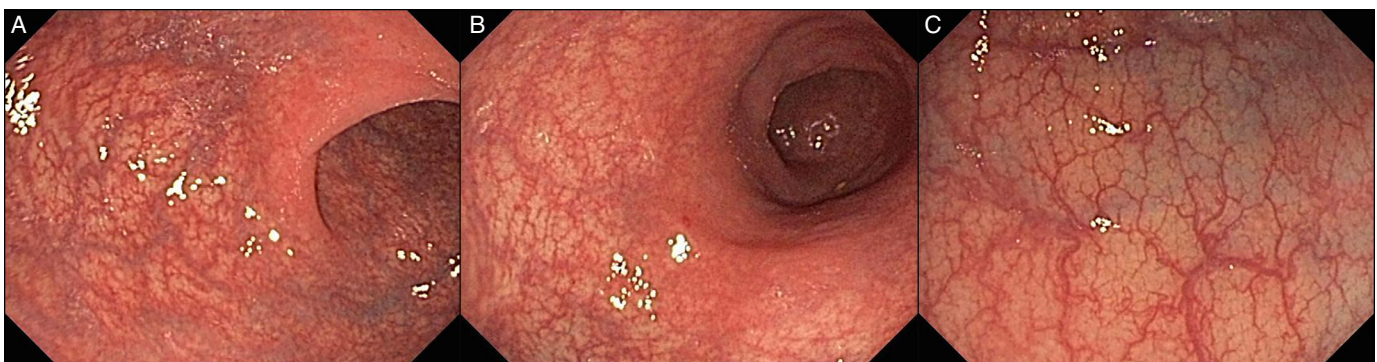

**Figure 3.** Eight-month follow-up flexible sigmoidoscopy of the rectum shows minimal erythema and mild friability from 0 to 20 cm. Otherwise, normal mucosa proximal to the rectum and up to the splenic flexure.

resulted in a viable pregnancy with dichorionic twin girls, and she recently delivered two healthy baby girls at 36 weeks and 6 days.

## DISCUSSION

This case suggests that disease activity, even mild to moderate, can reduce the success of IVF, as our patient had 4 unsuccessful IVF trials in the setting of active UC. This case also corroborates expert considerations that conception may be best attempted after 6 months of remission, primarily advised to minimize the risk of active disease during pregnancy.<sup>12,16</sup> Our patient’s unsuccessful fifth cycle of IVF was administered 2 months after starting topical and oral therapy for UC, but the increased bHCG response could be suggestive of an improved response, as increased bHCG levels are



**Figure 2.** Two-month follow-up flexible sigmoidoscopy of the (A) rectum showing only mild erythema and mild friability up to 25 cm. Otherwise, the (B) sigmoid colon and (C) descending colon were normal to the splenic flexure.

typically associated with increased likelihood of a viable gestation.<sup>17</sup> Vitamin B12, vitamin D, and iron labs should be checked and corrected to help ensure a healthy pregnancy and fetal development, especially as women with IBD often have low levels.<sup>12</sup> Therefore, in addition to the standard infertility work-up, an infertile IBD patient should be optimized prior to IVF by having her active disease addressed and any vitamin deficiencies corrected, with an appropriate period of remission.

## DISCLOSURES

Author contributions: M. Cannon, E. Kane Jr, and G. Konijeti gathered data, and JJ Pan and G. Konijeti analyzed and interpreted the data. JJ Pan drafted the manuscript, and JJ Pan and G. Konijeti revised the draft. E. Kane Jr and G. Konijeti provided technical or material support. G. Konijeti is the article guarantor.

Financial disclosure: None to report.

Informed consent was obtained for this case report.

Received March 29, 2016; Accepted June 9, 2016

## REFERENCES

1. Mayberry JF, Weterman IT. European survey of fertility and pregnancy in women with Crohn's disease: A case control study by European collaborative group. *Gut*. 1986;27(7):821-5.
2. Tavernier N, Fumery M, Peyrin-Biroulet L, et al. Systematic review: Fertility in non-surgically treated inflammatory bowel disease. *Aliment Pharmacol Ther*. 2013;38(8):847-53.
3. Hudson M, Flett G, Sinclair TS, et al. Fertility and pregnancy in inflammatory bowel disease. *Int J Gynaecol Obstet*. 1997;58(2):229-37.
4. Ørding Olsen K, Juul S, Berndtsson I, et al. Ulcerative colitis: Female fecundity before diagnosis, during disease, and after surgery compared with a population sample. *Gastroenterology*. 2002;122(1):15-9.
5. Wikland M, Jansson I, Asztély M, et al. Gynaecological problems related to anatomical changes after conventional proctocolectomy and ileostomy. *Int J Colorectal Dis*. 1990;5(1):49-52.
6. Tulchinsky H, Averboukh F, Horowitz N, et al. Restorative proctocolectomy impairs fertility and pregnancy outcomes in women with ulcerative colitis. *Colorectal Dis*. 2013;15(7):842-7.
7. Öresland T, Palmablad S, Ellström M, et al. Gynaecological and sexual function related to anatomical changes in the female pelvis after restorative proctocolectomy. *Int J Colorectal Dis*. 1994;9(2):77-81.
8. Bartels SA, D'Hoore A, Cuesta MA, et al. Significantly increased pregnancy rates after laparoscopic restorative proctocolectomy: A cross-sectional study. *Ann Surg*. 2012;256(6):1045-8.
9. Beyer-Berjot L, Maggiori L, Birnbaum D, et al. A total laparoscopic approach reduces the infertility rate after ileal pouch-anal anastomosis: A 2-center study. *Ann Surg*. 2013;258(2):275-82.
10. Van Assche G, Dignass A, Reinisch W, et al. The second European evidence-based consensus on the diagnosis and management of Crohn's disease: Special situations. *J Crohns Colitis*. 2010;4(1):63-101.
11. Arkuran C, McComb P. Crohn's disease and tubal infertility: The effect of adhesion formation. *Clin Exp Obstet Gynecol*. 2000;27(1):12-3.
12. Mahadevan U, Matro R. Care of the pregnant patient with inflammatory bowel disease. *Obstet Gynecol*. 2015;126(2):401-12.
13. Oza SS, Pabby V, Dodge LE, et al. In vitro fertilization in women with inflammatory bowel disease is as successful as in women from the general infertility population. *Clin Gastroenterol Hepatol*. 2015;13(9):1641-46.e3.
14. Pabby V, Oza SS, Dodge LE, et al. In vitro fertilization is successful in women with ulcerative colitis and ileal pouch anal anastomosis. *Am J Gastroenterol*. 2015;110(6):792-7.
15. Oza SS, Pabby V, Dodge LE, et al. Factors associated with the success of in vitro fertilization in women with inflammatory bowel disease. *Dig Dis Sci*. 2016.
16. Friedman S, McElrath TF, Wolf JL. Management of fertility and pregnancy in women with inflammatory bowel disease: A practical guide. *Inflamm Bowel Dis*. 2013;19(13):2937-48.
17. Chung K, Sammel MD, Coutifaris C, et al. Defining the rise of serum HCG in viable pregnancies achieved through use of IVF. *Hum Reprod*. 2006;21(3):823-8.