A rare costovertebral malformation in a Kenyan infant

To the editor: Costovertebral malformations were first described by Saul Jarcho and Paul Levin in 1938.[1] Various terms, including costovertebral dysplasia, spondylocostal dysplasia or dysostosis (SCD or SCDO), Jarcho-Levin syndrome, Lavy-Moseley syndrome, or spondylothoracic dysostosis (STD) or dysplasia have been used.[1] Berdon *et al.*[1] distinguished SCD from STD in their review of early cases based on the clinical features and genotypes available at the time. These malformations have both autosomal recessive and dominant genes affecting the notch signalling pathway that controls somitogenesis and axial skeletogenesis in embryogenesis.[2,3] The International Consortium for Vertebral Anomalies and Scoliosis classifies segmentation defects of the vertebrae (SDVs) into seven broad phenotypes including SCD and STD, based on radiological and clinical features.[3] The global incidence is not well known, but a Spanish registry of congenital anomalies showed that 264 of 1 052 517 live births had SCDO, of which 15 were the Jarcho-Levin phenotype.[4] There are few case reports from sub-Saharan Africa.[5,6] Imaging shows characteristic vertebral and thoracic anomalies involving fusion of the ribs and hemivertebrae, giving the ribcage a 'crab-like' appearance, kyphoscoliosis, and other associated visceral organ anomalies.[1-3] Prenatal three-dimensional (3D) ultrasound as early as 12 weeks can visualise increased fetal nuchal transparency, absent or deformed ribs, deformed vertebrae and distorted spinal architecture including shortening, kyphoscoliosis and spina bifida.[7] Prenatal carrier gene testing for high-risk couples and pre-implantation genetics for the known SDV genotypes is possible.[3] Mortality is high in infancy as a result of respiratory failure and pneumonia.[1,3] In the following case seen at our institution, a baby presented with symptoms of pneumonia and sepsis and was found to have thoracic malformations on imaging. We obtained consent from the hospital Head of Clinical Services and the Ethics and Research Committee to publish this case report, and we have maintained patient anonymity

A term female baby weighing 2 940 g was noted to have developed persistent respiratory distress soon after delivery at a different facility. She was on oxygen therapy but was not ventilated, and was treated for neonatal sepsis and respiratory insufficiency for 2 weeks in the newborn unit (NBU). She presented at our facility at 6 weeks of age with acute-onset cough, fever, vomiting and difficulty in breathing. A chest radiograph had confirmed the presence of vertebral and rib anomalies, and she had a small patent ductus arteriosus, detected by echocardiography while in the NBU. No maternal illness and no teratogenic or environmental exposures were noted, and there was no parental consanguinity or family member with a similar skeletal disorder. She had been immunised on schedule, and had achieved appropriate motor and growth milestones for her age. No feeding or breathing difficulties had been reported since discharge home from the NBU.

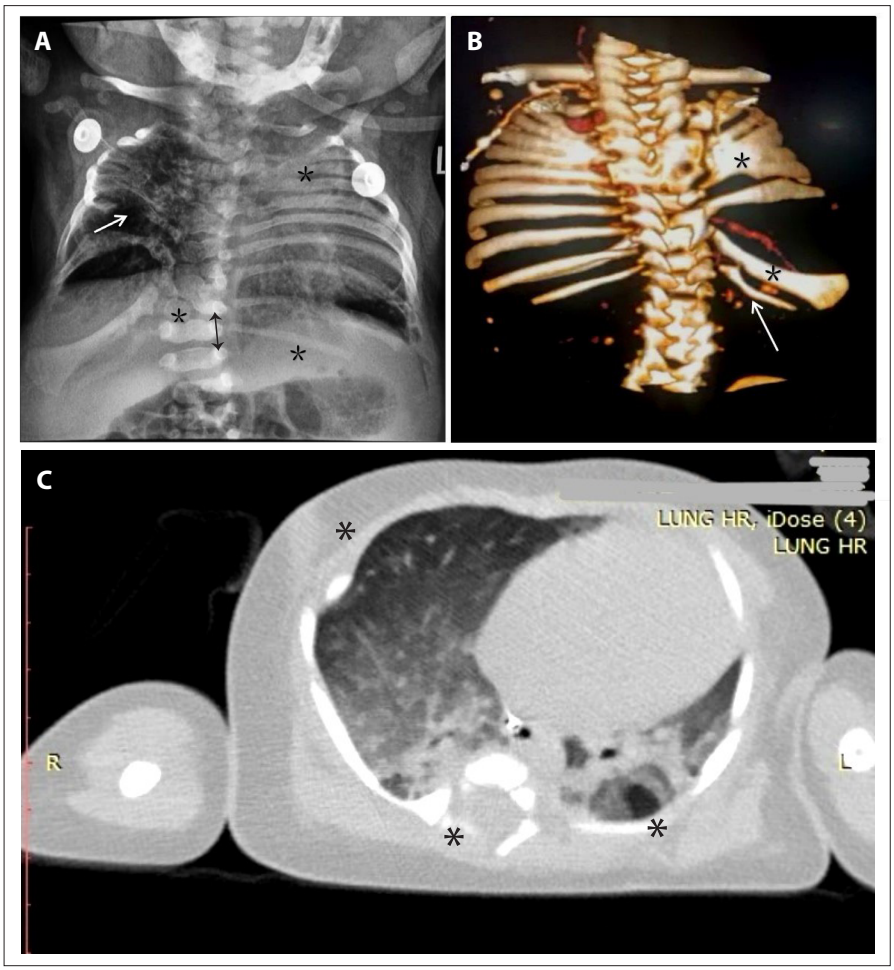

Fig. 1. (A) Chest radiograph. Arrow: rib deformities, absent posterior lower ribs and reduced right lung volume. Top asterisk: fusion of ribs and deformed vertebrae. Bottom asterisk: rib hypoplasia, which is bilateral. Spinal asterisk: hemivertebrae and mild scoliosis. Left vertebral line: pedicular prominence ('tramline' sign). Left lung opacification is also noted. (B) Posterior view of the three-dimensional reconstruction of the spine and ribs, showing a 'crab-like' ribcage. Absent 1st ribs bilaterally. Top right asterisk: fused posterior ribs bilaterally and fused vertebral bodies. Bottom right asterisk: fused ribs 8 and 11. Arrow: hypoplastic 12th rib bilaterally. Scoliosis is better visualised. (C) Computed tomography scan of the chest. Left asterisk: posterior bullae of the lungs with interstitial and cystic lesions in the mid- and upper zones, features of pneumonia/pneumonitis and possible pulmonary malformations. The large airways are normal. Right top asterisk: absent ribs. Right bottom asterisk: spina bifida.

On admission the baby had signs of severe pneumonia and sepsis, and both hypoxia and respiratory acidosis were noted on blood gas analysis. Sputum culture was positive for multidrug-resistant *Enterobacter aerogenes*. Blood culture was negative. A chest radiograph, a 3D computed tomography (CT) chest scan and a contrast-enhanced CT chest scan were done (Fig. 1). Abdominal-pelvic and brain CT scans were normal, and no visceral or skeletal anomalies were noted. She developed new-onset sepsis 2 weeks later. *Enterococcus faecium* was cultured in a urine specimen, and despite intensive care support including mechanical ventilation she progressed to respiratory failure, eventually dying after 3 weeks in hospital.

Our case may be classified as STD because of the phenotype, the severity of defects and the baby's death in early infancy, but genetic testing was not available to confirm it.[1,3] STD and SCDO subtype 2 are caused by pathogenic variants of the mesoderm posterior basic helix-loop-helix transcription factor 2 (*MESP2*) gene, but SCDO has a less severe phenotype. *MESP2* is part of the notch signalling pathway responsible for somite anterior boundary formation of the developing vertebrae during embryogenesis. STD is often fatal in the first year of life because of thoracic restriction of lung growth, respiratory mechanics and airway clearance defects[1,3] cause respiratory insufficiency, progressing to failure and recurrent chest infections. Martínez-Frías *et al*.[4] reported that 70% of their cases were fatal early in life.

In view of the genetic basis of SDVs, it is important to establish a genetic cause, as this facilitates family planning. Seven genotypes have been identified that affect the notch signalling pathway.[8] Genetic testing is now available in our country, but only in a few private centres such as our institution, and it takes several weeks to get results. The tests are costly at USD300 - 2 000, and as they are self-financed, many families are unable to afford them.

For patients with severe defects who survive the neonatal period, implantation of a vertical expandable prosthetic titanium rib (VEPTR) is possible in specialised centres from 6 months of age onwards.[6,9] Approved for use to correct and control spine and thoracic abnormalities, the VEPTR increases the thoracic volume to allow lung growth and is adjusted as the patient grows. It has also been shown to reduce the need for respiratory support, thus enhancing prognosis and quality of life. VEPTRs should be implanted before 2 years of age, as this is the period of maximal alveolar growth.[9]

In conclusion, to improve the outcome of these thoracic disorders in our region, we need to enhance ultrasound screening during the antenatal period, and provide appropriate follow-up during the postnatal period and early neonatal care to support respiration and prevent infections. Pre-implantation and prenatal genetic testing is available for high-risk families. VEPTRs have been shown to improve prognosis, especially when implanted in early childhood.

A Irungu, MB ChB, MMed (Paeds & Child Health), FS Paed Pulm
Paediatric Pulmonology Unit, Division of Paediatrics, Gertrude's Children's Hospital, Nairobi, Kenya
anne.m.irungu@gmail.com

R Patil, MBBS, MD, FS Paed Int Care
Critical Care Unit, Division of Paediatrics, Gertrude's Children's Hospital, Nairobi, Kenya

M N Awori, MB ChB, MMed (Gen Surg), FCS, CTS (ECSA)
Cardiothoracic Unit, Division of Surgery, Gertrude's Children's Hospital, Nairobi, Kenya; Lecturer, Thoracic and Cardiovascular Surgery Unit, Department of Surgery, Faculty of Medicine, University of Nairobi, Kenya

A Metto, MB ChB
Critical Care Unit, Division of Paediatrics, Gertrude's Children's Hospital, Nairobi, Kenya

1. Berdon WE, Lampl BS, Cornier AS, et al. Clinical and radiological distinction between spondylothoracic dysostosis (Lavy-Moseley syndrome) and spondylocostal dysostosis (Jarcho-Levin syndrome). Pediatr Radiol 2011;41(3):384-388. https://doi.org/10.1007/s00247-010-1928-8
2. Lefebvre M, Dieux-Coeslier A, Baujat G, et al. Diagnostic strategy in segmentation defect of the vertebrae: A retrospective study of 73 patients. J Med Genet 2018;55(6):422-429. https://doi.org/10.1136/jmedgenet-2017-104939
3. Turnpenny PD, Sloman M, Dunwoodie S; ICVS (International Consortium for Vertebral Anomalies and Scoliosis). Spondylocostal dysostosis, autosomal recessive. 25 August 2009 (updated 21 December 2017). In: Adam MP, Mirzaa GM, Pagon RA, et al., eds. GeneReviews. Seattle: University of Washington, 1993-2023. https://www.ncbi.nlm.nih.gov/books/NBK8828 (accessed 19 September 2022).
4. Martínez-Frías ML, Bermejo E, Paisán L, et al. Severe spondylocostal dysostosis associated with other congenital anomalies: A clinical/epidemiologic analysis and description of ten cases from the Spanish registry. Am J Med Genet 1994;51(3):203-212. https://doi.org/10.1002/ajmg.1320510306
5. Odéhouri-Koudou TH, Yaokreh JB, Tembély S, et al. Sporadic occurrence of Jarcho-Levin syndrome in an Ivorian newborn. Case Rep Orthop 2013;2013:129625. https://doi.org./10.1155/2013/129625
6. Beighton P, Horan FT. Spondylocostal dysostosis in South African sisters. Clin Genet 1981;19(1):23-25. https://doi.org/10.1111/j.1399-0004.1981.tb00662.x
7. Hull AD, James G, Pretorius DH. Detection of Jarcho-Levin syndrome at 12 weeks' gestation by nuchal translucency screening and three-dimensional ultrasound. Prenat Diagn 2001;21(5):390-394. https://doi.org/10.1002/pd.67
8. Umair M, Younus M, Shafiq S, Nayab A, Alfadhel M. Clinical genetics of spondylocostal dysostosis: A mini review. Front Genet 2022;13:996364. https://doi.org/10.3389/fgene.2022.996364
9. Karlin JG, Roth MK, Patil V, et al. Management of thoracic insufficiency syndrome in patients with Jarcho-Levin syndrome using VEPTRs (vertical expandable prosthetic titanium ribs). J Bone Joint Surg Am 2014;96(21):e181. https://doi.org/10.2106/JBJS.M.00185

Submitted 23 April 2023. Accepted 8 January 2024. Published 4 April 2024.

Afr J Thoracic Crit Care Med 2024;30(1):e984. https://doi.org/10.7196/AJTCCM.2024.v30i1.984