

Functional Medicine

Placenta Percreta With Invasion into the Urinary Bladder

Zachary L. Smith*, Shailen S. Sehgal, Keith N. Van Arsdalen, Irwin S. Goldstein

Division of Urology, Hospital of the University of Pennsylvania, Philadelphia, PA, USA

ARTICLE INFO

Article history:

Received 26 November 2013

Accepted 27 November 2013

Keywords:

Placenta percreta

Placenta previa

Bladder

Cystorrhaphy

Reconstruction

ABSTRACT

Placenta percreta is a rare condition, which can lead to significant morbidity and potentially mortality. We present a case of a 38-year-old woman who presented at 24 weeks gestation with vaginal bleeding and was found to have complete placenta previa with placenta percreta invading the urinary bladder. Her hospital course was complicated by bilateral pulmonary emboli. She underwent an exploratory laparotomy, repeat Caesarean section, and total abdominal hysterectomy. Because of placental invasion into the bladder, the procedure was complicated by bladder and ureteral injuries for which urology carried out repair. Postoperatively, the patient had a persistent bladder leak until postoperative day #39.

© 2014 The Authors. Published by Elsevier Inc. Open access under [CC BY-NC-SA](http://creativecommons.org/licenses/by-nc-sa/4.0/) license.

Introduction

Placenta percreta (PP) is a condition in which the placenta abnormally penetrates entirely through the myometrium and into the uterine serosa. This might be complicated by attachment of the placenta to surrounding structures or organs, such as the urinary bladder or rectum. PP is a potentially fatal condition, and mortality rate is correlated to the extent of involvement of surrounding structures. When PP is complicated by bladder invasion, mortality rates have been estimated as high as 9.5% and 24% for mother and child, respectively.¹ Knowledge of this condition and expectant management are especially important, as the incidence is on the rise—an estimated 50-fold increase in the last 50 years—attributed to the increased frequency of Caesarean deliveries.²

Case presentation

A 38-year-old woman (G₆P₃₀₂₃) at 24 weeks gestation presented with vaginal bleeding. She reported that 1 week before she awoke in a “puddle of fluid.” She denied gross hematuria. She had a history of 3 Caesarean sections. Fetal ultrasound showed complete placenta previa with placental vessels invading the bladder confirming PP (Fig 1). She was admitted for expectant management.

Maternal fetal medicine, anesthesia, neonatal intensive care, and urology were all consulted.

Magnesium sulfate, antibiotics, and steroids were administered prophylactically. On hospital day #2, the patient had an increased oxygen requirement and tachycardia. A computed tomographic scan of the chest revealed extensive bilateral pulmonary emboli. She underwent inferior vena cava filter placement, was transferred to the surgical intensive care unit, and continuous heparin infusion was initiated.

On hospital day #6, the patient went into labor and was taken to the operating room for a multidisciplinary procedure. She underwent exploratory laparotomy and repeat Caesarean section through a fundal uterine incision by the obstetrics team. A viable female neonate was delivered with Apgar scores of 9 and 9. A total abdominal hysterectomy and lysis of adhesions were then performed by the gynecologic oncology service. The anterior uterine wall was then recognized to be affixed to the bladder. Dissection of the anterior uterine wall from the posterior bladder was accompanied by large posterior cystotomy. On routine inspection, decreased efflux was noted from the right ureteral orifice, and the right ureter was markedly dilated.

At this point, intraoperative urology consultation was requested. The right ureter was secured, and a suture was identified that appeared to be constricting it. This was released with immediate return of urine from the ureteral orifice. A double-J ureteral stent was placed, and cystorrhaphy was performed. No leak was identified on bladder irrigation, and an omental flap was placed between the bladder and the vaginal cuff. A Jackson-Pratt drain and a Foley catheter were placed. In total, the patient required resuscitation with 37 units of various blood products.

* Corresponding author. Tel.: +1-267-253-4707; fax: +1-215-615-0247.

E-mail address: Zachary.Smith@uphs.upenn.edu (Z.L. Smith).

The patient's postoperative course was complicated by intermittent fevers and multiple blood transfusions. A voiding cystourethrogram (VCUG) was performed on postoperative day (POD) #14, which demonstrated a small leak from the posterior bladder wall. Foley catheter was maintained, and a repeat VCUG was performed on POD #21 showing persistent leak. She was discharged home with a Foley catheter in place.

At her follow-up visit on POD #39, a VCUG revealed resolution of the leak, and the Foley catheter was removed. The patient's ureteral stent was removed 11 weeks postoperatively.

Discussion

The incidence of PP has increased 50-fold in the last half-century to a currently estimated 1 in 1000 pregnancies. This increased prevalence is attributed to the increased frequency of Caesarean deliveries. The incidence of concomitant bladder invasion is much lower, occurring in approximately 1 in 10,000 births.² The diagnosis of PP might be made during prenatal screening ultrasound; however, bladder involvement is usually not identified until the time of delivery. Symptoms such as gross hematuria, which might be expected, occur in only approximately 25% of cases.³

The gravest complication of PP is severe hemorrhage. Karayalçin et al⁴ described in a series of 73 cases that the most common indication (42.4%) for unplanned hysterectomy was placenta previa and/or accreta. Massive resuscitation with numerous blood products is often required to adequately resuscitate the patient after hemorrhage.

Our management of the case is presented as previously mentioned; however, the methods of handling bladder invasion by PP vary widely. For example, complete surgical devascularization of the uterus before attempting separation from the bladder might decrease the chance of severe hemorrhage. Alternatively, attainment of vascular control at the lower uterine segment by ligation before developing the vesicouterine space might prove beneficial in this endeavor as well. In addition, in some situations, it might be reasonable to preemptively open the bladder adjacent to the uterine attachment. This would allow for direct visualization of the trophoblast invasion of the bladder.

The previously described techniques are useful in that they can be carried out in the hands of a skilled obstetrician. However, a recent analysis of PP with bladder involvement looked at timing of urology consultation relative to outcome. In this series, 2 of 5 cases of PP with bladder invasion underwent preoperative urology consultation, which resulted in no urinary complications in this group. The remaining 3 cases underwent urology consultation during or immediately after surgery and represented 3 bladder injuries and 1 ureteral injury.⁵

It is our opinion that early urologic consultation and operative assistance will decrease the incidence and/or severity of urinary complications during surgical management of PP with bladder involvement. After review of our case, we would recommend preoperative placement of ureteral catheters and early intraoperative consultation. Ureteral catheter placement is a well-established method of decreasing the incidence of ureteral injury during gynecologic operations. However, the incidence of PP with bladder invasion is exceedingly rare and is often managed in an

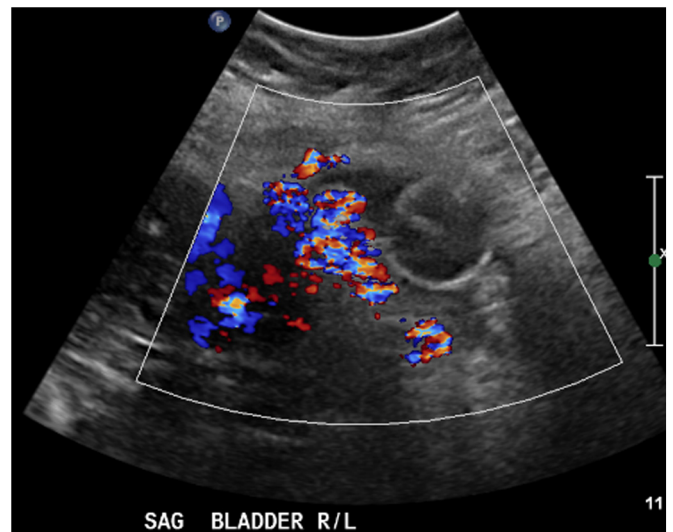


Figure 1. Color Doppler ultrasound at 24 wk gestation. Ultrasound demonstrates complete placenta previa with an enlarged placenta with prominent vascularity throughout the myometrium with loss of the retroplacental clear space, consistent with placenta accreta. The bladder is poorly distended during this examination; however, there does appear to be irregular soft tissue extending into the bladder near the dome and demonstration of several prominent vessels crossing from the anterior myometrium into the region of the bladder. Findings are highly suspect for placenta percreta with invasion into the bladder.

emergent fashion precluding the preoperative placement of ureteral catheters. This is all the more the reason for anticipatory urologic consultation as soon as available.

Conclusion

PP is a morbid condition of increasing incidence. It should be considered in any pregnant patient presenting with gross hematuria, although this is not a sensitive finding. A previous history of Caesarean section might be associated with PP; however, there has been no correlation between other pelvic procedures to this condition, making screening even more difficult. After review of our case and the current published data available, it is our opinion that early urologic consultation and a multidisciplinary approach to delivery and management are of utmost importance. If possible, preoperative ureteral catheter placement is recommended to aid in intraoperative identification of ureters.

References

1. Price FV, Resnik E, Heller KA, Christopherson WA. Placenta previa percreta involving the urinary bladder: a report of two cases and review of the literature. *Obstet Gynecol.* 1991;78(3 Pt 2):508–511.
2. Abbas F, Talati J, Wasti S, et al. Placenta percreta with bladder invasion as a cause for life threatening hemorrhage. *J Urol.* 2000;164:1270–1274.
3. Takai N, Eto M, Sato F, et al. Placenta percreta invading the urinary bladder. *Arch Gynecol Obstet.* 2005;271:274–275.
4. Karayalçin R, Ozcan S, Ozyer S, Mollamahmutoglu L, et al. Emergency peripartum hysterectomy. *Arch Gynecol Obstet.* 2011 Apr;283:723–727.
5. Ng MK, Jack GS, Bolton DM, Lawrentschuk N. Placenta percreta with urinary tract involvement: the case for a multidisciplinary approach. *Urology.* 2009 Oct;74:778–782. Epub 2009 Jul 30.