



# Acute Cerebellar Ataxia Associated with COVID-19 Infection in a 5-Year-Old Boy

Kimberly A O'Neill, MD  and Aparna Polavarapu, MD

## Abstract

**Background:** Neurologic manifestations can occur in many adult patients with COVID-19 but are less frequently described in the literature than the respiratory or inflammatory effects of the disease. There are even fewer reports of the neurologic manifestations of the disease in children. **Case Report:** A 5-year-old boy with type I diabetes mellitus had minimal symptoms from COVID-19 infection. Eight days later, he developed acute ataxia, double vision, tremor, and dysmetria. Cerebrospinal fluid (CSF) and imaging were unremarkable. He was treated with supportive care and discharged home after 4 days. Neurologic symptoms gradually improved and resolved at 2 month follow up. **Conclusion:** Providers should be aware of acute cerebellar ataxia as a possible complication in pediatric patients recovering from COVID-19.

## Keywords

ataxia, brain, cerebellum, children, MRI, neuroimaging, pediatric

Received September 27, 2021. Received revised October 20, 2021. Accepted for publication November 16, 2021.

## Introduction

Severe acute respiratory syndrome coronavirus 2 (SARS-CoV-2) was first described in December 2019 and is responsible for causing the COVID-19 disease and the worldwide pandemic. As of September 2021, about 220 million people have been infected with the disease, sometimes fatally with 4.5 million deaths.<sup>1</sup> In general, COVID-19 appears to affect adults more severely than children. Currently, children make up about 13 to 15% of cases, 2 to 3% of hospitalizations, and <0.25% of deaths in the United States.<sup>2</sup>

Neurologic manifestations can occur in 35 to 82% of adult patients with COVID-19 but are less frequently described in the literature than the respiratory or inflammatory effects of the disease.<sup>3,4</sup> Neurologic complications include anosmia, ageusia, encephalopathy, stroke, central nervous system demyelination or peripheral nervous system involvement. There are even fewer reports of the neurologic manifestations in children, although some centers describe neurologic symptoms in up to 43% of children hospitalized with COVID-19.<sup>5</sup> Most cases are related to multisystem inflammatory syndrome in children (MIS-C).<sup>6,7</sup>

Acute cerebellar ataxia, an illness that most often affects children, has been described previously in a 13-year-old boy after COVID-19 infection by Tomar et al.<sup>8</sup> Here, we report a case of acute cerebellar ataxia associated with COVID-19 infection in a patient age 5.

## Case Presentation

A 5-year-old boy with type I diabetes mellitus was exposed by a classmate with COVID-19 illness. The patient's family was tested, and all members resulted positive. Over the next few days, the young boy had minimal symptoms, described as rhinorrhea and decreased energy. Besides the initial testing encounter, the family did not seek medical care as he was relatively well, and they isolated at home as the COVID-19 pandemic continued in New York City in March 2021.

Eight days later, the patient's parents noted he was off-balanced while walking. He also reported "seeing double"; his hands were shaking, causing him to drop things like his glass of milk. He had one low grade fever to 101 degrees F and mildly decreased appetite but otherwise appeared well, so the family monitored him at home. His blood glucose was in the normal range for him. Eleven days after the initial exposure

Montefiore Medical Center, Albert Einstein College of Medicine, Bronx, NY, USA

## Corresponding Author:

Kimberly A. O'Neill, Division of Child Neurology, Montefiore Medical Center, Albert Einstein College of Medicine, 111 East 210th St, NW1 Rm 020, Bronx, NY 10467, USA.

Email: [kioneil@montefiore.org](mailto:kioneil@montefiore.org)



Creative Commons Non Commercial CC BY-NC: This article is distributed under the terms of the Creative Commons Attribution-NonCommercial 4.0 License (<https://creativecommons.org/licenses/by-nc/4.0/>) which permits non-commercial use, reproduction and distribution of the work without further permission provided the original work is attributed as specified on the SAGE and Open Access page (<https://us.sagepub.com/en-us/nam/open-access-at-sage>).

to COVID-19, the mother reported these symptoms to his endocrinologist who encouraged them to go to the emergency room. By this time, he was unable to ambulate independently and needed to hold onto something in order to walk. He had swaying truncal movements while sitting upright. His hands would shake while he played with his toys. Otherwise, he was thinking clearly and was his normal active self.

The family reported all medications were stored away in the house and the patient did not have access to them. Of note, in addition to over-the-counter medications like acetaminophen or ibuprofen, his father was on an immunosuppressant regimen for a kidney transplant. Family denied any new foods or exposure at home. He did not receive any vaccinations during this time. There was no family history of progressive or episodic ataxia.

He was diagnosed with type 1 diabetes mellitus one year earlier with serum testing positive for glutamic acid decarboxylase (GAD) antibodies (value 47 IU/mL) and islet cell antibodies. His home medications included basal and bolus insulin injections, and he wore a Dexcom G6 continuous glucose monitor. Despite treatment, he had variable glucose levels and a most recent hemoglobin A1c value of 10%. He had an episode of gross hematuria in the past that was attributed to nephrolithiasis. He had a family history of kidney disease.

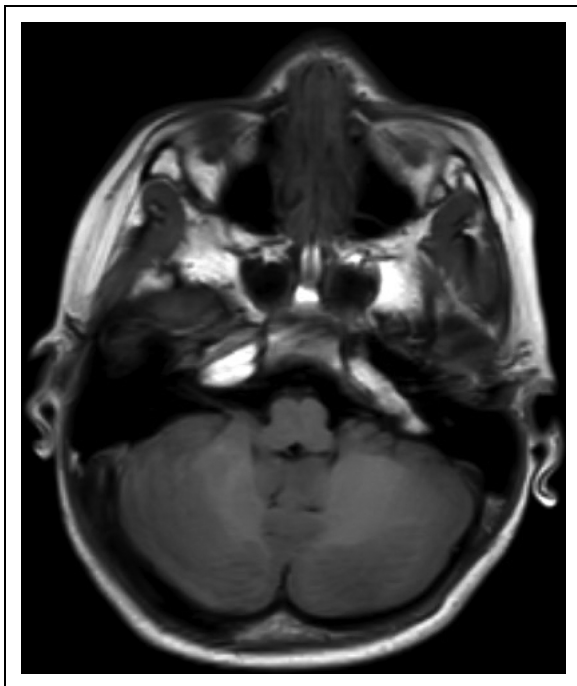
On physical examination, his temperature was 36.6 °C, blood pressure 110/73 mm Hg, heart rate 73 beats/min, respiratory rate 28 breaths/min, and oxygen saturation 99% on room air. His initial glucose was 265 mg/dL. He was well appearing and playful. His mental status was appropriate for his age. Neurologic examination showed mild dysarthria, truncal titubation, irregular rapid alternating hand movements, bilateral

dysmetria on finger-to-nose and heel-to-shin testing. His gait was wide-based and ataxic. He was unable to tandem. The rest of the neurologic examination was unremarkable. Notably, he had no nystagmus.

Laboratory workup revealed normal routine studies except for a decreased sodium of 129 mEq/L (normal 135-145 mEq/L), elevated creatinine 0.84 mg/dL (normal <0.6 mg/dL), and elevated glucose 511 mg/dL (normal 70-140 mg/dL). SARS-CoV-2 IgG nucleocapsid antibody serum testing was positive. Nasopharyngeal swab was positive for SARS-CoV-2 (COVID-19) by polymerase chain reaction (PCR). Urinalysis showed elevated glucose to >1000 mg/dL and ketones to 15 mg/dL, although this was close to his prior baseline studies. Otherwise, complete blood count (CBC), basic metabolic panel (BMP), liver function test (LFT), C-reactive protein (CRP), erythrocyte sedimentation rate (ESR), and venous blood gas (VBG) were unrevealing. During hospitalization, his glucose levels had a wide range (105-511 mg/dL) but the studies were never consistent with diabetic ketoacidosis.

Cerebrospinal fluid (CSF) was obtained. The opening pressure was elevated to 28 cm H<sub>2</sub>O but he was moving during testing. CSF was clear and colorless with 8 WBC (normal <5 cells/uL) and 0 RBC (normal 0 cells/uL). Manual differential showed 86% lymphocytes and 14% monocytes. CSF total protein was 20 (normal 10-40 mg/dL) and glucose was 110 mg/dL. Other infectious testing sent from the CSF resulted negative. The CSF sample was sent to the New York State Department of Health and tested negative for SARS-CoV-2. Brain magnetic resonance imaging (MRI) with and without contrast was normal on hospital day 2 (Figure 1).

The patient remained admitted for 4 days, with some improvement in his ataxia. He was discharged home with a rolling walker and outpatient physical therapy. Although he continued to have some balance issues one month after discharge, by two months his symptoms had completely resolved.



**Figure 1.** Normal axial T1-weighted MRI of the cerebellum.

## Discussion

Acute cerebellar ataxia is the most common cause of acute ataxia in children. It usually affects children 2 to 5 years of age and often occurs after a recent febrile illness. Symptoms include double vision, difficulty with speech, uncoordinated movements, nausea, vomiting, truncal and gait ataxia. Workup is required to rule out other causes of acute ataxia including intoxication, infection, tumor, or metabolic disease. CSF studies may be normal or show pleocytosis or elevated protein. MR imaging is most often normal.<sup>9</sup> Abnormalities on MRI may classify the diagnosis as acute cerebellitis, although this nomenclature is debated.<sup>10-12</sup> Children often have a self-limited course and return to baseline over the course of a few months. The treatment is mostly supportive.<sup>11</sup>

Pediatric acute cerebellar ataxia after COVID-19 infection has previously been reported by Tomar in 2021. In this case, a 13-year-old boy developed mild respiratory symptoms and tested positive for SARS-CoV-2 by nasopharyngeal swab. Over 10 days later, he presented with symptoms of clumsiness

and ataxia. His repeat testing was notable for negative nasopharyngeal swab, but positive COVID serum antibodies. He had normal CSF without pleocytosis and normal imaging. He was treated with intravenous methylprednisolone and had improvement of symptoms over 20 days.<sup>8</sup>

An adult case of acute cerebellar ataxia associated with COVID-19 infection was described by Povlow in 2021. A 30-year-old male presented with nausea, vomiting, slurred speech and difficulty walking and tested positive for SARS-CoV-2 by PCR. CSF showed mild pleocytosis and MRI was normal. He had some improvement over his 10-day hospital stay with supportive treatment.<sup>13</sup>

Although acute cerebellar ataxia is a relatively frequent diagnosis in children, there have not been many reports in children affected by COVID-19. This may be due to children's relative resistance to the effects of severe illness from SARS-CoV-2. Some theorize that COVID-19 may cause more deleterious effects or sequela in children that are immunocompromised or suffer from a chronic illness,<sup>5</sup> as our patient did with poorly controlled type 1 diabetes mellitus. Interestingly, acute cerebellar ataxia is most commonly seen in age 2 to 5,<sup>9</sup> yet there has not been a previous reported case in this age group associated with COVID-19 infection.

Although children appear to be relatively resilient to the effects of the SARS-CoV-2 virus and COVID-19 infection, they can suffer neurologic manifestations of the disease. Further research is needed to better understand which pediatric patients are at risk for neurologic symptoms and the mechanism behind nervous system involvement.

As most school districts send children back to classrooms in Fall 2021, physicians should be aware of cerebellar ataxia in children recently affected by COVID-19.

### Acknowledgments

Our team would like to acknowledge Dr. Solomon Moshe, MD for his assistance with this case.

### Declaration of Conflicting Interests

The author(s) declared no potential conflicts of interest with respect to the research, authorship, and/or publication of this article.

### Funding

The author(s) received no financial support for the research, authorship and/or publication of this article.

### ORCID iD

Kimberly A O'Neill  <https://orcid.org/0000-0001-6021-8683>

### References

1. Prevention. CDC COVID Data Tracker 2021. Updated September 18, 2021. <https://covid.cdc.gov/covid-data-tracker/#datatracker-home>.
2. Pediatrics AAP Children and COVID-19: State-Level Data Report [Website]. 2021. Updated September 13, 2021. <https://www.aap.org/en/pages/2019-novel-coronavirus-covid-19-infections/children-and-covid-19-state-level-data-report/>.
3. Mao L, Jin H, Wang M, et al. Neurologic manifestations of hospitalized patients with coronavirus disease 2019 in wuhan, China. *JAMA Neurol.* 2020;77(6):683.
4. Liotta EM, Batra A, Clark JR, et al. Frequent neurologic manifestations and encephalopathy-associated morbidity in covid-19 patients. *Ann Clin Transl Neurol.* 2020;7(11):2221-2230.
5. Lin JE, Asfour A, Sewell TB, et al. Neurological issues in children with COVID-19. *Neurosci Lett.* 2021;743:135567.
6. Abdel-Mannan O, Eyre M, Löbel U, et al. Neurologic and radiographic findings associated with COVID-19 infection in children. *JAMA Neurol.* 2020;77(11):1440.
7. Feldstein LR, Rose EB, Horwitz SM, et al. Multisystem inflammatory syndrome in U.S. Children and adolescents. *N Engl J Med.* 2020;383(4):334-346.
8. Tomar LR, Shah DJ, Agarwal U, Batra A, Anand I. Acute post-infectious cerebellar ataxia due to COVID-19. *Mov Disord Clin Pract.* 2021;8(4):610-612.
9. Connolly AM, Dodson WE, Prensky AL, Rust RS. Course and outcome of acute cerebellar ataxia. *Ann Neurol.* 1994;35(6):673-679.
10. Emelifeonwu JA SJ, Kaliaperumal C, Gallo P, Sokol D, Soleiman H, Kandasamy J. Acute cerebellitis in children: a variable clinical entity. *J Child Neurol.* 2018;33(10):675-684.
11. Thakkar K, Maricich SM, Alper G. Acute ataxia in childhood: 11-year experience at a major pediatric neurology referral center. *J Child Neurol.* 2016;31(9):1156-1160.
12. Fadakar N, Ghaemmaghami S, Masoompour SM, et al. A first case of acute cerebellitis associated with coronavirus disease (COVID-19): a case report and literature review. *Cerebellum.* 2020;19(6):911-914.
13. Povlow A, Auerbach AJ. Acute cerebellar ataxia in COVID-19 infection: a case report. *J Emerg Med.* 2021;60(1):73-76.