

## CASE REPORT

## Endovascular Treatment of Thoracic Aortic Pseudoaneurysm Through a Subclavian Approach in Patient with Aortoiliac Occlusive Disease: A Case Report

Ezequiel Paredes-Mariñas <sup>a,\*</sup>, Carme Llorc-Pont <sup>a</sup>, Francisca Castro-Balance <sup>a</sup>, Vicente Rimbau-Alonso <sup>b</sup>

<sup>a</sup>Vascular Surgery Department, Hospital del Mar, Barcelona, Spain

<sup>b</sup>Vascular Surgery Division, Hospital Clinic, Barcelona, Spain

**Introduction:** Thoracic endovascular aortic repair (TEVAR) has become the preferred option for treatment of thoracic aortic pathology, but lack of vascular access options is a common contraindication to TEVAR.

**Case report:** The authors report a case of a 67 year old male patient with multiple revascularisation procedures: bilateral axillofemoral bypass and thoracic aortofemoral bypass, both occluded. An anastomotic pseudoaneurysm of the thoracic aorta developed and detected on computed tomography angiography (CTA). A femoral artery approach could not be performed because of complete occlusion of both iliac arteries. A left subclavian artery approach was performed and through a Dacron prosthetic graft extension anastomosed to the proximal segment of the occluded axillofemoral bypass a distal component of a Zenith Alpha endograft (Cook®) was successfully deployed upside down. There was a good seal without endoleaks and no complications.

**Conclusion:** In patients with aortic bypass systematic follow up is important to detect anastomotic pseudoaneurysm and prevent its related complications. TEVAR may be offered for the treatment of thoracic aortic aneurysm pathology even in patients with a lack of vascular access. In the absence of a standard iliofemoral approach, use of an alternative subclavian approach may be considered. The reduction of the carrier system profiles allows performance of TEVAR with safety and efficiency.

© 2018 The Authors. Published by Elsevier Ltd on behalf of European Society for Vascular Surgery. This is an open access article under the CC BY-NC-ND license (<http://creativecommons.org/licenses/by-nc-nd/4.0/>).

Article history: Received 27 February 2018, Revised 1 May 2018, Accepted 3 May 2018,

**Keywords:** Thoracic, Aorta, Pseudoaneurysm, TEVAR, Vascular, Access

### INTRODUCTION

Thoracic endovascular aortic repair (TEVAR) has become the preferred option for treatment of thoracic aortic pathology, but lack of vascular access options is a common contraindication to TEVAR. Herein, the case of a 67 year old male patient with a pseudoaneurysm of the thoracic aorta and bilateral aortoiliac occlusion successfully treated using a subclavian approach is presented.

### CASE REPORT

A 67 year old male patient with hypertension, dyslipidaemia, obesity, chronic obstructive pulmonary disease, sleep apnea syndrome, right ventricular dysfunction secondary to severe pulmonary hypertension, ischaemic stroke and left hemiparesis with complete recovery and without significant carotid stenosis, and normal renal function, presented intermittent claudication of the lower extremities

secondary to bilateral aortoiliac occlusion with multiple previous revascularisation procedures: bilateral axillofemoral bypass and thoracic aortofemoral bypass, both occluded (Fig. 1). An anastomotic pseudoaneurysm (APA) of the thoracic aorta measuring 102×87 mm was observed on computed tomography angiography (CTA) (Fig. 2).

After a comprehensive evaluation of the imaging findings and of the patient's condition, the case was considered suitable for an endovascular repair. TEVAR was chosen given the high anaesthetic risk and avoidance of abdominal re-intervention morbidity and mortality. The Zenith Alpha Thoracic endograft (Cook®) was considered because of its lower profile introduction system. This endograft was developed to address vascular access issues associated with larger profile devices and to increase conformability in tortuous anatomy.

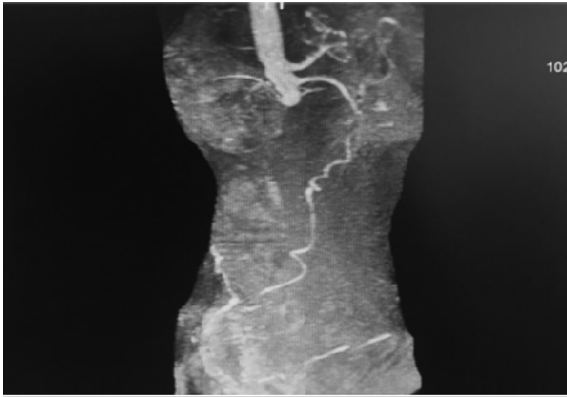
A femoral artery approach, the most common for TEVAR, could not be performed because of complete occlusion of both iliac arteries. A left subclavian artery approach was performed with local anaesthesia. After dissection of the proximal anastomosis of the occluded axillofemoral bypass, a Dacron prosthetic graft (8 mm) was anastomosed to the proximal segment of the bypass (Fig. 3). Arterial control was achieved with a clamp and a Flexor® Introducer Sheath

\* Corresponding author.

E-mail address: [eparedesma@gmail.com](mailto:eparedesma@gmail.com) (Ezequiel Paredes-Mariñas).

2405-6553/© 2018 The Authors. Published by Elsevier Ltd on behalf of European Society for Vascular Surgery. This is an open access article under the CC BY-NC-ND license (<http://creativecommons.org/licenses/by-nc-nd/4.0/>).

<https://doi.org/10.1016/j.ejvssr.2018.05.002>



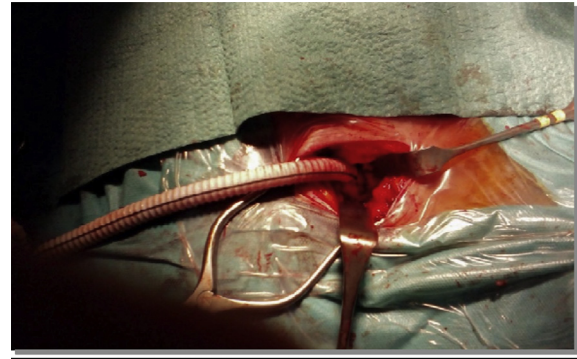
**Figure 1.** Infrarenal aortic occlusion.

(Cook®) was placed inside the subclavian artery. The catheterisation of the aortic arch was made with a hydrophilic guide wire and angiography was performed through the pigtail flush catheter. After replacing the hydrophilic guide wire with a Lunderquist wire, a 34×142 mm distal component of a Zenith Alpha endograft (Cook®) (18 Fr introducer sheath) was advanced through the Dacron prosthetic extension and placed in the thoracic aorta. It was then deployed upside down using fluoroscopy for guidance and avoiding twisting. Finally, a molding balloon was performed sealing the aortic pseudoaneurysm successfully. Final angiography showed a good seal and there were no endoleaks or complications during the post-operative period (Fig. 4).

One month later, complete exclusion of APA was observed with no endoleaks or complications on follow up CTA.

## DISCUSSION

Thoracic endovascular aortic repair has become the preferred approach for the treatment of thoracic aortic



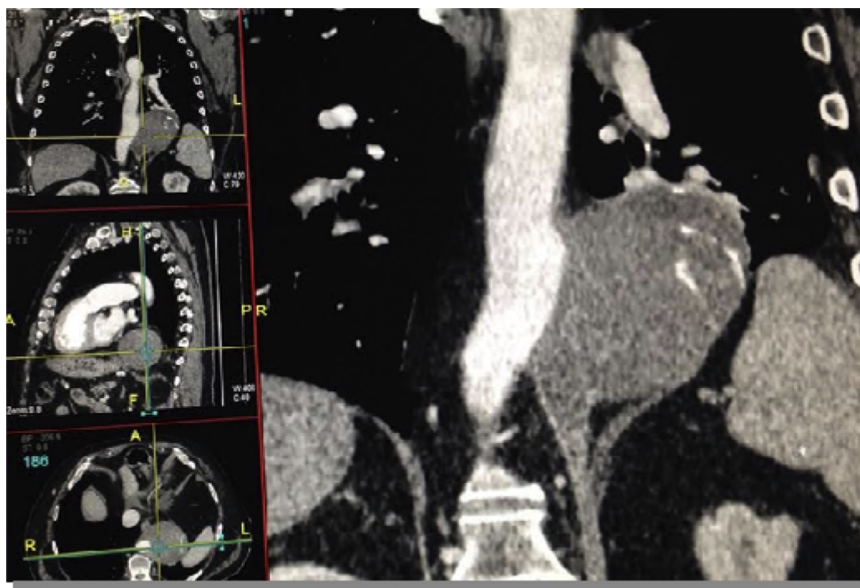
**Figure 3.** Dacron prosthesis extension from a left subclavian artery approach.

pathology since the approval of the first endograft device by the U.S. Food and Drug Administration (FDA) in 2005.<sup>1</sup> Pseudoaneurysms can be treated in the same way as aortic aneurysms with endoprosthesis or stent graft positioning with anchorages placed in the healthy pre- and post-anastomotic arterial lumen possibly oversized to avoid migration.<sup>2–4</sup>

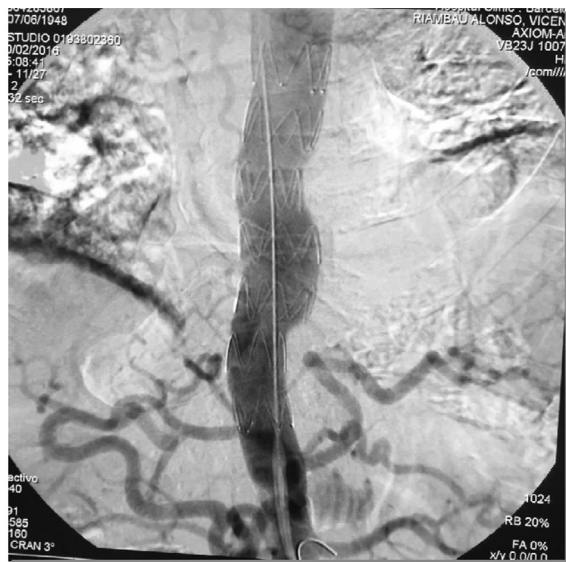High mortality rates for open surgery have been reported. Emergency surgical repair has 70–83% morbidity and 8–70% mortality as most APAs occur in elderly patients with several comorbidities. The need for prolonged aortic clamping in the presence of comorbidities and of a hostile abdomen, because of previous retroperitoneal intervention, often makes surgery challenging.<sup>2,3,5–10</sup>

Moreover, TEVAR enables safe and effective aneurysm exclusion, can be used for treatment of patients in critical conditions, and is associated with shorter operating times, minimal additional blood loss, and lower fluid requirements.<sup>11,12</sup>

Unfavourable anatomy is the main contraindication to TEVAR, which may include inadequate proximal or distal seal zones, tortuosity, extremes of aortic diameter, or lack of



**Figure 2.** Thoracic aorta pseudoaneurysm.



**Figure 4.** Thoracic aortic endograft sealing the pseudoaneurysm.

vascular access options.<sup>13</sup> Commonly the procedure is performed by gaining femoral access for placement of the relatively large sheath required for TEVAR.<sup>14</sup> Poor access has been reported as the most common exclusion criterion for endovascular aneurysm repair and the leading cause of conversion to open repair. That is the reason why alternative approaches may need to be considered.<sup>15</sup>

In the present case, the option for TEVAR was based on the patient's anaesthetic risk and previous attempts at revascularisation. The absence of a femoral artery approach, the need for a Dacron prosthetic extension in the subclavian approach, and an angulated aortic arch, were challenging technical features which had to be managed to successfully to perform TEVAR.

Devices have undergone changes in terms of the design and the materials used to achieve a lower profile, therefore increasing the number of patients for whom endovascular repair is suitable.<sup>16</sup> Profile reduction must lead to significant benefits for the patient, including safer and shorter procedures, decreased pain and discomfort, and faster recovery, all without compromising the durability and long-term effectiveness of the repair.<sup>17</sup>

## CONCLUSION

In patients with aortic bypass systematic follow up is important to detect APA and prevent its related complications. TEVAR may be offered in the treatment of thoracic aortic aneurysm pathology even in patients with lack of vascular access. In the absence of a standard iliofemoral approach, the use of an alternative subclavian approach may be considered. The reduction of the carrier system profile allows for safe and efficient performance of TEVAR.

## REFERENCES

- Najibi S, Terramani T, Weiss VJ, Mac Donald MJ, Lin PH, Redd DC, et al. Endoluminal versus open treatment of descending thoracic aortic aneurysms. *J Vasc Surg* 2002;**36**:732–7.
- Trentadue M, Puppini G, Perandini S, Mezzetto L, Veraldi GF, Montemezzi S, et al. Endovascular repair of an unusually complex anastomotic pseudoaneurysm of an aorto-bisiliac graft. *Pol J Radiol* 2017;**82**:244–7. <https://doi.org/10.12659/PJR.899825>. 2017 May 1.
- Curti T, Stella A, Rossi C, Galaverni C, Saccà A, Resta F, et al. Endovascular repair as first-choice treatment for anastomotic and true iliac aneurysms. *J Endovasc Ther* 2001;**8**:139–43.
- Magnan PE, Albertini JN, Bartoli JM, Ede B, Valerio N, Moulin G, et al. Endovascular treatment of anastomotic false aneurysms of the abdominal aorta. *Ann Vasc Surg* 2003;**17**:365–74.
- Ten Bosch JA, Waasdorp EJ, de Vries JP, Moll FL, Teijink JA, van Herwaarden JA. The durability of endovascular repair of para-anastomotic aneurysms after previous open aortic reconstruction. *J Vasc Surg* 2011;**54**:1571–8.
- Duvnjak S, Andersen PE, Larsen KE, Roeder O. Endovascular repair of postoperative vascular graft related complications after aorto-iliac surgery. *Int Angiol* 2014;**33**:386–91.
- Lagana D, Carrafiello G, Mangini M, Recaldini C, Lumia D, Cuffari S, et al. Endovascular treatment of anastomotic pseudoaneurysms after aorto-iliac surgical reconstruction. *Cardiovasc Intervent Radiol* 2007;**30**:1185–91.
- Morrissey NJ, Yano OJ, Soundararajan K, Eisen L, McArthur C, Teodorescu V, et al. Endovascular repair of para-anastomotic aneurysms of the aorta and iliac arteries: preferred treatment for a complex problem. *J Vasc Surg* 2001;**34**:503–12.
- Tiesenhausen K, Hausegger KA, Tauss J, Amann W, Koch G. Endovascular treatment of proximal anastomotic aneurysms after aortic prosthetic reconstruction. *Cardiovasc Intervent Radiol* 2001;**24**:49–52.
- Locati P, Socrate AM, Costantini E. Paraanastomotic aneurysms of the abdominal aorta: a 15-year experience review. *Cardiovasc Surg* 2000;**8**:274–9.
- Minami T, Imoto K, Uchida K, Karube N, Yasuda S, Choh T, et al. Thoracic endovascular aortic repair for ruptured descending thoracic aortic aneurysm. *J Card Surg* 2015;**30**:163–9.
- Botsios S, Frömke J, Walterbusch G, Schuermann K, Reinstadler J, Dohmen G. Endovascular treatment for non-traumatic rupture of the descending thoracic aorta: long-term results. *J Card Surg* 2014;**29**:353–8.
- Aranson NJ, Watkins MT. Percutaneous interventions in aortic disease. *Circulation* 2015;**131**:1291–9. <https://doi.org/10.1161/CIRCULATIONAHA.114.006512>.
- Lee WA, Brown MP, Nelson PR, Huber TS. Total percutaneous access for endovascular aortic aneurysm repair ("Preclose" technique). *J Vasc Surg* 2007;**45**:1095–101.
- Murray D, Ghosh J, Khwaja N, Murphy MO, Baguneid MS, Walker MG. Access for endovascular aneurysm repair. *J Endovasc Ther* 2006;**13**:754–61.
- Bersin R. The evolution of low-profile endograft design. *Endovascular Today* 2011;**9**:54–8.
- Nzara R, Rybin D, Doros G, Didato S, Farber A, Eslami MH, et al. Perioperative outcomes in patients requiring iliac conduits/access for endovascular abdominal aortic aneurysm repair. *Ann Vasc Surg* 2015;**29**:1548–53.